




Contents lists available at ScienceDirect

JPRAS Open

journal homepage: <http://www.journals.elsevier.com/jpras-open>

Medial canthal reconstruction with multiple local flaps[☆]

Akihiro Ogino^{*}, Kiyoshi Onishi, Emi Okada, Miho Nakamichi

Department of Plastic and Reconstructive Surgery, Toho, University Omori Medical Center, Tokyo, Japan

ARTICLE INFO

Article history:

Received 3 February 2017

Accepted 13 August 2017

Available online 29 September 2017

Keywords:

Medial canthal reconstruction

Glabellar flap

Rintala flap

Orbicularis oculi myocutaneous flap

ABSTRACT

Background: It is often difficult to reconstruct comparatively large defects in the medial canthal region. The authors have performed reconstruction with multiple local flaps in 4 medial canthal defects after resection of malignant skin tumors.

Method: The defects exceeded the medial canthal region, extending to the upper eyelid and the lower eyelid. The medial canthal defect was covered by transposition of a glabellar flap, the upper eyelid defect was covered by an upper eyelid myocutaneous advancement flap, and the lower eyelid defect was covered by a cheek rotation flap. Then the donor site of the glabellar flap was covered by a Rintala flap.

Results: There was no recurrence in any of the cases, and good results were obtained. One case showed mild linear contracture, but the patient did not want corrective surgery.

Conclusion: This method is somewhat complicated compared to reconstruction with a single flap, but it is a combination of standard local flaps and is a simple reconstructive procedure. By adding additional resection, the suture line is consistent with the border of the facial unit, so postoperative scarring is inconspicuous. This technique is aesthetically useful because of the continuity of colour and texture resulting from the use of adjacent flaps.

© 2017 The Author(s). Published by Elsevier Ltd on behalf of British Association of Plastic, Reconstructive and Aesthetic Surgeons. This is an open access article under the CC BY-NC-ND license (<http://creativecommons.org/licenses/by-nc-nd/4.0/>).

[☆] The contents of this article are added to the contents presented at the 59th Annual Meeting of the Japanese Society of Plastic Surgery (15 April 2016, Fukuoka, Japan).

^{*} Corresponding author. Department of Plastic and Reconstructive Surgery, Toho, University Omori Medical Center, 6-11-1, Omori-nishi, Ota-ku, Tokyo 143-8541, Japan.

E-mail address: akihiro.ogino@med.toho-u.ac.jp (A. Ogino).

<https://doi.org/10.1016/j.jpra.2017.08.007>

2352-5878/© 2017 The Author(s). Published by Elsevier Ltd on behalf of British Association of Plastic, Reconstructive and Aesthetic Surgeons. This is an open access article under the CC BY-NC-ND license (<http://creativecommons.org/licenses/by-nc-nd/4.0/>).

Introduction

The medial canthal region has the least skin excess, thin subcutaneous tissue, and has a characteristic form showing a depression in the centre. The medial canthal region is also a common site for malignant skin tumours, particularly basal cell carcinoma, and when a defect after tumour resection extends to the nasal sidewall and dorsum, the upper and lower eyelids, and extends to deep tissues such as the periosteum and medial canthal ligament, it may be difficult to reconstruct. In medial canthal reconstruction, the continuity of colour and texture, skin thinness and reproduction of the natural external appearance are required, and reconstruction with a flap adjacent to the defect is desirable.

Spinelli et al.¹ divided the periocular region into 5 zones, and recommended selecting the reconstruction method considering each regional feature. In this report, reconstruction with multiple flaps was performed in cases of tissue defects in the medial canthal region that extended to the upper and lower eyelids. That is, the defect was divided into the medial canthal, the upper eyelid, and the lower eyelid, and each defect was reconstructed by an individual flap. Medial canthal defects were covered by transposition of a glabellar flap. Upper eyelid defects were covered by an upper eyelid myocutaneous advancement flap, and lower eyelid defects were covered by a cheek rotation flap. The donor site of glabellar flap was then covered by a Rintala flap. This report describes the surgical procedures and outlines our clinical cases.

Subjects and methods

The subjects of this study were four patients admitted to our department. All patients were male, aged 54 to 75 years. The original disease was a basal cell carcinoma in three cases, and a squamous cell carcinoma in one case. The defects had a maximum diameter of 22 to 37 mm.

Surgical procedures

In all cases, surgery was performed under general anaesthesia. The incised margin was usually 5 mm from the tumour and the incision depth was usually as deep as the periosteum or the medial canthal ligament. Complete resection of the tumour was confirmed by intraoperative pathological diagnosis.

The operative procedure is shown in [Figure 1](#). This is a case of basal cell carcinoma ([Figure 1A](#)). The defect after tumour resection exceeded the medial canthal, extending from the nasal dorsum to the inside of the upper eyelid and the inside of the lower eyelid. There was no damage to the lacrimal duct or medial canthal ligament ([Figure 1B](#)). The repaired defect of the nasal dorsum should match with the border of the facial unit, by adding an additional resection and placing the scar in the midfacial line. The defect was divided into the medial canthal, the upper eyelid, and the lower eyelid according to the periocular zone classification.

Reconstruction of the medial canthal region: We designed a rectangular glabellar flap with the lateral border of the topographic curve heading from the lateral side of the nasal dorsum to the medial side of the eyebrow on the side of the glabella adjacent to the defect. The flap was elevated with the caudal subcutaneous tissue as a pedicle and prepared to gradually become thinner from the proximal toward the distal side. The flap was transposed to the medial canthal defect, and an anchor suture fixation was performed on the medial canthal ligament ([Figure 1C](#)).

Reconstruction of the upper eyelid medial side: The inferior border of the eyebrow and the upper eyelid were incised, and the upper eyelid myocutaneous flap was elevated with the lateral side as a pedicle and advanced to the defect ([Figure 1D](#)).

Reconstruction of the lower eyelid medial side: We extended the lower eyelid incision outward, elevated the cheek flap and rotated it inward. Excess skin on the lateral side of nose was excised ([Figure 1E](#)).

Finally, a Rintala flap was elevated and advanced to close the donor site of the glabellar flap ([Figure 1F](#)). The flap was elevated on the periosteum, and the surroundings were undermined slightly wider for transfer without tension. The elevated flap was fixed by anchor sutures between the reverse side of the flap and the periosteum to prevent relapse after surgery. Burrow's triangles on the Rintala flap were resected at the superior border of the eyebrow.

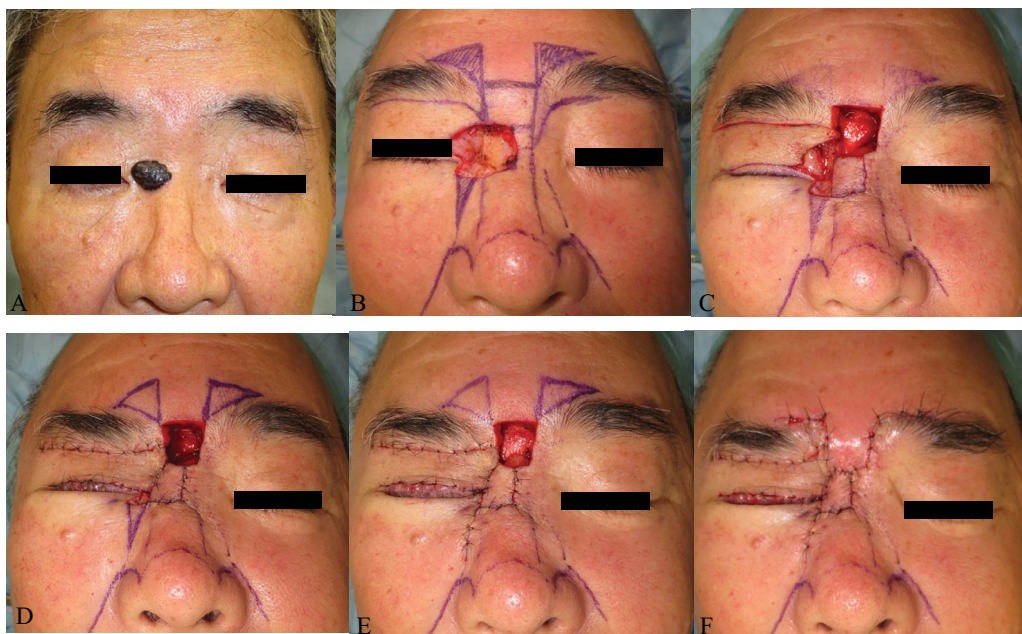


Figure 1. Operative procedure. A, A case of BCC. Preoperative view. B, Defect after resection of BCC. C, A glabellar flap is elevated and transferred to the medial canthal defect. D, An upper eyelid myocutaneous flap is advanced to cover the residual defect on the upper eyelid. E, A cheek flap is advanced to cover the residual defect on the lower eyelid. F, The donor site of the glabellar flap is closed with a Rintala flap. Postoperative view.

Results

In all cases, intraoperative histopathologic examination was performed, and it was possible to perform immediate reconstruction after confirming that there were no remnant tumour cells on the surgical margin. Complete resection of the tumour was also confirmed on the permanent pathological specimen. There were no cases in which the lacrimal duct and medial canthal ligament were excised, and in all cases the flaps survived without complication. The postoperative observation period was 1 year 6 months to 5 years. There were no recurrences, and good results were obtained (Figures 2 and 3). One case showed a mild linear contracture at the medial canthal region, but the patient did not want corrective surgery.

Discussion

The medial canthal is a region where multiple sites such as the upper eyelid, the lower eyelid, the eyebrows and the nose converge, and the colour, texture, and thickness of the skin are different for each site. The skin of the medial canthal region is slightly thicker than the skin of the upper and lower eyelids and thinner than the skin of the nose and the glabella. Furthermore, since the medial canthal region has a complicated structure including the medial canthal ligament and the lacrimal duct, and has a characteristic form showing a depression in the centre, some ingenuity is necessary to devise and perform cosmetic reconstruction. Various reconstruction methods such as forehead flaps and glabellar flaps have been reported,^{2,3} and these are selected mainly based on the size of the defect.

In 1993, Spinelli et al.¹ divided the periocular region into 5 zones, and recommended selection of a reconstruction method considering each regional feature. That is, in the medial canthal region, it is said that the local flap and upper eyelid myocutaneous flap are excellent, with upper eyelid myocutaneous

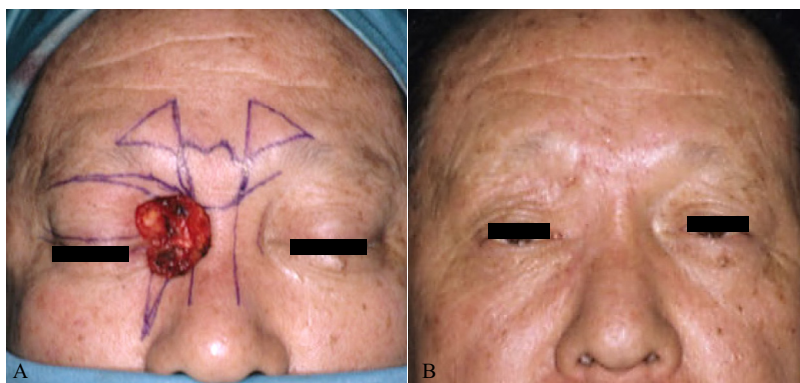


Figure 2. A 63-year-old male patient. A, Medial canthal defect and design of the flaps. B, Postoperative view after 5 years.

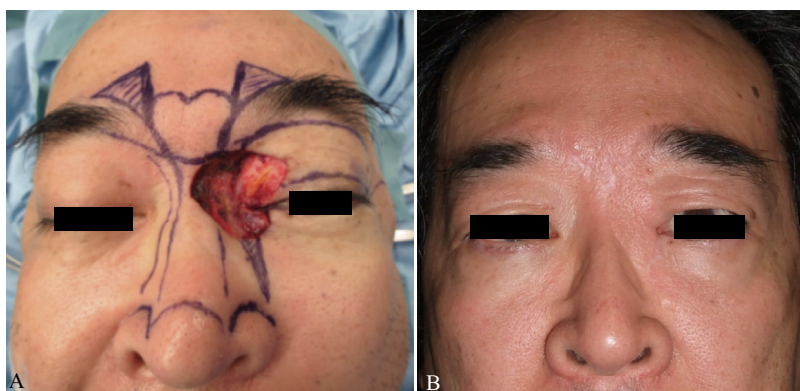


Figure 3. A 60-year-old male patient. A, Medial canthal defect and design of the flaps. B, Postoperative view after 18 months.

flap as the first choice. The upper eyelid myocutaneous flap is a useful method in that it is thin, excellent in texture and colour, has a stable blood supply, and offers inconspicuous scarring of the donor site.^{4,5} It is often transferred in the form of a V-Y advancement flap, but it is difficult to use it to cover large defects extending beyond the medial canthal region to the glabella and the external nose.

The forehead flap and glabellar flap are thick, and if transferred without thinning, trap-door phenomenon and pancake-like bulging may occur, so satisfactory results cannot be assured.⁶ Although the forehead flap is effective for reconstruction of large medial canthal defects, it has the following disadvantages: a two-stage operation is necessary, the flap is thick, requiring defatting later, and despite a good colour match to the eyelids, the texture does not match.⁷ The glabellar flap, on the other hand, is useful for reconstruction of a relatively small medial canthal defect.⁸

In 2007, Onishi et al.⁹ reported medial canthal reconstruction with a glabellar flap combined with a Rintala flap, as follows: A rectangular glabellar flap was designed in accordance with the unit principle. After thinning, the elevated glabellar flap was trimmed into the defect shape and transposed to the medial canthus defect. A Rintala flap was elevated and advanced to close the donor site of the glabellar flap. In addition, they described that even defects extending beyond the medial canthal to the lateral side of the upper and lower eyelids could be accommodated by transferring the tip of the glabellar flap when divided into two portions.

For large defects exceeding the medial canthal region, there are various strategies to reconstruct with combined multiple flaps or a single flap, but it is important to consider the continuity of colour and texture to achieve a natural external appearance of the medial canthal region. Chao et al.¹⁰ devised a combination of glabellar flap in which the tip was divided into two portions and an orbicularis oculi myocutaneous V-Y advancement flap for a large medial canthal defect extending to the upper and lower eyelids.

Lykoudis et al.¹¹ reported the combined use of glabellar flap and nasolabial flap for reconstruction of large medial canthal defects and referred to a “pickaxe” double flap technique because the shape was similar to that tool. This method is a combination of two standard flaps. It is simple, reliable, highly reproducible, and cosmetically highly satisfactory not only for medial canthal defects but also for composite defects extending to the nasal sidewall and upper and lower eyelids. Berry et al.¹² used three local flaps—tripier flap, a cheek flap, and a glabellar flap—whereas Ayhan et al.¹³ used a Cheek flap, an upper eyelid myocutaneous flap, and a lateral nasal wall flap for reconstruction of large medial canthal defects.

The technique reported in this study has a complicated design and a somewhat complicated procedure. However, the postoperative suture line is consistent with the aesthetic unit and is inconspicuous, so satisfactory cosmetic results can be expected. This method was thought to be a useful procedure because it can be applied to a large medial canthal complex defect extending from the nasal dorsum to the nasal sidewall and the upper and lower eyelids by a combination of standard multiple local flaps.

Conclusions

The reconstruction of medial canthal defects by combined multiple local flaps is described. Reconstruction by means of this procedure was performed in four cases, and good results were obtained. Although the procedure is somewhat complicated compared with reconstruction using a single flap, it is a simple combination of standard local flaps adjacent to the defect. This technique can be performed readily and applied to relatively large defects. It is also aesthetically useful because of its inconspicuous postoperative suture lines.

Disclosure

None of the authors has a financial interest in any of the products, devices, or drugs mentioned in this article.

Acknowledgment

Informed patient consent was obtained for the publication of the figures in this article.

References

- Spinelli HM, Jelks GW. Periocular reconstruction; a systemic approach. *Plast Reconstr Surg*. 1993;91:1017–1024.
- Harris GJ, Logani SC. Multiple aesthetic unit flaps for medial canthal reconstruction. *Ophthalmol Plast Reconstr Surg*. 1998;14:352–359.
- Mustard JC, Mustard JC, ed. *Surgery of the Medial Canthus. Repair and Reconstruction in the Orbital Region*. 3rd ed. Edinburgh: Churchill Livingstone; 1991:255–281.
- Jelks GW, Glat PM, Jelks EB, et al. Medial canthal reconstruction using a medially based upper eyelid myocutaneous flap. *Plast Reconstr Surg*. 2002;110:1636.
- d'Alcontres FS, D'Amico E, Colonna MR, et al. The orbicularis oculi myocutaneous flap in the repair of the medial canthal region. A new strategy for canthal resurfacing. *Br J Plast Surg*. 2004;57:540–542.
- Mutlu ÖÖ, Egemen O, Dilber A, et al. Aesthetic unit-based reconstruction of periorbital defects. *J Craniofac Surg*. 2016;27:429–432.
- Kim JH, Kim JM, Park JW, et al. Reconstruction of the medial canthus using an ipsilateral paramedian forehead flap. *Arch Plast Surg*. 2013;40:742–747.
- Cody AK, David JA, Oren F. Glabellar flaps in nasal reconstruction. *Facial Plast Surg Clin N Am*. 2011;19:113–122.
- Onishi K, Maruyama Y, Okada E, et al. Medial canthal reconstruction with glabellar combined rintala flaps. *Plast Reconstr Surg*. 2007;119:537–541.

10. Chao Y, Xin X, Jiangping C. Medial canthal reconstruction with combined glabellar and orbicularis oculi myocutaneous advancement flaps. *J Plast Reconstr Aesthet Surg*. 2010;63:1624–1628.
11. Lykoudis EG, Lykoudis GE, Alexiou GA. "Pickaxe" double flap: A useful "tool" for reconstruction of deep large medial canthal defects-5-year experience and brief literature review. *Aesth Plast Surg*. 2015;39:410–413.
12. Berry MG, Fernandes AE. Triple-flap medial canthal reconstruction. *Can J Plast Surg*. 2008;16:170–172.
13. Ayhan S, Ozmen S, Sarigüney Y, et al. Reconstruction of the medial canthal region with the "triple-flap" technique. *Ann Plast Surg*. 2001;47:354–355.