

CLINICAL RESEARCH

## Laparoscopic ventral rectopexy with sacrocolpopexy for coexisting pelvic organ prolapse and external rectal prolapse

Yoshiyuki Kiyasu, Akira Tsunoda, Tomoko Takahashi and Masayoshi Nomura

*From the Gastroenterological Surgery, Department of Kameda Medical Center, Chiba, Japan*

### Abstract:

**Objectives:** Pelvic organ prolapse (POP) POP is defined as the protrusion of pelvic organs from the vaginal canal. POP often coexists with internal rectal prolapse or external rectal prolapse (ERP). A series of patients with coexisting POP and ERP who underwent laparoscopic ventral rectopexy (LVR) combined with laparoscopic sacrocolpopexy (LSC) are reported here. **Methods:** Seven patients underwent LVR and LSC together. Fecal incontinence was assessed by the Fecal Incontinence Severity Index (FISI), constipation was assessed by the Constipation Scoring System (CSS), and urinary incontinence was assessed by the International Consultation on Incontinence Questionnaire-Short Form (ICIQ-SF). Anatomical disorders were assessed by Pelvic Organ Prolapse Quantification (POP-Q) and defecography. **Results:** The patients' median age was 81 (60-88) years. The median operative time was 380 (282-430) minutes. The median postoperative hospital stay was 3 (1-5) days. There were no postoperative complications. The FISI, CSS, POP-Q, and defecography findings improved postoperatively; however, the ICIQ-SF deteriorated in 2 of 5 patients. **Conclusions:** LVR combined with LSC for coexisting POP and ERP is feasible.

### Keywords:

pelvic organ prolapse (POP), external rectal prolapse (ERP), laparoscopic ventral rectopexy (LVR), laparoscopic sacrocolpopexy (LSC), fecal incontinence severity index (FISI), constipation scoring system (CSS)

J Anus Rectum Colon 2017; 1(4): 141-146

### Introduction

Pelvic organ prolapse (POP) is a common disease among elderly women. In gynecology or urology, POP is defined as the uterus, bladder, small or large intestine, and/or rectum protruding from the vagina. In addition, POP may be associated with urinary and defecation disorders, such as urinary incontinence, fecal incontinence, and constipation<sup>1</sup>.

In surgical treatment for cystocele and/or hysterocele, the mesh has been widely used because of its lower recurrence rate. Since the Food and Drug Administration pronouncements in 2011<sup>2</sup>, the abdominal approach has been preferred over the vaginal approach because of fewer mesh-related complications, and laparoscopic sacrocolpopexy (LSC) has been performed because of its minimal invasiveness and satisfactory results<sup>3-5</sup>. Meanwhile, a technical point on LSC has been questioned, that is, whether a posterior mesh is to be

uniformly placed in addition to an anterior vesico-vaginal mesh<sup>6</sup>.

As with LSC, the recent widespread use of laparoscopic surgery has made laparoscopic rectopexy the standard for the treatment for ERP<sup>7</sup>. In 2004, D'Hoore et al. reported a type of pelvic autonomic nerve-preservation surgery, laparoscopic ventral rectopexy (LVR). This method fixes the anterior wall of the lower rectum to the sacral promontory with a mesh, which results in a lower postoperative constipation rate when compared with that resulting from posterior rectopexy<sup>8</sup>, and its good outcome for rectal intussusception has also been reported<sup>9,10</sup>.

When ERP is associated with cystocele and/or hysterocele, they should be repaired simultaneously. Even though simultaneous open abdominal repair or the combination of laparoscopic and perineal approaches to the coexisting POP and ERP has been reported to have been employed<sup>11-13</sup>, si-

Corresponding author: Yoshiyuki Kiyasu, kiyasu.yoshiyuki@kameda.jp

Received: December 21, 2016, Accepted: June 29, 2017

Copyright © 2017 The Japan Society of Coloproctology

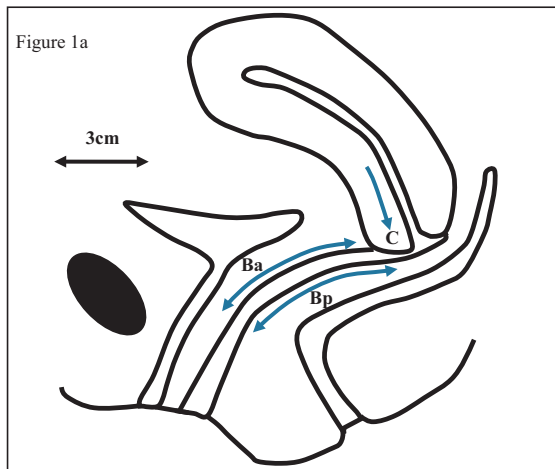


Figure 1b: Ba score

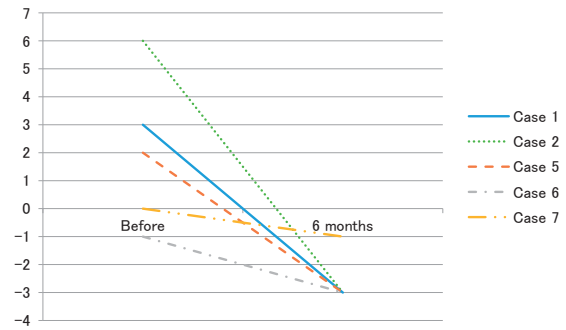


Figure 1c: C score

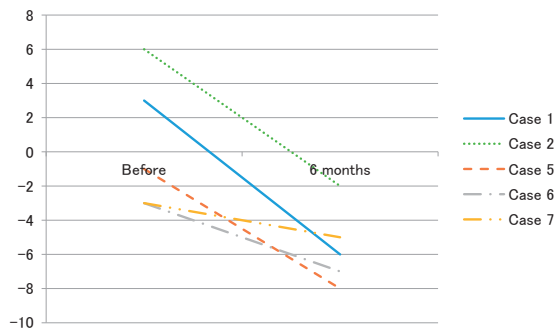
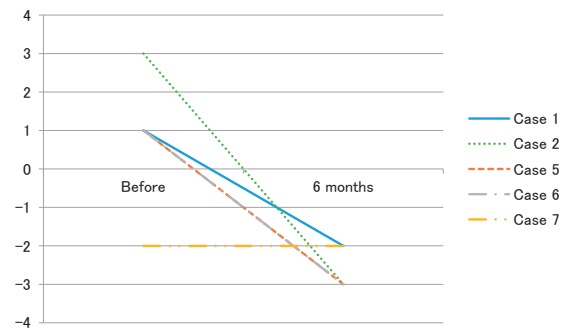


Figure 1d: Bp score



**Figure 1.** a. The schema of the POP-Q score (figure modified from that of a previous study (13)). Positions are expressed as centimeters above the hymen (negative number) or centimeters below the hymen (positive number) with the plane of the hymen being defined as zero.

b-d. POP-Q scores before and 6 months after LVR.

LVR, laparoscopic ventral rectopexy; POP-Q, pelvic organ prolapse quantification; “Ba,” “C,” and “Bp” show the degrees of cystocele, hysterocele, and rectocele, respectively

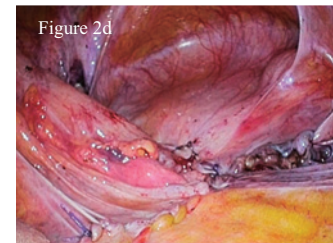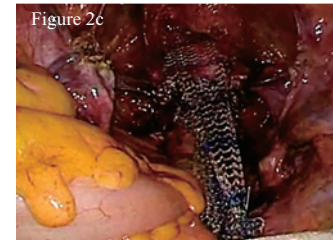
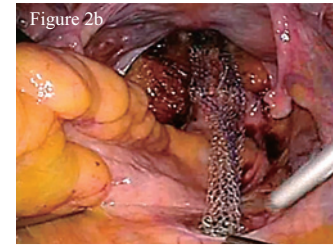
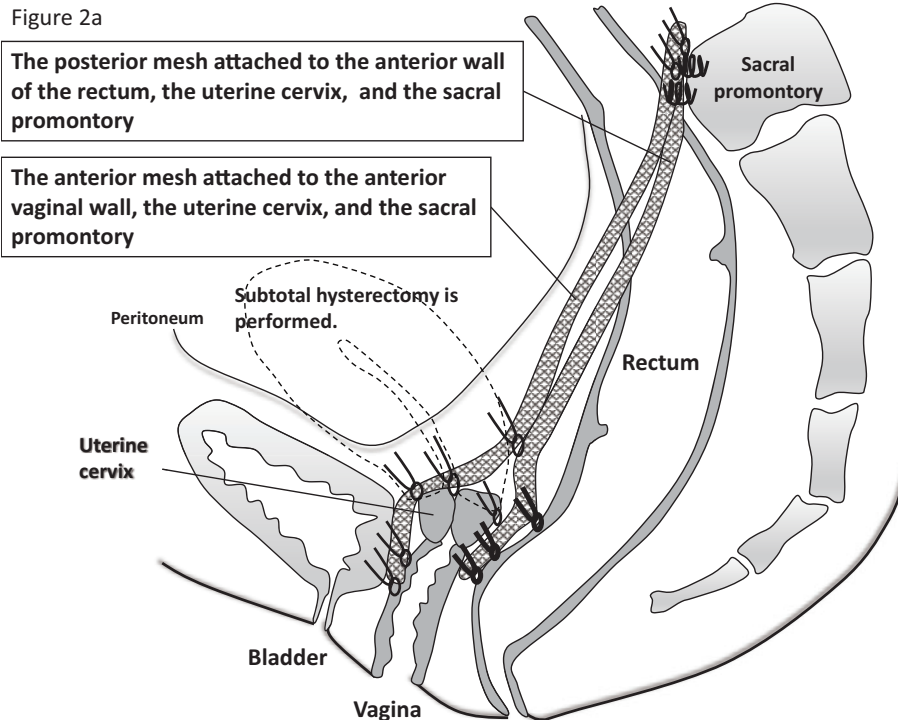
multaneous complete laparoscopic repair has not yet been reported. We have performed LVR and LSC together for the coexisting POP and ERP, and our outcomes are reported.

### Methods

Between February 2013 and August 2015, seven patients underwent simultaneous LVR and LSC for coexisting POP and ERP or recto-anal intussusceptions. Whether the patients had a hysterocele and/or cystocele was determined by physical examination, using Pelvic Organ Prolapse Quantification (POP-Q)<sup>14</sup>, before surgery and six months after surgery. This scheme defines “Ba (a point that represents the most distal position of any part of the upper anterior vaginal wall from the vaginal cuff or anterior vaginal fornix to a point of anterior vaginal wall 3 cm proximal to the external urethral meatus),” “C (a point that represents either the most distal edge of the cervix or the vaginal cuff),” and “Bp (a point that represents the most distal position of the upper posterior vaginal wall from the vaginal cuff or posterior vaginal fornix to a point of posterior vaginal wall 3 cm proximal to the hymen)” as showing the degrees of cystocele, hysterocele, and rectocele, respectively (Figure 1a). Urinary incontinence

was assessed by the International Consultation on Incontinence Questionnaire-Short Form (ICIQ-SF)<sup>15</sup>. ERP, rectocele, recto-anal intussusception, and enterocele were diagnosed by defecography before surgery and six months after surgery. A rectocele greater than 2 cm in diameter was regarded as abnormal. Recto-anal intussusception was diagnosed when the apex of the rectal intussusception impinged on the internal anal orifice or was in the anal canal, on the basis of the images taken during maximal straining defecation. Rectal prolapse can be classified with the Oxford Rectal Prolapse grade<sup>16</sup>. Using this grading system, recto-anal intussusception is graded at III/IV, and ERP is graded at V. Our definition of ERP was complete ERP, and incomplete ERP was excluded. Enterocele was diagnosed when the extension of the loop of the small and/or large bowel was located between the vagina and the rectum, below the ischio-coccygeal line<sup>17</sup>.

Fecal incontinence was assessed by the Fecal Incontinence Severity Index (FISI)<sup>18</sup>, and constipation was assessed by the Constipation Scoring System (CSS)<sup>19</sup> before surgery and three or six months after surgery. The data are presented as median values (range).



**Figure 2.** a. Our schema for laparoscopic ventral rectopexy with sacrocolpopexy.  
 b. A strip of polypropylene mesh was sutured as distally as possible on the rectal wall with six interrupted 2-0 non-absorbable sutures and was settled on the sacral promontory with a stapler.  
 c. Hysterectomy was performed and another mesh was sutured to the anterior aspect of the vagina. The two strips of mesh were sutured to each other and fixed without traction on the sacral promontory.  
 d. The mesh was peritonealized by suturing the uterosacral ligament and the free edge of the divided peritoneum.

### Operating procedure

First, LVR was performed (Figure 2a). The surgical technique was previously described by the D'Hoore group<sup>8)</sup>, with some modifications. A peritoneal incision was made from just above the sacral promontory while preserving the right hypogastric nerve. This incision was extended along the right side of the rectum and over the bottom of the pouch of Douglas in an inverted J-shape. Denonvillier's fascia was incised, and the rectovaginal septum was broadly opened. Its distal extent, usually 3 cm-4 cm from the anal verge, was confirmed by digital rectal examination. A strip of polypropylene mesh (PROLEN<sup>TM</sup> Soft Polypropylene Mesh by Ethicon, Inc.), trimmed to 3.0 cm × 18.0 cm, was introduced. If a patient had rectocele, the width of the mesh was widened to 5 cm in a 5-cm length of the distal end. Then, unlike LSC involving double mesh fixing, this posterior mesh was sutured as distally as possible on the rectal muscular wall with six interrupted 2-0 non-absorbable sutures. The mesh was settled tension-free on the sacral promontory with a stapler (ProTack<sup>TM</sup> Tyco Autosuture 5 mm stapler, Covidien Japan Inc., Tokyo, Japan) (Figure 2b), (Video S1).

Second, LSC was performed (Figure 2a) by gynecologists. The surgical technique was previously reported<sup>9)</sup>. The bilateral round ligaments, ovarian ligaments, and ascending

branches of the uterine arteries were coagulated and dissected. Subtotal hysterectomy was subsequently performed. The cut end was closed by 2-0 absorbable sutures. When a patient had rectocele, the posterior mesh was sutured to the bilateral puborectalis muscles with 2-0 non-absorbable sutures. Then, the bladder and the vagina were dissected until the posterior side of the urinary catheter in the bladder was identified. Following this dissection, the second mesh, trimmed to 3.0 cm × 20.0 cm, was inserted. It was fixed on the anterior vaginal wall with three 2-0 non-absorbable sutures. In addition, the mesh and the uterine cervix were secured. The first and the second mesh were sutured with 2-0 non-absorbable sutures on the cut end of the uterus. The second mesh was also fixed to the sacral promontory (Figure 2c). Finally, the mesh was peritonealized by suturing the uterosacral ligament and the free edge of the divided peritoneum to avoid small bowel adhesion to the mesh (Figure 2d) (Video S2).

### Results

The median age of the seven patients was 81 (60-88) years. While there were 2 missing values, the median number of deliveries was 3 (2-3); no patient had undergone previous pelvic surgery. Four of the seven patients had more than three kinds of POP (Table 1). In case 3, who had ERP

**Table 1.** Patient Characteristics.

	Age	Number of deliveries	Hysterocele	Cystocele	Rectocele	External rectal prolapse	Rectal intussusception	Enterocoele	ASA
Case 1	60	2		○		○			2
Case 2	87	unknown		○		○			2
Case 3	88	unknown		○		○		○	2
Case 4	81	3	○			○			2
Case 5	72	3		○	○		○	○	2
Case 6	60	3	○	○		○			1
Case 7	83	2	○	○	○	○			2

**Table 2.** Surgical Outcome.

	Operation	Blood loss (mL)	Operation time (min)	Postoperative stay (day)
Case 1	LVR, LSC, Delorme procedure	50	430	2
Case 2	LVR, LSC	20	301	5
Case 3	LVR, LSC	200	380	3
Case 4	LVR, LSC	20	327	1
Case 5	LVR, LSC, Hemorrhoidectomy	200	380	2
Case 6	LVR, LSC	20	282	4
Case 7	LVR, LSC, Umbilical hernia repair	15	426	4

Figure 3a: CSS score

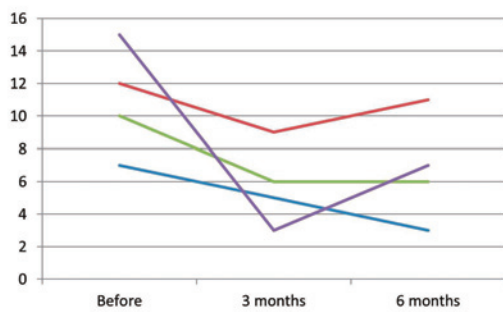


Figure 3b: FISl score

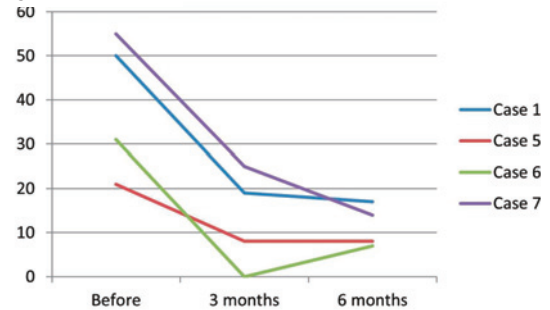
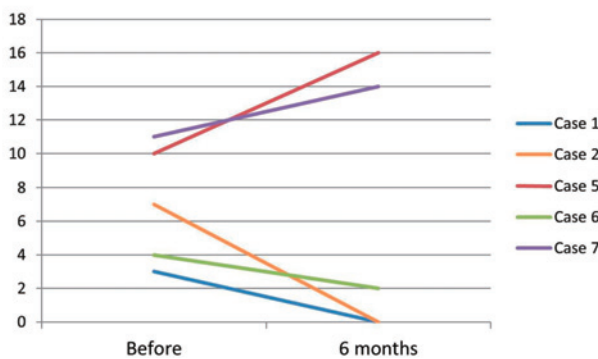


Figure 3c: ICIQ-SF score



**Figure 3.** a. FISl scores before and 6 months after LVR.

LVR, laparoscopic ventral rectopexy; FISl, fecal incontinence severity index

b. CSS scores before and 6 months after LVR.

LVR, laparoscopic ventral rectopexy; CSS, constipation scoring system

c. ICIQ-SF scores before and 6 months after LVR.

LVR, laparoscopic ventral rectopexy; ICIQ-SF, The International Consultation on Incontinence Questionnaire-Short Form

and enterocele, preoperative defecography showed that the small bowel protruded together with the rectum from the anus. In case 5, who had recto-anal intussusception associ-

ated with rectocele and enterocele, the small bowel was located between the vagina and the rectum, below the ischio-coccygeal line, thus being consistent with the definition.



The surgical outcome is shown in Table 2. The median duration of the operation was 380 (282-430) minutes, and the median blood loss was 20 (15-200) ml. There were no intraoperative or postoperative complications. The postoperative hospital stay was 3 (1-5) days. In one case, after the operation, the patient's rectal prolapse was treated; however, a mild mucosal prolapse that was remaining was revealed. Therefore, we added the Delorme procedure. To summarize, one patient underwent hemorrhoidectomy, another underwent umbilical hernia repair, and another underwent the Delorme procedure.

The FIS1 and CSS scores before and after surgery are shown in Figures 3a and 3b. The scores were not assessed in three patients with cognitive disorders. The scores of the remaining four patients improved postoperatively. The changes in the Ba, C, and Bp scores are shown in Figures 1b-1d. The scores were not assessed in two patients due to their noncooperation. The scores of three points in the other five cases improved within 6 months after surgery when compared with those before surgery. The ICIQ-SF scores are shown in Figure 3c. Three cases improved; however, two cases deteriorated postoperatively. The scores were not assessed in two patients with cognitive disorders. Postoperative defecography showed no recurrence in the six patients with ERP or in the one patient with recto-anal intussusception. During the median follow-up of 13 (3-33) months, there was no recurrence of POP and no mesh-related complications.

## Discussion

When compared with open surgery, the duration of a laparoscopic procedure is likely to be longer, therefore respiratory complications are a concern for elderly people. The present patients had no postoperative complications and were discharged in a few days.

This study showed that not only anatomical abnormalities of pelvic organs but also functional defecation disorders improved after surgery. However, urinary incontinence did not improve in all seven patients postoperatively. Previous studies reported that some patients who did not have urinary incontinence before surgery could have de novo stress incontinence after POP surgery<sup>20</sup>, and the percentage of de novo urinary incontinence after LSC was reported to be about 6%<sup>21</sup>. In the present series, the two patients who had de novo incontinence did not have specific findings on the preoperative POP-Q score and maximum flow rate. Patients who had positive urodynamic tests, with a reduction in the prolapse, and with a properly fitted vaginal ring pessary were considered to be at high risk of developing postoperative de novo stress urinary incontinence<sup>20</sup>. Thus, informed consent and discussing the necessity of additional surgeries for de novo urinary incontinence is necessary before these combined surgeries.

In conclusion, this study suggests that LVR combined with LSC is feasible for patients with coexisting POP and

ERP.

### Conflicts of interest

There are no conflicts of interest.

### Ethical statement

All patients gave their informed consent prior to their inclusion in this study.

### References

1. Jackson SL, Weber AM, Hull TL, et al. Fecal incontinence in women with urinary incontinence and pelvic organ prolapse. *Obstet Gynecol.* 1997 Mar; 89(3): 423-7.
2. van Geelen JM, Dwyer PL. Where to for pelvic organ prolapse treatment after the FDA pronouncements? A systematic review of the recent literature. *Int Urogynecol J.* 2013 May; 24(5): 707-18.
3. Wattiez A, Boughizane S, Alexandre F, et al. Laparoscopic procedures for stress incontinence and prolapse. *Curr Opin Obstet Gynecol.* 1995 Aug; 7(4): 317-21.
4. Ganatra AM, Rozet F, Sanchez-Salas R, et al. The current status of laparoscopic sacrocolpopexy: a review. *Eur Urol.* 2009 May; 55(5): 1089-103.
5. Lee RK, Mottrie A, Payne CK, et al. A review of the current status of laparoscopic and robot-assisted sacrocolpopexy for pelvic organ prolapse. *Eur Urol.* 2014 Jun; 65(6): 1128-37.
6. Antiphon P, Elard S, Benyoussef A, et al. Laparoscopic promontory sacral colpopexy: is the posterior, recto-vaginal, mesh mandatory? *Eur Urol.* 2004 May; 45(5): 655-61.
7. Tou S, Brown SR, Nelson RL, et al. Surgery for complete (full-thickness) rectal prolapse in adults. *Cochrane Database Syst Rev.* 2015 Nov; 11: CD001758. doi: 10.1002/14651858.CD001758.pub 3.
8. D'Hoore A, Cadoni R, Penninckx F, et al. Long-term outcome of laparoscopic ventral rectopexy for total rectal prolapse. *Br J Surg.* 2004 Nov; 91(11): 1500-5.
9. Portier G, Kirzin S, Cabarrot P, et al. The effect of abdominal ventral rectopexy on faecal incontinence and constipation in patients with internal intra-anal rectal intussusception. *Colorectal Dis.* 2011 Aug; 13(8): 914-7.
10. Sileri P, Franceschilli L, de Luca E, et al. Laparoscopic ventral rectopexy for internal rectal prolapse using biological mesh: postoperative and short-term functional results. *J Gastrointest Surg.* 2012 Mar; 16(3): 622-8.
11. Lim M, Sagar PM, Gonsalves S, et al. Surgical management of pelvic organ prolapse in females: functional outcome of mesh sacrocolpopexy and rectopexy as a combined procedure. *Dis Colon Rectum.* 2007 Sep; 50(9): 1412-21.
12. Watadani Y, Vogler SA, Warshaw JS, et al. Sacrocolpopexy with rectopexy for pelvic floor prolapse improves bowel function and quality of life. *Dis Colon Rectum.* 2013 Dec; 56(12): 1415-22.
13. Sagar PM, Thekkinkattil DK, Heath RM, et al. Feasibility and functional outcome of laparoscopic sacrocolpoporectomy for combined vaginal and rectal prolapse. *Dis Colon Rectum.* 2008; 51(9): 1414-20.
14. Bump RC, Mattiasson A, Bø K, et al. The standardization of terminology of female pelvic organ prolapse and pelvic floor dysfunction. *Am J Obstet Gynecol.* 1996 Jul; 175(1): 10-7
15. Karantanis E, Fynes M, Moore KH, et al. Comparison of the ICIQ-SF and 24-hour pad test with other measures for evaluating the severity of urodynamic stress incontinence. *Int Urogynecol J Pelvic Floor Dysfunct.* 2004 Apr; 15(2): 111-6

16. Wijffels NA, Jones OM, Cunningham C, et al. What are the symptoms of internal rectal prolapse? *Colorectal Dis.* 2013; 15(3): 368-73.
17. Mahieu P, Pringot J, Bodart P. Defecography: II. Contribution to the diagnosis of defecation disorders. *Gastrointest Radiol.* 1984 Dec; 9(1): 253-61.
18. Rockwood TH, Church JM, Fleshman JW, et al. Patient and surgeon ranking of the severity of symptoms associated with fecal incontinence: the fecal incontinence severity index. *Dis Colon Rectum.* 1999 Dec; 42(12): 1525-32.
19. Agachan F, Chen T, Pfeifer J, et al. A constipation scoring system to simplify evaluation and management of constipated patients. *Dis Colon Rectum.* 1996 Jun; 39(6): 681-5.
20. Liang CC, Chang YL, Chang SD, et al. Pessary test to predict postoperative urinary incontinence in women undergoing hysterectomy for prolapse. *Obstet Gynecol.* 2004 Oct; 104(4): 795-800.
21. Rozet F, Mandron E, Arroyo C, et al. Laparoscopic sacral colpopexy approach for genito-urinary prolapse: experience with 363 cases. *Eur Urol.* 2005 Feb; 47(2): 230-6.

Journal of the Anus, Rectum and Colon is an Open Access article distributed under the Creative Commons Attribution-NonCommercial-NoDerivatives 4.0 International License. To view the details of this license, please visit (<https://creativecommons.org/licenses/by-nc-nd/4.0/>).