

# An intraneural ganglion cyst of the ulnar nerve at the wrist: a case report and literature review

Journal of International Medical Research

49(1) 1–7

© The Author(s) 2021

Article reuse guidelines:

[sagepub.com/journals-permissions](https://sagepub.com/journals-permissions)

DOI: 10.1177/0300060520982701

[journals.sagepub.com/home/imr](https://journals.sagepub.com/home/imr)



Gu Heng Wang<sup>1,2</sup> , Tian Mao<sup>1</sup>, Ya Lan Chen<sup>3</sup>,  
Cheng Xu<sup>4</sup>, Shu Guo Xing<sup>1</sup>, Xue Jun Ni<sup>4</sup> and  
Ai Dong Deng<sup>1</sup>

## Abstract

**Background:** Intraneural ganglion cysts of the ulnar nerve at the wrist are rare and poorly understood. We report a case of an intraneural ganglion cyst at the level of the wrist.

**Case presentation:** A 48-year-old man presented with the complaints of weakness for 6 months and serious aggravation for 1 month in his right hand. After examinations, including ultrasound, the patient was diagnosed with an intraneural ganglion cyst. Intraoperatively, with exposure of the ulnar nerve, we found that the intraneural ganglion cyst was at the level of Guyon's canal and extended approximately 6 cm proximally. Postoperatively, sensation of the fingers was normal, but atrophy of his muscles and limited straightening of his ring and little fingers were similar to those preoperatively.

**Conclusions:** Diagnosis of an intraneural cyst before surgery is mostly based on ultrasound and magnetic resonance imaging. Transection of the articular branch is an important measure to prevent recurrence of this cyst. If the ulnar nerve is compressed and causes symptoms, nerve decompression, including removal/aspiration of the cyst, and sometimes external neurolysis of the nerve, are necessary to relieve the symptoms and allow regeneration of the nerve. However, these should be performed without damaging the nerve fascicles.

<sup>1</sup>Department of Hand Surgery, Affiliated Hospital of Nantong University, Nantong, P.R. China

<sup>2</sup>Department of Orthopedics, The Second Affiliated Hospital of Soochow University, Suzhou, P.R. China

<sup>3</sup>Department of Medical Informatics, School of Medicine, Nantong University, Nantong, P.R. China

<sup>4</sup>Department of Medical Ultrasound, Affiliated Hospital of Nantong University, Nantong, P.R. China

## Corresponding author:

Gu Heng Wang, Department of Hand Surgery, Affiliated Hospital of Nantong University, #20 Xisi Road, Nantong 226001, P.R. China; Department of Orthopedics, The Second Affiliated Hospital of Soochow University, #1055 Sanxiang Road, Suzhou 215000, P.R. China.  
Email: [guhengwang@yahoo.com](mailto:guhengwang@yahoo.com)



## Keywords

Intraneural cyst, ulnar nerve, wrist, ganglion, ultrasound, articular branch

Date received: 15 July 2020; accepted: 30 November 2020

**Type of study/level of evidence:** Therapeutic IV.

## Introduction

Intraneural ganglion cysts are uncommon mucinous cysts, which occur within the epineurium of nerves. These cysts are usually found in the peroneal nerve and the second most common location is the ulnar nerve.<sup>1,2</sup> There are fewer cases of ulnar nerve cysts occurring at the wrist (5.3%) compared with the elbow (9.0%).<sup>3,4</sup> If cysts penetrate along the ulnar nerve to Guyon's canal, this can cause the syndrome of ulnar compression. Chen et al.<sup>5</sup> reported a case of an intraneural ganglion cyst that originated from the pisotriquetral joint and caused symptoms of ulnar compression. Naam et al.<sup>1</sup> reported a case of an intraneural ganglion of the ulnar nerve at the wrist and the patient presented with a mass and symptoms of compression. We report a case of intraneural ganglion cyst of the ulnar nerve at the level of the wrist that extended proximally. The cyst was interesting because it had grown along the main trunk of the ulnar nerve for approximately 6 cm proximally. We also review the literature of intraneural ganglion cysts of the ulnar nerve at the wrist to analyze their characteristics and main points of management.

## Case presentation

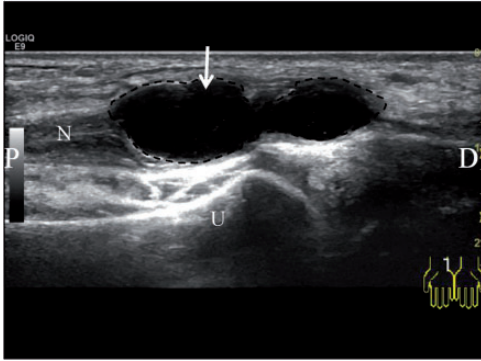
A 48-year-old man presented to our clinic with complaints of weakness for 6 months

and serious aggravation for 1 month in his dominant right hand. The patient presented with decreased sensation along the volar aspects of the ulnar nerve of the ring and little fingers. The patient's ring and little fingers could not straighten out completely. The duration of interosseous muscle atrophy of the hand was 2 months. His previous medical history was healthy and he had no pre-existing medical conditions.

On examination, the medial palm and ulnar aspect of the ring finger and the entire anterior side of the little finger had decreased sensation. The power of finger abduction and adduction was minimal. The dorsal interosseous muscles of his right hand were obviously atrophied. Tinel's sign over Guyon's canal was positive.

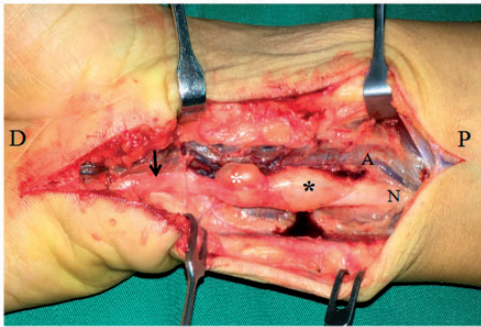
An electromyographic and nerve conduction examination showed ulnar neuropathy at the level of the wrist. An ultrasound examination of the wrist demonstrated a cyst within the ulnar nerve (Figure 1).

Under brachial plexus anesthesia and a pneumatic tourniquet, the ulnar nerve was exposed with an ulnar wrist incision. Intraoperatively, the ulnar nerve in Guyon's canal was compressed and decompression was cautiously performed. After decompression, the proximal part of the ulnar nerve with the intraneural ganglion cyst was exposed (Figure 2). The origin of the cyst was unclear. The cyst extended approximately 6 cm proximally and was 0.8 cm at its widest point. Therefore, the incision extended to the forearm during



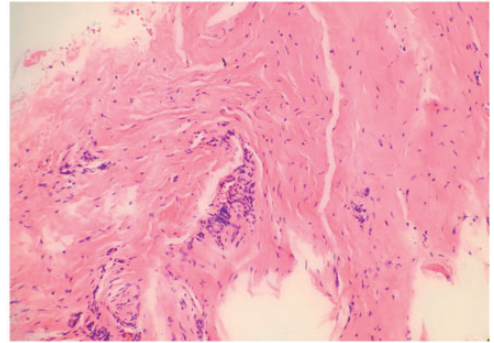
**Figure 1.** Ultrasound images of the intraneural ganglion of the ulnar nerve at the wrist. The arrow shows an intraneural ganglion cyst (one cyst with two dilatations).

N, ulnar nerve; U, ulna; D, distal; P, proximal.



**Figure 2.** Photograph of a zigzag incision in the wrist. An intraneural ganglion cyst of the main trunk of the ulnar nerve at the wrist was exposed during surgery. The arrow shows the location where the nerve was compressed. The white asterisk shows that the cyst is partly dissected. The black asterisk shows that the cyst is not dissected. A, ulnar artery and accompanying vein; N, ulnar nerve; D, distal; P, proximal.

the operation. The cyst was separated from the ulnar nerve fascicles under  $3.5\times$  loupe magnification. At the proximal end, the cyst complex included nerve fascicles and it could not be separated from the nerve fascicles completely. Finally, the ulnar nerve was completely decompressed and the wall



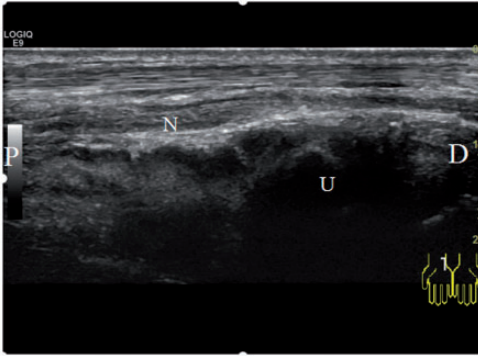
**Figure 3.** Pathology confirming diagnosis of the cyst (hematoxylin and eosin stain,  $\times 200$ ).

of the cyst was cautiously excised, except for part of it at the proximal end. Pathology confirmed the diagnosis of the cyst (Figure 3).

At the time of follow-up of 17 months, the patient had returned to work and the sensation of his fingers was the same as that in the contralateral side (5 mm in the ring and little fingers with static 2-point discrimination, and 0.4 g in the ring and little fingers by the Semmes–Weinstein test). However, the atrophied muscles and limited straightening of the ring and small fingers were similar to those preoperatively. The total active motion of his little and ring fingers was  $248^\circ$  and  $255^\circ$ , respectively. The total active motion outcome uses the sum of the metacarpophalangeal joint, proximal interphalangeal joint, and distal interphalangeal joint flexion minus the extensor lag at these joints. Tinel's sign over Guyon's canal was negative. An ultrasound examination showed no recurrence of the ganglion (Figure 4).

## Discussion

There are three major theories to explain formation of intraneural ganglion cysts, including the degenerative theory, tumoral theory, and synovial (articular) theory.



**Figure 4.** Ultrasound image shows no recurrence of the ganglion.

N, ulnar nerve; U, ulna; D, distal; P, proximal.

In 1884, F. Swinford Edwards first described an intraneural ganglion cyst that affected the deep branch of the ulnar nerve and arose from a carpal joint.<sup>6</sup> In 2003, Zielinski<sup>7</sup> reported that intraneural ganglion cysts originated from the carpus and grew into the muscular branch and then traveled into the ulnar nerve through bifurcation. Spinner et al.<sup>8</sup> believed that intraneuronal ganglion cysts form from extension of synovial fluid along the articular branch and then dissect along the epineurium of the nerve to reach the main nerve or another branch. Details of intraneural ganglion cysts of the ulnar nerve at the level of the wrist in the English literature in last two decades are shown in Table 1.<sup>1,5,7,9-15</sup> These studies suggest that the synovial (articular) theory is the most logical and applicable explanation. Some authors<sup>7,9,10,15</sup> did not find an articular branch, which connected with the adjacent joint. According to Spinner et al.<sup>6</sup> in 2011, only 23% cases had joint connections identified for intraneural ganglion cysts at the wrist. Another study showed that the number of joint connections in the ulnar nerve at wrist was 10 of 35 (28.6%) patients.<sup>14</sup> In our case, we released the ulnar nerve without an obvious articular

branch and this did not support the synovial (articular) theory. A small articular branch might have been resected unknowingly or did not exist in this case. Regardless, surgeons need to pay attention to searching for the articular branch during surgery, which is important for preventing recurrence of cysts.<sup>5,8</sup>

According to the synovial (articular) theory, many authors recommend dissection of the articular branch of the nerve because they believe that it is the origin of the cyst.<sup>1,16-18</sup> In our case, we released and decompressed the ulnar nerve completely and ensured that there were no branches connected with the joint. Dissection and excision of the cyst from the nerve is difficult and requires magnification, even though it has the potential to injure the nerve fascicles. Removal of the cyst is not necessary when there are no symptoms of nerve compression. If the nerve is compressed by the cyst, surgeons can consider draining or incompletely resecting the wall to decompress the nerve. In our case, we carefully separated the cyst and left a small part of the wall, which formed a complex with nerve fascicles. We support the opinion that the cyst does not need to be completely removed, but the articular branch must be resected.<sup>19,20</sup>

As previously reported,<sup>1,7</sup> intraneural ganglion cysts are usually diagnosed at the time of surgery. Therefore, an imaging examination, including magnetic resonance imaging or ultrasound, is recommended for better preoperative planning. In the current case, we made the diagnosis by ultrasound preoperatively. An ultrasound examination is useful for not only intraneural ganglion cysts, but also for extraneural cysts. Ultrasound examination can improve the accuracy of diagnosis, but the examiner needs to have received relevant training. In our hospital, ultrasound is used as a routine examination for identifying the area for compression and guiding surgery. Magnetic

**Table 1.** Reported cases of intraneural ulnar cysts in the wrist within the last 2 decades in the English literature.

Reference	Year	Number of cases	Age (years)/sex	Side	Location	Management of the cysts	Joint connections	Joint involved
Kitamura et al. <sup>9</sup>	2000	1	44/F	R	Main trunk	Excision	N	–
Chick et al. <sup>10</sup>	2001	1	No description	No description	Main trunk	Incision and drainage	N	–
Zielinski <sup>7</sup>	2003	1	54/M	R	Main trunk and deep branch	Excision	N	–
Chalidis et al. <sup>11</sup>	2009	1	52/F	L	Main trunk	Excision	Y	Pisiform-triquetral joint
Colbert et al. <sup>12</sup>	2011	1	69/M	R	Deep branch	Excision	Y	Triquetral-hamate joint <sup>b</sup>
Chen et al. <sup>5</sup>	2011	1	43/M	R	Main trunk and branch	Excision	Y	Pisiform-triquetral joint
Okada et al. <sup>13</sup>	2011	1	51/M	R	Main trunk	Excision	Y	Distal radioulnar joint
Spinner et al. <sup>14</sup>	2012	1	50/M	L	Deep branch	Resected the articular branch	Y	Triquetral-hamate joint
Naam et al. <sup>1a</sup>	2015	3	–	–	Main trunk	No description	One case had connection	No description
		2	–	–	Deep branch	No description	One case had connection	No description
		2	–	–	Dorsal cutaneous branch	No description	One case had connection	No description
Öztürk et al. <sup>15</sup>	2017	1	25/F	R	Superficial branch	Excision	N	–

<sup>a</sup>Seven cases of intraneural ganglion cysts of the ulnar nerve at the hand and wrist were described by Naam et al.<sup>1</sup> and three of them (1, main trunk; 1, deep branch; 1, dorsal cutaneous branch) were reported to have joint connections. In the three cases of joint connection, two connected to the pisotriquetral joint and one connected to the distal radioulnar joint. However, which intraneural cyst connected to which joint was not specified. <sup>b</sup>The original magnetic resonance imaging scans were reviewed and the joint connection was found.<sup>14</sup>

No description: no detailed description was provided in the article.

F, female; M, male; R, right; L, left; N, no; Y, yes.



resonance imaging has special value in diagnosing intraneural ganglion cysts and a three-dimensional fast spin-echo sequence is recommended, especially for identifying the articular branch.<sup>21</sup>

## Conclusion

There are multiple factors that can affect the outcome of intraneural ganglion cysts. Diagnosis and treatment of intraneural ganglion cysts before the nerve is damaged are preferable. Diagnosis of intraneural ganglion cysts is mostly based on ultrasound and magnetic resonance imaging. Transection of the articular branch is an important measure to prevent recurrence of these cysts. If the ulnar nerve is compressed and causes symptoms, nerve decompression, including removal/aspiration of cysts, and sometimes external neurolysis of the nerve are necessary to relieve the symptoms and allow regeneration of the nerve. However, this should be performed without damaging the nerve fascicles.

## Ethics statement

Consent for publication was obtained from the patient. This study was approved by the ethics review committee of the Affiliated Hospital of Nantong University (2018-k019).

## Declaration of conflicting interest

The authors declare that there is no conflict of interest.

## Funding

The authors disclosed receipt of the following financial support for the research, authorship, and/or publication of this article: This work was supported by the Key Research and Development Projects of Jiangsu Province (No. BE 2017681).

## ORCID iD

Gu Heng Wang  <https://orcid.org/0000-0003-3084-4303>

## References

1. Naam NH, Carr SB and Massoud AH. Intraneural Ganglions of the Hand and Wrist. *J Hand Surg Am* 2015; 40: 1625–1630.
2. Sharma RR, Pawar SJ, Delmendo A, et al. Symptomatic epineural ganglion cyst of the ulnar nerve in the cubital tunnel: a case report and brief review of the literature. *J Clin Neurosci* 2000; 7: 542–543.
3. Ming Chan K, Thompson S, Amirjani N, et al. Compression of the ulnar nerve at the elbow by an intraneural ganglion. *J Clin Neurosci* 2003; 10: 245–248.
4. Desy NM, Wang H, Elshiekh MA, et al. Intraneural ganglion cysts: a systematic review and reinterpretation of the world's literature. *J Neurosurg* 2016; 125: 615–630.
5. Chen WA, Barnwell JC, Li Y, et al. An ulnar intraneural ganglion arising from the pisotriquetral joint: case report. *J Hand Surg Am* 2011; 36: 65–67.
6. Spinner RJ and Wang H. The first described joint-associated intraneural ganglion cyst. *Neurosurgery* 2011; 69: 1291–1298.
7. Zielinski CJ. Intraneural ganglion of the ulnar nerve at the wrist. *Orthopedics* 2003; 26: 429–430.
8. Spinner RJ, Amrami KK, Wolanskyj AP, et al. Dynamic phases of peroneal and tibial intraneural ganglia formation: a new dimension added to the unifying articular theory. *J Neurosurg* 2007; 107: 296–307.
9. Kitamura T, Oda Y, Matsuda S, et al. Nerve sheath ganglion of the ulnar nerve. *Arch Orthop Trauma Surg* 2000; 120: 108–109.
10. Chick G, Alnot JY and Silbermann-Hoffman O. Intraneural mucoid pseudocysts. A report of ten cases. *J Bone Joint Surg Br* 2001; 83: 1020–1022.
11. Chalidis BE, Sachinis NC and Dimitriou CG. Ulnar nerve penetration by a volar ganglion in the Guyon canal. *Plast Reconstr Surg* 2009; 124: 264e–266e.
12. Colbert SH and Le MH. Case report: intraneural ganglion cyst of the ulnar nerve at the wrist. *Hand (N Y)* 2011; 6: 317–320.
13. Okada M, Sakaguchi K, Oebisu N, et al. A ganglion within the ulnar nerve and communication with the distal radioulnar joint

- via an articular branch: case report. *J Hand Surg Am* 2011; 36: 2024–2026.
14. Spinner RJ, Wang H, Howe BM, et al. Deep ulnar intraneural ganglia in the palm. *Acta Neurochir (Wien)* 2012; 154: 1755–1763.
  15. Öztürk U, Salduz A, Demirel M, et al. Intraneural ganglion cyst of the ulnar nerve in an unusual location: A case report. *Int J Surg Case Rep* 2017; 31: 61–64.
  16. Spinner RJ, Mikami Y, Desy NM, et al. Superficial radial intraneural ganglion cysts at the wrist. *Acta Neurochir (Wien)* 2018; 160: 2479–2484.
  17. Spinner RJ, Amrami KK, Ibrahim Elshiekh MA, et al. Sural Intraneural Ganglion Cysts Are Joint-related. *Arch Plast Surg* 2012; 39: 77–79.
  18. Spinner RJ, Atkinson JL, Harper CM Jr, et al. Recurrent intraneural ganglion cyst of the tibial nerve. Case report. *J Neurosurg* 2000; 92: 334–337.
  19. Li P, Lou D and Lu H. The cubital tunnel syndrome caused by intraneural ganglion cyst of the ulnar nerve at the elbow: a case report. *BMC Neurol* 2018; 18: 217.
  20. Desy NM, Lipinski LJ, Tanaka S, et al. Recurrent intraneural ganglion cysts: Pathoanatomic patterns and treatment implications. *Clin Anat* 2015; 28: 1058–1069.
  21. Shahid KR, Spinner RJ, Skinner JA, et al. Evaluation of intraneural ganglion cysts using three-dimensional fast spin echo-cube. *J Magn Reson Imaging* 2010; 32: 714–718.