

Effectiveness of a combination of cyclosporine A, suplatast tosilate and prednisolone on periodic oscillating hypereosinophilia

Shinsaku Imashuku¹

Ikuyo Ueda²

Tohru Inaba³

¹Divisions of Pediatrics and Hematology, Takasago-seibu Hospital, Takasago, Japan; ²Department of Pediatrics, Kyoto Prefectural University of Medicine, Kyoto, Japan; ³Department of Infection Control and Laboratory Medicine, Kyoto Prefectural University of Medicine, Kyoto, Japan

Abstract: We report the treatment course of a 29-year-old man who has had unique oscillating *FIP1L1-PDGFR*A fusion gene-negative hypereosinophilic syndrome (HES) for nearly 6 years. His periodic oscillating pattern of eosinophilia associated with angioedematous soft tissue swelling has shown two to three seasonal peaks (>15,000/ μ L absolute eosinophil counts [AEC]) a year. Initially, the patient, who was thought to have distinct HES not compatible with previously described cases, did not respond to treatment except for a temporary response to imatinib mesylate. For 6 years, from 2005 to 2010, he was treated with a combination of oral cyclosporine A, suplatast tosilate, and a small dose of prednisolone, which significantly reduced the peak heights of AEC as well as blunting the oscillating patterns.

Keywords: hypereosinophilic syndrome, eosinophilia, angioedema, IgM, sIL-2R, treatment, cyclosporin A, suplatast tosilate

Introduction

Idiopathic hypereosinophilic syndrome (HES) is characterized by persistent or recurrent hypereosinophilia of unknown origin. Currently, we recognize that HES consists of the myeloproliferative form and the lymphocytic form (T-cell-mediated disorders).¹ Recent identification of *FIP1L1-PDGFR*A fusion gene-positive HES, as a subgroup, has opened a door to innovative treatment using imatinib mesylate in patients with a subset of HES.^{2,3} However, treatment of other patients with a heterogeneous subgroup of Gleich syndrome (periodic angioedema and eosinophilia) and other types of HES without known pathogenesis remains to be explored in future. The causes of periodic oscillating hypereosinophilia⁴⁻¹¹ are often obscure and need to be precisely diagnosed clinically and/or molecularly for the most effective therapy. The patient reported here has shown significant periodic oscillating hypereosinophilia, which was shown to be *FIP1L1-PDGFR*A fusion gene-negative, and was suspected to have Gleich syndrome, but not a version compatible with cases previously described. Our patient is considered to have a distinct subtype of HES in which we documented (a) the pattern of seasonal oscillation of eosinophilia over 6 years and (b) effective control of eosinophilia with a combination of cyclosporin A, suplatast tosilate, and a small dose of prednisolone.

Case report

A 29-year-old male patient with periodic oscillating hypereosinophilia was first diagnosed to have HES (absolute eosinophil counts (AEC) >1500/ μ L) at age 21. From age 21 to 26 years, he was treated for HES at a local hospital on and off with oral prednisolone, but details of the oscillating pattern were unknown. Since he was referred to us, his HES

Correspondence: Shinsaku Imashuku
Division of Pediatrics, Takasago-seibu
Hospital, 1-10-41 Nakasuji, Takasago,
Hyogo Prefecture, 676-0812, Japan
Tel +81 794 47 0100
Fax +81 794 47 0180
Email shinim95@mbox.kyoto-inet.or.jp

was found to be characterized by high levels of serum soluble IL-2R (up to 2700 U/mL; normal <518 U/mL), IgM (up to 1140 mg/dL; normal <190 mg/dL), tryptase (14.4 µg/L, normal 2.1–9.0 µg/L), and vitamin B12 (1400 pg/mL; normal 233–924 pg/mL). Serum levels of IL-5 were elevated to 46.7 U/mL (normal <7.8 U/mL), but serum IgE levels remained consistently within the normal range. At the time of referral, he was initially treated with prednisolone (30 mg/day) alone, but did not attain a remission. The patient was found to have *FIP1L1-PDGFR*A fusion gene-negative; however because there was no useful therapy available, he was treated with imatinib mesylate (100–200 mg/day) at age 26, which was effective in reducing the AEC and negating the oscillating pattern of HES temporarily for about 30 weeks.¹² Thereafter, the patient’s oscillating hyper eosinophilia became uncontrollable again.

In order to determine the pathogenesis of his HES and improve therapeutic measures, we performed flow

cytometry analysis on his lymphocytes, which showed that the CD3–CD4+ population, a subset described in cases of Gleich syndrome,⁹ was increased, accounting for 5.7% of the total (normal <1.0%), but clonality studies on T cell receptors (TCR) showed no rearrangement bands for TCR-C-beta, -J-gamma, and J-delta1 genes (data not shown). Thus, we assumed that his HES could be defined as Gleich syndrome⁹; however it was not clear if the seasonal periodic oscillation of AEC was compatible with this syndrome. In addition, we were aware that AEC showed a good correlation with some serum biomarkers, which was not previously noted in patients with Gleich syndrome. As first noted, such cyclic episodes were temporarily suppressed during the imatinib therapy.¹² After the patient became refractory to imatinib, we were able to document the exact oscillating pattern closely over the past 6 years. This revealed episodes of abundant eosinophilia (AEC >10,000/µL) two to three times

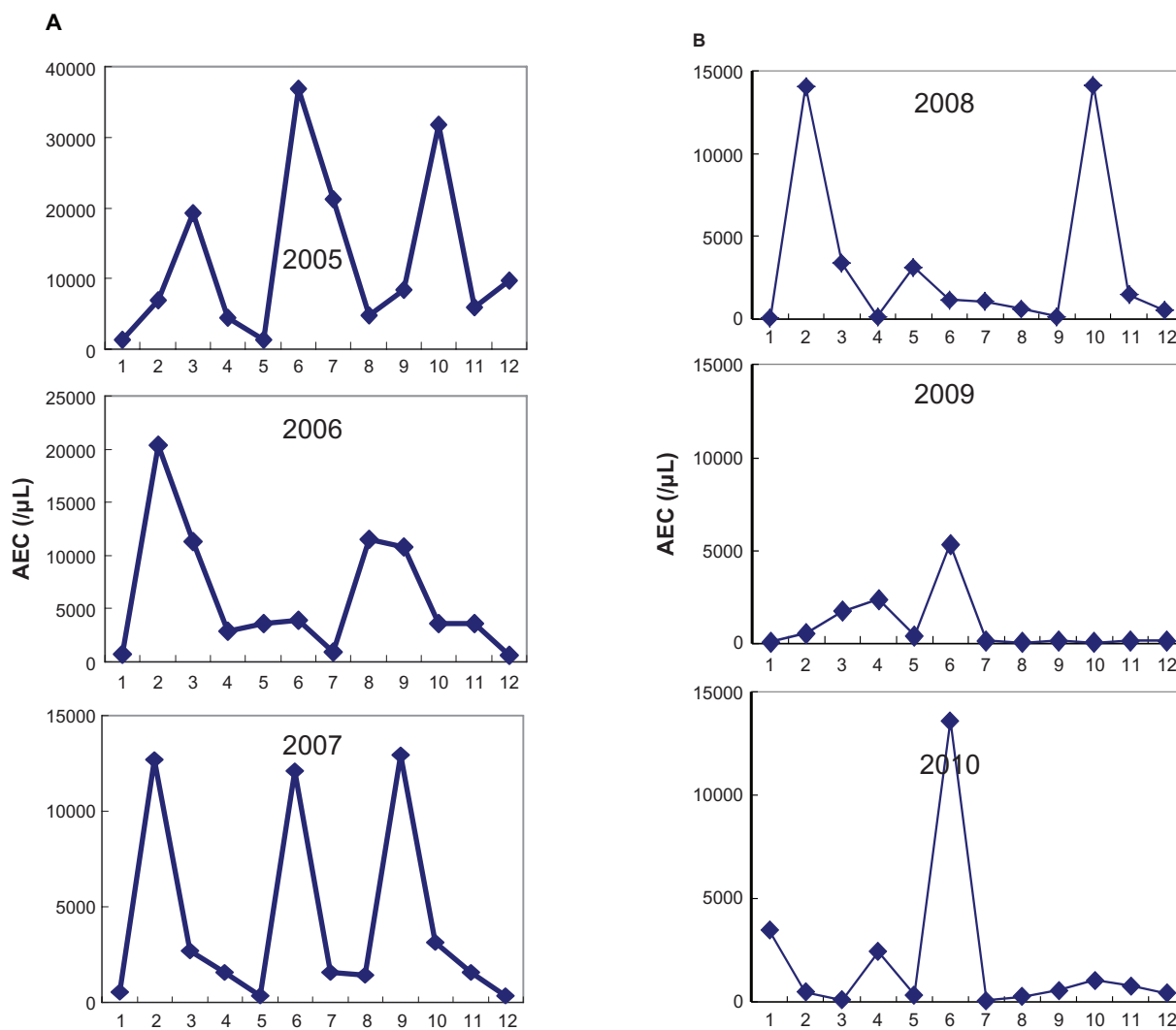


Figure 1 Monthly oscillation of absolute eosinophil counts (AEC) in the patient. Peaks of AEC are seen to be significantly reduced from 2005 to 2007 (A), and from 2008 to 2010 (B).

Note: Numbers in the abscissa indicate months from January to December.

a year, one in early spring (February–March), another in fall (September–October) and another in between (June) in two of the 3 years from 2005 to 2007 (Figure 1A). Among various biological markers, soluble IL-2R ($r = 0.857$, $P < 0.001$) and serum IgM ($r = 0.685$, $P < 0.0025$) values were closely associated with this eosinophilic oscillation (Figure 2); however, none of hemoglobin, platelet counts, IgG, or IgA levels were correlated with the oscillation in eosinophil levels.

During the peak hypereosinophilic episodes, the patient showed soft tissue swellings on the face, forearms, and the lower legs, which could be a kind of angioedematous presentation, but never associated with urticarial rash or fever. As further treatment, we searched for alternative therapeutic measures; anti-IL-5 therapy using humanized anti-IL-5 monoclonal antibody^{13,14} was not available in Japan. Since cyclosporine A was proven beneficial in the treatment of HES¹⁵ and the suplatast tosilate, the Th2 cytokine inhibitor, was reported effective for a patient with hypereosinophilia with a high level of serum IL-5¹⁶ as well as for a patient with eosinophilic gastroenteritis associated with elevated serum IL-5 and sIL-2R,¹⁷ we employed a combination of oral suplatast tosilate (300 mg/day) combined with cyclosporine A (150 mg/day) and prednisolone (10–15 mg/day) over the past 6 years. As seen in Figure 1, peak heights of AEC reduced from 2005 to 2007 (Figure 1A), and further reduced yearly to 2010 in association with reduced incidence of the episodes (Figure 1B). Since July 2010, no further episodes have been seen for over 1 year. However, it was found that the CD3–CD4+ population remained at a level similar to that prior to the initiation of treatment (6.7% of the total). Our observation explains the effectiveness of the combined

therapy for this type of HES. As of October 2011, the patient is doing well without any cardiac or other visceral end organ dysfunction.

Discussion

In HES, Xiao et al described a 54-year-old man who had periodic oscillations in eosinophils, WBC, platelet counts, and Hb.⁴ Cyclic oscillations in blood cell counts were also reported for an HES case by Malcovati et al.⁵ In the case of Xiao et al, the oscillatory cycle lasted approximately 2 months.⁴ In cases of Gleich syndrome, eosinophilic cycles are known to occur every 3–5 weeks, ie, almost every month,^{8,9,11} and are related to the menstrual cycle in female patients.¹⁸ As shown in Figure 1, our case showed cyclic episodes occurring two to three times a year from 2005 to 2007; thereafter this cycle gradually became blunted over the next 3 years. It seems that the episodic cycles in our case are distinct from previously described patients with HES.

In Gleich syndrome, episodic angioedema with eosinophilia is associated with high serum IL-5.^{6–11} Although our case shows angioedematous soft tissue swelling at the peak heights of hypereosinophilic episodes, his clinical features are not associated with the high IgE levels described by several authors,^{6,7,10} or with the itchy urticarial rash described by Schiavino et al.⁷ In addition, the patient did not respond to prednisolone alone as previously reported.^{7,9,10} Clonally proliferated helper T lymphocytes were also shown by several authors in cases of Gleich syndrome.^{10,11} Although we identified some increase in the CD3–CD4+ subset in peripheral blood, no T cell clonality was shown in our case. The hematopoietic abnormalities in the cases of Xiao et al and

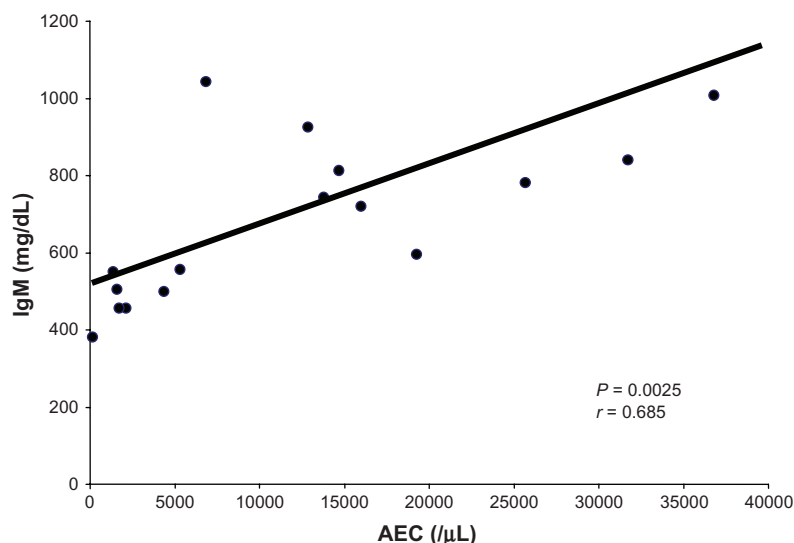


Figure 2 Correlation between absolute neutrophil counts (AEC) and serum IgM levels.

Malcovati et al are thought to originate at the pluripotent stem cell levels.^{4,5} By contrast, periodic oscillations of eosinophils in Gleich syndrome are thought to be regulated by T-cell expansion-associated IL-5 release.^{10,11,19} Distinct oscillations in the AEC of our case, particularly in association with serum IgM levels, appear to occur via a varied pathogenesis, which may represent a variant of Gleich syndrome, although precise mechanism(s) remain unknown. So far no triggering factors have been identified to explain the seasonal hypereosinophilic episodes in our case.

In a situation where no anti-IL-5 antibody is available, we have found that a combination of cyclosporin A, suplatast tosilate, and prednisolone is a good alternative approach in controlling the hypereosinophilic episodes, although suplatast tosilate is said to suppress IgE, but not IgG or IgM production in vivo.²⁰ Over the past 6 years, the three drug combination slowly abolished AEC oscillations in our case. How these drug combinations have acted to slowly alleviate his oscillating HES is unknown. Since we found no decrease of CD3-CD4+ subset with treatment, it was assumed that the inhibitory effect of the treatment including cyclosporin A was not through an effect on the CD3-CD4+ subset. Other possible mechanism(s) needs to be clarified in future. The fact that the precise pathogenesis of oscillating hypereosinophilia is still unknown underscores that there is considerable heterogeneity in HES and/or in Gleich syndrome. Clarification of the basic mechanisms of how eosinophils periodically oscillate is required.

Disclosure

The authors report no conflicts of interest in this work.

References

- Gleich GJ, Leiferman KM. The hypereosinophilic syndromes: still more heterogeneity. *Curr Opin Immunol*. 2005;17(6):679–684.
- Cools J, DeAngelo DJ, Gotlib J, et al. A tyrosine kinase created by fusion of the PDGFRA and FIP1L1 genes as a therapeutic target of imatinib in idiopathic hypereosinophilic syndrome. *N Engl J Med*. 2003;348(13):1201–1214.
- Pardanani A, Brockman SR, Paternoster SF, et al. FIP1L1-PDGFR fusion: Prevalence and clinicopathologic correlates in 89 consecutive patients with moderate to severe eosinophilia. *Blood*. 2004;104(10):3038–3045.

- Xiao Z, Hao Y, Qin T, Han Z. Periodic oscillation of blood leukocytes, platelets, and hemoglobin in a patient with chronic eosinophilic leukemia. *Leukemia Res*. 2003;27:89–91.
- Malcovati L, la Starza R, Merante S, Pietra D, Mecucci C, Cazzola M. Hypereosinophilic syndrome and cyclic oscillations in blood cell counts. A clonal disorder of hematopoiesis originating in a pluripotent stem cell. *Haematologica*. 2004;89(4):497–499.
- Wolf C, Pehamberger H, Breyer S, Leiferman KM, Wolff K. Episodic angioedema with eosinophilia. *J Am Acad Dermatol*. 1989;20(1):21–27.
- Schiavino D, Gentiloni N, Murzilli F, Gebreselassie M, La Rocca LM, Patriarca G. Episodic angioedema with eosinophilia (Gleich syndrome). *Allergol Immunopathol (Madr)*. 1990;18(4):233–236.
- Butterfield JH, Leiferman KM, Abrams J, et al. Elevated serum levels of interleukin-5 in patients with the syndrome of episodic angioedema and eosinophilia. *Blood*. 1992;79(3):688–692.
- Okubo Y, Sato E, Hossain M, Ota T, Yoshikawa S, Sekiguchi M. Periodic angioedema with eosinophilia: increased serum level of interleukin-5. *Intern Med*. 1995;34(2):108–111.
- Roufosse F, Schandené L, Sibille C, et al. Clonal Th2 lymphocytes in patients with the idiopathic hypereosinophilic syndrome. *Br J Haematol*. 2000;109(3):540–548.
- Morgan SJ, Prince HM, Westerman DA, McCormack C, Glaspole I. Clonal T-helper lymphocytes and elevated IL-5 levels in episodic angioedema and eosinophilia (Gleich's syndrome). *Leuk Lymphoma*. 2003;44(9):1623–1625.
- Imashuku S, Kakazu N, Ueda I, et al. Response to imatinib mesylate in a patient with idiopathic hypereosinophilic syndrome associated with cyclic eosinophil oscillations. *Int J Hematol*. 2005;81(4):310–314.
- Klion AD, Law MA, Noel P, Kim YJ, Haverty TP, Nutman TB. Safety and efficacy of the monoclonal anti-interleukin-5 antibody SCH55700 in the treatment of patients with hypereosinophilic syndrome. *Blood*. 2004;103(8):2939–2941.
- Sutton SA, Assa'ad AH, Rothenberg ME. Anti-IL-5 and hypereosinophilic syndromes. *Clin Immunol*. 2005;115(1):51–60.
- Fukuta A, Hara T, Tsurumi H, Moriwaki H. Hypereosinophilic syndrome with DIC treated successfully with a combination of high-dose methylprednisolone and cyclosporin A. *Rinsho Ketsueki*. 2001;42(11):1145–1147.
- Kusumoto H, Mizuno K, Yonemaru M, et al. Successful treatment of chronic eosinophilic pneumonia with suplatast tosilate. *Nihon Kyobu Shikkan Gakkai Zasshi*. 1997;35:550–554. Japanese.
- To M, Suzuki N, Fueta M, Yamada H, Ogawa C, Sano Y. A case of eosinophilic gastroenteritis: observation of serum IL-5 and sIL-2R levels before and after remission. *Arerugi*. 2004;53(4):443–447. Japanese.
- Garcia-Abujeta JL, Martin-Gil D, Martin M, et al. Impaired type-1 activity and increased NK cells in Gleich's syndrome. *Allergy*. 2001;56(12):1221–1225.
- Brugioni D, Airo P, Rossi G, et al. A case of hypereosinophilic syndrome is associated with the expansion of a CD3-CD4+ T-cell population able to secrete large amounts of interleukin-5. *Blood*. 1996;87(4):1416–1422.
- Zhao GD, Yokoyama A, Kohno N, Sakai K, Hamada H, Hiwada K. Effect of suplatast tosilate (IPD-1151T) on a model of asthma: inhibition of eosinophilic inflammation and bronchial hyperresponsiveness. *Int Arch Allergy Immunol*. 2000;121(2):116–122.

International Medical Case Reports Journal

Publish your work in this journal

The International Medical Case Reports Journal is an international, peer-reviewed open-access journal publishing original case reports from all medical specialties. Previously unpublished medical posters are also accepted relating to any area of clinical or preclinical science. Submissions should not normally exceed 2,000 words or

Submit your manuscript here: <http://www.dovepress.com/international-medical-case-reports-journal-journal>

4 published pages including figures, diagrams and references. The manuscript management system is completely online and includes a very quick and fair peer-review system, which is all easy to use. Visit <http://www.dovepress.com/testimonials.php> to read real quotes from published authors.

Dovepress