

## Diffuse Exfoliative Rash with Sepsis and Eosinophilia: A Case of Erythroderma?

Authors' Contribution:  
Study Design A  
Data Collection B  
Statistical Analysis C  
Data Interpretation D  
Manuscript Preparation E  
Literature Search F  
Funds Collection G

ABDEF 1,2 **Jake Cho**  
EF 1,2 **Selsabeel A. Elyaman**  
BCDEF 1,2 **Stephen A. Avera**  
CDE 1,3 **Kenneth Iyamu**

1 Graduate Medical Education, University of Central Florida College of Medicine, Orlando, FL, U.S.A.  
2 Internal Medicine Residency Program, HCA Ocala Regional Medical Center, Ocala, FL, U.S.A.  
3 Faculty of Internal Medicine, HCA Ocala Regional Medical Center, Ocala, FL, U.S.A.

**Corresponding Author:** Jake Cho, e-mail: [Jake.Cho@ucf.edu](mailto:Jake.Cho@ucf.edu)  
**Conflict of interest:** None declared

**Patient:** Male, 56  
**Final Diagnosis:** Exfoliative dermatitis  
**Symptoms:** Edema • erythema • pruritus • rash • sepsis • shivers  
**Medication:** Vancomycin  
**Clinical Procedure:** Skin biopsy  
**Specialty:** General and Internal Medicine



**Objective:** Unusual clinical course  
**Background:** Erythroderma is an exfoliative dermatitis that manifests as generalized erythema and scaling that involves 90% of the body surface. If untreated, erythroderma can be fatal because of its metabolic burden and risk of secondary infections.

**Case Report:** The patient was a 56-year-old male with prior rash attributed to group A Streptococcal cellulitis and discharged on Augmentin, Clindamycin with hydrocortisone cream, and Bactrim, but he had been noncompliant. He was admitted again for rash involving the face, torso, and extremities characterized by diffuse, desquamative, dry scales in morbilliform pattern. The patient was septic with *Staphylococcus aureus* bacteremia and compromised skin barrier. He was started on vancomycin and switched to Cefazolin IV due to concern for drug reaction. Autoimmune workup included antibodies for anti-Jo-1, anti-dsDNA, anti-centromere, and ANCA. However, only antinuclear antibody and scleroderma antibody were positive. Given the unclear workup results and lack of response to antibiotics, the patient was started on prednisone 60 mg PO and topical Triamcinolone 0.1% cream. A skin biopsy revealed psoriasiform hyperplasia with atypical T cell infiltrate and eosinophils, but negative for T cell gene rearrangement. The rash resolved after day 12 of application of topical Triamcinolone.

**Conclusions:** This case is unique in terms of the rarity of erythroderma and the diagnostic challenge given confounding factors such as noncompliance and drug reaction. Serious causes, such as SLE and cutaneous T cell lymphoma, were ruled out. Fortunately, the rash responded well to steroids; however, given the adverse effects of long-term use of topical steroids, the patient will need follow up with Dermatology.

**MeSH Keywords:** Dermatitis, Atopic • Dermatitis, Exfoliative • Exanthema • Lymphoma, T-Cell, Cutaneous • Sepsis • Triamcinolone

**Full-text PDF:** <https://www.amjcaserep.com/abstract/index/idArt/917427>

 1737   14  9



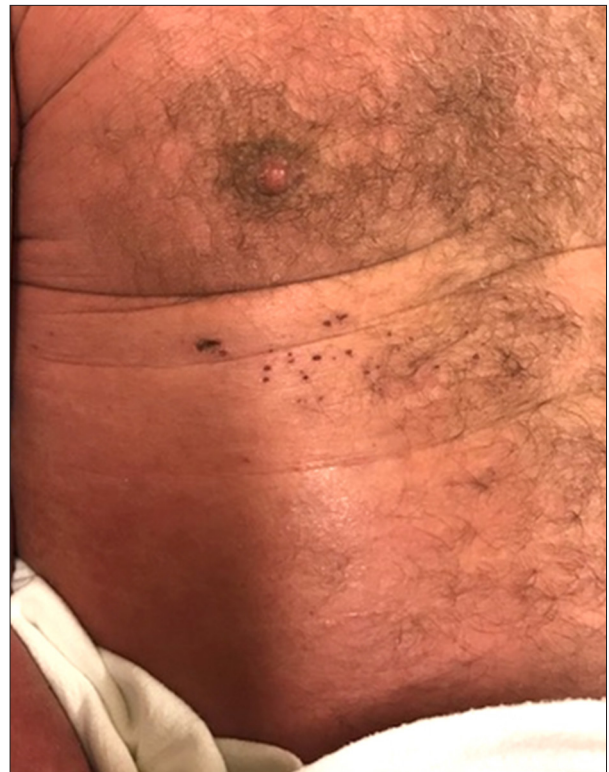## Background

Erythroderma is an inflammatory disorder that manifests as generalized erythema of the skin and exfoliative dermatitis that usually involves more than 90% of the body surface. If not properly managed, erythroderma can be fatal because of its metabolic burden and risk of secondary infections [1]. The annual incidence has been estimated at 1 per 100 000 in a 2001 Netherlands study [1]. Based on international registries, the male-to-female ratio ranges from 2: 1 to 4: 1 and the mean age is 40–60 years [2]. Erythroderma is a rare skin disorder that is usually secondary to factors such as dermatoses (e.g., psoriasis and pityriasis rubra pilaris), drug reaction (e.g., to carbamazepine), malignancies, systemic diseases (e.g., cutaneous T cell lymphoma), infections, and idiopathic disorders (e.g., hyperkeratosis) [3].

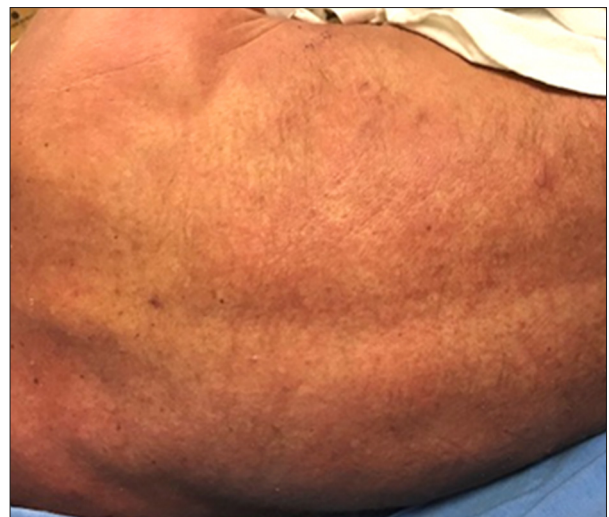
## Case Report

Here, we describe a case of diffuse exfoliative dermatitis in a 56-year-old man who was admitted multiple times for persistent skin rash. On prior admissions spanning 3 months, he was diagnosed with group A Streptococcal (GAS) cellulitis as well as impetigo. He had been previously discharged on Augmentin, then Clindamycin with hydrocortisone cream, and Bactrim, although with poor compliance. On this occasion he was admitted for throbbing pain in the legs and arms and diffuse desquamative rash involving the face, torso, and upper and lower extremities. There was sparing of the palms, soles, rectum, oral labia, and mucosa. There were tender, vesicular, dry varicella-appearing lesions on the right upper back. His admission vitals were body temperature 37°C, respiratory rate 22 bpm, blood pressure 158/116 mmHg, pulse 130 bpm, and oxygen saturation 98%. The patient was noted to be in emotional distress, lying in the lateral decubitus position and shivering. The rash was characterized by diffuse desquamative dry scales in a morbilliform pattern (Figures 1–5). The lesions were intensely pruritic, causing the patient to constantly scratch and exacerbate the scaly plaques. Initial labs showed azotemia with a BUN of 24 mg/dL and leukocytosis of 17.9 thou/mm<sup>3</sup>. Given the copious areas of lacerated skin, blood cultures positive for *Staphylococcus aureus*, and unstable vital signs, he was treated for sepsis with vancomycin IV and later switched to Cefazolin IV due to concern for drug reaction.

The differential diagnosis for the rash included erythroderma syndrome, hypereosinophilic syndrome, cellulitis secondary to GAS or *S. aureus* infection, drug eruption, eczematous dermatitis, psoriasis, ichthyosis, cutaneous T cell lymphoma (mycosis fungoides), and acute lupus erythematosus. Antibiotic allergic reactions such as toxic epidermal necrolysis were less likely given the start of the rash prior to antibiotic exposure, persistent

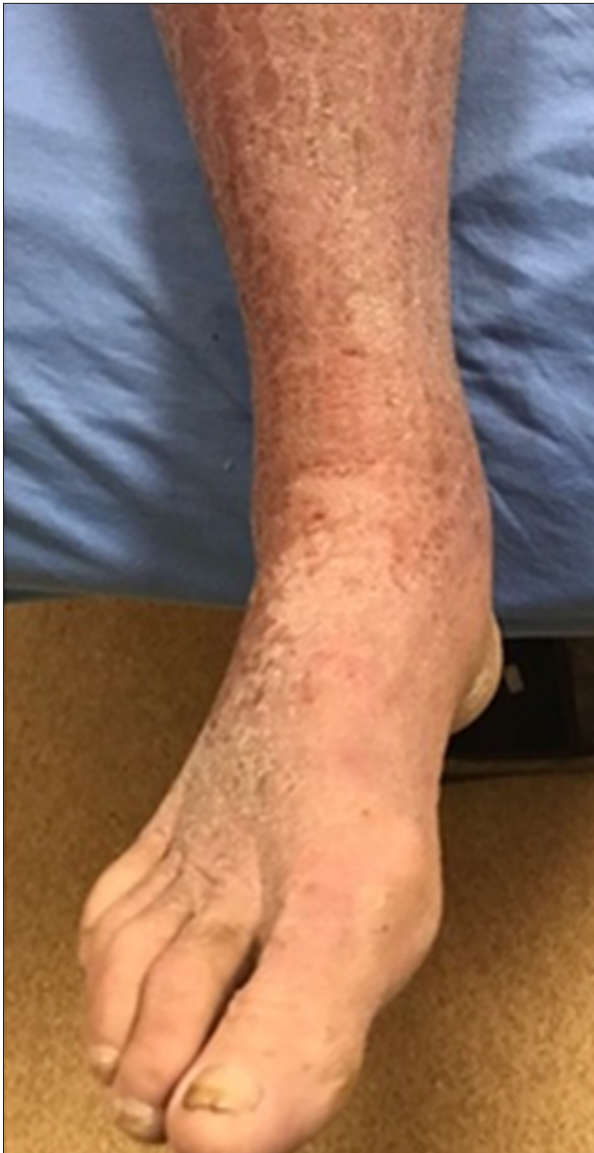

**Figure 1.** Rash on torso before systemic and topical steroids, with grouped crusted vesicular lesions.



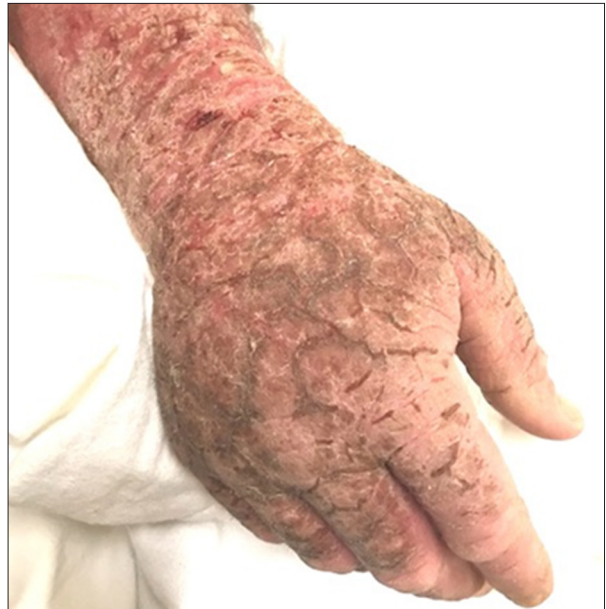**Figure 2.** Rash on back before systemic and topical steroids.

symptoms regardless of therapy, lack of mucosal involvement, and bullous desquamation of the skin. Diphenhydramine was prescribed for pruritus. The right lateral torso vesicular rash was diagnosed as shingles and treated with PO Acyclovir. CT imaging of the chest, abdomen, and pelvis was negative for signs of malignancy or other acute processes. A workup for HIV1/2 and rapid plasma regain test for syphilis were negative. Interestingly, autoimmune panels for ANA and scleroderma

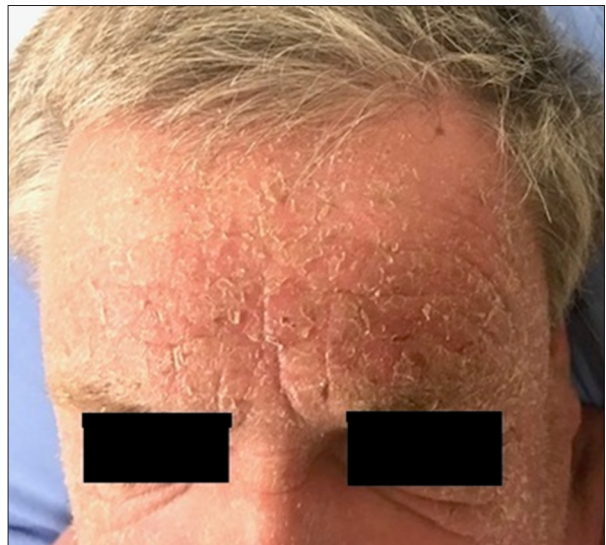

**Figure 3.** Rash on legs before systemic and topical steroids.

antibody (Scl-70) were positive, but testing for dermatomyositis (Jo-1 antibodies), systemic lupus erythematosus (anti-dsDNA), CREST (anti-centromere), and ANCA were all negative. By day 4 of IV vancomycin treatment, the patient's rash and pruritus had not improved, causing him significant emotional distress. Due to concern of drug reaction to vancomycin, antibiotics were changed to IV cefazolin given his limited autoimmune markers and lack of response to anti-bacterial agents, and he was started on prednisone 60 mg PO and topical Triamcinolone 0.1% cream applied copiously and faithfully BID. A skin biopsy of the dorsum of the right hand was also performed and submitted to Pathology. Fortunately, his symptoms began to improve the following day. The biopsy was diagnosed as psoriasiform hyperplasia with atypical T cell infiltrate and eosinophils (Figures 6–9). The specimen was also sent to

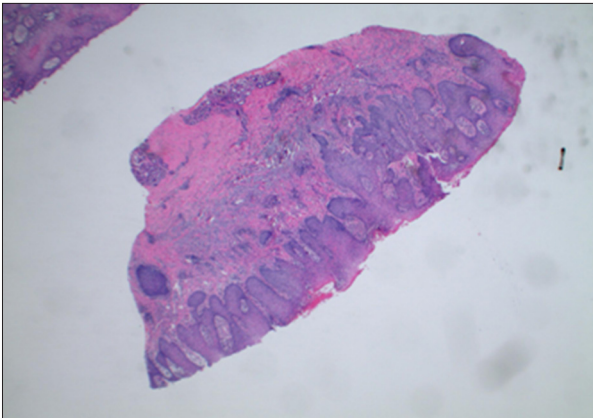


**Figure 4.** Rash on hands before systemic and topical steroids.

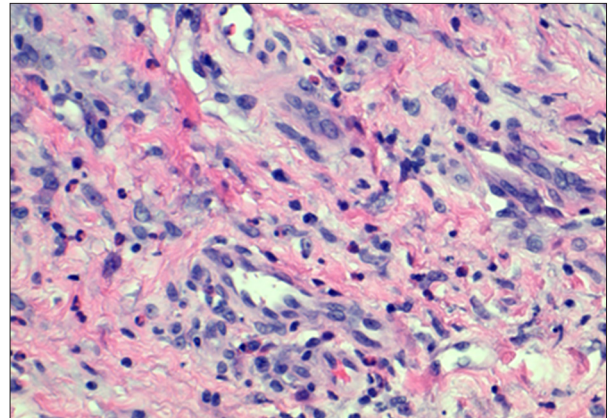


**Figure 5.** Rash on face before systemic and topical steroids.

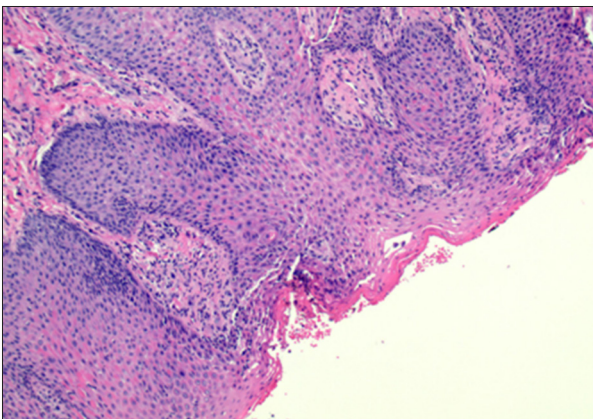
the University of Michigan Dermatopathology Department for T cell gene rearrangement studies, which did not reveal clonal cells. Only after persistent and diligent application of the topical Triamcinolone did the patient begin to make substantial progress, to the point where the desquamation and erythema had resolved by day 12 (Figures 10–14). The oral prednisone was tapered from 60 mg to 40 mg and then to 10 mg. Due to the methicillin-sensitive *Staphylococcus aureus* bacteremia, he was subsequently discharged on IV cefazolin via PICC line, as well as continued Triamcinolone cream, along with recommendation to follow up with Dermatology. Fortunately, the patient did follow up with Dermatology at least 3 times within the first 2 months. During his initial follow-up visits, he was



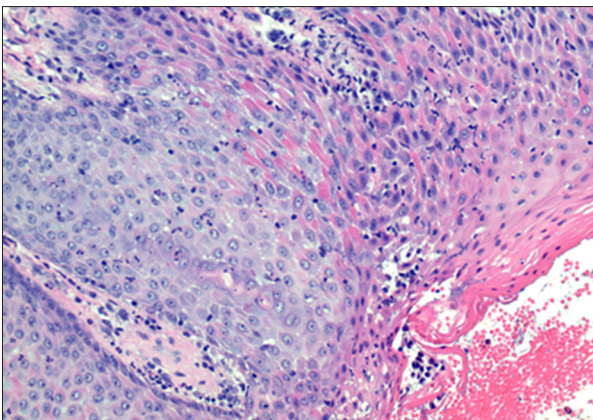
**Figure 6.** Histopathology; psoriasiform hyperplasia with perivascular infiltrate and scale crust.



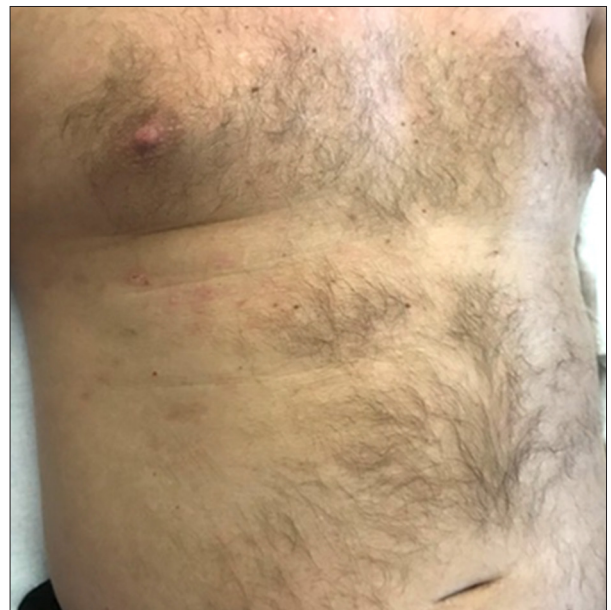**Figure 9.** Histopathology; rash appears to be a psoriasiform dermatitis, likely secondary to drugs.



**Figure 7.** Histopathology; psoriasiform hyperplasia with perivascular infiltrate and scale crust.



**Figure 8.** Histopathology; skin has intraepidermal lymphs, polymorphonuclear cells and eosinophils around vessels in dermis.



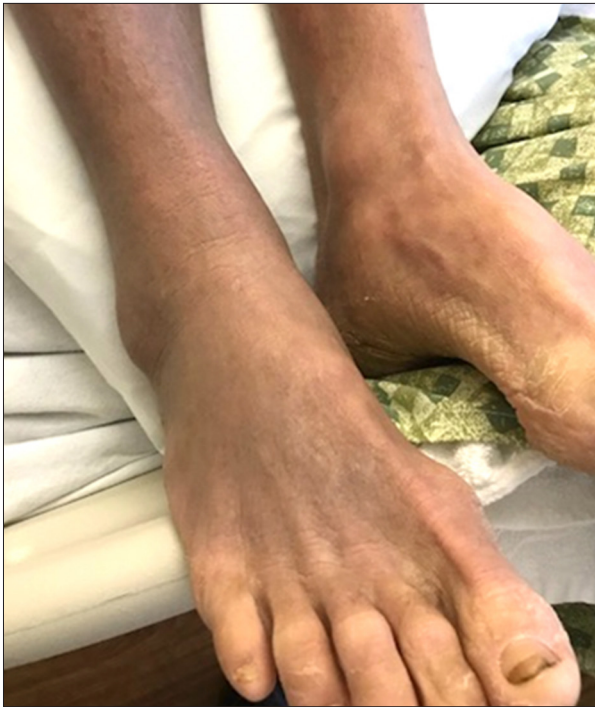**Figure 10.** Rash on torso after 12 days of PO prednisone and topical steroids (Triamcinolone 0.1% cream).

counseled to continue topical Triamcinolone acetonide 0.1% ointment (TAC). He was also given a one-time injection of IM Kenalog 1cc (40 mg). To ensure compliance, the Dermatology clinic went so far as to supply a free sauna suit to aid with

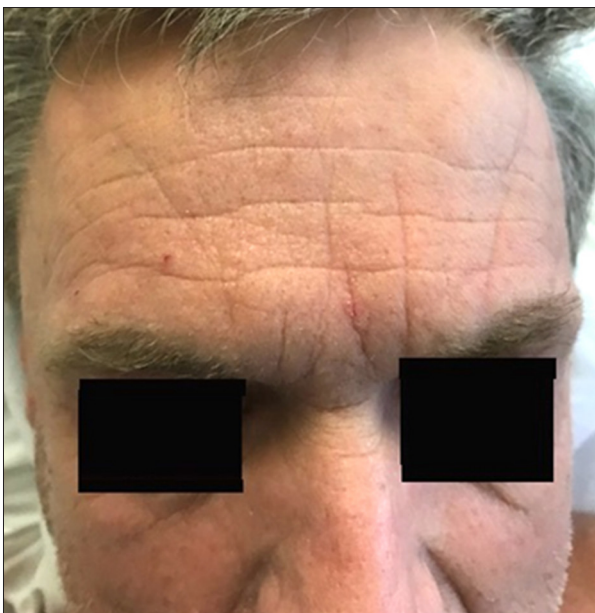the topical ointment application. The patient also underwent a skin punch biopsy from the chest wall and bacterial culture analysis from the right forearm epidermis. Despite continued dermatologic care, including a free sauna suit, procedures, and medications, the patient remained noncompliant. He did not use the suit because he had depleted the jar of TAC, and despite switching oral antibiotics multiple times to accommodate his list of allergic reactions, the patient was eventually lost to follow up.

## Discussion

Given the results of the workup and clinical response, the presenting rash is most consistent with erythroderma syndrome

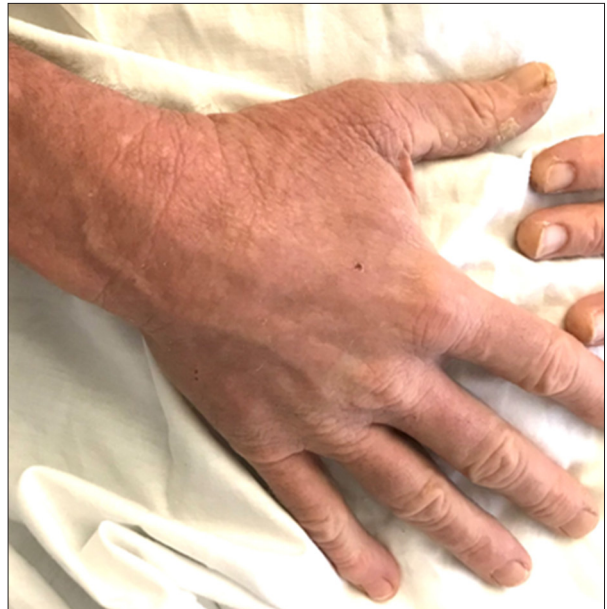

**Figure 11.** Rash on legs after 12 days of PO prednisone and topical steroids (Triamcinolone 0.1% cream).

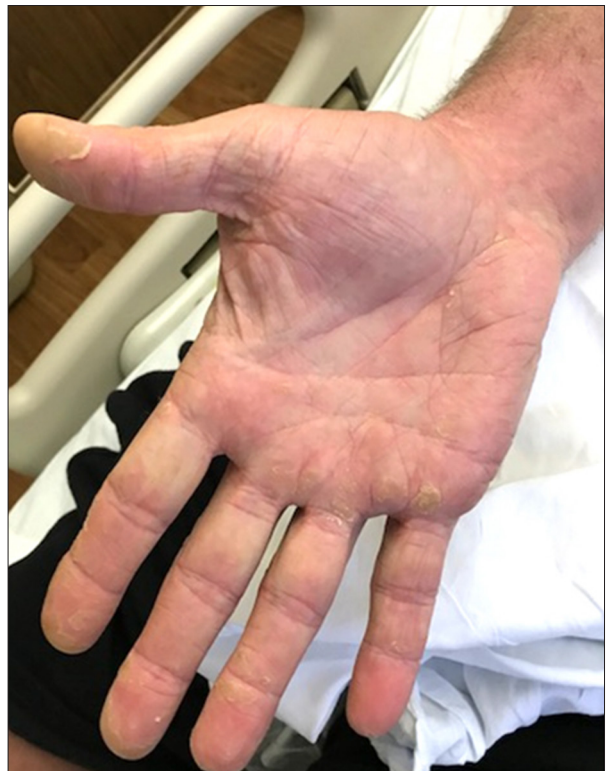

**Figure 12.** Rash on face after 12 days of PO prednisone and topical steroids (Triamcinolone 0.1% cream).

or exfoliative dermatitis [1]. The initiating factor was unclear but most likely due to a drug reaction. As noted by the pathologist, the histology showed psoriasiform hyperplasia with perivascular infiltrate and scale crust with lymphocytes, polymorphonuclear neutrophils, and eosinophilia, likely secondary to drugs. Results from the repeat chest wall punch biopsy



**Figure 13.** Rash on hands after 12 days of PO prednisone and topical steroids (Triamcinolone 0.1% cream).



**Figure 14.** Rash on palms after 12 days of PO prednisone and topical steroids (Triamcinolone 0.1% cream).

are congruent with the initial findings. The biopsy specimen measured about 0.6 cm by 0.5 cm and was analyzed by a dermatopathologist. The histology was consistent with an eczematous process such as allergic contact dermatitis, nummular

dermatitis, or atopic dermatitis. Spongiotic drug eruption was also a possibility. Features of pityriasis rubra pilaris or mycosis fungoides were not identified and periodic acid-Schiff stain was negative for fungal hyphae (histology not available). The overall diagnosis was subacute spongiotic dermatitis with numerous eosinophils, which can be caused by a variety of conditions, including contact dermatitis, atopic dermatitis, and drug reactions [4]. Chronic spongiotic dermatitis acquires psoriasiform configuration over time [5], which is consistent with the initial impression of psoriasiform dermatitis (Figure 2). An environmental cause could not be ruled out as the patient resided in an encampment within the borders of a national park and had no daily access to clean water supply or electrical power. Interesting features of this case included signs of marked protein depletion (total protein 6.1 g/dL and albumin 2.7 g/dL) despite adequate oral intake and a BMI of 26. We suspect this was from cutaneous protein losses due to extreme keratotic turnover that inhibited thermo-regulation and caused excessive water loss [1]. Hence, the persistent shivering and cold intolerance and signs of acute kidney injury on labs that improved with volume resuscitation. Interestingly, the CBC not only showed leukocytosis (WBC 17.2 thou/mm<sup>3</sup>) but also eosinophilia with EOS count of 3.4 thou/mm<sup>3</sup>. High eosinophils in the setting of positive ANA and scleroderma antibodies may suggest hypereosinophilia compounded by scleroderma [6,7]. Classically, hypereosinophilic syndrome (HES) is a myeloproliferative disorder defined as peripheral eosinophilia (>1500 cells/mm<sup>3</sup>) with end-organ damage due to tissue eosinophilia and absence of a secondary cause [8]. The main organs involved are skin (erythroderma), lungs, intestine, heart (myocardial fibrosis, chronic heart failure), and kidneys [8]. Although his renal function and lung imaging were unremarkable, cardiac echocardiography showed a reduced left ventricular ejection fraction (EF 35%) with diastolic dysfunction. Transesophageal echocardiography was negative for endocarditis; however, given the reduced EF, the patient was started on low-dose Lisinopril PO and metoprolol tartrate PO. Although the nature of his heart failure was unclear, the differential diagnosis includes eosinophilic myocarditis caused by eosinophilic infiltration, degranulation, and lymphocytic infiltration leading to thrombosis and fibrosis [9].

## Conclusions

This case is unique in terms of the rarity of erythroderma and the diagnostic challenge given numerous confounding factors. In general, erythroderma can be categorized as either insidious or acute [3]. Insidious processes include systemic diseases such as psoriasis and cutaneous T cell lymphoma. Although drug reaction is the most common cause for acute onset, this patient had a history of medication noncompliance, making

it difficult to identify a culprit drug, as demonstrated by the multiple iterations of PO antibiotics during follow-up dermatologic care. Nevertheless, due diligence was undertaken to incorporate clinical information and microanatomy of the skin, including T cell gene rearrangement studies, to narrow the differential diagnosis. Autoimmune marker findings and histological evaluation ruled out more serious causes such as systemic lupus erythematosus and cutaneous T cell lymphoma. Fortunately, the patient responded well clinically to both oral and topical steroids. However, given the adverse effects of topical steroids, the patient will need long-term guidance from Dermatology. This case also highlights the social aspects of patient compliance. Despite access to appropriate follow-up dermatologic care, including repeat skin biopsy, bacterial culture, and prescription treatment, this patient experienced social difficulty in affording the one-pound jar of TAC, being compliant with daily use of the free sauna suit, and eventually being lost to follow-up. Hence, treatment success in the indigenous patient population, as in this patient, depends not only accurate diagnosis and treatment but equally as important, being aware of potential social barriers to medical compliance.

## Acknowledgements

We would like to thank Dr. Jeffrey Gray, D.O. Pathology, Laboratory Medical Director at Ocala Regional Medical Center, Ocala, FL, for analyzing and providing the digital microscopy slides for histologic studies in this case. We would also like to thank the University of Michigan Dermatopathology Department for further analysis of the dermatologic tissue for T cell gene rearrangement. We also acknowledge Dr. Sergey Kachur, University of Central Florida College of Medicine, Graduate Medical Education, Orlando, FL, Ocala Regional Medical Center, Internal Medicine Faculty, Ocala, FL for proof-reading this manuscript.

(\*) Special thanks to Dr. Kathryn Holloway, M.D. of Ocala Dermatology & Skin Cancer Center, Ocala, FL for providing Dermatology clinic follow-up progress notes, Dermatopathology histology report, and microbiology skin culture results from 3 clinic visits.

## Disclosures

This research was supported (in whole or in part) by HCA and/or an HCA affiliated entity. The views expressed in this publication represent those of the author(s) and do not necessarily represent the official views of HCA or any of its affiliated entities.

## Conflict of interest

None.

## References:

---

1. Sehgal VN, Srivastava G, Sardana K: Erythroderma/exfoliative dermatitis: A synopsis. *Int J Dermatol*, 2004; 43(1): 39–47
2. Li J, Zheng HY: Erythroderma: A clinical and prognostic study. *Dermatology*, 2012; 225(2): 154–62
3. Akhyani M, Ghodsi, ZS, Toosi S, Dabbaghian H: Erythroderma: A clinical study of 97 cases. *BMC Dermatol*, 2005; 5: 5
4. Alsaad KO, Ghazarian D: My approach to superficial inflammatory dermatoses. *J Clin Pathol*, 2005; 58(12): 1233–41
5. Sutarjono B, Lebovitch H: Psoriasiform spongiotic dermatitis. *BMJ Case Rep*, 2019; 12: e228690
6. Ramirez GA, Yacoub MR, Ripa M et al: Eosinophils from physiology to disease: A comprehensive review. *Biomed Res Int*, 2018; 2018: 9095275
7. Simon D, Wardlaw A, Rothenberg ME: Organ-specific eosinophilic disorders of the skin, lung, and gastrointestinal tract. *J Allergy Clin Immunol*, 2010; 126(1): 3–13; quiz 14–15
8. Abdulsalam MS, Ghanta HC, Pandurangan P et al: A Case of erythroderma secondary to hypereosinophilia. *J Clin Diagn Res*, 2016; 10(5): OD15–16
9. Khalid M, Gayam V, Dahal S et al: Hypereosinophilic syndrome complicated by eosinophilic myocarditis with dramatic response to steroid. *J Investig Med High Impact Case Rep*, 2018; 6: 2324709618764512