



Case report

Endobronchial laser ablation in the management of epithelial-myoeipithelial carcinoma of the trachea

David McCracken ^{a, *}, Jason Wieboldt ^a, Pushpinder Sidhu ^b, Kieran McManus ^b^a Causeway Hospital, 4 Newbridge Road, Coleraine BT52 1HS, UK^b Royal Victoria Hospital, 274 Grosvenor Road, Belfast BT12 6BA, UK

ARTICLE INFO

Article history:

Received 28 August 2015
 Received in revised form
 18 October 2015
 Accepted 19 October 2015

Keywords:

Airway
 Bronchoscopy
 Epithelial-myoeipithelial

ABSTRACT

A 52 year old, never smoker presented to hospital with progressive shortness of breath and significant stridor over a five month period. He also described the feeling of needing to cough but being unable to expectorate. CT Thorax demonstrated a mass lesion in the trachea just distal to the larynx which was then confirmed on rigid bronchoscopy. Subsequent histology confirmed an epithelial-myoeipithelial carcinoma.

Only a few case reports document these rare salivary gland tumours occurring in other locations such as the respiratory tract. After staging showed only local disease, the patient was managed with rigid bronchoscopy and laser ablation therapy.

We present the first documented case to be treated with endobronchial laser ablation therapy with discussion of the incidence, presentation and characteristics of these tumours including the treatment options, as well as the use of laser ablation in the management of benign and malignant endobronchial lesions.

© 2015 The Authors. Published by Elsevier Ltd. This is an open access article under the CC BY-NC-ND license (<http://creativecommons.org/licenses/by-nc-nd/4.0/>).

1. Introduction

Epithelial-myoeipithelial carcinoma is a rare, apparently low grade malignancy of the salivary glands which occurs most commonly in the parotid gland. These tumours may also present in other manners such as primary pulmonary malignancies with only a very small number of cases previously reported.

Of these pulmonary manifestations, the frequent presentations include breathlessness, cough, occasional haemoptysis or often even as incidental findings, with only one case documenting stridor as a key feature, as in our case.

Due to the extremely infrequent presentation of such cases, no defined treatment paradigms or “gold standards” exist. We present the first documented case to be treated with endobronchial laser ablation therapy.

2. Case presentation

A 52 year old, previously fit and well gentleman presented to hospital with progressive shortness of breath and significant stridor

over a five month period. He also described the feeling of needing to cough but being unable to expectorate. He gave no history of haemoptysis or weight loss.

He was a never smoker who gave no personal or contact history of tuberculosis, no significant occupational exposures and no history of asthma or atopy, although his GP had treated his progressive dyspnoea as asthma with inhaled bronchodilators to no effect. He had no other significant past medical history or drug history.

Computed Tomography (CT) of the Thorax (Fig. 1) demonstrated a twelve millimetre, partially obstructive, pedunculated mass lesion in the trachea just distal to the larynx at the level of C7 which was then confirmed on rigid bronchoscopy. A staging CT showed no metastatic disease or lymphadenopathy.

Biopsy specimens obtained following laser ablation were initially non-diagnostic but were felt to represent low grade tumour derived from an accessory gland in the mucosa. Specialist expert input was sought from pathologists in the Royal Brompton Hospital, London. Their report described fibrovascular stroma infiltrated by an epithelial tumour comprising of solid islands and tubular aggregates of mild to focally moderately pleomorphic epithelial cells. The epithelial cells showed irregular infiltration. In areas of tubular architecture, a focal dual layer was noted, with the inner layer staining for cytokeratines and the outer layer staining

* Corresponding author.

E-mail address: dmccracken04@qub.ac.uk (D. McCracken).

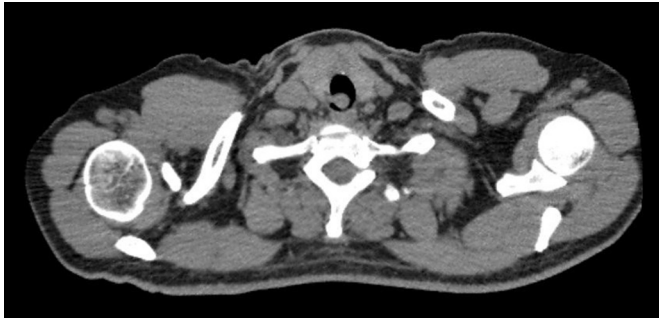


Fig. 1. Axial CT image demonstrating partially occlusive, pedunculated tracheal lesion.

for S100 and smooth muscle actin. There was also an associated moderate non-specific chronic inflammatory cell infiltrate.

Given the morphology, the specimens were classified as an epithelial-myoepithelial carcinoma.

Management options were discussed at the regional lung cancer multidisciplinary team meeting involving respiratory, thoracic and oncology specialist teams and the decision was made to proceed with rigid bronchoscopy and laser ablation therapy.

A Nd-YAG laser was used with the fibre passed through a fiberoptic bronchoscope which was then passed through a rigid bronchoscope, the latter being required to control the airway. Initial biopsies were fragmented meaning that margins could not be adequately assessed and so further laser ablation therapy was undertaken in an attempt to ensure satisfactory removal of the entire lesion.

Positron Emission Tomography (PET-CT) demonstrated no abnormal active uptake at the original site of the lesion, or at any distant metastatic or nodal site, and the decision was made for follow up with surveillance CT and bronchoscopy initially after 3 months.

3. Discussion

Tracheal tumours are extremely rare and have been estimated to comprise approximately 0.1% of all malignancies [1] with figures for new cases quoted between 1.4 and 2.6 per 1,000,000 every year [2,3].

Of these cases of tracheal tumours, the majority are made up of squamous cell carcinoma and adenoid cystic carcinoma, but salivary gland tumours may also occur infrequently due to the presence of submucosal glands in the trachea and bronchi [4].

Epithelial-myoepithelial tumours are low grade, indolent malignancies of the salivary glands, most commonly the parotids, with only approximately 120 documented cases [5], thus representing approximately 1% of salivary gland tumours [6]. They may also seldom occur in extraglandular locations such as the respiratory tract, a location which comprises a tenth of the number of cases documented [4].

Histologically these are malignant tumours composed of two cell types in varying proportions creating a double layer. These consist of an inner layer of eosinophilic, duct lining epithelial cells creating a tubular structure, surrounded by an outer layer of solid, clear myoepithelial cells [7].

Treatment options for these cases remains unclear. The consensus has been that wide surgical excision, in keeping with the routine management of salivary gland tumours, may be appropriate, and the majority of case studies have demonstrated this in the form of segmental tracheal resection with end-to-end anastomosis [5,7]. The necessity for negative margins from surgical resection is generally accepted as a minimum [9] as incomplete

excision is associated with local recurrence and metastases [6]. It has been suggested that recurrence rates may be as high as 40% but this may be, at least in part, due to incomplete resection [6]. Very little evidence exists as to the benefit of radiotherapy or chemotherapy; however one case report describes complete resolution of metastatic disease with chemotherapy [8].

Endobronchial laser ablation therapy is a treatment option for patients with benign and malignant tracheal or bronchial tumours with its evidence base strongly established in the 1980s and 90s [10–12].

In the past, it has more commonly been used in benign lesions or in those patients for whom treatment is not intended to be curative. This is due to the advanced stage of disease often evident at presentation and the invasive and aggressive nature of many primary lung malignancies. In these cases, laser ablation is used to give symptomatic relief by debulking tumour and removing the endobronchial obstruction [13].

Increasingly, however, laser ablation is being used in patients with early malignancy or low-grade malignancy. Many screening programmes, along with the improvement of imaging and staging techniques have resulted in an increase in stage I and II cancers detected, allowing for less invasive treatment strategies. Endobronchial laser ablation can be seen as a suitable, curative, non-invasive management option when staging investigations have demonstrated minimal invasion and no nodal involvement or metastases, with some studies demonstrating 90–100% success rates with regards to recurrence at 5 years [13–15].

In this case, the multidisciplinary team felt that endobronchial laser ablation was an appropriate treatment option given the low grade nature of the lesion, no evidence of local invasion, no nodal involvement or metastases, but also given the reduced procedural morbidity and mortality, and the cost effectiveness when compared with other surgical options such as segmental tracheal resection with anastomosis.

Due to the significant recurrence rates quoted for epithelial-myoepithelial carcinoma, early follow up at three months with repeat computed tomography and bronchoscopy have been arranged.

4. Conclusions

- Tracheal tumours are extremely rare but salivary gland tumours may occasionally present in the respiratory tract due to the presence of submucosal glands
- Epithelial-myoepithelial tumours are low grade malignancies of the salivary glands that seldom occur in extraglandular locations
- Treatment options are unclear due to the small number of cases but surgical resection with negative margins is generally considered a minimum
- Endobronchial laser ablation therapy has an increasing role in the curative management of malignant lesions with minimal invasion and no nodal involvement or metastases

References

- [1] B.F. Meyers, D.J. Mathisen, Management of Tracheal Neoplasms, *Oncologist* 2 (4) (1997) 245–253.
- [2] J. Honings, J.A. van Dijk, A.F. Verhagen, H.F. van der Heijden, H.A. Marres, Incidence and treatment of tracheal cancer: a nationwide study in the Netherlands, *Ann. Surg. Oncol.* 14 (2) (2007 Feb) 968–976.
- [3] A.I. Urdaneta, J.B. Yu, L.D. Wilson, Population based cancer registry analysis of primary tracheal carcinoma, *Am. J. Clin. Oncol.* 34 (1) (2011 Feb) 32–37.
- [4] G. Muñoz, F. Felipo, I. Marquina, C. Del Agua, Epithelial-myoepithelial tumour of the lung: a case report referring to its molecular histogenesis, *Diagn. Pathol.* 6 (2011) 71.
- [5] M. Konoglou, A. Cheva, P. Zarogoulidis, K. Porpodis, A. Pataka, A. Mpaliaka, et al., Epithelial-myoepithelial carcinoma of the trachea—a rare entity case report, *J. Thorac. Dis.* 6 (Suppl 1) (2014 Mar) S194–S199.

- [6] I. Fonseca, J. Soares, Epithelial-myoepithelial carcinoma, in: L. Barnes, J.W. Eveson, P. Reichart, et al. (Eds.), *World Health Organization Classification of Head and Neck Tumours*, first ed., IARC Press, Lyon, 2005, pp. 225–226.
- [7] H. Horinouchi, T. Ishihara, M. Kawamura, R. Kato, K. Kikuchi, K. Kobayashi, et al., Epithelial myoepithelial tumour of the tracheal gland, *J. Clin. Pathol.* 46 (1993) 185–187.
- [8] H. Yamazaki, Y. Ota, T. Aoki, A. Kaneko, Lung metastases of epithelial-myoepithelial carcinoma of the parotid gland successfully treated with chemotherapy: a case report, *J. Oral Maxillofac. Surg.* 71 (1) (2013 Jan) 220–226.
- [9] A. Muslimani, M. Kundranda, S. Jain, H. Daw, Recurrent Bronchial Epithelial-Myoepithelial Carcinoma After Local Therapy, *Clin. Lung Cancer* 8 (6) (2007) 386–388.
- [10] M.R. Hetzel, C. Nixon, W.M. Edmondstone, D.M. Mitchell, F.J.C. Millard, E.M. Nanson, et al., Laser therapy in 100 tracheobronchial tumours, *Thorax* 40 (1985) 341–345.
- [11] W.M. Brutinel, D.A. Cortese, J.C. McDougall, R.G. Gillio, E.J. Bergstralh, A two-year experience with the neodymium-YAG laser in endobronchial obstruction, *Chest* 91 (2) (1987 Feb) 159–165.
- [12] D.J. Ross, Z. Mohsenifar, S.K. Koerner, Survival characteristics after neodymium: YAG laser photoresection in advanced stage lung cancer, *Chest* 98 (3) (1990 Sep) 581–585.
- [13] C.T. Bolliger, T.G. Sutedja, J. Strausz, L. Freitag, Therapeutic bronchoscopy with immediate effect: laser, electrocautery, argon plasma coagulation and stents, *Eur. Respir. J.* 27 (6) (2006) 1258–1271.
- [14] T.G. Sutedja, A.J. van Boxem, P.E. Postmus, The curative potential of intraluminal bronchoscopic treatment for early-stage non-small-cell lung cancer, *Clin. Lung Cancer* 2 (4) (2001 May) 264–270.
- [15] T.J. van Boxem, B.J. Venmans, F.M. Schramel, J.C. van Mourik, R.P. Golding, P.E. Postmus, T.G. Sutedja, Radiographically occult lung cancer treated with fiberoptic bronchoscopic electrocautery: a pilot study of a simple and inexpensive technique, *Eur. Respir. J.* 11 (1) (1998 Jan) 169–172.