

## INTESTINAL OBSTRUCTION FROM MECKEL'S DIVERTICULUM IN AN ADULT; UNSUSPECTED BUT FOUND- A CASE REPORT

O.A Ajagbe<sup>1</sup>, M.C Okor<sup>1</sup>, O.T Ojediran<sup>1</sup>, O.E Dada<sup>1</sup>, O.O Ayandipo<sup>2</sup>, M.A Ajani<sup>3</sup>

1. Department of Surgery, University College Hospital, Ibadan, Nigeria.
2. Department of Surgery, College of Medicine, University of Ibadan, Ibadan, Nigeria.
3. Department of Pathology, College of Medicine, University of Ibadan, Ibadan, Nigeria.

*Correspondence:*

**Dr. O.A Ajagbe**

Department of Surgery,  
University College Hospital,  
Ibadan, Nigeria.  
Email: dr\_ajagbe1@yahoo.com

*Submission Date: 8th June, 2023*

*Date of Acceptance: 30th Oct., 2023*

*Publication Date: 1st Nov., 2023*

### ABSTRACT

**Introduction:** Most cases of Meckel's Diverticulum (MD) are asymptomatic and when symptomatic, preoperative diagnosis of MD maybe a dilemma. Intestinal obstruction is a major complication in the adult population.

**Case presentation:** We report a case of a 24-year-old female presenting with intestinal obstruction from Meckel's Diverticulum.

**Conclusion:** MD is largely asymptomatic in adults, however may be present and should be included in our array of differential diagnoses.

**Keywords:** Acute intestinal obstruction, Meckel's diverticulum, Nigeria

### INTRODUCTION

The thought of Meckel's diverticulum (MD) usually brings to mind a pathology of the pediatric population and often managed by pediatric surgeons rather than those who care for adults.<sup>1</sup> It is rarely symptomatic in adults however when it does present with symptoms, they are those of its complications ranging from lower GI bleeding to intestinal obstruction.<sup>2</sup> Because of its rare presentation in the adult population, it is usually missed or misdiagnosed preoperatively.<sup>3</sup>

It is almost always discovered inadvertently in adults and as such the management is based on the findings at surgical intervention. Treatment of symptomatic MD is surgery, the type of procedure depends on the integrity of diverticulum base and adjacent ileum as well as the presence and the location of ectopic tissue within it.<sup>4</sup>

The aim of this case report is to incite surgeons to entertain a high index of suspicion of Meckel's Diverticulum while managing and exploring adults with acute abdomen or abdominal symptoms.

### CASE PRESENTATION

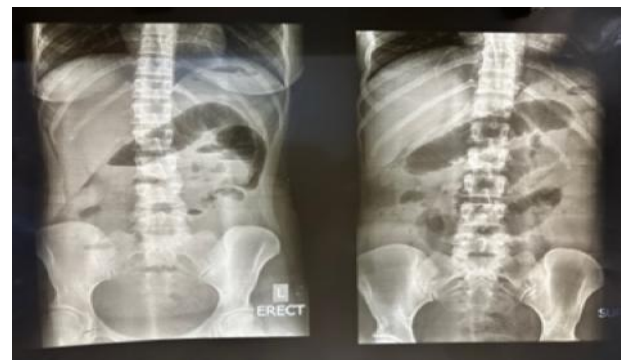The patient is a 24-year-old female nursing student who presented to the emergency department with a four-day history of constipation and progressive abdominal distention. She had an associated feeling of being unwell with 2 episodes of vomiting.

She had no co-morbidities, no prior history of abdominal surgeries, and is nulliparous.

Examination revealed a young lady, acutely ill-looking, not pale, not febrile, dehydrated, and tachycardic. Her

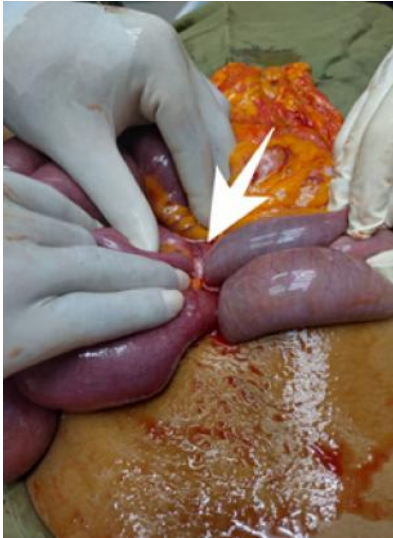abdomen was distended and moved with respiration, the bowel sounds were hyperactive. Rectal examination revealed an empty rectum with no palpable masses. Other aspects of the physical examination appeared normal.

A diagnosis of intestinal obstruction from small bowel volvulus was made. She was optimized for surgery, commenced on broad-spectrum antibiotics, fluids and was placed on Nil per Os (NPO) in preparation for exploratory laparotomy. The plain abdominal X-rays showed multiple air-fluid levels with dilated proximal bowel and relative gaslessness in the pelvis (Figure 1).

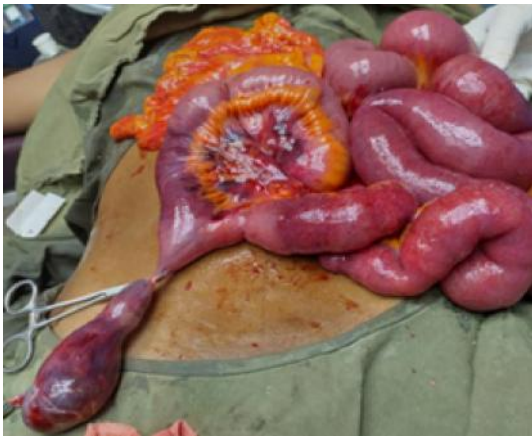

**Figure 1:** Preoperative X-ray showing multiple air-fluid levels and dilated bowel loops

She had laparotomy with intra-operative findings of dilated proximal bowel loops, a constriction band over the ileum approximately 60cm from the ileocaecal junction connected to a diverticulum on the antimesenteric border of the ileum. (Figures 2 and 3). The Meckel's diverticulum was excised at the stalk base.

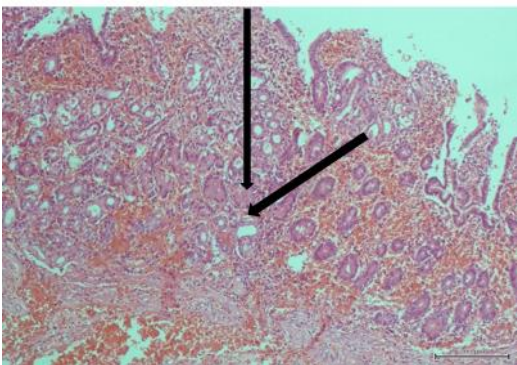


**Figure 2:** Intraoperative picture showing the band over the ileum (white arrow)



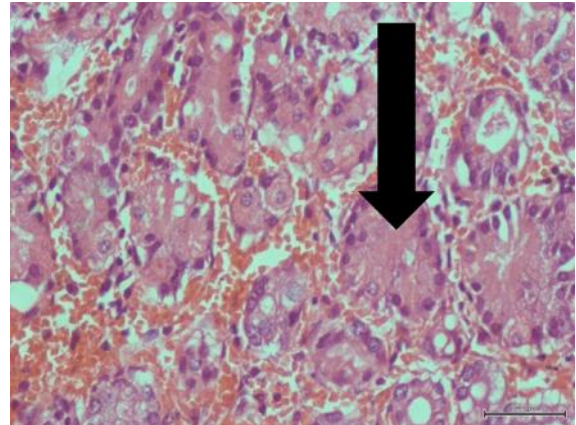
**Figure 3:** shows the Meckel's diverticulum on the antimesenteric border of the ileum (clamped at the base)

On the second postoperative day, she was commenced on a clear fluid diet and this was graduated to a normal diet. The postoperative period was uneventful and she was discharged on the 5<sup>th</sup> postoperative day.



**Figure 4a:** Photomicrograph showing distinct layers of Meckel's diverticulum with focal areas of gastric-type glands (arrows). (Haematoxylin and eosin stains, X100)

Histopathology specimen showed a true ileal diverticulum with a focal area of gastric tissue (Figures 4a and b)



**Figure 4b:** Photomicrograph showing Meckel's diverticulum with focal areas of gastric-type glands (arrow). (Haematoxylin and eosin stains, X400).

### DISCUSSION

Obstruction from Meckel's Diverticulum is a known symptom or as it were a complication. MD is often asymptomatic in adults, usually discovered incidentally at surgeries for other purposes or found as a cause of obstruction<sup>5</sup> as exemplified by the above case.

Obstruction of the small intestine, lower gastrointestinal tract bleeding, and inflammation are some presenting complaints in the symptomatic patient.<sup>6</sup> Most acute surgical emergencies are usually related to intestinal obstruction, however, MD causing intestinal obstruction is rare in the literature.<sup>7</sup>

Other rare complications include inversion of Meckel's diverticulum, torsion, volvulus of ileum around Meckel's diverticulum or fibrous cord, and perforation - spontaneously or by foreign body.<sup>8</sup>

MD is considered a true diverticulum composed of all layers of the intestine, usually located on the antimesenteric border of the ileum, about 30 cm to 90cm from the ileocecal valve.<sup>5</sup>

In our case, MD was located at 60cm proximal to ileocecal valve. In the general population, the prevalence of MD is 0.3%–2.9% with male to female ratio of 1.5:1–4:1.<sup>9</sup> Only about 4% of patients with MD become symptomatic while others remain asymptomatic for life.<sup>5</sup>

The classical symptoms of intestinal obstruction is abdominal pain and distention, vomiting and or constipation. The case presented with abdominal pain,

distention, and vomiting suggesting intestinal obstruction. Multiple air fluid levels in diagnostic imaging indicate pathological accumulation of fluid and/or gas and are characteristic findings in X-rays of small bowel obstruction<sup>10</sup> which was also classical for our case. (Figure 1).

Nonetheless, labeling MD as a culprit for the cause of obstruction is a herculean task using basic radiographic examination alone though hallmarks of bowel obstruction, or a gas fluid level in the diverticulum may be demonstrated.<sup>11</sup>

Delayed diagnosis of MD spells doom as it may result in significant morbidity and mortality. Its early recognition is imperative since a delay in surgery of thirty-six (36) hours or more can triple the mortality rate from 8% to 25% in patients featured with strangulation<sup>10</sup>. Therefore, surgeons/clinicians must be intentional about MD, its presentation, and the best practices for its diagnosis and management. Symptoms, clinical suspicion, and availability determine the diagnostic method to be selected. Technetium 99m pertechnetate scintigraphy (Meckel's Scan) is the investigation of choice to diagnose MD<sup>12</sup>, but it also has moderate diagnostic sensitivity in children and adolescents with poor sensitivity in adults. However, with new inventions such as video capsule endoscopy (VCE) and balloon enteroscopy, the preoperative diagnosis of MD looks promising.<sup>13</sup>

Surgical resection has always been the treatment of choice in symptomatic MD<sup>14</sup>. Our patient underwent surgery and had excision of the diverticulum, there was no post-operative sequelae reported in this patient.

Since the diagnosis of MD was only made intraoperatively, it suggests that we are still lacking preoperative diagnosis and this brings to fore, that newer diagnostic techniques are being awaited. Until then, our clinical acumen preoperatively and intraoperatively still needs to be broadened and sharpened.

## CONCLUSION

MD is largely asymptomatic in adults, however may be present and should be included in our array of differential diagnoses.

The authors declare no conflict of interest.

“Written informed consent was obtained from the patient for publication of this case report and accompanying images.

## REFERENCES

1. **Lequet J**, Menahem B, Alves A, *et al.* Meckel's diverticulum in the adult. *J Visc Surg.* 2017 Sep;154(4):253-259.
2. **Rayan MN**, Tang X, Khazem M, *et al.* Case for Thought: Meckel's Diverticulum in the Adult Population. *Cureus.* 2022 Apr 26;14(4):e24494.
3. **Sagar J**, Kumar V, Shah DK. Meckel's diverticulum: a systematic review. *J R Soc Med.* 2006 Oct;99(10):501-5. Erratum in: *J R Soc Med.* 2007 Feb;100(2):69.
4. **Blouhos K**, Boulas KA, Tsalis K, *et al.* Meckel's Diverticulum in Adults: Surgical Concerns. *Front Surg.* 2018 Sep 3;5:55.
5. **Bhattarai HB**, Bhattarai M, Shah S, *et al.* Meckel's diverticulum causing acute intestinal obstruction: A case series. *Clin Case Rep.* 2022 Nov 6;10(11):e6518.
6. **Mackey WC**, Dineen P. A fifty year experience with Meckel's diverticulum. *Surg Gynecol Obstet.* 1983 Jan;156(1):56-64.
7. **Newme K**, Hajong R, Khongwar D. Meckel's diverticulum causing acute intestinal obstruction: Report of two cases. *J Family Med Prim Care* 2020;9:4409-4411.
8. **Puligandla PS**, Becker L, Driman D, *et al.* Inverted Meckel's diverticulum presenting as chronic anemia: case report and literature review. *Can J Surg.* 2001 Dec;44(6):458-459.
9. **Ruscher KA**, Fisher JN, Hughes CD, *et al.* National trends in the surgical management of Meckel's diverticulum. *J Pediatr Surg.* 2011 May;46(5):893-896.
10. **Almas T**, Alsubai AK, Ahmed D, *et al.* Meckel's diverticulum causing acute intestinal obstruction: A case report and comprehensive review of the literature. *Ann Med Surg (Lond).* 2022 May 7;78:103734.
11. **Elsayes KM**, Menias CO, Harvin HJ, *et al.* Imaging manifestations of Meckel's diverticulum. *AJR Am J Roentgenol.* 2007 Jul;189(1):81-88.
12. **Xinias I**, Mavroudi A, Fotoulaki M, *et al.* Wireless Capsule Endoscopy Detects Meckel's Diverticulum in a Child with Unexplained Intestinal Blood Loss. *Case Rep Gastroenterol.* 2012 Sep; 6(3):650-659.
13. **García-Compeán D**, Jiménez-Rodríguez AR, Del Cueto-Aguilera *et al.* Meckel's diverticulum diagnosis by video capsule endoscopy: A case report and review of literature. *World J Clin Cases.* 2018 Nov 26;6(14):791-799.
14. **Cullen JJ**, Kelly KA, Moir CR, *et al.* Surgical management of Meckel's diverticulum. An epidemiologic, population-based study. *Ann Surg.* 1994 Oct;220(4):564-8; discussion 568-569.