

Delayed regaining of gait ability in a patient with brain injury

A case report

Sung Ho Jang, MD, Hyeok Gyu Kwon, PhD*

Abstract

Background: Little is known about delay in regaining gait ability at a chronic stage after brain injury. In this study, we report on a single patient who regained the gait ability during 2 months of intensive rehabilitation starting 2 years after a brain injury.

Methods and results: A 40-year-old male patient diagnosed with viral encephalitis underwent comprehensive rehabilitation until 2 years after onset. However, he could not even sit independently and presented with severe physical deconditioning and severe ataxia. To understand his neurological state, 4 neural tracts related to gait function were reconstructed, and based on the state of these neural tracts, we decided that the patient had the neurological potential to walk independently. Therefore, we assumed that the main reasons for gait inability in this patient were severe physical deconditioning and truncal ataxia. Consequently, the patient underwent the following intensive rehabilitative therapy: administration of drugs for control of ataxia (topiramate, clonazepam, and propranolol) and movement therapy for physical conditioning and gait training. As a result, after 2 months of rehabilitation, he was able to walk independently on an even floor, with improvement of severe physical deconditioning and truncal ataxia.

Conclusion: We described the rehabilitation program in a single patient who regained the gait ability during 2 months of intensive rehabilitation starting 2 years after a brain injury.

Abbreviations: CPCT = corticopontocerebellar tract, CRT = corticoreticulospinal tract, CST = corticospinal tract, DRTT = dentatorubrothalamic tract, FAC = Functional Ambulation Category, SARA = Scale for Assessment and Rating of Ataxia.

Keywords: ataxia, gait, motor recovery, rehabilitation

1. Introduction

In rehabilitation, gait regaining is a common goal in patients with gait deficits due to brain injury. Gait requires comprehensive components: stepping movements, muscle power of leg and trunk, maintenance of equilibrium, interlimb coordination, somatosensory input, cardiovascular fitness, and so on.^[1–4] Therefore, gait dysfunction, a common sequela of brain injury, is usually caused by motor weakness, somatosensory problems, balance problems, incoordination of movement, and so on.^[1–6] The vast majority of the patients regain gait at the early stage after

brain injury.^[7–10] However, little is known about delayed regaining of gait ability at a chronic stage after brain injury.^[11,12] We believe that research on the delayed regaining of gait ability following brain injury is very important because this could be helpful for successful rehabilitation of gait regaining in patients with long-term gait dysfunction.

We report on a patient who regained the ability to ambulate after 2 months of intensive rehabilitation that was only started 2 years after the initial brain injury.

2. Case report

A 40-year-old male patient diagnosed with viral encephalitis was treated for status epilepticus at the neurology department of a university hospital for 6 months without complications and was then transferred to a local rehabilitation hospital (Fig. 1A). No previous medical history of neurological, physical, or psychiatric illness was noted. Despite undergoing general and comprehensive rehabilitation (administration of drugs, physical and occupational therapy, and neuromuscular electrical stimulation) until 2 years after onset, he was not able to walk independently. Consequently, he was transferred to a rehabilitation department of another university hospital approximately 2 years after onset. His cognitive function was within normal range (Mini-Mental State Examination score, 27). The patient could not even sit independently and presented with mild ataxic dysarthria, severe physical deconditioning due to being bedridden long term, quadriparesis (upper extremities—right side: 4/left side: 4 and lower extremities—right side: 3/left side: 3, no muscle atrophy), spasticity of the ankle (Modified Ashworth Scale: 1+ grade), severe resting and intentional tremor on 4 extremities, and severe

Editor: Chunxia Cao.

This research was supported by Basic Science Research Program through the National Research Foundation of Korea (NRF) funded by the Ministry of Education (2015R1D1A4A01020385).

The authors have no conflicts of interest to disclose.

Department of Physical Medicine and Rehabilitation, College of Medicine, Yeungnam University, Daegu, Republic of Korea.

* Correspondence: Hyeok Gyu Kwon, Department of Physical Medicine and Rehabilitation, College of Medicine, Yeungnam University, 317-1, Daemyungdong, Namku, Daegu 705-717, Republic of Korea (e-mail: khg0715@hanmail.net)

Copyright © 2016 the Author(s). Published by Wolters Kluwer Health, Inc. All rights reserved.

This is an open access article distributed under the terms of the Creative Commons Attribution-Non Commercial-No Derivatives License 4.0 (CCBY-NC-ND), where it is permissible to download and share the work provided it is properly cited. The work cannot be changed in any way or used commercially.

Medicine (2016) 95:38(e4898)

Received: 9 June 2016 / Received in final form: 18 August 2016 / Accepted: 24 August 2016

<http://dx.doi.org/10.1097/MD.0000000000004898>

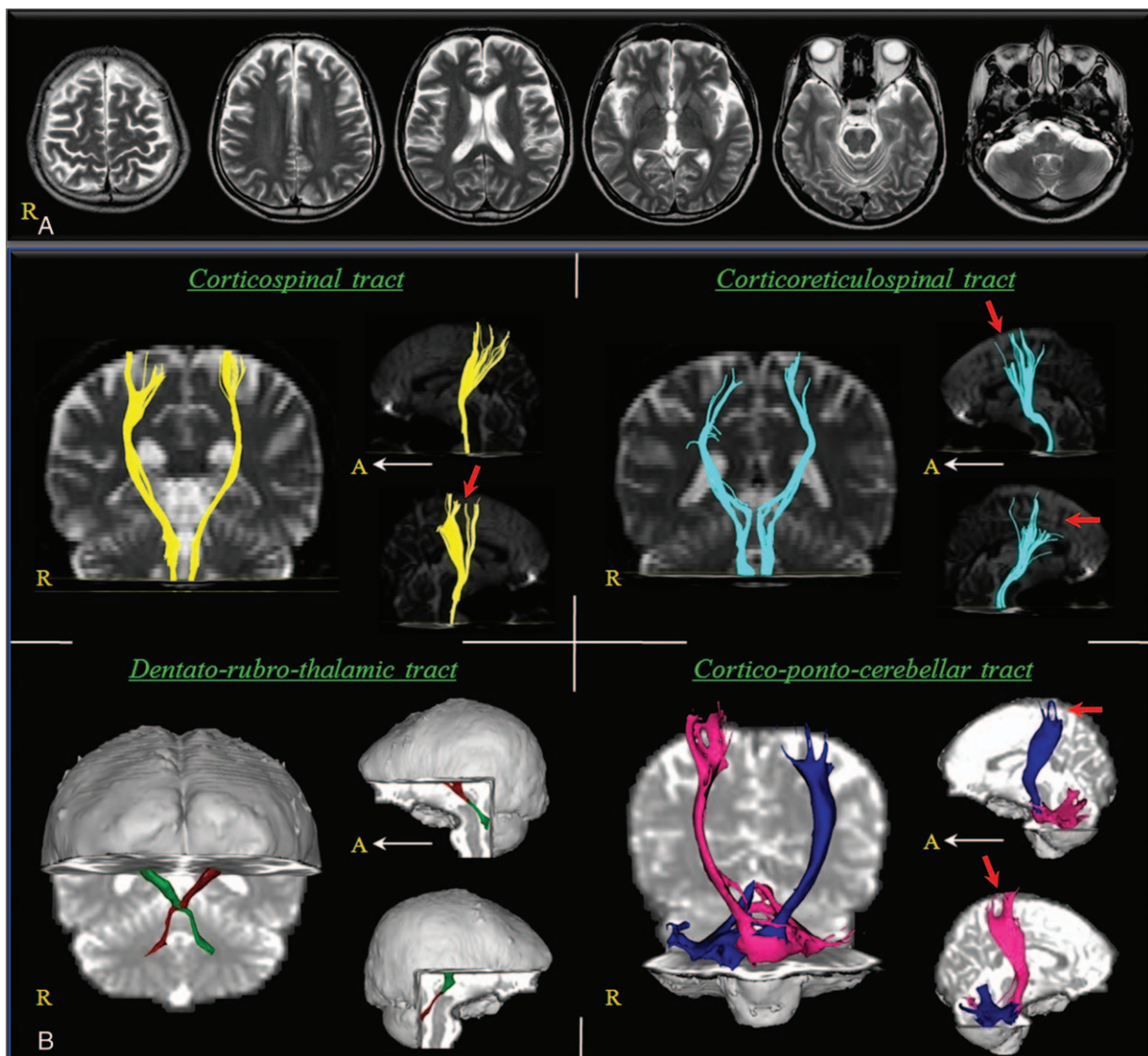


Figure 1. (A) T2-weighted brain magnetic resonance (MR) images at 2 years after onset show no abnormality. (B) The corticospinal tract, corticoreticulospinal tract (CRT), dentatorubrothalamic tract, and corticopontocerebellar tract (CPCT) show the integrity between cortex and brainstem or cerebellar hemisphere in both hemispheres. In contrast, the right corticospinal tract, both CRTs, and both CPCTs show partial injuries (arrows) at the subcortical white matter.

truncal ataxia (Scale for Assessment and Rating of Ataxia [SARA, 26 points] and Functional Ambulation Category [FAC, 0 point]) (Table 1).^[13,14] SARA (0–40 points: a higher score indicates a worse stage) and FAC (0–5 points: a lower score indicates a worse state) were measured for ataxia and gait function, respectively.^[13,14] At that time, he was prescribed the following drugs without change or stopping: spasticity control (baclofen 60 mg and diazepam 15 mg) and epilepsy control (dantrolene 75 mg, levetiracetam 1500 mg, and valproate 1800 mg). To understand the neurological state, 4 neural tracts (the corticospinal tract [CST] and corticoreticulospinal tract [CRT] for leg weakness, and the dentatorubrothalamic tract [DRTT] and corticoponto-cerebellar tract [CPCT] for ataxia) were reconstructed.^[15–18] For reconstruction of these neural tracts, we used DTI-Studio software (CMRM, Johns Hopkins Medical Institute, Baltimore, MD, USA) based on deterministic tracking for CST and CRT with a fractional anisotropy of 0.2 and a tract turning angle of <60° and FMRIB Software Library (University of Oxford, Oxford, UK) based on probability tracking for DRTT and CPCT

with a result threshold of 2 streamlines.^[19,20] CST, CRT, DRTT, and CPCT were analyzed using regions of interest (ROIs) as follows^[15–18]: CST: ROI 1—anterior portion of upper pons on the axial image and ROI 2—anterior portion of lower pons on the

Table 1

Clinical data for the patient.

Duration from onset		24-mo	26-mo
MRC	Shoulder abductor	4	4
	Elbow flexor	4	4
	Finger flexor	4	4
	Finger extensor	4	4
	Hip flexor	3	4
	Knee extensor	3	4
	Ankle dorsiflexor	3	4
	SARA	26	14
FAC	0	3	

FAC = Functional Ambulation Category, MRC = Medical Research Council, SARA = Scale for Assessment and Rating of Ataxia.

axial image^[15]; CRT: ROI 1—reticular formation of the medulla on the axial image and ROI 2—tegmentum of the midbrain on the axial image^[18]; DRTT: ROI 1—dentate nucleus on the coronal image, ROI 2—junction of the superior cerebellar peduncle on the coronal image, and ROI 3—contralateral red nucleus of the upper midbrain on the axial image^[16]; and CPCT: ROI 1—primary sensorimotor cortex on axial image, ROI 2— anterior pons on the axial image, and ROI 3—contralateral cerebellar hemisphere on coronal image.^[17] Although partial injuries were observed in the right CST, both CRT, and both CPCTs, based on the state of these neural tracts, we decided that the patient had the neurological potential to walk independently (Fig. 1B). Therefore, we assumed that the main reasons for gait inability in this patient were ascribed to severe physical deconditioning and truncal ataxia. Consequently, the patient underwent the following intensive rehabilitative therapy: administration of drugs for control of ataxia: topiramate: 37.5 mg, clonazepam: 4 mg, and propranolol: 60 mg; and movement therapy (30 min/d and 5 times/wk) for physical conditioning and gait training in sections of the physical and occupational therapy, and bedside: motor strengthening of both legs and trunk, exercises for trunk stability and control, static and dynamic balance training in sitting and standing positions, and neuromuscular electrical stimulation (30 min/d and 5 times/wk) of both knee extensor and ankle dorsiflexor.^[21–25] As a result, after 2 months rehabilitation, he was able to walk independently on an even floor with improvement of severe physical deconditioning, truncal ataxia (SARA: 14 points and FAC: 3 points), and spasticity (Modified Ashworth Scale: 0 grade).^[13,14] The patient provided written informed consent, and the study protocol was approved by the Yeungnam University Hospital Institutional Research Board.

3. Discussion

In this study, we report on a patient who regained the gait ability during 2 months of intensive rehabilitation, starting 2 years after brain injury. Before admission to our hospital, although the patient received general and comprehensive rehabilitation including the administration of drugs, physical, and occupational therapy for range of motion exercise, motor strengthening, and neuromuscular electrical stimulation, he did not improve enough to walk. However, during 2 months rehabilitation at our hospital, he could walk independently. We considered the main reasons for regaining of gait ability in this patient. First, when the patient started rehabilitation at our hospital, we decided that he had the neurological potential to walk independently by confirmation of 4 neural tracts related to gait function that were not so severely injured as to preclude walking. In addition, descending tracts involving the bulbar reticular activating system that were not injured could contribute in the successful rehabilitation.^[26] Second, we examined the main causes of gait inability in this patient (severe physical deconditioning and truncal ataxia) and designed an intensive rehabilitation program to resolve these problems within 2 months. At the start of rehabilitation, the patient could not even sit independently; however, after rehabilitation, the patient was able to walk independently. We think the administration of drugs (topiramate, clonazepam, and propranolol) was effective for control of severe ataxia including tremor and movement therapy was effective for regaining of physical condition and gait ability.^[21–25] Therefore, we suggest that clinicians and therapists seeing patients who are not able to walk at a chronic stage after brain injury should

determine the neurological potential for independent gait of the patient, determine precise causes of gait inability, then design an intensive and individualized rehabilitation program including appropriate prescription of drugs.

Since the introduction of DTI, a few studies have reported on delayed gait recovery following brain injury.^[11,12] In 2012, Kwon and Jang reported on a patient who did not recover motor function of the left lower extremities until 6 months after onset of putaminal intracerebral hemorrhage. However, following active rehabilitation including medications for apraxia, the patient gradually recovered motor function on the left lower extremities due to resolution of apraxia, and he could finally walk independently at 9 months after the stroke.^[11] The next year, Seo et al^[12] described a patient with intracerebral hemorrhage, who showed delayed gait recovery due to relief of severe leg spasticity, which started at 8 months after the initial injury. During the 3 months' rehabilitation (from 8 to 11 months after onset), the patient regained the ability to walk independently on even floor. By contrast, with our patient, resolution of severe physical deconditioning and truncal ataxia appeared to be the main causes of regaining gait ability.

In conclusion, we described the rehabilitation program in a patient who regained the gait ability by 2 months intensive rehabilitation that started 2 years after brain injury. We believe that this rehabilitation program could be a good example to rehabilitate patients who cannot walk following brain injury. However, this study is limited because it is based on a single case report. Therefore, we suggest that further studies including larger case numbers of patients who could not walk are warranted.

References

- Shik ML, Orlovsky GN. Neurophysiology of locomotor automatism. *Physiol Rev* 1976;56:465–501.
- Keenan MA, Perry J, Jordan C. Factors affecting balance and ambulation following stroke. *Clin Orthop Relat Res* 1984;182:165–71.
- Friedman PJ. Gait recovery after hemiplegic stroke. *Int Disabil Stud* 1990;12:119–22.
- Patterson SL, Forrester LW, Rodgers MM, et al. Determinants of walking function after stroke: differences by deficit severity. *Arch Phys Med Rehabil* 2007;88:115–9.
- Jorgensen HS, Nakayama H, Raaschou HO, et al. Recovery of walking function in stroke patients: the Copenhagen Stroke Study. *Arch Phys Med Rehabil* 1995;76:27–32.
- Jang SH. The recovery of walking in stroke patients: a review. *Int J Rehabil Res* 2010;33:285–9.
- Wade DT, Wood VA, Hewer RL. Recovery after stroke—the first 3 months. *J Neurol Neurosurg Psychiatry* 1985;48:7–13.
- Jorgensen HS, Nakayama H, Raaschou HO, et al. Outcome and time course of recovery in stroke. Part II: Time course of recovery. The Copenhagen Stroke Study. *Arch Phys Med Rehabil* 1995;76:406–12.
- Kim CH. Motor recovery after stroke. *J Korean Acad Rehabil Med* 1995;19:55–61.
- Jang SH, Kwon HG. Recovery of an injured corticospinal tract during early stage rehabilitation following pontine infarct. *Neural Regen Res* 2016;11:519–20.
- Kwon H, Jang SH. Delayed recovery of gait function in a patient with intracerebral haemorrhage. *J Rehabil Med* 2012;44:378–80.
- Seo JP, Lee MY, Kwon YH, et al. Delayed gait recovery in a stroke patient. *Neural Regen Res* 2013;8:1514–8.
- Weyer A, Abele M, Schmitz-Hubsch T, et al. Reliability and validity of the scale for the assessment and rating of ataxia: a study in 64 ataxia patients. *Mov Disord* 2007;22:1633–7.
- Cunha IT, Lim PA, Henson H, et al. Performance-based gait tests for acute stroke patients. *Am J Phys Med Rehabil* 2002;81:848–56.
- Jang SH. Somatotopic arrangement and location of the corticospinal tract in the brainstem of the human brain. *Yonsei Med J* 2011;52:553–7.
- Kwon HG, Hong JH, Hong CP, et al. Dentatorubrothalamic tract in human brain: diffusion tensor tractography study. *Neuroradiology* 2011;53:787–91.

- [17] Hong JH, Jang SH. Functional magnetic resonance imaging and diffusion tensor tractography of the corticopontocerebellar tract in the human brain. *Neural Regen Res* 2011;6:76–80.
- [18] Yeo SS, Chang MC, Kwon YH, et al. Corticoreticular pathway in the human brain: diffusion tensor tractography study. *Neurosci Lett* 2012; 508:9–12.
- [19] Smith SM, Jenkinson M, Woolrich MW, et al. Advances in functional and structural MR image analysis and implementation as FSL. *Neuroimage* 2004;23(suppl 1):S208–19.
- [20] Jang H, van Zijl PC, Kim J, et al. DtiStudio: resource program for diffusion tensor computation and fiber bundle tracking. *Comput Methods Programs Biomed* 2006;81:106–16.
- [21] Sethi KD. Tremor. *Curr Opin Neurol* 2003;16:481–5.
- [22] Owen DA, Marsden CD. Effect of adrenergic beta-blockade on parkinsonian tremor. *Lancet* 1965;2:1259–62.
- [23] Dietrichson P, Espen E. Primidone and propranolol in essential tremor: a study based on quantitative tremor recording and plasma anticonvulsant levels. *Acta Neurol Scand* 1987;75:332–40.
- [24] Biary N, Koller W. Kinetic predominant essential tremor: successful treatment with clonazepam. *Neurology* 1987;37:471–4.
- [25] Hedera P, Cibulcik F, Davis TL. Pharmacotherapy of essential tremor. *J Cent Nerv Syst Dis* 2013;5:43–55.
- [26] Tapia JA, Trejo A, Linares P, et al. Reticular activating system of a central pattern generator: premovement electrical potentials. *Physiol Rep* 2013;1:e00129.