

 **Case Report** 

# Surgical Treatment of a Left Axillary Arterial Aneurysm with Marfan Syndrome by Combining Two Skin Incisions

Hiroshi Sato, MD, PhD and Syuichi Naraoka, MD, PhD

An axillary arterial aneurysm is a rare disorder, with few surgical cases reported to date. Here we report the case of a left axillary arterial aneurysm associated with Marfan syndrome. A 44-year-old female with Marfan syndrome presented with numbness of the left upper limb and a pulsatile mass on the left chest. A computed tomography scan revealed a highly enlarged and tortuous left axillary arterial aneurysm. We performed a graft replacement and resection of the aneurysm with two skin incisions. After the surgery, the blood flow to the patient's left upper limb was confirmed, and the neurological symptoms improved significantly.

**Keywords:** axillary arterial aneurysm, Marfan syndrome

## Introduction

An isolated aneurysm of the axillary artery is a relatively rare entity with a reported incidence rate of less than 1% among peripheral arterial aneurysms.<sup>1,2)</sup> As the etiology of the axillary aortic aneurysm is primarily arteriosclerotic, its association with connective tissue disorders, including Marfan syndrome, is even rarer. Open surgical reconstruction and excision of the aneurysm are the leading treatment modalities because of the high curability. However, some cases are challenging to reconstruct depending on the degree of aneurysmal enlargement as the axillary artery is anatomically surrounded by vital organs such as

the clavicle or brachial plexus. Here, we present the case of a left axillary aortic aneurysm with Marfan syndrome that was successfully treated with graft replacement and aneurysmal resection by combining supraclavicular and infraclavicular approach. We obtained the patient's consent for possible publication of this case report.


## Case Report

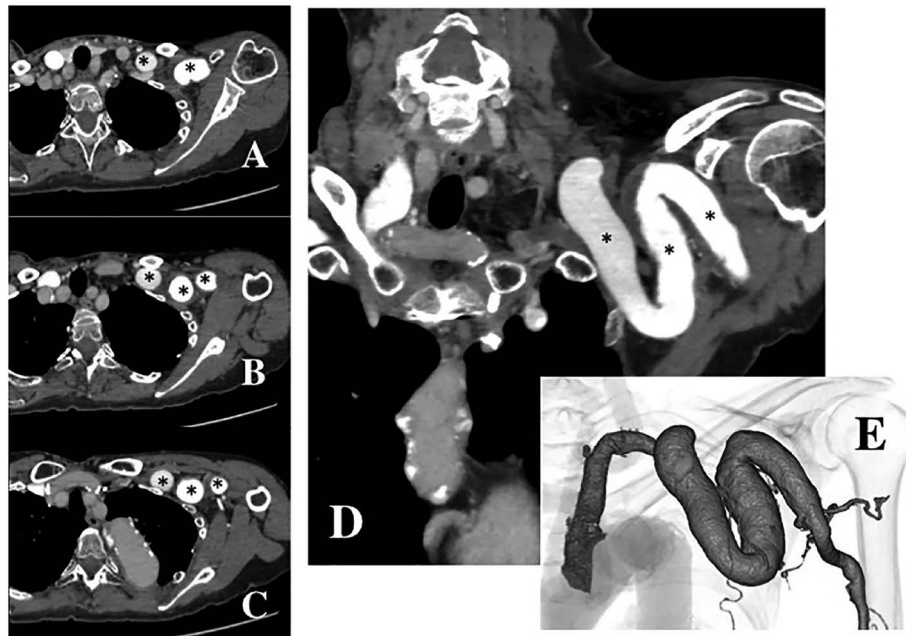
A 44-year-old female presented with numbness of the left upper limb and a pulsatile mass on the left chest at our outpatient service. She has been following up in our hospital since the age of 27 years when she underwent aortic root replacement for annuloaortic ectasia (AAE). Since then, she has been performed the aortic graft replacements for dissected aortic aneurysm total five times. A contrast-enhanced computed tomography (CT) scan revealed a highly tortuous left axillary aortic aneurysm (maximum diameter, 22 mm) (Fig. 1). We attributed the numbness to the compression of the brachial plexus due to the aneurysm. Accordingly, we performed an elective graft replacement with resection of the aneurysm to prevent aneurysmal rupture and thromboembolic events.

During the operation, the aneurysm was exposed through two skin incisions (Fig. 2). The first skin incision was 4 cm on the supraclavicular area along the left clavicle. We carefully dissected the surrounding tissues and approached the aneurysm by avoiding any injury to the brachial plexus and internal jugular vein. In addition, we performed taping of the proximal anastomotic site. The second incision was 8 cm on the infraclavicular area from the sternoclavicular joint to the anterior axillary line. The major and minor pectoral muscles were not transected, but were separated along the length of the muscle fibers. The taping of three sites of the aneurysm was performed for segmental aortic clamping (Fig. 3A). After intravenously injecting 5,000 IU heparin, we performed graft replacement using an expanded 6-mm polyester vascular prosthesis with external ring support after clamping of the proximal and distal arterial segments (Figs. 3B and 3C). We carefully located the vascular graft through the

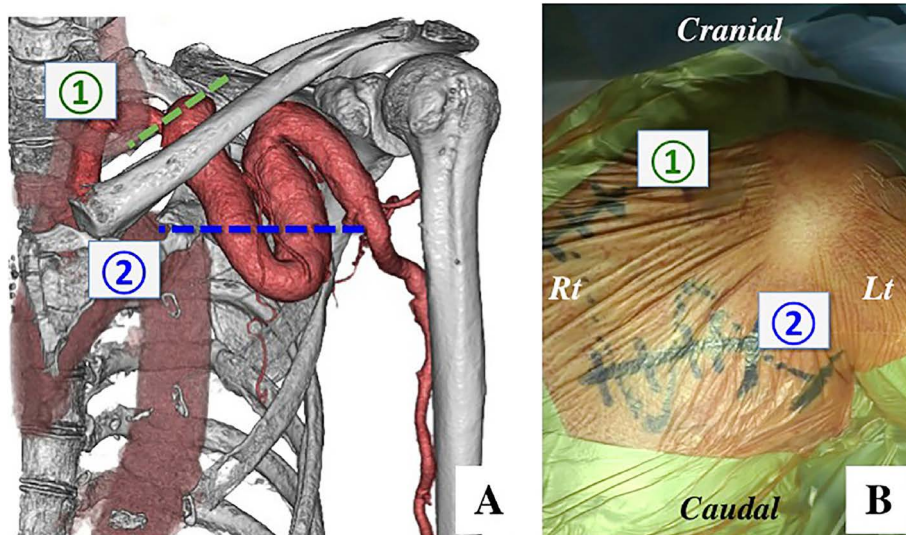
*Department of Cardiovascular Surgery, Hakodate Goryoukaku Hospital, Hakodate, Hokkaido, Japan*

Received: October 25, 2017; Accepted: December 15, 2017  
Corresponding author: Hiroshi Sato, MD, PhD. Department of Cardiovascular Surgery, Hakodate Goryoukaku Hospital, 38-3 Goryoukaku, Hakodate, Hokkaido 040-8611, Japan  
Tel: +81-138-51-2295, Fax: +81-11-613-7318  
E-mail: h.sato0229@gmail.com

 ©2018 The Editorial Committee of Annals of Vascular Diseases. This article is distributed under the terms of the Creative Commons Attribution License, which permits use, distribution, and reproduction in any medium, provided the credit of the original work, a link to the license, and indication of any change are properly given, and the original work is not used for commercial purposes. Remixed or transformed contributions must be distributed under the same license as the original.



**Fig. 1** Preoperative contrast-enhanced computed tomography (CT) scan, axial images (A), (B), and (C) and coronal image (D), demonstrated the left axillary aortic aneurysm, which was highly tortuous and enlarged to a diameter of 22 mm across the clavicle (\*). Arterial branches from the aneurysm were revealed on a 3D-CT scan (E).



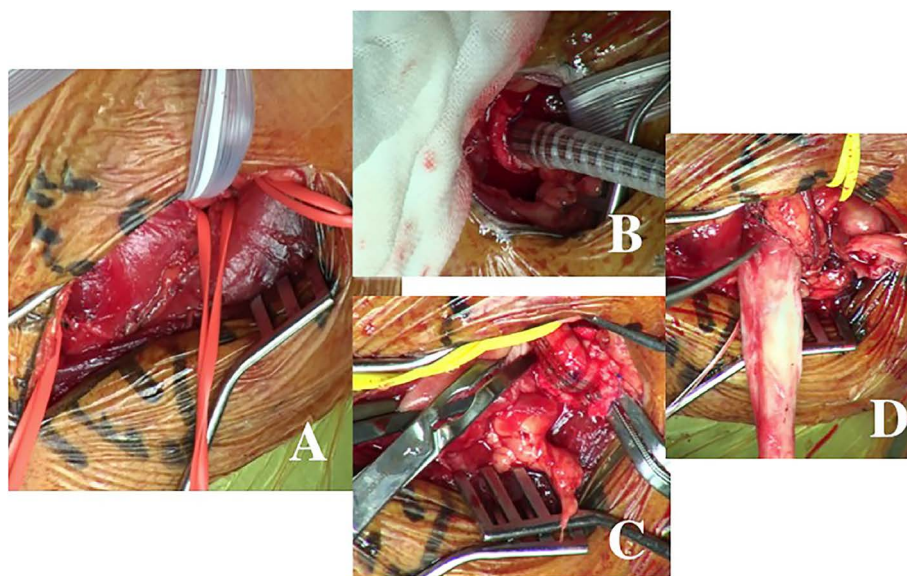
**Fig. 2** A preoperative 3D-CT scan illustrates the surrounding bones (A) and view of the operating field before the skin incision (B). The two images demonstrate the location of two skin incisions (①, ②). The 4-cm skin incision was made in the supraclavicular area along the clavicle (①). The 8-cm skin incision was made from the sternoclavicular joint to the anterior axillary line (②).

clavicle without touching the brachial plexus. Complete aneurysmal resection was performed after the ligation of branches from the aneurysm that were detected on a preoperative CT scan (Fig. 3D). After the operation, we confirmed the blood flow to the left upper and significant improvement in the numbness. A post-operative CT scan

revealed no problems at the reconstruction site.

## Discussion

Aneurysm of the axillary artery is a rare form of peripheral arterial aneurysm. To date, few case reports have pre-



**Fig. 3** Operative finding: the major and minor pectoral muscles were separated along the length of the muscle fibers, and the taping on three sites of the axillary arterial aneurysm was performed (A). Graft replacement was performed using an expanded 6-mm polyester vascular prosthesis with external ring support (B and C). Arterial branches from the aneurysm were ligated, adhesive tissues surrounding the aneurysm were dissected, and the aneurysm was excised entirely (D).

sented cases of the axillary aortic aneurysm in comparison with other peripheral arterial aneurysms. Reportedly, the incidence rate of axillary arterial aneurysms among all peripheral arterial aneurysms accounts for only 0.13%–0.50%.<sup>1)</sup> While the primary cause of the axillary arterial aneurysm is arteriosclerosis, other causes include thoracic outlet syndrome, infection, blunt trauma, and connective tissue disorders such as Marfan syndrome. In a review of cases of the axillary arterial aneurysm reported until 1995, arteriosclerosis was found to be the leading cause, comprising approximately 60% of all cases, followed by connective tissue disorders, including Marfan syndrome, which accounted for about 10%.<sup>2)</sup> Among patients with Marfan syndrome, about 6.3%–8.5% presented with an axillary arterial aneurysm.<sup>3)</sup> Furthermore, a bilateral axillary aneurysm with Marfan syndrome is even rarer, and few studies have reported such cases.<sup>4,5)</sup> Notably, our case did not exhibit an aneurysmal change in the right axillary artery, and the size of the artery was standard.

To date, surgical graft replacement with resection of an aneurysm has been the standard treatment of the axillary arterial aneurysm<sup>6,7)</sup>; this combination is the most preferred complete treatment option for the symptoms due to an enlarging aneurysm and prevention of rupture or arterial occlusion. However, the operative procedure must be carefully performed to prevent postoperative complications because of the vital organs, such as the brachial plexus, internal jugular vein, and major and minor pectoral muscles, surrounding the aneurysm. No-

tably, some cases require invasive procedures, such as an incision on the neck, resection of the clavicle or rib, or sternotomy, depending on the aneurysmal form.<sup>6)</sup> In our case, clavicular resection might have been necessary for a safe and effective operation because the aneurysm was located across the clavicle. However, as our patient was a relatively young woman, least possible invasive surgery was preferred for esthetic purposes and preventing pseudoarthrosis due to resection of the clavicle.<sup>7)</sup> Hence, we performed two skin incisions in the supraclavicular and infraclavicular areas, graft replacement, and complete aneurysmectomy without resection of the clavicle. In this approach, although the problem of dissecting the tissues just below the clavicle was imminent, complete aneurysmectomy, including the part below the clavicle, was accomplished because preoperative CT scan confirmed the absence of branches from the aneurysm below the clavicle. Furthermore, the major and minor pectoral muscles were not transected but only separated along the length of the muscle fibers. We accomplished least possible invasive surgery by planning the preoperative surgical strategy in conformity with the form and location of the aneurysm.

Some studies have reported the effectiveness of endovascular repair by a covered-stent or stent-graft for the axillary arterial aneurysm.<sup>8,9)</sup> Reportedly, endovascular treatment is less invasive compared to open surgery and has a low risk of complications caused by a surgical procedure. Hence, this therapy could be considered for patients with anatomical suitability for endovascular device

approach and deployment. However, the positive effects of endovascular repair on neurological symptoms are unknown, and the high risk of adverse events due to endovascular repair and endoleak at chronic phase have been reported in patients with Marfan syndrome.<sup>10)</sup> Hence, we believe that open surgical repair with resection of an aneurysm is a better treatment option than endovascular repair in patients with Marfan syndrome.

## Conclusion

This report highlights that vascular graft replacement and complete resection of an aneurysm in a patient with a left axillary arterial aneurysm with Marfan syndrome could be safely performed without complications using well-designed incisions. The severe need of sufficient operative field for open surgical repair of the axillary arterial aneurysm often depends on the degree of aneurysmal enlargement because of the vital organs surrounding the axillary artery. Hence, devising sufficient preoperative strategy, including the location of skin incisions or the need of resection of the clavicle, is imperative.

## Disclosure Statement

The authors declare no conflict of interest.

## Author Contributions

Writing: HS

Critical review and revision: all authors

Final approval of article: all authors

Accountability for all aspects of the work: all authors

## References

- 1) Dent TL, Lindenauer SM, Ernst CB, et al. Multiple arteriosclerotic arterial aneurysms. *Arch Surg* 1972; **105**: 338-44.
- 2) Dougherty MJ, Calligaro KD, Savarese RP, et al. Atherosclerotic aneurysm of the intrathoracic subclavian artery: a case report and review of the literature. *J Vasc Surg* 1995; **21**: 521-9.
- 3) Yetman AT, Roosevelt GE, Veit N, et al. Distal aortic and peripheral arterial aneurysms in patients with Marfan syndrome. *J Am Coll Cardiol* 2011; **58**: 2544-5.
- 4) Haruki T, Ito H, Sakata K, et al. Bilateral axillary artery aneurysms after Bentall procedure in Marfan syndrome. *Asian Cardiovasc Thorac Ann* 2015; **23**: 1072-4.
- 5) Igari K, Kudo T, Toyofuku T, et al. Bilateral axillary artery aneurysms presenting as upper limb ischemia. *Ann Vasc Surg* 2015; **29**: 1659.e9-12.
- 6) Pairolero PC, Walls JT, Payne WS, et al. Subclavian-axillary artery aneurysms. *Surgery* 1981; **90**: 757-63.
- 7) Tetik O, Yilik L, Besir Y, et al. Surgical treatment of axillary artery aneurysm. *Tex Heart Inst J* 2005; **32**: 186-8; discussion, 185.
- 8) He C, Wu X, Cao J, et al. Endovascular management of spontaneous axillary artery aneurysm: a case report and review of the literature. *J Med Case Rep* 2013; **7**: 140.
- 9) Park SK, Hwang JK, Park SC, et al. Endovascular treatment of a spontaneous aneurysm in the axillary artery. *Interact Cardiovasc Thorac Surg* 2015; **20**: 140-2.
- 10) Waterman AL, Feezor RJ, Lee WA, et al. Endovascular treatment of acute and chronic aortic pathology in patients with Marfan syndrome. *J Vasc Surg* 2012; **55**: 1234-40.