

Severe Abdominal Pain as a Presentation of Lead Poisoning: A Case Presentation

Wei Ge¹, Li-Hua Shao¹, Hai-Yan Gong², Gang Chen¹

¹Department of General Surgery, Nanjing Drum Tower Hospital, The Affiliated Hospital of Nanjing University Medical School, Nanjing, Jiangsu Province, 210008, People's Republic of China; ²Physical Examination Center, Nanjing Drum Tower Hospital, The Affiliated Hospital of Nanjing University Medical School, Nanjing, Jiangsu Province, 210008, People's Republic of China

Correspondence: Hai-Yan Gong, Physical Examination Center, Nanjing Drum Tower Hospital, The Affiliated Hospital of Nanjing University Medical School, Nanjing, Jiangsu Province, 210008, People's Republic of China, Email haiyangong666@126.com; Gang Chen, Department of General Surgery, Nanjing Drum Tower Hospital, The Affiliated Hospital of Nanjing University Medical School, Nanjing, Jiangsu Province, 210008, People's Republic of China, Email 331812195@qq.com

Background: Lead poisoning is a rare but serious disease. The clinical manifestations of lead poisoning are various and nonspecific, such as abdominal pain, headache, dizziness, nightmare, fatigue and so on. Rapid diagnosis of lead poisoning is challenging because it does not have special symptoms and the morbidity is very low.

Case Presentation: A 31-year-old woman presented with epigastric discomfort without any obvious cause. The patient was diagnosed with lead poisoning, as the blood levels of heavy metals were detected and the lead was 463.17 µg/L, which was very high (normal value was less than 100 µg/L). The patient was treated with intravenous drip of calcium sodium edentate and got better. The patient achieved good recovery and there was no recurrence.

Conclusion: Lead poisoning is a rare disease and easy to be misdiagnosed as acute abdomen disease when present with abdominal pain. Lead poisoning should be considered when common causes of abdominal pain are excluded, especially patients with anemia and abnormal liver function. The diagnosis of lead poisoning is mainly relied on the blood or urine lead concentrations. Then we should firstly cut off the contact with lead and use metal complexing agent to facilitate lead excretion.

Keywords: lead poisoning, abdominal pain, acute abdomen, calcium sodium edentate

Background

Lead poisoning is a rare but serious disease. The cause can be due to occupational or environmental exposure. Ingestion, inhalation, or dermal exposure to the lead contamination can cause poisoning.^{1,2} The clinical manifestations of lead poisoning are various and nonspecific, such as abdominal pain, headache, dizziness, nightmare, fatigue and so on.³ Lead poisoning acute abdomen can be misdiagnosed as an acute abdomen.⁴ Rapid diagnosis of lead poisoning is challenging because it does not have special symptoms and the morbidity is very low.⁵ This case presentation aims to provide information on epidemiology, clinical experience, diagnosis, and treatment of lead poisoning, with the objective of aiding the early diagnosis and treatment of lead poisoning. Written informed consent was obtained from the patient. This study was approved by the IRB of Nanjing Drum Tower Hospital, the affiliated hospital of Nanjing University Medical School.

Case Presentation

A 31-year-old woman felt epigastric discomfort without any obvious cause, along with gluttony, nausea and vomit on December 28, 2018. She went to hospital two days later and treated with acid-inhibitory drug. However, there was no improvement with the patient. She underwent a gastroscopy showing chronic gastritis on January 4, 2019 and taken omeprazole and domperidone. There was also no remission. On January 7, 2019, she felt tolerable abdominal pain without any treatment. Then she felt abdominal pain intensified along with anus stopping exhaust and defecate on the next day. The patient went to the emergency room and taken a series of examinations. Blood routine examination showed

leukocyte $7.4 \times 10^9/L$, neutrophil 80%, hemoglobin 94g/L. Routine urine test showed urine protein (++) , ketone body (+), and occult blood (-). Other examinations such as blood electrolytes, abdominal elevation film, and color Doppler ultrasound of liver, bile, pancreas, spleen, and urinary system were normal. The patient felt better after treated by analgesia.

The next day, severe abdominal pain attacked the patient again. On examination, the urine pregnancy experiment was negative and the abdominal computerized tomography (CT) scan was also normal. The abdomen was soft, and there was tenderness in hypogastrium without rebound pain and muscle tension. She was treated by enema and anti-infection with no anesis. A repeat blood routine examination showed leukocyte $9.9 \times 10^9/L$, neutrophil 84.2%, hemoglobin 102g/L. Liver function showed abnormal liver function (alanine transaminase [ALT] 401U/L, aspartate transaminase [AST] 77 U/L, total bilirubin [TB] 30.8umol/L, direct bilirubin [DB] 2.6 umol/L, indirect bilirubin [IB] 28.2 umol/L, glutamyl transpeptidase [GGT] 138 U/L). Routine urine test and gynecological sonography provided no positive result. As the patient's symptoms could not be improved and cause was unclear, she presented to the emergency department at our hospital on January 11, 2019.

When in our hospital, her abdominal pain was worse with anus stopping exhaust defecate. On examination, the vital signs were normal. The blood routine examination showed leukocyte $14.8 \times 10^9/L$, neutrophil 88.1%, hemoglobin 100g/L. The abdominal CT scan revealed intestinal obstruction and small amount of pelvic effusion (Figure 1A–C). The electrocardiography was sinus rhythm. A diagnosis of acute intestinal obstruction was made, and she was dealt with ambrosia, anti-inflammation, acid-inhibitory, spasmolysis, and analgesia. That evening, the abdominal pain was recurrent and markedly increased, and the peregoric, such as dezocine or tramadol hydrochloride could remit briefly. Later, imageological examination of superior mesenteric blood vessels reconstruction was made, which showed no abnormal

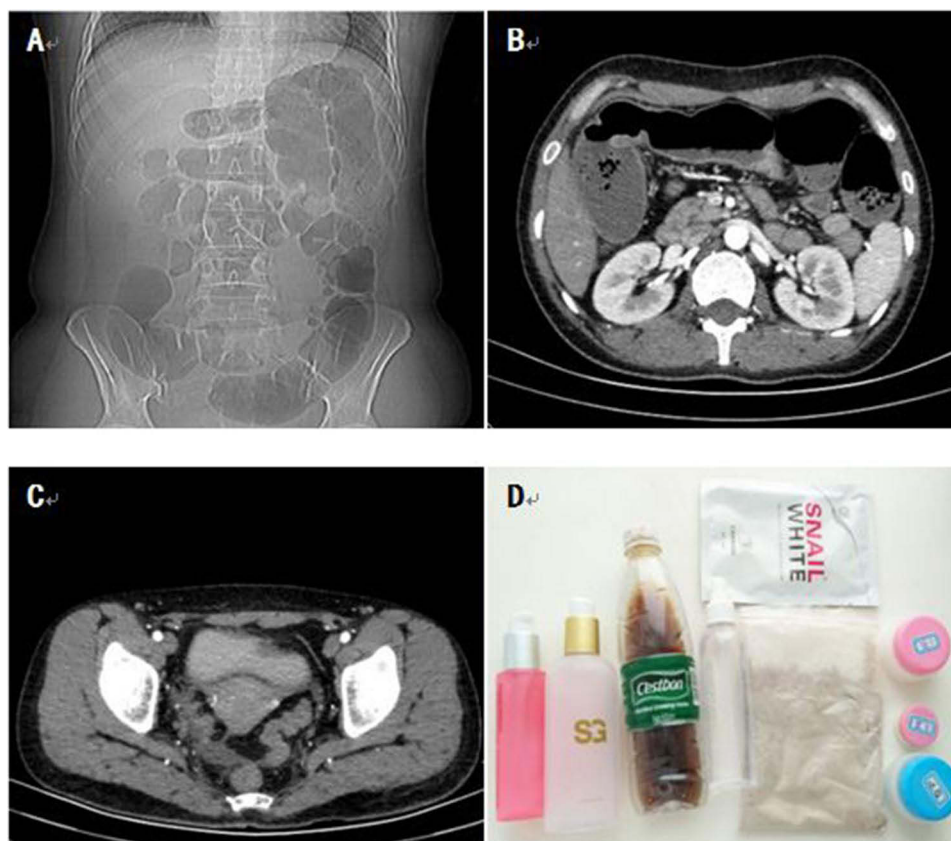


Figure 1 (A). The abdominal elevation film showed the colon and small intestine dilated with pneumatosis; (B). The small intestine was dilated effusion; (C). There was effusion in the pelvic cavity; (D). The cosmetic used by the patient was unbranded.

change in the blood vessels. The emergency department also could not get a definitive diagnosis, and the patient was transferred to colorectal surgery.

On examination, the temperature was 37.2°C, the blood pressure was 131/83mmHg, the pulse was 71/min, and breathe was 20/min. There was pressing pain in the hypogastrium and the bowel sound was weak; the remainder of the examination was normal. The primary diagnosis was intestinal obstruction and the patient was treated with fast, anti-infection, acid-inhibitory, inhibition of enzyme, spasmolysis, and nutrition support. Magnesium sulfate and racolamine hydrochloride could relieve the abdominal pain, while the dezocine could not.

On January 13, 2019, A repeat blood routine examination showed leukocyte $12.1 \times 10^9/L$, neutrophil 83.9%, hemoglobin 94g/L. Liver function showed abnormal liver function (ALT 181.2 U/L, AST 32 U/L, TB 23.3umol/L, DB 9.6 umol/L, GGT 138 U/L). The infectious disease indicators were all normal. Repeated severe abdominal pain attacked the patient today and magnesium sulfate helped her momentarily. The patient defecated today. Then she was treated with enema and taken for an electronic colonoscopy with nothing unusual.

Up to now, the course of the disease continued for 16 days without a definite diagnosis. The common causes of acute abdominal diseases, such as gastrointestinal perforation, acute cholecystitis, acute pancreatitis, gynecological disease, and urologic diseases were all excluded. A series of test results mentioned above showed anemia and abnormal liver function. So we should consider the rare cause of abdominal pains, such as Porphyria, abdominal epilepsy, herpes zoster, heavy metal poisoning, and so on. We have made the physical examination carefully and found no herpes, so the herpes zoster was excluded. The electroencephalogram was normal and the abdominal epilepsy was not considered. Then, we took the patient's urine and place it in the sun for an hour without color change. So the Porphyria was also excluded. Blood levels of heavy metals were detected and the lead was 463.17 $\mu\text{g/L}$, which was very high (normal value was less than 100 $\mu\text{g/L}$). Therefore, the diagnosis of lead poisoning was made.

The patient was treated with intravenous drip of calcium sodium edentate. The frequency of abdominal pain decreased gradually. She felt pain once a day on January 15 and 16. Later, she felt comfortable and resumed eating. Test results indicated an improvement in liver function. A week later, the blood level of lead dropped to 443.79 $\mu\text{g/L}$. According to the treatment guidelines, she should continue to receive intravenous drip of calcium sodium edentate.

In addition, we have also paid attention to the source of lead poisoning. Combing the common causes of lead poisoning and living habit of the patient, we focused on a set of cosmetics without trademark (Figure 1D). She have used the cosmetics for more than half a year and got a very good whitening effect. We test the lead content of this cosmetic and found that the lead concentration was 65.3mg/kg, which was higher than the national safety standard significantly. Therefore, we thought this set of cosmetics was the cause of lead poisoning. She stopped using this set of cosmetics immediately.

Discussion and Conclusions

Lead is an electropositive heavy metal that can affect various organ systems in humans including the peripheral and central nervous system, the gastrointestinal tract, joints, muscles, kidneys, and the hemopoetic system.⁶ Lead can cause acute and chronic poisoning in human. Acute lead poisoning is related with occupational environment and the incidence has declined. However, the chronic lead poisoning still exists and difficult to diagnose. The causes of lead poisoning were various. Lead is mainly inhaled through the respiratory tract in the form of dust, smoke or vapour. The second is through the digestive tract into the human body and part of the organic compounds, such as lead tetraethyl can be absorbed through the skin.⁷⁻¹⁰ In this presentation, the patient was chronic lead poisoning and the chief culprit was the cosmetics. The lead was absorbed through the skin and led to chronic lead poisoning.

The clinical manifestations are various without specificity. Mild symptoms are such as headache, dizziness, nightmare, fatigue, poor appetite, abdominal pain, diarrhea, nausea, vomit, joint pain, and so on. Severe symptoms are life-threatening, such as drop in blood pressure, hallucinations, delusions, irritability, delirium, systemic convulsions and even pupil dilation, loss of consciousness and so on. Sometimes abdominal pain was the main symptom and could be misdiagnosed as an acute abdominal disease.^{5,11} In this case, the manifestations were severe abdominal pain and intestinal obstruction. The nature of the pain was colic and the antispasmodic was effective. There were no life-threatening symptoms present in this patient and the diagnosis was timely.

The diagnosis of lead poisoning is mainly relied on blood or urine lead concentrations.^{12,13} According to the standard of diagnosis, when blood lead concentration is more than 1.2 umol/L or urine lead concentration is more than 0.39 umol/L, the diagnosis of lead poisoning could be made. The blood lead concentration was 463.17 µg/L (2.24 umol/L), so the diagnosis of lead poisoning was exactly. The differential diagnosis is important and necessary.¹⁴ Acute abdominal pain has a broad differential diagnosis that includes diseases of multiple systems. First of all, we should exclude the common digestive causes of acute abdominal pain. Common causes of acute abdominal pains, such as appendicitis, diverticulitis, cholecystitis, pancreatitis, gastrointestinal perforation, indigestion, volvulus and so on can be ruled out by the imaging and laboratory findings in this case. Gastritis and gastric ulcer have been considered but were not confirmed on a gastroscopy examination. Viral or drug-induced hepatitis were also suspected as the transaminase and GGT were elevated, but it was not consistent with the epidemiological examination and medication history.

Secondly, non-digestive causes of acute abdominal pain should also be ruled out. For example, gynecological diseases, such as dysmenorrhea, shift the pregnancy, rupture of corpus luteum, twisted testicular appendages and so on should be considered. The patient has taken gynecological sonography, gynecologic examination, and pregnancy tests and nothing abnormal was detected. Then, urologic diseases, such as urinary calculus, tumor and renal colic should also be excluded. The patient has also taken color Doppler ultrasound of urinary system without positive findings, besides the characteristics of the pain was not compatible with renal colic. At last, some rare conditions that cause abdominal pains, such as porphyria, abdominal epilepsy, herpes zoster, acute myocardial infarction and so on should be excluded. For Porphyria, the urine turns red after exposure, acidification and heated, we took the patient's urine and place it in the sun for an hour without color change. So the porphyria was excluded. For abdominal epilepsy, electroencephalogram showed paroxysmal slower wave activity, accompanied by epileptic discharge. However, the electroencephalogram of this patient was normal. The electrocardiogram was normal, so that the acute myocardial infarction was excluded. Besides, we have made the physical examination carefully and found no herpes, so the herpes zoster was also unconsidered.

We should firstly cut off the contact with lead and use metal complexing agent to facilitate lead excretion when the diagnosis of lead poisoning was made. Commonly used drugs are disodium edetate, dimercaptophosphate, dimercaptophosphate, calcium edetate sodium, diethylenetriamine pentaacetic acid trisodium calcium, thiol complex agent, thiamine, penicillamine and so on.¹⁵⁻¹⁸ Spasmolytic could ease the pain when patient felt abdominal pain. Besides, glucocorticoids were used early, moderately, and briefly could promote the decline of blood lead. In this case, the patient was treated with sodium calcium edetate and dexamethasone and the symptoms improve quickly. After professional testing, we determined that her cosmetic with no brand was the cause of her lead poisoning. She stopped using the cosmetic immediately. Up to now, the patient has been followed up for more than 3 years without abdominal pain and the biomonitoring blood lead levels were normal. So the female should choose cosmetics carefully to keep healthy.

Lead poisoning is a rare disease and easy to misdiagnose as acute abdomen when present with abdominal pain. Lead poisoning should be considered when common causes of abdominal pain are excluded, especially for patients with anemia and abnormal liver function. The diagnosis of lead poisoning is mainly relied on the blood or urine lead concentrations. We should firstly cut off the contact with lead and use metal complexing agent to facilitate lead excretion when the diagnosis of lead poisoning is made.

Data Sharing Statement

All data generated or analyzed during this study are included in this published article.

Ethics Approval and Consent to Participate

Written informed consent was provided by this patient, and this study was approved by the IRB of Nanjing Drum Tower Hospital, the affiliated hospital of Nanjing University Medical School.

Consent for Publication

The publication of the paper has been approved by all authors.

Acknowledgments

We thank the patient for giving us written consent for publishing her details.

Funding

This paper was funded by the National Natural Science Foundation of China (021414380047).

Disclosure

The authors declare that they have no competing interests in this work.

References

1. Dignam T, Kaufmann RB, LeSturgeon L, Brown MJ. Control of lead sources in the United States, 1970–2017: public health progress and current challenges to eliminating lead exposure. *J Public Health Manag Pract.* 2019;25:S13–S22. doi:10.1097/PHH.0000000000000889
2. Huang R, Ning H, Baum CR, Chen L, Hsiao A. “What do you know?”—knowledge among village doctors of lead poisoning in children in rural China. *BMC Public Health.* 2017;17(1):895. doi:10.1186/s12889-017-4895-2
3. Miracle VA. Lead poisoning in children and adults. *Dimens Crit Care Nurs.* 2017;36(1):71–73. doi:10.1097/DCC.0000000000000227
4. Mehta V, Midha V, Mahajan R, et al. Lead intoxication due to ayurvedic medications as a cause of abdominal pain in adults. *Clin Toxicol.* 2017;55(2):97–101. doi:10.1080/15563650.2016.1259474
5. Christiansen D, Christiansen AL, Ebbehoj NE. [Acute abdominal pain caused by lead poisoning]. *Ugeskr Laeger.* 2019;181:11. Danish.
6. Papanikolaou NC, Hatzidaki EG, Belivanis S, Tzanakakis GN, Tsatsakis AM. Lead toxicity update. *A Brief Review Med Sci Monit.* 2005;11(10):RA329–336.
7. Homan CS, Brogan GX, Orava RS. Lead toxicity. In: Viccellio P, editor. *Emergency Toxicology.* 2nd ed. Philadelphia, PA: Lippincott-Raven; 1998:363–379.
8. Chen L, Zhao QN, Qian XR, et al. Association between the HOTAIR polymorphism and susceptibility to lead poisoning in a Chinese population. *Biomed Environ Sci.* 2018;31(6):473–478. doi:10.3967/bes2018.063
9. Ahamed M, Verma S, Kumar A, Siddiqui MK. Environmental exposure to lead and its correlation with biochemical indices in children. *Sci Total Environ.* 2005;346(1–3):48–55. doi:10.1016/j.scitotenv.2004.12.019
10. Fischbein A, Hu H. Occupational and environmental exposure to lead. In: Rom WM, Markowitz SB, editors. *Environmental and Occupational Medicine.* Philadelphia: Lippincott Williams & Wilkins; 2007:954–990.
11. Froutan H, Kashefi Zadeh A, Kalani M, Andrabai Y. Lead toxicity: a probable cause of abdominal pain in drug abusers. *Med J Islam Repub Iran.* 2011;25:16–20.
12. Recasens V, Montanes A, Bustamante E. Lead poisoning as final diagnosis in a study of normocytic anemia. *Int J Hematol.* 2019;109(2):135–136. doi:10.1007/s12185-018-02570-1
13. Centers for Disease Control and Prevention. Adult blood lead epidemiology and surveillance—United States, 2008–2009. *MMWR Morb Mortal Wkly Rep.* 2011;60(25):841–845.
14. Friedman LS, Simmons LH, Goldman RH, Sohani AR. Case records of the Massachusetts general hospital. Case 12–2014. A 59-year-old man with fatigue, abdominal pain, anemia, and abnormal liver function. *N Engl J Med.* 2014;370(16):1542–1550. doi:10.1056/NEJMcpc1314242
15. Gracia RC, Snodgrass WR. Lead toxicity and chelation therapy. *Am J Health Syst Pharm.* 2007;64(1):45–53. doi:10.2146/ajhp060175
16. Kim HC, Jang TW, Chae HJ, et al. Evaluation and management of lead exposure. *Ann Occup Environ Med.* 2015;27:30.
17. Abelsohn AR, Sanborn M. Lead and children: clinical management for family physicians. *Can Fam Physician.* 2010;56(6):531–535.
18. Mottier DM, Cargnel E. [Abdominal pain as a presentation by lead poisoning. Case report]. *Arch Argent Pediatr.* 2017;115(2):e96–e98. Spanish. doi:10.5546/aap.2017.e96

International Medical Case Reports Journal

Dovepress

Publish your work in this journal

The International Medical Case Reports Journal is an international, peer-reviewed open-access journal publishing original case reports from all medical specialties. Previously unpublished medical posters are also accepted relating to any area of clinical or preclinical science. Submissions should not normally exceed 2,000 words or 4 published pages including figures, diagrams and references. The manuscript management system is completely online and includes a very quick and fair peer-review system, which is all easy to use. Visit <http://www.dovepress.com/testimonials.php> to read real quotes from published authors.

Submit your manuscript here: <https://www.dovepress.com/international-medical-case-reports-journal-journal>