

Mini Review Article

Headache in patients with Paget's Disease of Bones

Gerasimos Evangelatos, Alexios Iliopoulos

Rheumatology Department, 417 Army Share Found Hospital (NIMTS), Athens, Greece

All published work is licensed under Creative Common License CC BY-NC-SA 4.0 (Attribution-NonCommercial-ShareAlike)

Abstract

Paget's disease of bone (PDB) is a focal remodeling disorder of unknown origin. Head bones are frequently involved and patients may suffer from deformities and specific symptoms, mainly headache, or neurological deficits, such as deafness. Several pathophysiological entities can give rise to headache in PDB patients. Clinical, laboratory, radiological and scintigraphic findings contribute to distinguish headache related to PDB from other causes of headache. Up to the present, treatment with intravenous zoledronic acid has been reported to improve symptoms of PDB and induce long-standing biochemical and scintigraphic remission. In this review, the main strands of literature about epidemiology, pathophysiology, clinical characteristics and treatment of PDB-related headache are drawn together.

Keywords: Denosumab, Headache, Paget's disease of bones, Zoledronic acid

Introduction

Paget's disease of bone or *osteitis deformans* affects 1-2% of people over 55 years, mainly men of white race, with higher prevalence in certain countries¹. It is still debatable in the literature if paramyxoviruses (particularly measles and canine distemper) infection in childhood is the cause of PDB and, thus, the extensive vaccination against measles led to the decline of the disease's prevalence over the last decades². Furthermore, several studies indicate mutations in the *SQSTM1* gene as a predisposing genetic factor in some patients³.

PDB affects more than one bone (polyostotic form) in most cases. Patients with limited disease are usually asymptomatic. Nevertheless, patients can experience several symptoms depending on the site of the deformity. Skull and jaw involvement are present in 28% and 17% of cases respectively, with slightly higher incidence in Asian patients^{4,5}, while PDB in facial bones is uncommon.

Pathophysiology - Clinical Manifestations

The main disorder in pagetic bone is localized acceleration of bone remodeling, characterized by upregulation of both osteoclast and osteoblast activity⁶, resulting in the formation of enlarged bone with disordered architecture.

Neurological complications occur in the majority (up to 76%) of PDB cases anytime in the course of the disease⁷ and may be related to either the central or the peripheral nervous system. These complications are possibly result

of mechanical compression or reduced blood flow of neural tissue⁸. Head involvement of PDB may lead to various types of headache, hearing loss, or other cranial nerves deficits, hyperemia of skull and basilar invagination and its consequences. Headache in PDB patients is characterized as severe, mostly occipital, deteriorating when intracranial pressure increases, as in the case of coughing⁹.

A cornerstone of PDB pathophysiology is the enhanced vascularization of affected bones¹⁰, which may cause a regional vascular steal syndrome. Vertebrobasilar insufficiency syndrome might be a consequence of diversion of blood flow from the spinal arteries to the pagetic bone¹¹, igniting symptoms such as headache and dizziness. Cranial enlargement in some PDB patients leads to lethargy, and sometimes headache, due to blood shunting from brain vessels to the external carotid and temporal artery^{12,13}.

Skull base involvement causing platybasia and basilar invagination presents as posterior head pain. This malformation may lead to hydrocephalus, resulting in headache, dizziness and progressive dementia, but can also

The authors have no conflict of interest.

Corresponding author: Evangelatos Gerasimos, Monis Petraki
10-12, GR115-21

E-mail: gerevag@gmail.com

Edited by: George Lyritis

Accepted 10 May 2017

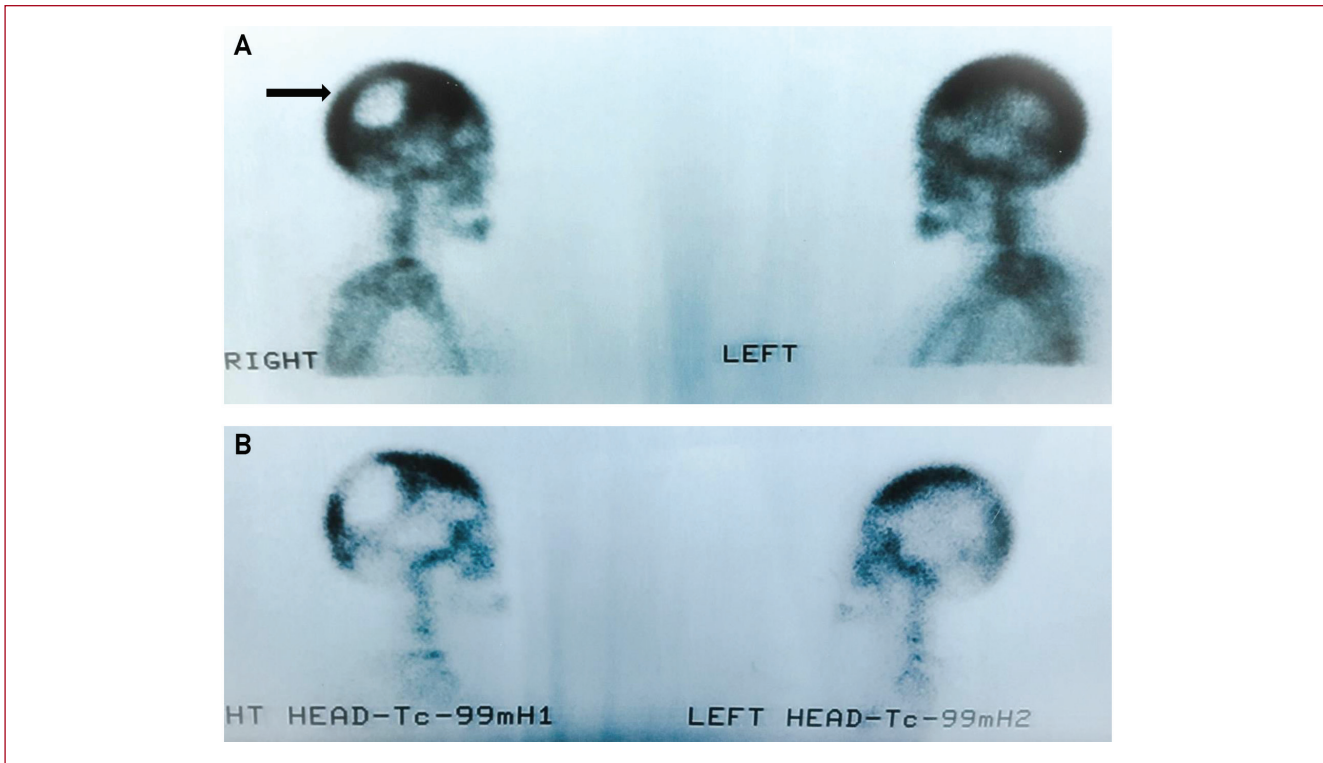


Figure 1. A 76-year-old female patient presented with severe headache at the neurosurgery department and underwent a surgical excision of a skull lesion misdiagnosed as a eosinophilic granuloma (arrow). Biopsy findings, SAP levels elevation and a later bone scan (A) established the diagnosis of PDB. Treatment with a single dose of i.v. 5 mg of zoledronic acid resulted in relief of headache and in significant biochemical and scintigraphic response 4 months later (B). (From archive of Rheumatology Department, 417 Army Share Found Hospital (NIMTS), Athens, Greece).

give rise, eventually, to brainstem compression⁹. Finally, Paget's disease of the cervical spine is uncommon and rarely generates radicular pain¹⁴.

The pagetic bone expansion can lead to cranial nerves compression. Involvement of V (Trigeminal) or VI (Abducens) nerves provokes trigeminal neuralgia and diplopia - paresthesia - unilateral hemifacial pain, respectively. If facial bones such as maxilla and mandible are affected, this will result in facial deformity and dental problems that trigger headache¹⁵. In some advanced cases, the overwhelming weight of an abnormal skull may disturb head stabilization and cause occipital headache, due to prolonged spasm of neck muscles¹⁶.

Pagetic bone is fragile and, therefore, related to pathologic fracture which is painful and in the case of the skull can cause headache. More often, bone pain is generated by micro-cracks or microfractures which, however, rarely lead to clinical fractures just as pathophysiology of pagetic lesion results in enhanced plasticity of affected bones¹⁷.

Headache in patients with PDB could also be a treatment related side-effect. Patients treated with intravenous bisphosphonates commonly experience a flu-like syndrome 24-48 hours after injection, which can cause headache.

Headache lasting for several days is not a rare complication of bisphosphonate treatment. Osteonecrosis of jaw (ONJ), due to bisphosphonate use for treatment of PDB could be a rare cause of headache. The prevalence of bisphosphonate-related ONJ may be reduced in PDB patients in comparison to their use in osteoporotic population, because of the significantly shorter duration of the therapy^{18,19}. Nevertheless, several cases of ONJ have been reported in PDB patients²⁰.

Approach considerations

Headache is not frequently the first manifestation of PDB. Headache as the first symptom has been reported at 0.9% of all PDB patients and at 1.6% of the symptomatic population²¹, but the exact incidence at long-term course of the disease is still unknown⁹. Symptomatic patients usually have more pelvic or spine involvement, than skull or facial lesions²². Isolated focal involvement of the skull bones in PDB can be misdiagnosed as local bone tumor (Figure 1). On the other hand, the majority of PDB patients, which are usually elderly people, have comorbidities that make every new symptom - for example, headache or lumbar back pain -

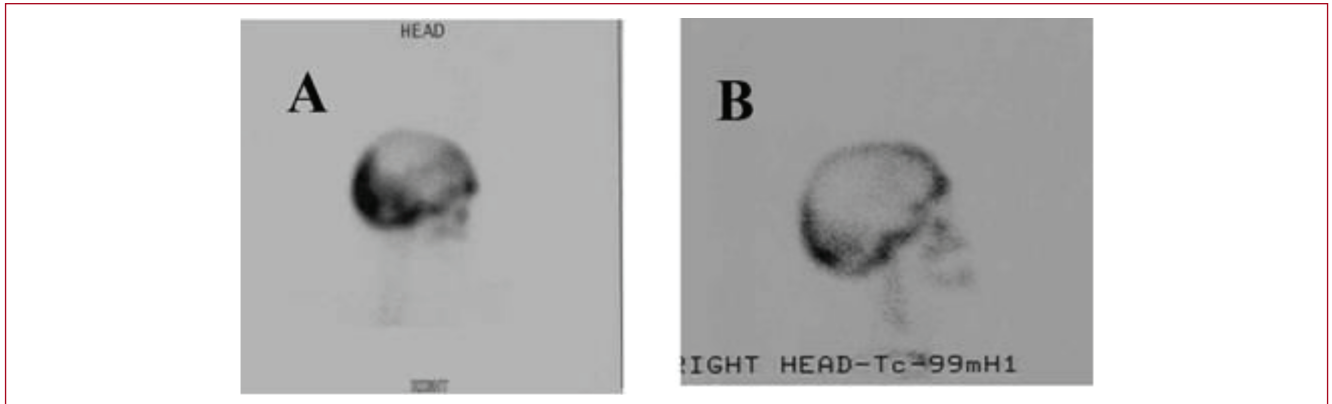


Figure 2. A 59-year-old male patient with PDB which diagnosed in the workout for persistent headache. The bone scanning before (A) treatment revealed skull lesions, which decreased significantly after a single 5 mg i.v. infusion of zoledronic acid (B). The patient still remains free of headache and with normal SAP level, 5 years after treatment. (From archive of Rheumatology Department, 417 Army Share Found Hospital (NIMTS), Athens, Greece).

a challenge for the physicians. In this population, a new onset of headache could have a broad spectrum of underlying causes, such as, a simple upregulation of blood pressure. A persistent headache in patients with history of PDB always needs to be evaluated for complications of the disease. On this basis, blood tests, skull x-rays, computed tomography, magnetic resonance imaging, and bone scintigraphy can contribute to differential diagnosis.

Clinical examination plays the major role, as signs of PDB may be obvious, for example increased local temperature, skull veins dilation, skull or face deformities, neck muscles tension, facial palsy or sensory disturbances. Elevated serum alkaline phosphatase (SAP) levels are connected to polyostotic disease²¹ and, thus, make head involvement more possible. Patients with PDB of skull have been reported to have higher baseline bone turnover markers²². Moreover, SAP (especially the bone isoenzyme) levels elevation may indicate a disease relapse, especially when SAP levels at 6 months after treatment exceed the middle of reference range, even if remain below the maximum normal value³. As for other markers, plasma procollagen-1 N-peptide (P1NP) levels have more specificity and can be used for monitoring on strong clinical suspicion especially when SAP levels are normal²³.

Every patient susceptible to PDB-related headache should undergo scintigraphy as it may reveal new or relapsed pagetic bone lesions. Although plain radiographs may also help, headache and hearing loss are less correlated with radiographic findings than other complications of PDB²⁴. Furthermore, patients with positive bone scanning and normal x-rays over 70% were symptomatic²⁵. In some cases, PET-CT scan can help as scintigraphy does, besides demonstrating disease activity before and after treatment²⁶.

Physicians should be alert for malignant transformation to osteosarcoma, a tumor with very poor prognosis²⁷, which

is, fortunately, rare (<1%) nowadays in PDB patients²⁸. Osteosarcoma rarely affects skull²⁷, but can provoke headache⁹. Even less common in PDB patients but mainly distributed in the skull and facial bones are painless benign giant cell tumors^{29,30}.

Treatment options

Recent guidelines have established a single-dose of intravenous (i.v.) zoledronic acid as the first line treatment for active PDB³¹. This treatment results in prolonged biochemical remission³² and improvement of the quality of life^{33,34}. Additionally, it can be re-administered at disease relapses, without development of drug resistance³⁴, as have been reported in treatment with other bisphosphonates. Oral bisphosphonates offer less clinical benefit over pain and quality of life, compared to iv zoledronic acid³³. There is no strong bibliographical evidence that bisphosphonates contribute to elimination of PDB - related headache. Nevertheless, the control of bone turnover with amino bisphosphonates, which is reflected upon bone turnover markers suppression, may confine symptoms, such as pain. Headache completely resolved in two cases of PDB treated with a single infusion of zoledronic acid in our department (Figures 1, 2). Several data from case reports or case series indicate that neurological complications ameliorate after treatment with bisphosphonates⁸ or calcitonin³⁵. Treatment with calcitonin has more side effects, significantly less efficacy and response duration, as well as greater possibility for drug resistance comparing to bisphosphonates³⁶. Nowadays, calcitonin is only considered as an alternative therapy in patients who cannot tolerate bisphosphonates and is used mainly in patients with eGFR less than 30 ml/min. Cases of patients treated effectively with denosumab showing a short-term decline in headache severity have also

been reported³⁷. Patients with skull involvement tend to show less biochemical response to treatment²².

In clinical practice, paracetamol and nonsteroidal anti-inflammatory drugs (NSAIDs) are used as symptomatic treatment for mild or intermittent pain³⁸. A clinical trial with a large cohort of 1324 PDB patients compared intensive bisphosphonate treatment to symptomatic treatment with analgesics or NSAIDs followed by bisphosphonates for non-responders, with a mean time of follow up of 3 years³⁹. The patients of both groups showed similar symptom response, fracture rate and quality of life. Nevertheless, the methodology and study design are questionable, while no patient received i.v. zoledronic acid. Carbamazepine has been used for trigeminal neuralgia, hemifacial spasm and neuropathic pain generally⁴⁰. Before surgery (especially neurosurgery) bisphosphonates are commonly used to diminish bone vascularity and, as a result, intra-operating bleeding³.

Conclusion

Headache, although it is not a common symptom of PDB patients, may affect their quality of life and reveal a disease complication. On this basis, headache should be a "red flag" symptom for skull involvement, especially for patients with concomitant neurologic symptoms and signs. On the other hand, patients should be evaluated under scrutiny because several other conditions can provoke headache in a PDB patient. Despite the insufficient data, treatment with zoledronic acid seems to diminish the severity of the PDB-related headache through targeting the underlying pathology, with denosumab as an alternative treatment, when bisphosphonates are contraindicated.

References

- Shaker JL. Paget's Disease of Bone: A Review of Epidemiology, Pathophysiology and Management. *Ther Adv Musculoskel Dis* 2009; 1(2):107-125.
- Poór G, Donáth J, Fomet B, Cooper C. Epidemiology of Paget's disease in Europe: the prevalence is decreasing. *J Bone Miner Res* 2006;21:1545-1549.
- Bolland MJ, Cundy TJ. Paget's disease of bone: clinical review and update. *Clin Pathol* 2013;66:924-927.
- Umamaheswari G, Pangarikar AB, Urade VB, Parab PG. Management of craniofacial osteitis deformans. *Ann Maxillofac Surg* 2014;4:243-6.
- Wang WC, Cheng YS, Chen CH, Lin YJ, Chen YK, et al. Paget's disease of bone in a Chinese patient: A case report and review of the literature. *Oral Surg Oral Med Oral Pathol Oral Radiol Endod* 2005; 99(6):727-733.
- Galson DL, Roodman GD. Pathobiology of Paget's disease. *J Bone Miner Res* 2014;29:85-98.
- Daniel Rubin, Robert Levin. Neurologic Complications of Paget Disease of Bone. *Endocr Pract* 2009;15(2):158-166.
- Poncelet A. The neurologic complications of Paget's disease. *J Bone Miner Res* 1999;14(2):88-91.
- McCloskey EV, Kanis JA. Neurological Complications of Paget's Disease. *Clin Rev Bone Miner Metab* 2002;1(2):135-143.
- Wootton R, Reeve J, Spellacy E, Tellez-Yudilevich M. Skeletal blood flow in Paget's disease of bone and its response to calcitonin therapy. *Clin Sci Mol Med* 1978;54(1):69-74.
- Douglas DL, Duckworth T, Kanis JA, Jefferson AA, Martin TJ, et al. Spinal cord dysfunction in Paget's disease of bone. Has medical treatment a vascular basis? *J Bone Joint Surg Br* 1981;4:495-503.
- Blotman F, Blard JM, Labauge R, Simon L. Ultrasonic study of the brain circulation in patients with Paget's disease. Preliminary results. *Rev Rhum Mal Osteoartic* 1975;42:647-651.
- Ibbertson HK, Henley JW, Fraser TR, Tait B, Stephens EJ, et al. Paget's disease of bone - clinical evaluation and treatment with diphosphonates. *Aust NZ J Med* 1979;9:31-35.
- Altman RD. Musculoskeletal manifestations of Paget's disease of bone. *Arthritis Rheum* 1980;23:1121-1127.
- Smith BJ, Eveson JW. Paget's disease of bone with particular reference to dentistry. *J Oral Pathol* 1981;10:233-247.
- Singer F. Paget's Disease of Bone. [Updated 2016 Jan 8]. In: De Groot LJ, Chrousos G, Dungan K, et al, editors. *Endotext* [Internet]. South Dartmouth (MA): MDText.com, Inc.; 2000-.
- Zimmermann EA, Köhne T, Bale HA, Panganiban B, Gludovatz B et al. Modifications to nano- and microstructural quality and the effects on mechanical integrity in Paget's disease of bone. *J Bone Miner Res* 2015;30(2):264-73
- Bolland M, Hay D, Grey A, Reid I, Cundy T. Osteonecrosis of the jaw and bisphosphonates--putting the risk in perspective. *N Z Med J* 2006;119(1246):72-77.
- Seton M, Krane SM. Use of zoledronic acid in the treatment of Paget's disease. *Ther Clin Risk Manag* 2007;3(5):913-918.
- Hess LM, Jeter JM, Benham-Hutchins M, Alberts DS. Factors associated with osteonecrosis of the jaw among bisphosphonate users. *Am J Med* 2008;121(6):475-483.
- Varenna M, Zucchi F, Galli L, Manara M, DeMarco G, et al. Demographic and Clinical Features Related to a Symptomatic Onset of Paget's Disease of Bone. *J Rheumatol* 2010;37(1):155-160.
- Peris P, Alvarez L, Vidal S, Kasper D, Leeming DJ, et al. Biochemical response to bisphosphonate therapy in pagetic patients with skull involvement. *Calcif Tissue Int* 2006;79(1):22-6.
- Al Nofal AA, Altayar O, BenKhadra K, Qasim Agha OQ, Asi N, et I. Bone turnover markers in Paget's disease of the bone: A Systematic review and meta-analysis. *Osteoporos Int* 2015;26:1875.
- Seton M, Moses AM, Bode RK, Schwartz C. Paget's disease of bone: the skeletal distribution, complications and quality of life as perceived by patients. *Bone* 2011;48(2):281-5.
- Smith SE, Murphey MD, Motamedi K, Mulligan ME, Resnik CS, et al. From the archives of the AFIP. Radiologic spectrum of Paget disease of bone and its complications with pathological correlation. *Radiographics* 2002;22:1191-216.
- Radhesh Krishna Lalam, Victor N. Cassar-Pullicino, Naomi Winn. Paget Disease of Bone. *Semin Musculoskelet Radiol* 2016;20(03):287-299.
- Shaylor PJ, Peake D, Grimer RJ, Carter SR, Tillman RM, et al. Paget's Osteosarcoma - no Cure in Sight. *Sarcoma* 1999;3(3-4):191-192.
- Mangham DC, Davie MW, Grimer RJ. Sarcoma arising in Paget's disease of bone: Declining incidence and increasing age at presentation. *Bone* 2009;44(3):431-436.
- Jacobs TP, Michelsen J, Polay JS, D'Adamo AC, Canfield RE. Giant cell tumor in Paget's disease of bone: familial and geographic clustering. *Cancer* 1979;44:742-747.
- Nuzzo V, Ferrara T, Zuccoli A, et al. Infiltrating giant cell tumor in a case of Paget's disease of bone. *Arch Osteoporos* 2009;4:91-94.
- Singer FR, Bone HG 3rd, Hosking DJ, Lyles KW, Murad MH, et

- al; Endocrine Society. Paget's Disease of Bone: An Endocrine Society Clinical Practice Guideline. *J Clin Endocrinol Metab* 2014; 99(12):4408-4422.
32. Reid IR, Lyles K, Su G, Brown JP, Walsh JP, et al. A single infusion of zoledronic acid produces sustained remissions in Paget disease: data to 6.5 years. *J Bone Miner Res* 2011;26(9):2261-70.
 33. Reid IR, Miller P, Lyles K, Fraser W, Brown JP, et al. Comparison of a Single Infusion of Zoledronic Acid with Risedronate for Paget's Disease. *N Engl J Med* 2005;353:898-908.
 34. Reid IR, Brown JP, Levitt N, Ivorra JAR, Bachiller-Corral J, et al. Retreatment of relapsed Paget's disease of bone with zoledronic acid: results from an open-label study. *Bonekey Rep* 2013;2:442.
 35. Chen JR, Rhee RS, Wallach S, Avramides A, Flores A. Neurologic disturbances in Paget disease of bone: response to calcitonin. *Neurology* 1979;29(4):448-57.
 36. Langston AL, Ralston SH. Management of Paget's disease of bone. *Rheumatology* 2004;43:955-9.
 37. Reid IR, Sharma S, Kalluru R, Eagleton C. Treatment of Paget's Disease of Bone with Denosumab: Case Report and Literature Review. *Calcif Tissue Int* 2016;99:322.
 38. Vallet M, Ralston SH. Biology and Treatment of Paget's Disease of Bone. *J Cell Biochem* 2016;117(2):289-99.
 39. Langston AL, Campbell MK, Fraser WD, MacLennan GS, Selby PL, et al. Randomized trial of intensive bisphosphonate treatment versus symptomatic management in paget's disease of bone. *J Bone Miner Res* 2010;25:20-31.
 40. Chakravorty NK. Neurological complications of Paget's disease of bone. *Br J Clin Pract* 1985;39:335-338.