



# Bone loss in shoulder instability: putting it all together

Laura E. Keeling<sup>1^</sup>, Nyaluma Wagala<sup>1^</sup>, Patrick M. Ryan<sup>2</sup>, Ryan Gilbert<sup>1</sup>, Jonathan D. Hughes<sup>1^</sup>

<sup>1</sup>Department of Orthopaedic Surgery, UPMC Freddie Fu Sports Medicine Center, University of Pittsburgh, Pittsburgh, PA, USA; <sup>2</sup>Department of Orthopedic Surgery, Baylor Scott & White Medical Center, Temple, TX, USA

*Contributions:* (I) Conception and design: LE Keeling, JD Hughes; (II) Administrative support: LE Keeling, JD Hughes; (III) Provision of study materials or patients: None; (IV) Collection and assembly of data: None; (V) Data analysis and interpretation: None; (VI) Manuscript writing: All authors; (VII) Final approval of manuscript: All authors.

*Correspondence to:* Laura E. Keeling, MD. Department of Orthopaedic Surgery, UPMC Freddie Fu Sports Medicine Center, University of Pittsburgh, 3200 South Water Street, Pittsburgh, PA 15203, USA. Email: keelingle@upmc.edu.

**Abstract:** Glenohumeral bone loss is frequently observed in cases of recurrent anterior and posterior shoulder instability and represents a risk factor for failure of nonoperative treatment. Patients with suspected glenoid or humeral bone loss in the setting of recurrent instability should be evaluated with a thorough history and physical examination, as well as advanced imaging including computed tomography (CT) and/or magnetic resonance imaging (MRI). In cases of both anterior and posterior instability, the magnitude and location of bone loss should be determined, as well as the relationship between the glenoid track (GT) and any humeral defects. While the degree and pattern of osseous deficiency help guide treatment, patient-specific risk factors for recurrent instability must also be considered when determining patient management. Treatment options for subcritical anterior bone loss include labral repair and capsular plication, while more severe deficiency should prompt consideration of bony augmentation including coracoid transfer or free bone block procedures. Concomitant humeral lesions are treated according to the degree of engagement with the glenoid rim and may be addressed with soft tissue remplissage or bony augmentation procedures. While critical and subcritical thresholds of glenoid bone loss guide the management of anterior instability, such thresholds are less defined in the setting of posterior instability. Furthermore, current treatment algorithms are limited by a lack of long-term comparative studies. Future high-quality studies as well as possible modifications in indications and surgical technique are required to elucidate the optimal treatment of anterior, posterior, and bipolar glenohumeral bone loss in the setting of recurrent shoulder instability.

**Keywords:** Shoulder instability; bone loss; glenohumeral bone loss; glenoid bone loss; Hill-Sachs

Received: 15 February 2023; Accepted: 31 May 2023; Published online: 05 July 2023.

doi: 10.21037/aoj-23-6

**View this article at:** <https://dx.doi.org/10.21037/aoj-23-6>

## Introduction

The shoulder is the most frequently dislocated major joint, with an incidence in the United States of up to 24 per 100,000 person-years (1). While stability of the glenohumeral joint derives primarily from static and dynamic soft tissue restraints including the labrum, capsule, and rotator cuff, these structures are complemented by the osseous morphology of the shoulder. Traumatic dislocations

may damage the bony architecture of the glenoid and humerus, while recurrent instability can be both a symptom and a cause of chronic bone loss. Notably, up to 90% of patients undergoing arthroscopic evaluation of recurrent shoulder instability demonstrate an osseous defect of the glenoid or humeral head (2).

Successful treatment of both primary and recurrent shoulder instability necessitates careful consideration of

<sup>^</sup> ORCID: Laura E. Keeling, 0000-0001-7776-6635; Nyaluma Wagala, 0000-0002-3560-7174; Jonathan D. Hughes, 0000-0002-1298-7514.

anterior and posterior glenoid bone loss, osseous (Hill-Sachs or reverse Hill-Sachs) lesions of the humeral head, and underlying ligamentous laxity that may predispose to multidirectional instability (MDI). Failure to address bone loss may lead to failure of surgical treatment, with rates of recurrent instability as high as 17.8% among contact athletes following arthroscopic soft tissue repair (3). Treatment algorithms in recent years have focused on defining “critical” versus “subcritical” glenoid bone loss (4), and in classifying bipolar glenoid and humeral lesions according to the glenoid track (GT) concept (5). While critical anterior bone loss has historically been defined as 20–25% of the glenoid diameter (6), studies have demonstrated increased failure rates with soft tissue stabilization in patients with as little as 13.5% glenoid bone loss (4). Furthermore, while bipolar lesions are typically characterized as “on-track” or “off-track” according to engagement of the Hill-Sachs lesion with the anterior glenoid rim, the recent concept of “distance to dislocation” (DTD) calls this binary framework into question (7). As the GT narrows and Hill-Sachs size increases, on-track lesions demonstrate a relatively small DTD, and become “near-track” lesions. Particularly in younger patients, “near-track” lesions may portend an increased risk of failure of soft-tissue procedures (7). Finally, the treatment of recurrent shoulder instability may be influenced by other osseous features, such as glenoid retroversion (8), and patient-specific factors, such as age, athletic status, and ligamentous laxity (9). It is important to note that in the setting of laxity and concomitant MDI, treatment algorithms differ, primarily favoring nonoperative over operative management (10).

The purpose of this paper is to provide a comprehensive review of the evaluation and management of bone loss in the context of shoulder instability. Both anterior and posterior glenoid bone loss, as well as humeral head and bipolar lesions will be discussed. Finally, the authors will describe an evidence-based treatment algorithm for both glenoid and humeral-sided lesions.

## Pathophysiology

### *Anterior*

Patients are at risk of anterior shoulder dislocations when the arm is in a position of 90 degrees of abduction with maximum external rotation of the shoulder. This position places stress on the anteroinferior capsule and the anterior band of the inferior glenohumeral ligament (IGHL), one of the principal static stabilizers of the shoulder (11).

When the force applied exceeds the resistance force of the IGHL and/or anteroinferior capsule, the ligament is disrupted and the glenohumeral joint subluxates or dislocates. In younger patients, the energy involved is often substantial; common etiologies include motor vehicle accidents, sports collisions, and skiing accidents (12). In elderly patients, low energy etiologies, such as falls from standing, are often implicated (13).

Dislocation often requires manual closed reduction with the aid of muscle relaxation or sedation (14). After reduction, the amount of residual instability in the shoulder is dependent on many factors, including mechanism of injury, magnitude of force involved, and additional bony or soft tissue injury, among others. One common associated injury is an avulsion of the anterior inferior capsulolabral complex. This is defined as a Bankart lesion and is present in up to 85% of traumatic anterior dislocations (15,16). Capsulolabral complex injuries are not limited to the anteroinferior location and are often seen extending superiorly, inferiorly, and even circumferentially. Multiple anterior dislocations may lead to pathologic superior translation of the humeral head, producing superior extension of capsulolabral injuries that further contribute to the cycle of repetitive dislocation (17). Moreover, Bankart lesions are often found in conjunction with additional injuries, such as humeral avulsion of the IGHL, known as a humeral avulsion of the glenohumeral ligament (HAGL) lesion (18).

In addition to soft tissue injuries, shoulder dislocations can result in bony injuries. When the humeral head dislocates anteriorly, the posterior head can be impacted along the anterior glenoid rim, resulting in a Hill-Sachs lesion. The Hill-Sachs lesion is often analyzed in relationship to the GT, with “off-track” lesions engaging the anterior glenoid rim and resulting in subluxation. Repetitive subluxations or dislocations may also erode the anterior rim of the glenoid, causing glenoid bone loss and resulting in a cycle of recurrent dislocating events (13,19).

Instability may be present without history of a frank dislocation as well. Repetitive microtrauma, commonly seen in overhead athletes such as volleyball players and baseball pitchers, causes repetitive load of the glenohumeral joint in abduction and excessive external rotation, resulting in subluxation to pathologic limits while maintaining glenohumeral contact (19).

### *Posterior*

While anterior shoulder instability is more commonly

encountered, posterior shoulder instability remains a relevant and challenging clinical problem. Though seen as a sequelae of dislocation events stemming from seizures and electrocution, the pathology most commonly stems from repetitive microtrauma with the shoulder in a position of flexion and internal rotation. This position is often seen in exercise activities such as bench press and push-ups as well as in the blocking position of offensive linemen in American football and a variety of military exercises (20). Similar to anterior instability, adaptive changes within the shoulder of overhead athletes predisposes these patients to posterior labral injuries (21). The superior labrum undergoes permissive detachment to allow for the terminal external rotation required in overhead throwing motions, and when this detachment extends posterior to the biceps anchor, the posterior labrum loses its compressive capability and the posterior band of the IGHL becomes compromised, resulting in a symptomatic throwing shoulder (21-23).

Abnormal bony anatomy may also predispose patients to posterior instability. The morphology of the glenoid with respect to its articulation with the humeral head has been scrutinized, and retroversion and dysplasia have been shown to be risk factors. In fact, every degree of increased glenoid retroversion increases posterior instability risk by 17% (24). Another important risk factor is the amount of bone loss present in association with instability. Posterior glenoid bone loss has been characterized morphologically as a loss of posterior concavity with increased glenoid retroversion, both of which lower the threshold for posterior subluxation (25). One study assessing outcomes after posterior stabilization found inferior outcomes were more closely linked to bone loss than glenoid version (26), with a similar study finding a decreased return to full duty in military patients with posterior bone loss exceeding 13.5% (27).

## Clinical evaluation

### History

Assessment of shoulder instability and possible bone loss should begin with a detailed history. Important patient characteristics include age, gender, sport played, mechanism of injury, number of previous instability events, treatments received, and a personal or family history of hyperlaxity (28). Males aged 15 to 29 years account for 48.6% of shoulder dislocations presenting to the emergency room, with a male-to-female incidence ratio of 2.64. Patients under age 30 also account for the majority (64%) of recurrent dislocations (1).

Age is therefore a critical risk factor for recurrent shoulder instability, with 72–100% of patients under 20 experiencing recurrent instability. For patients aged 20 to 30 years, the rate of recurrent instability is 70–82% (29). In college athletes, anterior and posterior subluxations represent the most common recurrent shoulder injuries (47.3% and 40.0%, respectively) (30).

Participation in contact sports or military service is associated with a high risk for shoulder instability. Collegiate athletes participating in ice hockey, lacrosse, football, and wrestling are more likely to sustain a shoulder injury than athletes engaging in other sports (31,32). A 5-year retrospective review of both male and female college athletes found an incidence rate of 31.3 per 100,000 for shoulder instability events, with wrestling and football having the highest incidence rates. A vast majority (86.5%) occurred from contact, and male athletes were two times as likely as female athletes to sustain an instability event (30). Quarterbacks have been found to experience shoulder instability events at a rate as high as 5.5 per 100,000 plays (20). The incidence of shoulder dislocations in the military was found to be 3.13 per 1,000 person-years in a retrospective 10-year review (33).

Scrutiny should be given to a history of shoulder instability events. Patients with recurrent instability may be at increased risk for glenohumeral bone loss, as each recurrent dislocation may contribute to cumulative bone defects (34). Although the number of instability events is not an accurate predictor for the magnitude of bone loss, any incident of instability has been correlated with the potential for bone loss as well as recurrent dislocation. Yoshida *et al.* found that recurrent anterior glenohumeral instability is associated with pathologic superior translation of the humeral head, leading to superior extension of capsulolabral injury, thereby increasing the likelihood of recurrent dislocation (17). Furthermore, Griffith *et al.* found some degree of bone loss in 41% of patients after an initial dislocation, and in 86% of patients with recurrent dislocation (35). A separate study found glenohumeral bone loss in 70% of patients after primary dislocation. In general, multiple instances of instability in a short timeframe, or previously failed capsulolabral repair suggest significant glenohumeral bone defects (19).

### Physical examination

A thorough examination of the shoulder girdle should be performed in any case of instability, with or without

suspected bone loss. A complete sensorimotor evaluation of the extremity is indicated to assess rotator cuff and periscapular muscle strength. Passive and active range of motion must also be evaluated and can provide insight into concomitant pathology. It is important to note that the specificity of individual physical exam maneuvers is poorly defined in the literature; thus, clinicians should combine several maneuvers for an accurate, pathology-based diagnosis (36,37).

The directionality of instability can be assessed through several maneuvers. The anterior apprehension and Jobe relocation tests have the highest positive predictive values (96%) for anterior shoulder instability, while the Jerk test, Kim test, and push-pull exams are most appropriate for posterior or MDI (21,37). Apprehension in lower degrees of abduction may indicate more significant bone loss (38). Any provocative maneuver should always be compared to the contralateral shoulder to assess baseline laxity. Generalized ligamentous laxity should also be assessed via the Beighton criteria, as underlying laxity may contribute to recurrent instability events (10,28).

Hill-Sachs defects are difficult to physically assess. Sensations of pain, crepitus, or catching when the arm is in a position of apprehension may be indicative of an engaging Hill-Sachs lesion, but the specificity of these findings is low (19). The Bony Apprehension Test was previously introduced as a method to assess for Hill-Sachs lesions but has since been shown to be inferior to the anterior apprehension test at identifying subcritical and critical bone loss (39,40). Glenoid bone loss may be assessed by the load and shift test, as decreased resistance may indicate a glenoid lesion in the direction of laxity (41).

While a combination of exam maneuvers maximizes sensitivity for glenohumeral instability, it does not always differentiate between soft tissue and bony pathology. Any abnormal or asymmetric finding during physical examination should be evaluated further by imaging (9).

## Imaging

After a thorough history and physical examination, it is essential to obtain appropriate and complete imaging in the workup of patients with shoulder instability. Both capsulolabral and bony pathology, including the morphology and extent of bone loss, must be identified, as patients with bony defects are at risk of recurrent instability (42). The relationship between the glenoid and any Hill-Sachs or reverse Hill-Sachs lesion must also be

identified. The “track” of the glenoid is the contact surface between the glenoid and the humeral head and consists of approximately 83–84% of the glenoid width (43,44). In the setting of anterior instability, if the Hill-Sachs lesion is “off-track”, it falls outside the GT and is at risk of engaging, levering on the rim of the glenoid, and dislocating the humeral head. If it is “on-track”, it will not engage with the glenoid during the arc of motion and is therefore less likely to contribute to dislocation. This can be assessed intraoperatively following repair of a Bankart lesion, as well as preoperatively with advanced imaging. Importantly, off-track lesions pose an increased risk of failure of Bankart repair, with subsequent instability if not addressed (4).

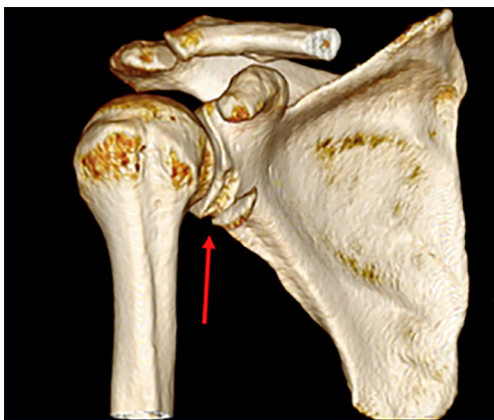
## Radiographs

Imaging evaluation should begin with a dedicated shoulder radiograph series, including standard anteroposterior (AP), true AP or Grashey, scapular Y, and axillary lateral views. The AP views may demonstrate subluxation in the coronal plane, while the axillary lateral view may demonstrate subluxation in the axial plane and begin to characterize any anterior or posterior glenoid bone loss. Additional radiographs to consider include the Stryker notch view, in which the humerus is placed in internal rotation, for assessment of a Hill-Sachs lesion (13) as well as the West Point view, a modification of the axillary lateral that best assesses glenoid bone loss (45). Even with this view, glenoid bone loss is sometimes missed, and thus advanced imaging is recommended (46).

## Advanced imaging

Computed tomography (CT) scans are useful for further evaluation of osseous anatomy, in situations of both acute injury and chronic bone loss. Characterization of anterior glenoid rim fractures, also known as “bony Bankart” lesions, is important as attrition of the fracture fragment may develop along with increased size of the glenoid defect if not addressed promptly (47) (*Figure 1*). In the setting of chronic bone loss, CT is indicated for assessment of the size and location of osseous deficiency. Multiple measurement techniques exist, including linear and area-based measurements. Controversy exists surrounding the superiority of such techniques, as well as the accuracy of two-dimensional (2D) versus three-dimensional (3D) modalities and CT versus magnetic resonance imaging (MRI) (48). In general, the literature suggests





**Figure 1** 3D-reconstructed CT scan with a red arrow pointing to a bony Bankart lesion. Adapted from Hughes *et al.* (13). 3D, three-dimensional; CT, computed tomography.

that area-based measurements are superior to linear-based measurements, which may overestimate bone loss (49,50). The “Pico” method described by Baudi *et al.* (51) is a popular area-based technique that has demonstrated high accuracy and reliability (48,50). In this method, a circle of best fit is placed according to the curvature of the posteroinferior glenoid and its area measured. The area of bone loss anteriorly is then measured and subtracted, giving a percentage area of deficiency (51).

Similar best-fit circle techniques are also useful in examining bone loss in the setting of posterior instability. While glenoid bone loss is typically measured on a sagittal view, axial sequences should also be scrutinized for the presence of glenoid dysplasia or retroversion. Glenoid retroversion greater than  $10^\circ$  is considered abnormal in the setting of recurrent posterior instability and should prompt consideration of bony augmentation procedures (52).

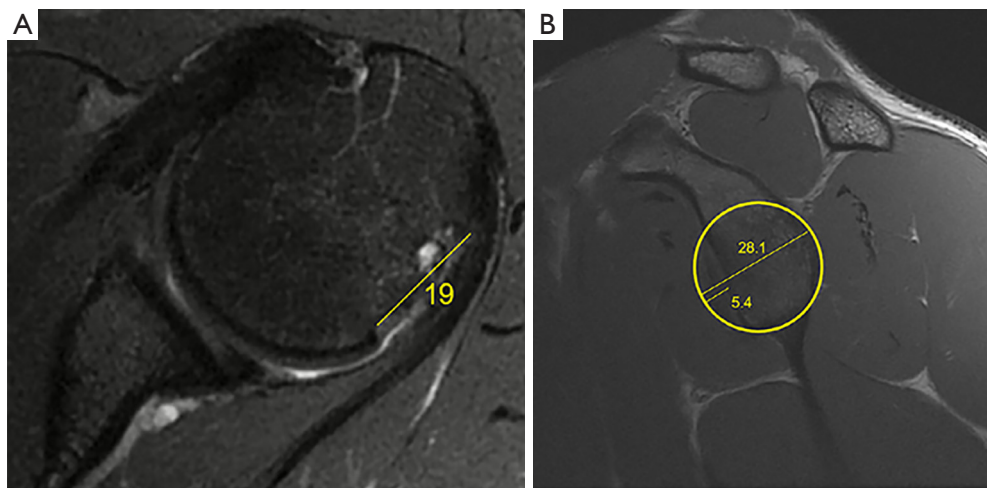
When considering 2D versus 3D CT, the majority of studies indicate that 3D CT is preferred, as it provides the most reproducible measurements with the use of a standardized “en face” view (48–50). The superiority of CT over MRI is less well-defined. Although CT is generally considered to be the “gold standard” imaging modality in evaluation of glenoid bone loss due to bony resolution, high sensitivity and specificity, and easy availability (48), recent studies suggest that 3D MRI is equivalent to 3D CT in evaluating bone loss (53–55). Thus, when considering the optimal study, the risk of ionizing radiation inherent to CT must be weighed against the potential cost and limited availability of 3D MRI.

CT and MRI are also used to assess the interplay between the GT and any concomitant Hill-Sachs or reverse Hill-Sachs lesion. In the setting of anterior instability, a recent scoping review (56) found the most common assessment of the GT is that described by DiGiacomo and Burkhart via the Hill-Sachs Interval (HSI), which is the distance from the medial aspect of the Hill-Sachs lesion to the insertion of the rotator cuff on an axial image (5). Following calculation of the HSI, the GT is determined using the formula  $GT = (D \times 0.83) - d$ , where  $D$  is the diameter of a best-fit circle on the glenoid and  $d$  is the diameter of bone loss (Figure 2). If the width of the HSI exceeds the size of the GT, then the lesion is considered “off-track” and will engage the glenoid rim. Conversely, if the HSI is smaller than the GT, the lesion is “on-track” and will not engage. The morphology of the Hill-Sachs lesion should also be considered, as lesions with more medial and inferior locations, greater width, and greater surface area loss have been associated with inferior clinical outcomes (57).

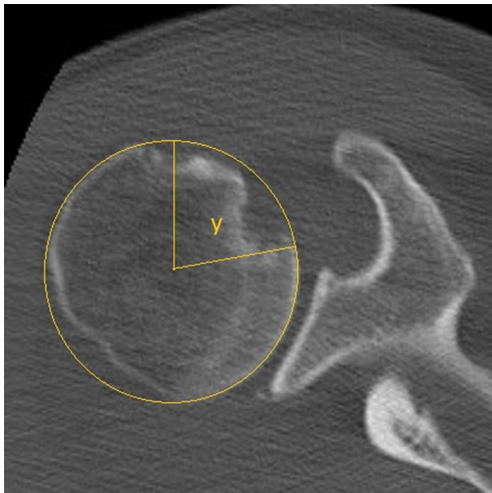
Recent literature has also focused on the concept of “DTD” (7,58). The DTD is calculated according to the formula  $DTD = GT - HSI$ . While a  $DTD > 0$  mm indicates an on-track lesion, studies demonstrate that a  $DTD < 8-10$  mm may be predictive of failure following arthroscopic Bankart repair, particularly in patients younger than 20 (7,58). The GT and HSI must therefore be carefully evaluated preoperatively, as their relationship has significant implications for treatment.

It is important to quantify any reverse Hill-Sachs lesion present in the setting of posterior instability. Although less well-described than techniques for quantifying anteriorly engaging lesions, measurement of a reverse humeral defect may be performed via calculation of the “gamma angle” (59). On the axial cut in which the lesion appears widest, a best-fit circle is drawn around the humeral head. The gamma angle is measured between a line connecting the bicipital groove and the center of best-fit circle, and a line connecting the center of the circle and the medial border of the defect (Figure 3). Furthermore, if glenoid bone loss is present,  $2.3^\circ$  should be added to the gamma angle for each millimeter of posterior bone loss. A gamma angle  $> 90^\circ$  represents an engaging lesion that may necessitate treatment (52).

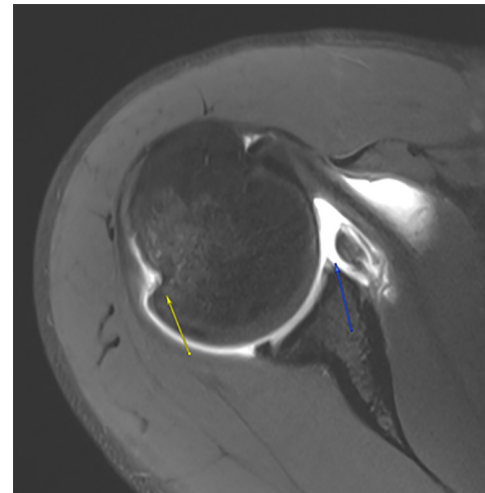
In conjunction with evaluation of bony anatomy, detailed evaluation of the soft tissue structures about the shoulder is necessary. MRI is therefore critical in assessing for associated injuries such as anteroinferior glenoid labrum defects (Bankart lesions), as well as HAGL lesions, anterior labral periosteal sleeve avulsions (ALPSAs), or glenoid articular cartilage defects (GLADs) (12) (Figure 4). This is true for



**Figure 2** T2-weighted axial (A) and sagittal (B) images in the assessment of an off-track Hill-Sachs lesion using the HSI and the GT. The HSI is defined as the distance from the medial aspect of the Hill-Sachs lesion to the insertion of the rotator cuff (19 mm in this case). The GT is found using the formula  $GT = (D \times 0.83) - d$ , where  $D$  is the diameter of the best fit circle on the glenoid (28.1 mm in this example) and  $d$  is the diameter of bone loss (5.4 mm). Thus,  $GT = 17.9$  mm, less than the HSI of 19 mm, making this an off-track lesion. Adapted from Hughes *et al.* (13). HSI, Hill-Sachs Index; GT, glenoid track.



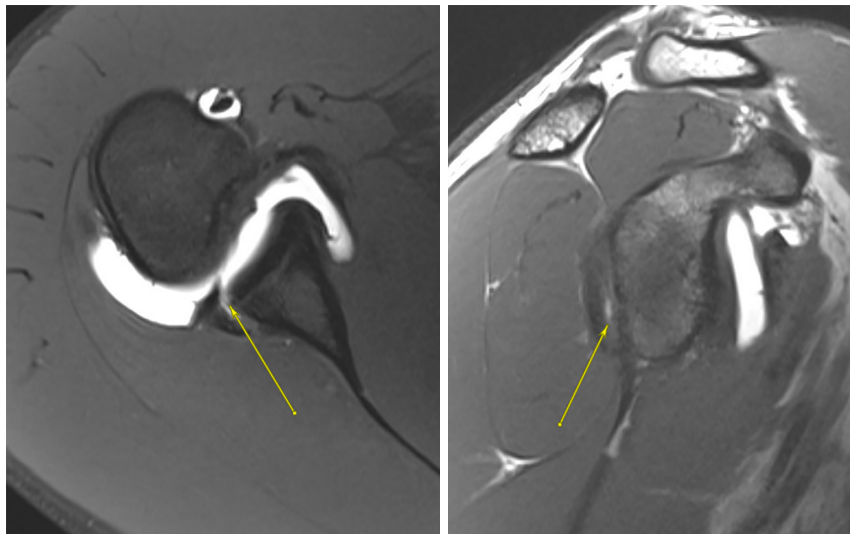
**Figure 3** Axial CT image demonstrating a reverse Hill-Sachs lesion with the gamma angle depicted. This angle is less than  $90^\circ$ , indicating a nonengaging lesion. CT, computed tomography.



**Figure 4** T2 axial image of an anteroinferior labral tear with medialization of the labrum and ALPSA lesion depicted by the blue arrow, as well as a small Hill-Sachs lesion about the posteroinferior humeral head depicted by the yellow arrow. ALPSA, anterior labroligamentous periosteal sleeve avulsion.

assessing both suspected traumatic anterior instability as well as posterior instability, where the posterior inferior glenoid should be scrutinized for the presence of a reverse Bankart lesion (*Figure 5*). The integrity of the rotator cuff should also be evaluated, particularly in patients over the age

of 40 years, as tearing of the rotator cuff frequently occurs concomitantly with shoulder instability events (60). The use of contrast should be considered, as magnetic resonance (MR) arthrography has been demonstrated more sensitive than nonenhanced MRI in assessing labral pathology, which



**Figure 5** T1-weighted fat saturated axial (left) and T1 sagittal (right) MRI images demonstrating a reverse bony Bankart lesion with an associated posterior labral tear depicted by the yellow arrows. MRI, magnetic resonance imaging.

remains important even in the setting of bone loss (61). Finally, in addition to conventionally obtained MRI images (including axial, coronal, and sagittal sequences), sequences that place the shoulder in abduction and external rotation should be performed as they increase the detection of labral lesions (62).

## Treatment

When considering management options for glenohumeral instability, it is important to adequately assess both glenoid and humeral bone loss, as the presence of such defects is a known risk factor for recurrent instability (4,63). Nevertheless, many factors influence decision-making in addition to the presence of bone loss, such as patient age, activity level, and desire to return to sport.

### *Anterior instability*

#### **Nonoperative treatment**

Nonoperative management plays a limited role in the care of a patient with anterior glenohumeral instability and associated bone loss. Although nonoperative treatment may be considered in the in-season athlete or first-time dislocator without bony injury (64), it is generally contraindicated in patients with osseous involvement due to the high risk of recurrent instability, as well as exacerbation of bone loss (65). Nonoperative treatment

may, however, be considered in the non-athlete for whom the medical risks of surgery outweigh the benefits. Such treatment consists of physical therapy for range of motion and strengthening, as well as counseling regarding the increased risk of recurrent instability due to underlying bony deficiency.

#### **Operative treatment**

While operative intervention is generally indicated in patients with glenohumeral instability and associated bone loss, treatment is guided by the degree and pattern of bony deficiency. However, determining the amount of glenoid bone loss that is clinically significant is difficult due to a lack of consensus throughout the literature (4). “Critical” bone loss has been defined as glenoid bone loss >20–25%, as numerous studies have shown high rates of recurrent instability following isolated arthroscopic Bankart repair in such patients (63,66,67). Conversely, “subcritical” bone loss has been described as glenoid bone loss <20% (13). However, recent studies have shown that bone loss as low as 13.5% may be associated with inferior patient outcomes following arthroscopic soft tissue stabilization (4). Therefore, successful surgical decision-making can be challenging in these patients. The Instability Severity Index Score (ISIS) is a system designed to identify patients at risk for failure of isolated soft tissue stabilization, with a score greater than 6 corresponding with a 70% recurrence risk (68). Although the predictive value of the ISIS has

been questioned (69), it remains a useful tool for identifying risk factors that correspond with failure of soft tissue procedures. Patient factors that increase the ISIS include age less than 20, the presence of visible glenoid bone loss or a Hill-Sachs lesion on X-ray, participation in competitive as well as contact or overhead sports, and the presence of hyperlaxity (68). All of these factors should be taken into account when considering surgical options.

Other useful predictors of recurrent instability include the Nonoperative Instability Severity Index Score (NISIS) (70) and the Glenoid Track Instability Management Score (GTIMS) (71). The GTIMS is particularly useful for surgical planning, as it has been demonstrated to delineate patients who would benefit from arthroscopic Bankart repair with more accuracy than the ISIS (71). A modification of the ISIS, the GTIMS replaces the radiographic parameters of the former and instead uses 3D CT as the sole radiographic criterion to assess whether an osseous lesion is on-track or off-track (71). With this scoring system, patients may be more conservatively recommended for soft tissue rather than bony stabilization.

In general, surgical treatment can be divided into soft-tissue procedures, including arthroscopic or open Bankart repair and remplissage (BRR), and bony procedures, including coracoid transfer (Latarjet, Bristow) and autograft or allograft reconstruction. In addition to assessing patient risk factors for recurrent instability, the primary step toward surgical decision-making for anterior instability is to identify which category of glenoid bone loss the patient falls into: <13.5% bone loss, 13.5–20% bone loss, 20–40% bone loss, or >40% bone loss. While patients with lesser degrees of bone loss may benefit from soft tissue procedures, increased severity of bone loss as well as the presence of bipolar lesions necessitates consideration of bony augmentation.

Arthroscopic Bankart repair, typically with capsular plication, is indicated in patients with minimal (<13.5%) bone loss and an on-track or absent Hill-Sachs lesion (72). In the setting of an acute bony Bankart fracture, arthroscopic repair may also be performed with a suture bridge technique, in which suture anchors are placed medially on the glenoid neck. The sutures are then passed around the fragment and loaded into a second row of anchors placed on the glenoid face (73). In both the acute and chronic settings, it is important to address any coexisting pathology, such as GLAD or ALPSA lesions, as failure to do so may increase the risk of recurrent instability (13). In appropriately selected patients, arthroscopic Bankart repair has demonstrated good clinical outcome scores and

return to sport rates approaching 80% (74,75). Although open Bankart repair was historically considered superior to arthroscopic repair in patients with recurrent anterior instability (76), with the use of modern techniques the literature now supports arthroscopic Bankart repair as an equivalent or superior option (77,78). While open Bankart repair may be considered in patients requiring a large capsular shift, such as those with hyperlaxity or those undergoing revision surgery (76), arthroscopic repair still represents a viable treatment option in patients with minimal glenoid and humeral bone loss.

Patients with higher degrees of bone loss as well as engaging Hill-Sachs lesions may be indicated for bony augmentation procedures to increase the size of the GT. Hill-Sachs lesions at high risk of engagement, such as those that are medial or wide, can also be considered for such procedures (57). While the precise degree of bone loss that mandates the use of a bony procedure remains undefined, studies have demonstrated excellent clinical outcomes in patients undergoing bony augmentation for both critical and subcritical bone loss (42,79). The definition of subcritical bone loss varies in the literature, yet is generally accepted to be between 10–20% (75) or 13.5–20% (13). In the wake of studies demonstrating higher rates of failure with isolated Bankart repair (4,68), patients with subcritical bone loss have frequently been indicated for coracoid transfer procedures, particularly in the presence of concomitant Hill-Sachs lesions (80). Studies have demonstrated decreased rates of failure (81) as well as improved patient-reported outcomes (82) in patients with subcritical bone loss undergoing Latarjet versus arthroscopic Bankart repair. However, concerns exist regarding the complication rate as well as sequelae of the Latarjet procedure (83). While long-term studies demonstrate good functional outcomes following Latarjet (84,85), a recent systematic review reported a 38% rate of arthritic change as well as a 36% rate of residual shoulder pain at mean 16.6-year follow-up (84).

In recent years, attention has shifted from Latarjet towards the addition of remplissage to arthroscopic Bankart repair in patients with subcritical bone loss and Hill-Sachs lesions. In the remplissage procedure, the infraspinatus and posterior capsule are sutured into the Hill-Sachs defect, creating a mechanical block to bony engagement while also decreasing external rotation and translating the humeral head posteriorly (86). In patients with Hill-Sachs lesions and subcritical bone loss, arthroscopic BRR is associated with lower rates of recurrent instability when compared



to Bankart repair alone (87). Furthermore, an early comparative study of BRR versus Latarjet for the treatment of off-track Hill-Sachs lesions with subcritical bone loss demonstrated a higher complication rate with Latarjet, yet improved outcomes following Latarjet in contact athletes, those undergoing revision surgery, and those with >10% glenoid bone loss (88). Subsequent systematic reviews and meta-analyses have reported overall similar outcomes between the two procedures, with a trend toward slightly increased complication rates with Latarjet and slightly increased failure rates with BRR in patients with increased glenoid bone loss (79,87,89). However, a recent study found similar patient-reported outcomes and failure rates at mean 2-year follow-up in patients undergoing BRR versus Latarjet for the treatment of anterior instability with >15% bone loss (90). Notably, the study cohort included patients with both on-track and off-track lesions. Thus, at this time the literature indicates similar outcomes in patients with subcritical bone loss following BRR and Latarjet, yet caution should be exercised when performing BRR in patients with combined off-track lesions and glenoid bone loss >10%.

In addition to remplissage, some authors have advocated for alternative humeral reconstructive techniques, including bone grafting (91) and disimpaction or balloon humeroplasty (92). While several technical descriptions exist in the literature, outcome studies are limited and demonstrate high rates of graft resorption and arthritic change, as well as complication and reoperation rates between 20% and 30% (93). Therefore, at this time, such procedures are not routinely recommended.

For patients with critical (>20–25%) bone loss, coracoid transfer procedures such as the Latarjet have traditionally been considered the standard of treatment due to excellent long-term outcomes with low rates of failure (80,94). However, alternative augmentation procedures have emerged to address limitations of the Latarjet, including the inability of the procedure to treat severe bone loss (>40%) and its lack of a true articular surface, as well as cases of failed Latarjet reconstruction (80). The most commonly performed bone-block procedures include distal tibia allograft (DTA), distal clavicle autograft, and allograft or autograft iliac crest bone graft (ICBG). The Eden-Hybinette (EH) procedure involves harvesting autograft from the inner table of the ilium, thereby allowing graft harvest of varying sizes to reconstruct the anterior glenoid (95). Although the EH has demonstrated good outcome scores and low recurrence rates similar to the Latarjet (96,97),

donor site morbidity constitutes a significant drawback of the procedure. Benefits of the DTA and allograft ICBG procedures include the avoidance of donor-site morbidity while restoring articular cartilage as well as surface area to the anterior glenoid (13). While arthroscopic as well as open techniques have been described, similar outcomes have been reported between the two, comparable to those of the Latarjet (98–101). A recent systematic review comparing free bone block procedures versus Latarjet in the management of anterior shoulder instability with glenoid bone loss demonstrated no difference in rates of recurrence, complications, return to sport, or progression of arthritis (100). Similarly, a systematic review comparing free bone block autografts versus allografts in a comparable patient population demonstrated no significant difference in outcomes or complication rates (101). Comparison was limited, however, by the lack of high-quality studies with long-term follow-up. Future studies are needed to determine the long-term efficacy and sequelae of both open and arthroscopic free bone block procedures in the management of recurrent anterior shoulder instability with bone loss.

### *Posterior instability*

Although treatment algorithms for posterior shoulder instability in the setting of bone loss are less well-defined than those for anterior instability, recurrent posterior instability represents a significant clinical concern. As with anterior bone loss, nonoperative treatment in patients with posterior bone loss demonstrates a high failure rate, particularly in high-risk populations such as the military or athletes performing repetitive posterior glenoid loading (102). While soft tissue repair alone yields good clinical outcomes in patients with minimal or no posterior bone loss (103), patients with erosive, traumatic, or dysplastic glenoid defects should be considered for bony augmentation procedures (104,105).

Although the threshold for critical bone loss in anterior instability has been highly scrutinized in the literature, the threshold for posterior instability remains unclear. Some authors have defined “critical” posterior bone loss requiring augmentation as 20% (106), while others recommend bone block augmentation according to a classification system that qualifies instability based on type (first-time, dynamic, static) and pathomechanism (107). A recent case-control study demonstrated a 10 times increased risk of failure of posterior capsulolabral repair with posterior bone loss of 11%, and

a 24 times increased risk with bone loss of 15% (105). As a result, some authors recommend performing bone block augmentation, typically with DTA or ICBG allograft, in patients with recurrent posterior instability and glenoid bone loss greater than 10% (52,105). These recommendations are limited however by the lack of long-term as well as high-quality studies examining outcomes of posterior augmentation procedures for glenoid bone loss. While case series have shown improvements in patient-reported outcome scores (108), complication rates including graft lysis and progression of osteoarthritis are high (109,110). A recent systematic review found that the use of posterior bone block augmentation for recurrent posterior shoulder instability resulted in high rates of recurrent instability and revision surgery with inconsistent improvements in patient outcomes (110). Thus, further high-quality studies as well as possible modifications in indications and surgical technique are required to elucidate the appropriate treatment of posterior glenoid bone loss.

Other surgical considerations include the presence of glenoid retroversion and/or posterior dysplasia. Glenoid retroversion  $>10^\circ$  and posteroinferior glenoid border deficiency have been identified as risk factors for failure of soft tissue repair in the treatment of recurrent posterior instability (111). While techniques of opening wedge osteotomy for the correction of retroversion have been described, both in isolation (112) and combined with bone block augmentation (113), these procedures are technically demanding and yield inconsistent clinical results (52,112,113). Larger studies with long-term follow-up are necessary to determine the utility of such techniques, which may still be considered experimental at this time.

Finally, it is also important to address any engaging reverse Hill-Sachs defect in the surgical treatment of posterior glenohumeral instability, as bipolar lesions are associated with failure of soft tissue repair (114). The previously described gamma angle (59) can be used to guide indications, although it has not been correlated with a specific treatment in the absence of a posterior glenoid defect. In patients with posterior glenoid bone loss and an engaging reverse Hill-Sachs lesion (defined as a gamma angle  $>90^\circ$ ), the preferred treatment is a reverse remplissage, in which the subscapularis tendon is sutured into the humeral defect (52,115). While numerous techniques have been published (115-118), outcome studies of the reverse remplissage or “modified McLaughlin” procedure in the setting of posterior bone loss and instability are lacking. Thus, as is common to the evidence-based management

of posterior glenoid bone loss, further high-quality and comparative studies are indicated.

### Authors' preferred treatment algorithm

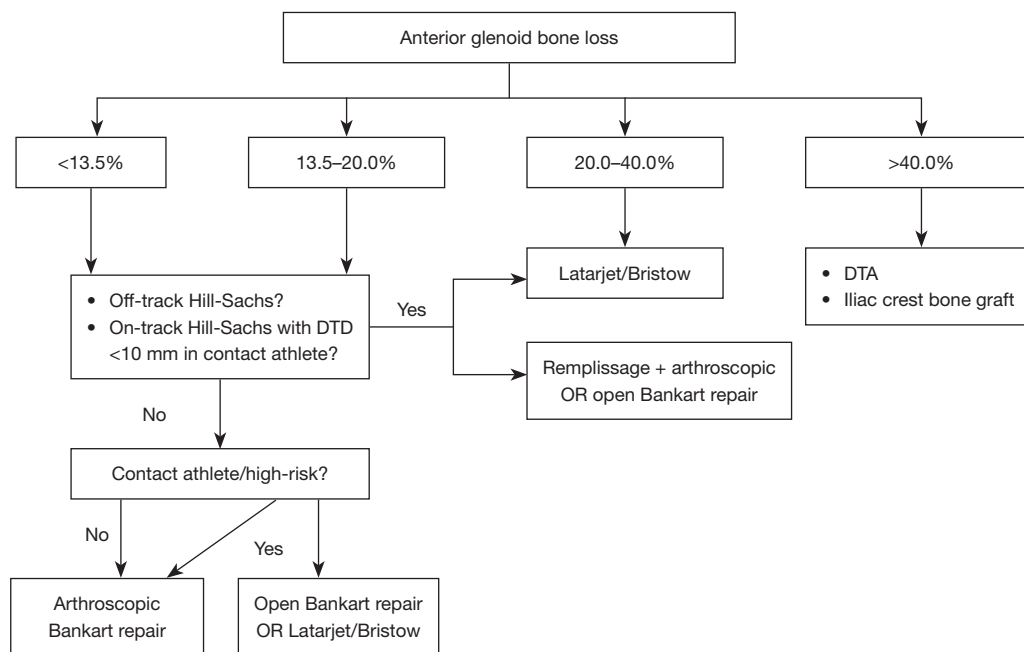
In all cases of recurrent shoulder instability, treatment should be individualized to the patient and his or her goals. While significant medical comorbidities may preclude operative management in certain patients, the high risk of recurrent instability inherent to glenohumeral bone loss mandates surgical treatment in most patients. The following sections will therefore describe operative treatment algorithms for glenohumeral bone loss in the settings of both anterior and posterior instability.

#### *Anterior instability*

All patients presenting with recurrent anterior shoulder instability are evaluated with a thorough history and physical examination to assess risk factors for recurrence as well as baseline and pathologic laxity. In cases of suspected bone loss based on history, examination, and radiographs, advanced imaging is obtained. Both CT and MRI are typically performed to evaluate the magnitude and location of osseous deficiency, anchors from prior capsulolabral repair, and the integrity of surrounding soft tissue structures.

Once imaging has been obtained, bone loss is analyzed on both the humeral and glenoid sides. Patients are divided into four categories based on the degree of glenoid bone loss:  $<13.5\%$ ,  $13.5\text{--}20\%$ ,  $20\text{--}40\%$ , and  $>40\%$  (*Figure 6*). In patients with  $20\text{--}40\%$  glenoid bone loss, the senior author prefers Latarjet due to the combined bony reconstruction of the coracoid and the sling effect of the conjoint tendon (13,79). Conversely, patients with  $>40\%$  glenoid bone loss typically require a larger graft and are indicated for free bone block augmentation using either DTA or ICBG allograft.

Patients with  $<20\%$  glenoid bone loss are managed differently according to age, status as a contact athlete, history of prior surgery, and the presence of a Hill-Sachs lesion. In noncontact athletes with minimal ( $<13.5\%$ ) bone loss, the preferred treatment is arthroscopic capsulolabral repair. However, if the patient has significant risk factors for recurrence according to the ISIS (68), further augmentation procedures are considered. In the presence of an off-track Hill-Sachs lesion, a remplissage is performed. For contact athletes, consideration is also given to performing an open



**Figure 6** Treatment algorithm for the management of glenohumeral bone loss in the setting of anterior shoulder instability. DTD, distance to dislocation; DTA, distal tibia allograft.

Bankart repair or a Latarjet, as studies have demonstrated decreased rates of recurrence with the use of these procedures in athletes compared to arthroscopic repair (119,120). The authors have also recently incorporated the concept of DTD into their treatment algorithm (7,58). For on-track lesions, as the DTD approaches 0 mm, the risk of recurrent dislocation increases exponentially, particularly in contact athletes (58). Thus, in contact athletes demonstrating “near-track” lesions with subcritical bone loss and a DTD <10 mm, consideration is given to combined BRR, or Latarjet (7,58).

### Posterior instability

Patients with suspected posterior bone loss in the setting of instability are similarly evaluated with a thorough history, physical examination, and advanced imaging. In patients with minimal (<10%) glenoid bone loss, posterior capsulolabral repair has demonstrated excellent outcomes, and is routinely performed (105). Those patients with an engaging reverse Hill-Sachs lesion, defined via preoperative measurement or intraoperative examination, may be indicated for reverse remplissage, although long-term outcomes of arthroscopic techniques are lacking. Due to the high rates of complication and recurrent instability

associated with posterior bone block augmentation and opening wedge osteotomy for glenoid bone loss and retroversion (110), respectively, these procedures are not routinely performed by the senior author.

### Conclusions

Glenohumeral bone loss commonly occurs with recurrent shoulder instability and is a risk factor for failure of both nonoperative treatment and soft tissue stabilization. Patients with suspected glenoid or humeral bone loss in the setting of recurrent instability should be evaluated with a thorough history and physical examination, as well as advanced imaging including CT and/or MRI. In cases of both anterior and posterior instability, the magnitude and location of bone loss should be determined, as well as the relationship between the GT and any humeral defects. While critical and subcritical thresholds guide treatment for the management of anterior instability, such thresholds are less defined in the setting of posterior instability. In either case, patient factors including age and level of sport should also be considered when determining treatment. Future studies should focus on the complex interplay between glenoid and humeral bone loss to establish evidence-based treatment algorithms in patients with both anterior and

posterior glenohumeral instability.

## Acknowledgments

*Funding:* None.

## Footnote

*Provenance and Peer Review:* This article was commissioned by the editorial office, *Annals of Joint* for the series “Bone Loss in Shoulder Instability and Shoulder Arthroplasty”. The article has undergone external peer review.

*Peer Review File:* Available at <https://aoj.amegroups.org/article/view/10.21037/aoj-23-6/prf>

*Conflicts of Interest:* All authors have completed the ICMJE uniform disclosure form (available at <https://aoj.amegroups.org/article/view/10.21037/aoj-23-6/coif>). The series “Bone Loss in Shoulder Instability and Shoulder Arthroplasty” was commissioned by the editorial office without any funding or sponsorship. JDH served as the unpaid Guest Editor for the series. The authors have no other conflicts of interest to declare.

*Ethical Statement:* The authors are accountable for all aspects of the work in ensuring that questions related to the accuracy or integrity of any part of the work are appropriately investigated and resolved.

*Open Access Statement:* This is an Open Access article distributed in accordance with the Creative Commons Attribution-NonCommercial-NoDerivs 4.0 International License (CC BY-NC-ND 4.0), which permits the non-commercial replication and distribution of the article with the strict proviso that no changes or edits are made and the original work is properly cited (including links to both the formal publication through the relevant DOI and the license). See: <https://creativecommons.org/licenses/by-nc-nd/4.0/>.

## References

- Zacchilli MA, Owens BD. Epidemiology of shoulder dislocations presenting to emergency departments in the United States. *J Bone Joint Surg Am* 2010;92:542-9.
- Yiannakopoulos CK, Mataragas E, Antonogiannakis E. A comparison of the spectrum of intra-articular lesions in acute and chronic anterior shoulder instability. *Arthroscopy* 2007;23:985-90.
- Leroux TS, Saltzman BM, Meyer M, et al. The Influence of Evidence-Based Surgical Indications and Techniques on Failure Rates After Arthroscopic Shoulder Stabilization in the Contact or Collision Athlete With Anterior Shoulder Instability. *Am J Sports Med* 2017;45:1218-25.
- Shaha JS, Cook JB, Song DJ, et al. Redefining “Critical” Bone Loss in Shoulder Instability: Functional Outcomes Worsen With “Subcritical” Bone Loss. *Am J Sports Med* 2015;43:1719-25.
- Di Giacomo G, Itoi E, Burkhart SS. Evolving concept of bipolar bone loss and the Hill-Sachs lesion: from “engaging/non-engaging” lesion to “on-track/off-track” lesion. *Arthroscopy* 2014;30:90-8.
- Lo IK, Parten PM, Burkhart SS. The inverted pear glenoid: an indicator of significant glenoid bone loss. *Arthroscopy* 2004;20:169-74.
- Li RT, Kane G, Drummond M, et al. On-Track Lesions with a Small Distance to Dislocation Are Associated with Failure After Arthroscopic Anterior Shoulder Stabilization. *J Bone Joint Surg Am* 2021;103:961-7.
- Li RT, Sheehan A, Wilson K, et al. Decreased Glenoid Retroversion Is a Risk Factor for Failure of Primary Arthroscopic Bankart Repair in Individuals With Subcritical Bone Loss Versus No Bone Loss. *Arthroscopy* 2021;37:1128-33.
- White AE, Patel NK, Hadley CJ, et al. An Algorithmic Approach to the Management of Shoulder Instability. *J Am Acad Orthop Surg Glob Res Rev* 2019;3:e19.00168.
- Rupp MC, Rutledge JC, Quinn PM, et al. Management of Shoulder Instability in Patients with Underlying Hyperlaxity. *Curr Rev Musculoskelet Med* 2023;16:123-44.
- Provencher MT, Midtgaard KS, Owens BD, et al. Diagnosis and Management of Traumatic Anterior Shoulder Instability. *J Am Acad Orthop Surg* 2021;29:e51-61.
- Hasebroock AW, Brinkman J, Foster L, et al. Management of primary anterior shoulder dislocations: a narrative review. *Sports Med Open* 2019;5:31.
- Hughes JD, Vaswani R, Paras TM, et al. Treatment algorithm for recurrent anterior shoulder instability: putting it all together. *Oper Tech Orthop* 2021;31:100862.
- Paxton ES, Dodson CC, Lazarus MD. Shoulder instability in older patients. *Orthop Clin North Am* 2014;45:377-85.
- Romeo AA, Cohen BS, Carreira DS. Traumatic anterior shoulder instability. *Orthop Clin North Am* 2001;32:399-409.
- Cutts S, Prempeh M, Drew S. Anterior shoulder



- dislocation. *Ann R Coll Surg Engl* 2009;91:2-7.
17. Yoshida M, Takenaga T, Chan CK, et al. Increased superior translation following multiple simulated anterior dislocations of the shoulder. *Knee Surg Sports Traumatol Arthrosc* 2023;31:1963-9.
  18. Magee T. Prevalence of HAGL lesions and associated abnormalities on shoulder MR examination. *Skeletal Radiol* 2014;43:307-13.
  19. Garcia GH, Liu JN, Dines DM, et al. Effect of bone loss in anterior shoulder instability. *World J Orthop* 2015;6:421-33.
  20. Anderson MJJ, Mack CD, Herzog MM, et al. Epidemiology of Shoulder Instability in the National Football League. *Orthop J Sports Med* 2021;9:23259671211007743.
  21. Sheehan AJ, Kibler WB, Conway J, et al. Posterior Labral Injury and Glenohumeral Instability in Overhead Athletes: Current Concepts for Diagnosis and Management. *J Am Acad Orthop Surg* 2020;28:628-37.
  22. Burkhart SS, Morgan CD, Kibler WB. The disabled throwing shoulder: spectrum of pathology Part I: pathoanatomy and biomechanics. *Arthroscopy* 2003;19:404-20.
  23. Kibler WB, Kuhn JE, Wilk K, et al. The disabled throwing shoulder: spectrum of pathology-10-year update. *Arthroscopy* 2013;29:141-61.e26.
  24. Owens BD, Campbell SE, Cameron KL. Risk factors for posterior shoulder instability in young athletes. *Am J Sports Med* 2013;41:2645-9.
  25. Beaulieu-Jones BR, Peebles LA, Golijanin P, et al. Characterization of Posterior Glenoid Bone Loss Morphology in Patients With Posterior Shoulder Instability. *Arthroscopy* 2019;35:2777-84.
  26. Mauro CS, McClincy MP, Bradley JP. Effect of Glenoid Version and Width on Outcomes of Arthroscopic Posterior Shoulder Stabilization. *Am J Sports Med* 2016;44:941-7.
  27. Hines A, Cook JB, Shaha JS, et al. Glenoid Bone Loss in Posterior Shoulder Instability: Prevalence and Outcomes in Arthroscopic Treatment. *Am J Sports Med* 2018;46:1053-7.
  28. Hurley ET, Matache BA, Wong I, et al. Anterior Shoulder Instability Part I-Diagnosis, Nonoperative Management, and Bankart Repair-An International Consensus Statement. *Arthroscopy* 2022;38:214-23.e7.
  29. Polyzois I, Dattani R, Gupta R, et al. Traumatic First Time Shoulder Dislocation: Surgery vs Non-Operative Treatment. *Arch Bone Jt Surg* 2016;4:104-8.
  30. Trojan JD, Meyer LE, Edgar CM, et al. Epidemiology of Shoulder Instability Injuries in Collision Collegiate Sports From 2009 to 2014. *Arthroscopy* 2020;36:36-43.
  31. Owens BD, Agel J, Mountcastle SB, et al. Incidence of glenohumeral instability in collegiate athletics. *Am J Sports Med* 2009;37:1750-4.
  32. Owens BD, Dawson L, Burks R, et al. Incidence of shoulder dislocation in the United States military: demographic considerations from a high-risk population. *J Bone Joint Surg Am* 2009;91:791-6.
  33. Kardouni JR, McKinnon CJ, Seitz AL. Incidence of Shoulder Dislocations and the Rate of Recurrent Instability in Soldiers. *Med Sci Sports Exerc* 2016;48:2150-6.
  34. Makhni EC, Tramer JS, Anderson MJJ, et al. Evaluating Bone Loss in Anterior Shoulder Instability. *J Am Acad Orthop Surg* 2022;30:563-72.
  35. Griffith JF, Antonio GE, Yung PS, et al. Prevalence, pattern, and spectrum of glenoid bone loss in anterior shoulder dislocation: CT analysis of 218 patients. *AJR Am J Roentgenol* 2008;190:1247-54.
  36. Kwong CA, Gusnowski EM, Tam KK, et al. Assessment of bone loss in anterior shoulder instability. *Ann Joint* 2017;2:63.
  37. Hegedus EJ, Cook C, Lewis J, et al. Combining orthopedic special tests to improve diagnosis of shoulder pathology. *Phys Ther Sport* 2015;16:87-92.
  38. Galvin JW, Ernat JJ, Waterman BR, et al. The Epidemiology and Natural History of Anterior Shoulder Instability. *Curr Rev Musculoskelet Med* 2017;10:411-24.
  39. Bushnell BD, Creighton RA, Herring MM. The bony apprehension test for instability of the shoulder: a prospective pilot analysis. *Arthroscopy* 2008;24:974-82.
  40. James M, Kwong CA, More KD, et al. Bony Apprehension Test for Identifying Bone Loss in Patients With Traumatic Anterior Shoulder Instability: A Validation Study. *Am J Sports Med* 2022;50:1520-8.
  41. Provencher MT, Bhatia S, Ghodadra NS, et al. Recurrent shoulder instability: current concepts for evaluation and management of glenoid bone loss. *J Bone Joint Surg Am* 2010;92 Suppl 2:133-51.
  42. Provencher MT, Ferrari MB, Sanchez G, et al. Current Treatment Options for Glenohumeral Instability and Bone Loss: A Critical Analysis Review. *JBJS Rev* 2017;5:e6.
  43. Yamamoto N, Itoi E, Abe H, et al. Contact between the glenoid and the humeral head in abduction, external rotation, and horizontal extension: a new concept of glenoid track. *J Shoulder Elbow Surg* 2007;16:649-56.
  44. Omori Y, Yamamoto N, Koishi H, et al. Measurement of the Glenoid Track In Vivo as Investigated by

- 3-Dimensional Motion Analysis Using Open MRI. *Am J Sports Med* 2014;42:1290-5.
45. Rabinowitz J, Friedman R, Eichinger JK. Management of Glenoid Bone Loss with Anterior Shoulder Instability: Indications and Outcomes. *Curr Rev Musculoskelet Med* 2017;10:452-62.
  46. Saliken DJ, Bornes TD, Bouliane MJ, et al. Imaging methods for quantifying glenoid and Hill-Sachs bone loss in traumatic instability of the shoulder: a scoping review. *BMC Musculoskelet Disord* 2015;16:164.
  47. Nakagawa S, Iuchi R, Hanai H, et al. The Development Process of Bipolar Bone Defects From Primary to Recurrent Instability in Shoulders With Traumatic Anterior Instability. *Am J Sports Med* 2019;47:695-703.
  48. Green GL, Arnander M, Pearse E, et al. CT estimation of glenoid bone loss in anterior glenohumeral instability: a systematic review of existing techniques. *Bone Jt Open* 2022;3:114-22.
  49. Bakshi NK, Cibulas GA, Sekiya JK, et al. A Clinical Comparison of Linear- and Surface Area-Based Methods of Measuring Glenoid Bone Loss. *Am J Sports Med* 2018;46:2472-7.
  50. Bois AJ, Fening SD, Polster J, et al. Quantifying glenoid bone loss in anterior shoulder instability: reliability and accuracy of 2-dimensional and 3-dimensional computed tomography measurement techniques. *Am J Sports Med* 2012;40:2569-77.
  51. Baudi P, Righi P, Bolognesi D, et al. How to identify and calculate glenoid bone deficit. *Chir Organi Mov* 2005;90:145-52.
  52. Hachem AI, Molina-Creixell A, Rius X, et al. Comprehensive management of posterior shoulder instability: diagnosis, indications, and technique for arthroscopic bone block augmentation. *EFORT Open Rev* 2022;7:576-86.
  53. Lander ST, Liles JL, Kim BI, et al. Comparison of computed tomography and 3D magnetic resonance imaging in evaluating glenohumeral instability bone loss. *J Shoulder Elbow Surg* 2022;31:2217-24.
  54. Lansdown DA, Cvetanovich GL, Verma NN, et al. Automated 3-Dimensional Magnetic Resonance Imaging Allows for Accurate Evaluation of Glenoid Bone Loss Compared With 3-Dimensional Computed Tomography. *Arthroscopy* 2019;35:734-40.
  55. Sgroi M, Huzurudin H, Ludwig M, et al. MRI Allows Accurate Measurement of Glenoid Bone Loss. *Clin Orthop Relat Res* 2022;480:1731-42.
  56. Gouveia K, Rizvi SFH, Dagher D, et al. Assessing Bone Loss in the Unstable Shoulder: a Scoping Review. *Curr Rev Musculoskelet Med* 2022;15:369-76.
  57. Golijanin P, Peebles L, Arner JW, et al. Advanced 3-Dimensional Characterization of Hill-Sachs Lesions in 100 Anterior Shoulder Instability Patients. *Arthroscopy* 2021;37:3255-61.
  58. Barrow AE, Charles SJ, Issa M, et al. Distance to Dislocation and Recurrent Shoulder Dislocation After Arthroscopic Bankart Repair: Rethinking the Glenoid Track Concept. *Am J Sports Med* 2022;50:3875-80.
  59. Moroder P, Runer A, Kraemer M, et al. Influence of defect size and localization on the engagement of reverse Hill-Sachs lesions. *Am J Sports Med* 2015;43:542-8.
  60. Gombera MM, Sekiya JK. Rotator cuff tear and glenohumeral instability: a systematic review. *Clin Orthop Relat Res* 2014;472:2448-56.
  61. Symanski JS, Subhas N, Babb J, et al. Diagnosis of Superior Labrum Anterior-to-Posterior Tears by Using MR Imaging and MR Arthrography: A Systematic Review and Meta-Analysis. *Radiology* 2017;285:101-13.
  62. Shafiei M, Shomal Zadeh F, Shafiee A, et al. Diagnostic performance of MRA in abduction and external rotation position in the detection of glenoid labral lesions: a systematic review and meta-analysis. *Skeletal Radiol* 2022;51:1611-21.
  63. Boileau P, Villalba M, Héry JY, et al. Risk factors for recurrence of shoulder instability after arthroscopic Bankart repair. *J Bone Joint Surg Am* 2006;88:1755-63.
  64. Shanley E, Thigpen C, Brooks J, et al. Return to Sport as an Outcome Measure for Shoulder Instability: Surprising Findings in Nonoperative Management in a High School Athlete Population. *Am J Sports Med* 2019;47:1062-7.
  65. Yow BG, Dickens JF. In-Season Management of Anterior Shoulder Instability. *Sports Med Arthrosc Rev* 2020;28:132-9.
  66. Burkhart SS, De Beer JF. Traumatic glenohumeral bone defects and their relationship to failure of arthroscopic Bankart repairs: significance of the inverted-pear glenoid and the humeral engaging Hill-Sachs lesion. *Arthroscopy* 2000;16:677-94.
  67. Ahmed I, Ashton F, Robinson CM. Arthroscopic Bankart repair and capsular shift for recurrent anterior shoulder instability: functional outcomes and identification of risk factors for recurrence. *J Bone Joint Surg Am* 2012;94:1308-15.
  68. Balg F, Boileau P. The instability severity index score. A simple pre-operative score to select patients for arthroscopic or open shoulder stabilisation. *J Bone Joint*

- Surg Br 2007;89:1470-7.
69. Dekker TJ, Peebles LA, Bernhardson AS, et al. Limited Predictive Value of the Instability Severity Index Score: Evaluation of 217 Consecutive Cases of Recurrent Anterior Shoulder Instability. *Arthroscopy* 2021;37:1381-91.
  70. Tokish JM, Thigpen CA, Kissenberth MJ, et al. The Nonoperative Instability Severity Index Score (NISIS): A Simple Tool to Guide Operative Versus Nonoperative Treatment of the Unstable Shoulder. *Sports Health* 2020;12:598-602.
  71. Di Giacomo G, Peebles LA, Pugliese M, et al. Glenoid Track Instability Management Score: Radiographic Modification of the Instability Severity Index Score. *Arthroscopy* 2020;36:56-67.
  72. Castagna A, Garofalo R, Conti M, et al. Arthroscopic Bankart repair: Have we finally reached a gold standard? *Knee Surg Sports Traumatol Arthrosc* 2016;24:398-405.
  73. Millett PJ, Braun S. The "bony Bankart bridge" procedure: a new arthroscopic technique for reduction and internal fixation of a bony Bankart lesion. *Arthroscopy* 2009;25:102-5.
  74. Murphy AI, Hurley ET, Hurley DJ, et al. Long-term outcomes of the arthroscopic Bankart repair: a systematic review of studies at 10-year follow-up. *J Shoulder Elbow Surg* 2019;28:2084-9.
  75. Aboalata M, Plath JE, Seppel G, et al. Results of Arthroscopic Bankart Repair for Anterior-Inferior Shoulder Instability at 13-Year Follow-up. *Am J Sports Med* 2017;45:782-7.
  76. Coyner KJ, Arciero RA. Shoulder Instability: Anterior, Posterior, Multidirectional, Arthroscopic Versus Open, Bone Block Procedures. *Sports Med Arthrosc Rev* 2018;26:168-70.
  77. Petrera M, Patella V, Patella S, et al. A meta-analysis of open versus arthroscopic Bankart repair using suture anchors. *Knee Surg Sports Traumatol Arthrosc* 2010;18:1742-7.
  78. Gao B, DeFroda S, Bokshan S, et al. Arthroscopic Versus Open Bankart Repairs in Recurrent Anterior Shoulder Instability: A Systematic Review of the Association Between Publication Date and Postoperative Recurrent Instability in Systematic Reviews. *Arthroscopy* 2020;36:862-71.
  79. Haroun HK, Sobhy MH, Abdelrahman AA. Arthroscopic Bankart repair with remplissage versus Latarjet procedure for management of engaging Hill-Sachs lesions with subcritical glenoid bone loss in traumatic anterior shoulder instability: a systematic review and meta-analysis. *J Shoulder Elbow Surg* 2020;29:2163-74.
  80. Prada C, Al-Mohrej OA, Patel A, et al. Managing Bone Loss in Shoulder Instability-Techniques and Outcomes: a Scoping Review. *Curr Rev Musculoskelet Med* 2021;14:447-61.
  81. Jeon YS, Jeong HY, Lee DK, et al. Borderline Glenoid Bone Defect in Anterior Shoulder Instability: Latarjet Procedure Versus Bankart Repair. *Am J Sports Med* 2018;46:2170-6.
  82. Bessière C, Trojani C, Carles M, et al. The open latarjet procedure is more reliable in terms of shoulder stability than arthroscopic bankart repair. *Clin Orthop Relat Res* 2014;472:2345-51.
  83. Pasqualini I, De Cicco FL, Tanoira I, et al. Classic Versus Congruent-Arc Latarjet Procedures. *Arthroscopy* 2023;39:8-10.
  84. Hurley ET, Jamal MS, Ali ZS, et al. Long-term outcomes of the Latarjet procedure for anterior shoulder instability: a systematic review of studies at 10-year follow-up. *J Shoulder Elbow Surg* 2019;28:e33-9.
  85. Hurley ET, Montgomery C, Jamal MS, et al. Return to Play After the Latarjet Procedure for Anterior Shoulder Instability: A Systematic Review. *Am J Sports Med* 2019;47:3002-8.
  86. Provencher MT, Frank RM, Leclere LE, et al. The Hill-Sachs lesion: diagnosis, classification, and management. *J Am Acad Orthop Surg* 2012;20:242-52.
  87. Hurley ET, Toale JP, Davey MS, et al. Remplissage for anterior shoulder instability with Hill-Sachs lesions: a systematic review and meta-analysis. *J Shoulder Elbow Surg* 2020;29:2487-94.
  88. Yang JS, Mehran N, Mazzocca AD, et al. Remplissage Versus Modified Latarjet for Off-Track Hill-Sachs Lesions With Subcritical Glenoid Bone Loss. *Am J Sports Med* 2018;46:1885-91.
  89. Gouveia K, Abidi SK, Shamshoon S, et al. Arthroscopic Bankart Repair With Remplissage in Comparison to Bone Block Augmentation for Anterior Shoulder Instability With Bipolar Bone Loss: A Systematic Review. *Arthroscopy* 2021;37:706-17.
  90. Horinek JL, Menendez ME, Narbona P, et al. Arthroscopic Bankart Repair With Remplissage as an Alternative to Latarjet for Anterior Glenohumeral Instability With More Than 15% Glenoid Bone Loss. *Orthop J Sports Med* 2022;10:23259671221142257.
  91. Tang J, Xu C, Zhao J. Arthroscopic Bone Grafting of the Humeral Head for Treatment of a Deep Hill-Sachs

- Lesion. *Arthrosc Tech* 2017;6:e1653-9.
92. Ratner D, Backes J, Tokish JM. Arthroscopic Reduction and Balloon HumeroPlasty in the Treatment of Acute Hill-Sachs Lesions. *Arthrosc Tech* 2016;5:e1327-32.
  93. Saltzman BM, Riboh JC, Cole BJ, et al. Humeral Head Reconstruction With Osteochondral Allograft Transplantation. *Arthroscopy* 2015;31:1827-34.
  94. Longo UG, Loppini M, Rizzello G, et al. Latarjet, Bristow, and Eden-Hybinette procedures for anterior shoulder dislocation: systematic review and quantitative synthesis of the literature. *Arthroscopy* 2014;30:1184-211.
  95. Warner JJ, Gill TJ, O'hollerhan JD, et al. Anatomical glenoid reconstruction for recurrent anterior glenohumeral instability with glenoid deficiency using an autogenous tricortical iliac crest bone graft. *Am J Sports Med* 2006;34:205-12.
  96. Moroder P, Plachel F, Becker J, et al. Clinical and Radiological Long-term Results After Implant-Free, Autologous, Iliac Crest Bone Graft Procedure for the Treatment of Anterior Shoulder Instability. *Am J Sports Med* 2018;46:2975-80.
  97. Moroder P, Schulz E, Wierer G, et al. Neer Award 2019: Latarjet procedure vs. iliac crest bone graft transfer for treatment of anterior shoulder instability with glenoid bone loss: a prospective randomized trial. *J Shoulder Elbow Surg* 2019;28:1298-307.
  98. Amar E, Konstantinidis G, Coady C, et al. Arthroscopic Treatment of Shoulder Instability With Glenoid Bone Loss Using Distal Tibial Allograft Augmentation: Safety Profile and Short-Term Radiological Outcomes. *Orthop J Sports Med* 2018;6:2325967118774507.
  99. Wong I, John R, Ma J, et al. Arthroscopic Anatomic Glenoid Reconstruction Using Distal Tibial Allograft for Recurrent Anterior Shoulder Instability: Clinical and Radiographic Outcomes. *Am J Sports Med* 2020;48:3316-21.
  100. Gilat R, Haunschild ED, Lavoie-Gagne OZ, et al. Outcomes of the Latarjet Procedure Versus Free Bone Block Procedures for Anterior Shoulder Instability: A Systematic Review and Meta-analysis. *Am J Sports Med* 2021;49:805-16.
  101. Gilat R, Wong SE, Lavoie-Gagne O, et al. Outcomes are comparable using free bone block autografts versus allografts for the management of anterior shoulder instability with glenoid bone loss: a systematic review and meta-analysis of "The Non-Latarjet". *Knee Surg Sports Traumatol Arthrosc* 2021;29:2159-74.
  102. DeLong JM, Jiang K, Bradley JP. Posterior Instability of the Shoulder: A Systematic Review and Meta-analysis of Clinical Outcomes. *Am J Sports Med* 2015;43:1805-17.
  103. Chan S, O'Brien LK, Waterman BR, et al. Low Risk of Recurrence After Posterior Labral Repair of the Shoulder in a High-Risk United States Military Population. *Arthrosc Sports Med Rehabil* 2020;2:e47-52.
  104. Bradley JP, Arner JW, Jayakumar S, et al. Risk Factors and Outcomes of Revision Arthroscopic Posterior Shoulder Capsulolabral Repair. *Am J Sports Med* 2018;46:2457-65.
  105. Arner JW, Ruzbarsky JJ, Midtgaard K, et al. Defining Critical Glenoid Bone Loss in Posterior Shoulder Capsulolabral Repair. *Am J Sports Med* 2021;49:2013-9.
  106. Di Giacomo G, Piscitelli L, Pugliese M. The role of bone in glenohumeral stability. *EFORT Open Rev* 2018;3:632-40.
  107. Moroder P, Scheibel M. ABC classification of posterior shoulder instability. *Obere Extrem* 2017;12:66-74.
  108. Camenzind RS, Martin Becerra J, Gossing L, et al. Acceptable Long-Term Outcomes of Arthroscopic Bone Grafting for Recurrent Posterior Shoulder Instability: Minimum Follow-Up of 5 Years. *Arthroscopy* 2021;37:816-23.
  109. Cerciello S, Visonà E, Morris BJ, et al. Bone block procedures in posterior shoulder instability. *Knee Surg Sports Traumatol Arthrosc* 2016;24:604-11.
  110. Cognetti DJ, Hughes JD, Kay J, et al. Bone Block Augmentation of the Posterior Glenoid for Recurrent Posterior Shoulder Instability Is Associated With High Rates of Clinical Failure: A Systematic Review. *Arthroscopy* 2022;38:551-63.e5.
  111. Eichinger JK, Galvin JW, Grassbaugh JA, et al. Glenoid Dysplasia: Pathophysiology, Diagnosis, and Management. *J Bone Joint Surg Am* 2016;98:958-68.
  112. Ortmaier R, Moroder P, Hirzinger C, et al. Posterior open wedge osteotomy of the scapula neck for the treatment of advanced shoulder osteoarthritis with posterior head migration in young patients. *J Shoulder Elbow Surg* 2017;26:1278-86.
  113. Ernstbrunner L, Hüller T, Waltenspül M, et al. Posterior Open-wedge Osteotomy and Glenoid Concavity Reconstruction Using an Implant-free, J-shaped Iliac Crest Bone Graft in Atraumatic Posterior Instability with Pathologic Glenoid Retroversion and Dysplasia: A Preliminary Report. *Clin Orthop Relat Res* 2021;479:1995-2005.
  114. Servien E, Walch G, Cortes ZE, et al. Posterior bone block procedure for posterior shoulder instability. *Knee Surg Sports Traumatol Arthrosc* 2007;15:1130-6.



115. Hachem AI, Bascones KR, Costa D'O G, et al. Arthroscopic Knotless Subscapularis Bridge Technique for Reverse Hill-Sachs Lesion With Posterior Shoulder Instability. *Arthrosc Tech* 2021;10:e103-16.
116. Arauz S, González-Martín D, Quiroga M, et al. Arthroscopic Modified McLaughlin Procedure and Remplissage for Treatment of Simultaneous Reverse Hill-Sachs and Hill-Sachs Lesions. *Arthrosc Tech* 2022;11:e1473-8.
117. Romano AM, Edwards TB, Nastrucci G, et al. Arthroscopic reduction and subscapularis remplissage (ARR) of chronic posterior locked shoulder dislocation leads to optimized outcomes and low rate of complications. *Knee Surg Sports Traumatol Arthrosc* 2021;29:2348-55.
118. Lavender CD, Hanzlik SR, Pearson SE, et al. Arthroscopic Reverse Remplissage for Posterior Instability. *Arthrosc Tech* 2016;5:e43-7.
119. Rhee YG, Ha JH, Cho NS. Anterior shoulder stabilization in collision athletes: arthroscopic versus open Bankart repair. *Am J Sports Med* 2006;34:979-85.
120. Zimmermann SM, Scheyerer MJ, Farshad M, et al. Long-Term Restoration of Anterior Shoulder Stability: A Retrospective Analysis of Arthroscopic Bankart Repair Versus Open Latarjet Procedure. *J Bone Joint Surg Am* 2016;98:1954-61.

doi: 10.21037/aoj-23-6

**Cite this article as:** Keeling LE, Wagala N, Ryan PM, Gilbert R, Hughes JD. Bone loss in shoulder instability: putting it all together. *Ann Joint* 2023;8:27.