

Moyamoya syndrome associated with neurofibromatosis type 1 in a pediatric patient*

Natália Battisti Serafini¹
Alanna Santoro Vinhas³

Cássio Battisti Serafini²
Marcio Barbosa Godinho⁴

DOI: <http://dx.doi.org/10.1590/abd1806-4841.20176829>

Abstract: Neurofibromatosis type 1 is a multisystem genetic disease of autosomal dominant transmission that reveals important cutaneous manifestations such as café-au-lait spots, multiple neurofibromas, and ephelides in skin fold areas, as well as hamartomatous lesions in the eyes, bones, glands, and central nervous system. Moyamoya disease is a rare progressive vaso-occlusive disorder that occurs with important ischemic cerebrovascular events. Despite the rarity of this association in childhood, children diagnosed with neurofibromatosis type 1 and focal neurologic symptoms should be investigated for moyamoya syndrome. The present study reports the case of a pediatric patient with a rapidly progressive cerebrovascular accident and a late diagnosis of Neurofibromatosis type 1 associated with moyamoya disease.

Keywords: Clinical diagnosis; Moyamoya disease; Neurofibromatosis 1

INTRODUCTION

Neurofibromatosis type 1 (NF-1), or von Recklinghausen's disease, is a multisystem genetic disease of autosomal dominant transmission. It is caused by a decrease in the production of the neurofibromin protein due to mutations in the NF1 gene, located on the long arm of chromosome 17 (17q11.2), resulting in a lack of control of cell growth and division. It presents with important cutaneous manifestations, such as café-au-lait spots, multiple neurofibromas, and ephelides in skin folds, as well as hamartomatous lesions in the eyes, bones, glands, and central nervous system (CNS). The incidence of NF-1 is 1/2,500 live births, regardless of race and gender. It is estimated that there are 80,000 cases of NF-1 in Brazil and 1.5 million cases worldwide.¹

Moyamoya disease (MMD) is a progressive vaso-occlusive disorder, most frequently observed in the Japanese population, with an estimated incidence of 1 case per million people per year. The frequency is higher among children under the age of 10. Its etiology is still unknown.² MMD involves stenosis of the terminal portions of the internal carotid arteries (ICA), their branches, and the main trunk of the anterior cerebral arteries and the middle cerebral arteries (MCA) due to a defect in the intima layer. Over time, the blockages result in small-caliber, inefficient vascular neoformations, generating a characteristic diagnostic pattern on cerebral angiography similar to a "hazy puff of smoke" (moyamoya, in Japanese).^{3,4}

The association between NF-1 and vascular changes is not uncommon. However, its association with specific cerebrovascular diseases, such as MMD, is rarely observed.^{5,6} The present study reports the case of a non-Asian preschooler with ischemic and rapidly progressive cerebrovascular accident (CVA), compatible with MMD, associated with a late diagnosis of NF-1.

Received on 15.12.2016.

Approved by the Advisory Board and accepted for publication on 25.03.2017.

* Work performed at Hospital Federal de Bonsucesso (HFB) – Rio de Janeiro (RJ), Brazil

Financial support: none.

Conflict of interest: none.

¹ Dermatologist – Rio de Janeiro (RJ), Brazil

² Tropical Dermatology Service at Hospital Central do Exército (HCE) – Rio de Janeiro (RJ), Brazil

³ Dermatology Service at Hospital Federal de Bonsucesso (HFB) – Rio de Janeiro (RJ), Brazil

⁴ Department of Pediatrics at Hospital Federal de Bonsucesso (HFB) – Rio de Janeiro (RJ), Brazil

©2017 by Anais Brasileiros de Dermatologia

CASE REPORT

We report the case of a two-year-old Caucasian male patient from Rio de Janeiro, who presented with a tonic-clonic convulsive seizure, right brachio-crural hemiplegia, ataxia, aphasia, and sudden-onset dysphagia. He was hospitalized for investigation. Computed tomography and nuclear magnetic resonance of the skull showed signs of left parietal-occipital ischemia (Figure 1). His family history revealed a diagnosis of NF-1 in a first-degree relative. On clinical examination, we observed several coffee-au-lait spots on the trunk, back, and extremities, with no ophthalmological alterations (Figures 2 and 3). We ruled out causes of thrombophilia. Triglyceride levels were within normal limits. An angioresonance of the head revealed a significantly reduced caliber of the right ICA, with no flow in its supraclinoid segment. We also observed a lack of flow in the left MCA, with the formation of multiple collateral vessels, compatible with MMD diagnosis and the patient's clinical presentation (Figure 4). The child showed significant spontaneous improvement of the neurological condition with persistence of small focal motor deficits during the period of hospitalization. He was referred to a reference neurosurgery service for surgical planning. The patient is being followed up.

DISCUSSION

It is known that NF-1 occurs most frequently during childhood. Its diagnosis is based on clinical criteria established by the National Institutes of Health (NIH).⁷ The presence of two or more of the following findings confirms its diagnosis: I) six or more coffee-au-lait spots with a diameter greater than 5 mm in children and greater than 15 mm in adults; II) two or more neurofibromas of any type or one plexiform neurofibroma; III) freckle-like lesions in the axillary or inguinal regions; IV) optic nerve glioma; V) two or more Lisch nodules (iris hamartomas); VI) sphenoid wing dysplasia or cortical thinning of the long bones, with or without pseudarthrosis; and VII) a first-degree relative diagnosed with NF-1 following these criteria. Our patient fulfilled two of the diagnostic criteria, confirming the diagnosis of NF-1.

MMD is a severe disease that may evolve with an unfavorable neurological course. In patients with NF-1 associated with MMD, early diagnosis and appropriate surgical treatment are of extreme importance both to improve cerebral hemodynamics and to reduce the incidence of new ischemic events.⁸

The association of MMD with other diseases has also been described, such as renovascular disease, aneurysms of the circle of Willis, arteriovenous malformation, sickle cell anemia, neurofibromatosis, polyarteritis nodosa, Down syndrome, and Fanconi anemia. Some authors use the term moyamoya "syndrome" when

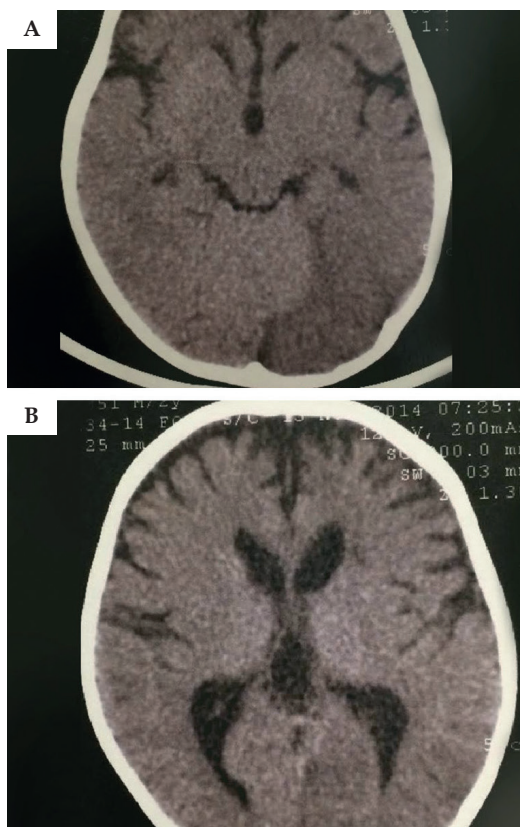


FIGURE 1: Computed tomography of the skull: left parietal-occipital hypodensity caused by sequelae of an ischemic insult evidenced in figures A and B

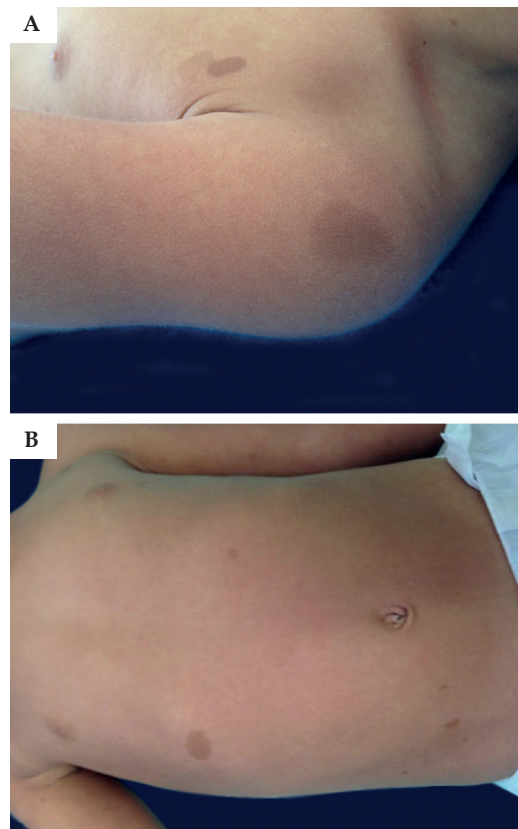


FIGURE 2: Coffee-au-lait spots on the left shoulder A and trunk B

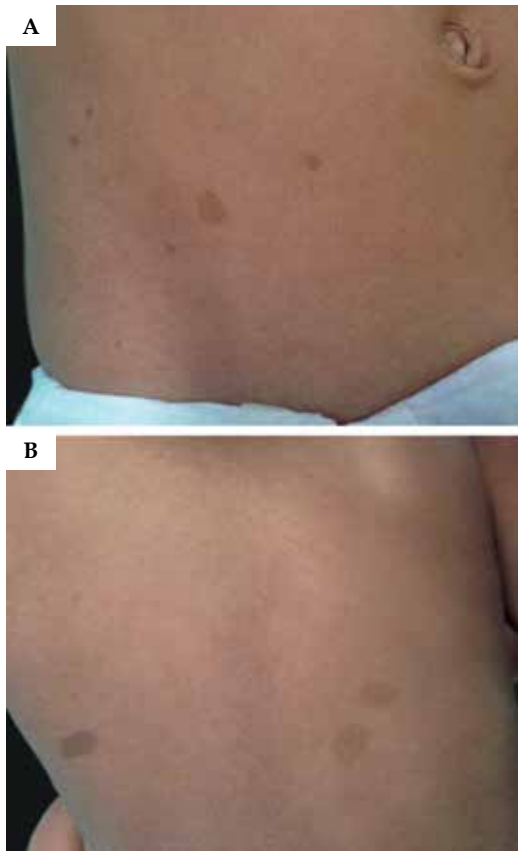


FIGURE 3: Manchas café-au-lait na fossa ilíaca direita **A** e no dorso **B**. Coffee-au-lait spots on the right iliac fossa **A** and on the back **B**

characteristic cerebrovascular changes occur associated with one of these diseases. However, when they occur isolatedly and idiopathically, the term adopted is moyamoya disease.^{1,4} Other authors consider that the characteristic arteriographic changes are bilateral in patients with moyamoya disease, while they are unilateral in moyamoya syndrome. The term “moyamoya”, when used alone, refers only to arteriographic changes, regardless of the cause.⁴ Therefore, we defined the present case, according to this classification, as moyamoya syndrome.

Despite the proximity of the NF1 gene (17q11.2) to the familial moyamoya disease gene (17q25), the participation of the NF1 gene in the occurrence of MMD is controversial.⁸ As observed in this case, the clinical characteristics in children mainly involves ischemic events such as transient ischemic attacks and ischemic strokes, as

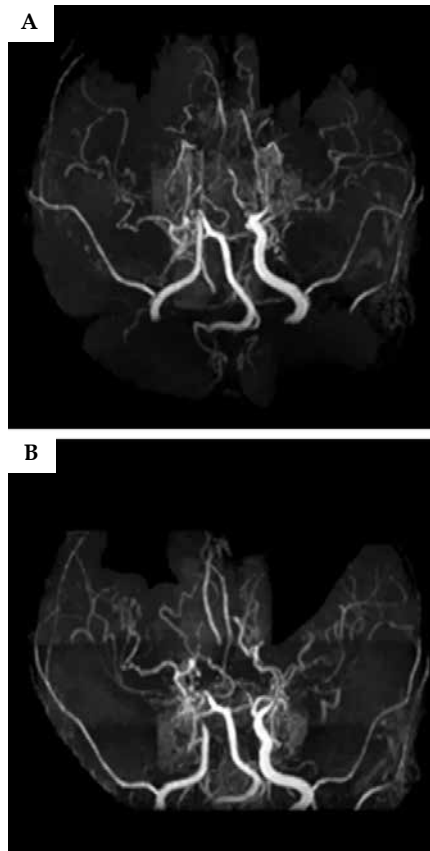


FIGURE 4: Angioresonance of the head: reduced caliber of the right internal carotid and left middle cerebral arteries and presence of neovascularization and numerous collateral vessels, shown in figures **A** and **B**

well as focal seizures with headache and intracranial hemorrhage. In adults, events tend to be hemorrhagic.^{3,8}

In NF-1, most patients with vascular lesions linked to the disease itself are asymptomatic. Present symptoms include paraesthesia, headache, status epilepticus, hemianopsia, nystagmus, aphasia, dysphasia, and borderline mental functioning.^{8,9}

The treatment of choice for patients with MMD is still surgical intervention, especially surgical revascularization, which aims to increase blood flow to the cortex hypoperfused by occlusions.^{4,8,10}

Although the association described herein is unusual, MMD is a potentially severe condition with a reserved neurological course of prognosis. The hypothesis of this association should be considered in patients with NF-1 who present with focal neurological symptoms, mainly because these can be confused with the neurological manifestations related to this disease. Thus, early therapy is essential to avoid or minimize irreversible sequelae. □

REFERENCES

1. Darrigo Jr LG, Geller M, Bonalumi Filho A, Azulay DR. Prevalence of plexiform neurofibroma in children and adolescents with type I neurofibromatosis. *J Pediatr (Rio J)*. 2007;83:571-3.
2. Farrugia M, Howlett DC, Saks AM. Moyamoya disease. *Postgrad Med J*. 1997;73:549-52.
3. Adamo Junior J, Paradela MVDH, Horigushi M. Doença cerebrovascular oclusiva crônica (moyamoya): relato de caso. *Arq Neuro-Psiquiatr*. 2001;59:435-9.
4. Scott RM, Smith ER. Moyamoya Disease and Moyamoya Syndrome. *N Engl J Med*. 2009;360(12):1226-37.
5. Veeravagu A, Guzman R, Patil CG, Hou LC, Lee M, Steinberg GK. Moyamoya disease in pediatric patients: outcomes of neurosurgical interventions. *Neurosurg Focus*. 2008;24:E16.
6. Koc F, Yerdelen D, Koc Z. Neurofibromatosis type 1 association with moyamoya disease. *Int J Neurosci*. 2008;118:1157-63.
7. Neurofibromatosis. *Natl Inst Health Consens Dev Conf Consens Statement*. 1987;6:1-7.
8. Vargiami E, Sapountzi E, Samakovitis D, Batziou S, Kyriazi M, Anastasiou A, et al. Moyamoya syndrome and neurofibromatosis type 1. *Ital J Pediatr*. 2014;40:59.
9. Pascual-Castroviejo I, Pascual-Pascual SI, Velázquez R, Víaño J, Martínez V. Moyamoya disease: follow-up of 12 patients. *Neurologia*. 2006;21:695-703.
10. Tan RM, Chng SM, Seow WT, Wong J, Lim CC. 'Moya' than meets the eye: neurofibromatosis type 1 associated with Moyamoya syndrome. *Singapore Med J*. 2008;49:e107-9.

*MAILING ADDRESS:**Cássio Battisti Serafini**Av. Londres, 616**Bonsucesso**21041-030 Rio de Janeiro, RJ – Brazil**E-mail: cassiobserafini@gmail.com*