



LBBAP in patients with normal intrinsic QRS duration: Electrical and mechanical characteristics

Shaoxian Wang MD^{1,*}  | Rongfang Lan MD^{2,*} | Ning Zhang MD² | Jia Zheng MD²  | Yuan Gao MD¹ | Jian Bai MD² | Xiang Wu MD² | Xinyue Xu MD¹ | Tianqi Wang MD¹ | Wei Xu MD^{1,2}

¹ Department of Cardiology, Nanjing Drum Tower Hospital, Clinical College of Nanjing Medical University, Nanjing, China

² Department of Cardiology, Nanjing Drum Tower Hospital, The Affiliated Hospital of Nanjing University, Nanjing, China

Correspondence

Wei Xu, MD, Nanjing Drum Tower Hospital, No. 321, Zhongshan Road, Gulou District, Nanjing 210008, Jiangsu Province, China.
Email: 13390900868@163.com

*These authors contributed equally to this work.

Abstract

Background: Left bundle branch area pacing (LBBAP) is an innovative pacing technology, which needs further study.

Methods: Seventy LBBAP patients with intrinsic QRS duration (QRSd) less than 120 ms were consecutively enrolled in our center. According to whether the left bundle branch potential (LBBp) was recorded or not, the patients were divided into the potential positive group (LBBAP+) and the potential negative group (LBBAP-). Electrocardiographic and echocardiographic parameters were used to evaluate electrical and mechanical characteristics. Lead parameters and complications were followed-up.

Results: There were 52 patients in LBBAP+ and 18 patients in LBBAP-. The QRSd and the left ventricular activation time (LVAT) were wider after LBBAP. QRSd showed no significant difference between LBBAP+ and LBBAP-. LVAT was significantly shorter in LBBAP+ than in LBBAP-. Frontal QRS axis shifted leftward and the V1 morphologies changed after LBBAP. QRS axis and V1 morphologies showed no significant differences between two groups. Paced R-wave transition moved forward compared with intrinsic R-wave transition in both groups. Peak systolic strain of left ventricle (LVPSS) increased, and peak systolic dispersion of left ventricle (LVPSSD) did not change significantly after LBBAP. Systolic and diastolic function as well as mechanical synchronism had no significant differences between two groups. LBBAP had great pacing parameters.

Conclusion: LBBAP changes electrical and mechanical characteristics and has good safety in patients with normal intrinsic QRSd. LBBAP+ and LBBAP- show no significant differences in mechanical synchronization and interventricular electrical synchronization. The LBBAP+ shows better left ventricular electrical synchronicity.

KEYWORDS

electrocardiogram, left bundle branch, potential

This is an open access article under the terms of the [Creative Commons Attribution-NonCommercial](https://creativecommons.org/licenses/by-nc/4.0/) License, which permits use, distribution and reproduction in any medium, provided the original work is properly cited and is not used for commercial purposes.

© 2020 The Authors. *Pacing and Clinical Electrophysiology* published by Wiley Periodicals LLC

1 | INTRODUCTION

With the development of pacing technology, researches on physiological pacing have made some achievements. Heart failure (HF) patients with left bundle branch block (LBBB) can benefit from the cardiac resynchronization therapy (CRT),¹ but the rate of non-response to CRT is 30-40%.² His bundle pacing (HBP) can correct bundle branch block³ and improve the electrical and mechanical synchronization of the patients with HF.^{4,5} However, the application of HBP is limited due to its rising thresholds and its high risk of lead revision.^{6,7} Left bundle branch area pacing (LBBAP) is a newly developed technology which has many advantages. Small sample size studies show that the success rate of LBBAP is high, the pacing parameters are stable, and LBBAP has broad application prospects.^{8,9} However, in previous LBBAP studies, the evidences of the capture of the left bundle branch (LBB) conduction system are nonuniform,¹⁰ and LBBAP shows different electrical characteristics among different patients.¹¹ The left bundle branch potential (LBBp) is mentioned as the evidence of LBB capture in many literatures. However, during the LBBAP procedure, except for the patients with LBBB, some patients with normal intrinsic QRS duration (QRSd) cannot record LBBp.¹² Whether the absence of LBBp will affect the pacing characteristics of LBBAP or not is still ambiguous. Grouped by recording LBBp or not, our center studied the LBBAP in patients with normal intrinsic QRSd, so as to thoroughly understand the electrical and mechanical characteristics of the LBBAP.

2 | METHODS

2.1 | Study population

All the patients who successfully received LBBAP in our center from November 2017 to August 2019 and met all the inclusion, and the exclusion criteria were involved in our study. The inclusion criteria for patients were: (a) intrinsic QRSd <120 ms; (b) electrocardiogram showed right bundle branch block pattern (R' wave should be seen in lead V1, showing qR or rSR') during unipolar pacing. Patients with intrinsic QRSd >120 ms were excluded. All the patients who received LBBAP have signed the written informed consent and this clinical study was approved by the scientific ethics committee of our hospital.

2.2 | LBBAP implantation

The anesthetized patients were operated on in the right anterior oblique (RAO) 30° position. C315 HIS sheath (Medtronic Inc.) and 3830 pacing lead (Medtronic Inc.) were inserted after the axillary vein was punctured. To determine the target region, C315 sheath and 3830 pacing lead should find His-bundle (HIS) region anatomically. Then the tip of 3830 lead was advanced through C315 sheath and used to map HIS potential (HISp). The target region was the site where HISp was recorded clearly. When repeated HISp mapping was not successful, it was changed to pacing mapping to find the target region. The operator should find the region that the pacing pattern is similar to its intrinsic QRS morphology during unipolar pacing. After labeling the target

region, the sheath and the lead were moved forward 1-2 cm from this region towards apex direction. When the 3830 lead was located on the right side of the interventricular septum, lead V1 was in the shape of "W" (usually with the notch at the bottom during pacing). The lead was then screwed in this site. The paced QRS pattern and lead impedance should be monitored every 2-3 rotations during clockwise screwing the lead. When the R' wave can be seen in the lead V1 and the impedance no longer increased or had a downward trend, the lead rotation should be stopped. At the left anterior oblique 45° position, the contrast was injected to determine the depth of the pacing lead in the septum. During implantation, the LBBp was usually recorded, and 12-lead electrocardiogram (ECG) on the body surface was continuously recorded on Bard LabSystem PRO EP Recording System. After the lead was implanted, the threshold test should be carried out from 10 V to lose capture at unipolar pacing, bipolar pacing, and ring pacing.

2.3 | Data collection

General information of patients was collected. The 12-lead ECG was analyzed off-line using the digital caliper of the Bard LabSystem PRO EP Recording System by two experienced specialists. The QRSd was measured at intrinsic status, endocardial status (3830 lead initially located on the right side of the interventricular septum), unipolar pacing status (high output at 10V @ 0.4 ms and low output at threshold), and bipolar pacing status (programmed output at 3.5 V @ 0.4 ms). Ventricular pacing signal to peak of R' wave in lead V5 was measured as paced left ventricular activation time (LVAT). The beginning of QRS wave to the peak of R' wave in lead V5 was measured as basic LVAT. The frontal QRS axis needed to calculate the net amplitude in lead I and AVF with the following formula: $\text{axis} = 57.3 \times \text{ATAN}(\text{AVF} / \text{I})$. The formula should be corrected by adding 180° to the results if the net QRS amplitude of lead I was negative. The R-wave transition in precordial leads was the lead interval where the amplitude ratio of R wave and S wave is 0.9-1.1. The unipolar paced morphology of lead V1 at 10 V @ 0.4 ms and the main QRS wave directions of lead II, III, and AVF at unipolar paced 10 V @ 0.4 ms were recorded. Each of the specialists measured the ECG three times independently. The data were summarized by the third specialist, and the averaged values were the final results.

In order to investigate the mechanical characteristics, conventional echocardiography, Doppler echocardiography, and two-dimensional speckle-tracking echocardiography were performed one week after the operation by an experienced echocardiographer in intrinsic status and LBBAP status. High quality images were then obtained and stored for further study. Considerations for echocardiography preparation are shown as follows. In LBBAP status, the LBBAP lead (ventricular lead) should be set in bipolar paced polarity as well as the 3.5 V amplitude.

In patients with sinus rhythm, the pacemakers were programmed in the DDD mode with paced AV 100 ms and sensed AV 50 ms in LBBAP status. In patients with atrial fibrillation, the pacemakers were programmed in the VVI mode. The lower rate of the pacemaker was routinely set at 75 beats per minute (bpm) and can be adjusted up to 90 bpm against actual situations in LBBAP status. To avoid fusion wave, the patients should take surface ECG to make sure the morphologies

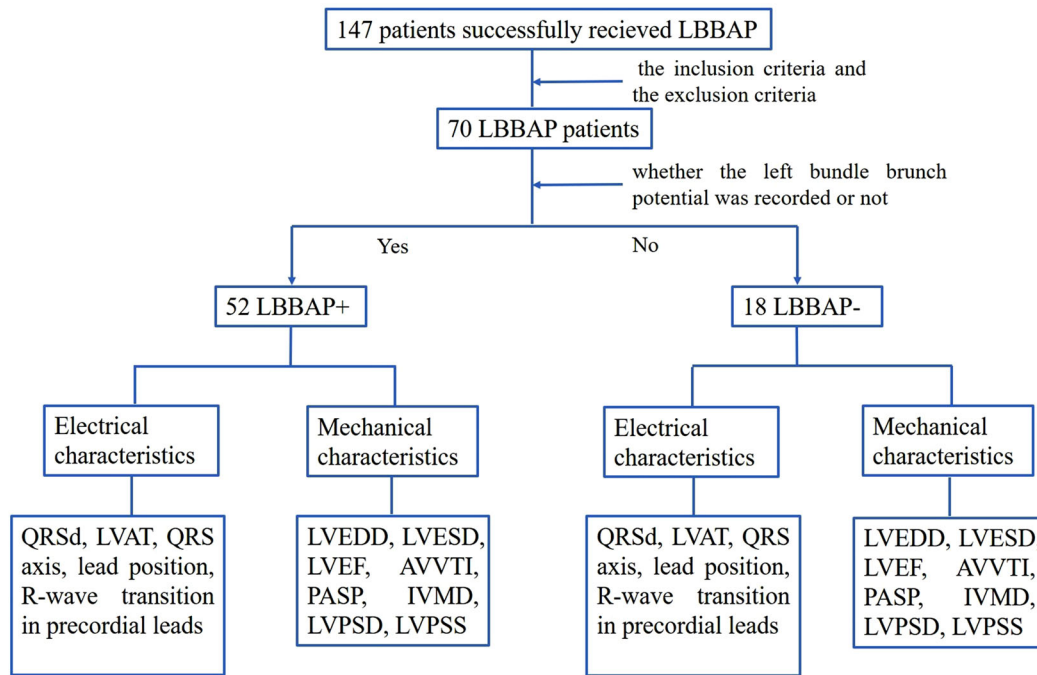


FIGURE 1 A flow diagram of data collection

Abbreviations: AVVTI, aortic valvular velocity time integral; IVMD, interventricular mechanical delay; LBBAP+, patients with left bundle branch potential; LBBAP–, patients without left bundle branch potential; LVAT, activation time of left ventricle; LVEF, ejection fraction of left ventricle; LVEDD, left ventricular end-diastolic diameter; LVESD, left ventricular end-systolic diameter; LVPSD, peak systolic dispersion of left ventricle; LVPSS, left ventricular peak systolic strain; PASP, pulmonary artery systolic pressure; QRSd, QRS duration [Color figure can be viewed at wileyonlinelibrary.com]

of QRS wave in LBBAP status were same as the morphologies of QRS wave in VVI mode at bipolar 3.5 V pacing before obtaining the echocardiographic parameters. The stored echocardiographic images were analyzed by the experienced echocardiographer. The data were verified by a second echocardiographic specialist. The averaged values were the final results. Left ventricular end-diastolic diameter (LVEDD), Left ventricular end-systolic diameter (LVESD), the ejection fraction of left ventricle (LVEF), and aortic valvular velocity time integral (AVVTI) were used to reflect the diastolic and systolic function of the left ventricle. Interventricular mechanical delay (IVMD) reflected mechanical synchronization between left and right ventricles. Peak systolic dispersion of left ventricle (LVPSD) and peak systolic strain of left ventricle (LVPSS) were obtained by automated function image (AFI) technique and showed systolic synchronism and systolic function of the left ventricle.

Lead parameters and complications were followed up immediately, 3 months, 6 months, and 12 months after the LBBAP operation.

2.4 | Statistical analysis

SPSS 24.0 was used for data analysis in our study. The Shapiro-Wilk test checked the normality. Continuous variables were analyzed by the *t*-test and were reported as mean \pm standard deviation. Classified variables were analyzed by the chi-square test, Fisher's exact test, and

Wilcoxon signed-rank test and were presented as percentages or frequencies. The intraclass correlation coefficient (ICC) was used to evaluate the inter-observer reliability. *P* value $<.05$ was considered as statistically significant.

3 | RESULTS

3.1 | General information

A total of 147 patients successfully received LBBAP in our center from November 2017 to August 2019. Among them, 70 patients met all the inclusion criteria and the exclusion criteria (Figure 1). There were 52 patients in LBBAP+ and 18 patients in LBBAP–. Table 1 shows the general information of these patients. The baseline characteristics of the two groups in electrocardiogram and echocardiography had no significant differences.

3.2 | Intraoperative information

Table 2 shows the intraoperative information in detail. The LBBp was recorded in 58 of 70 patients (74.29%) during the operation. The width from the starting of the LBBp to the starting of the QRS wave was 19.56 ± 8.01 ms. During the bipolar paced threshold test, the morphology of lead V1 changed from QS to qR/rSR' when the voltage

TABLE 1 Baseline information in LBBAP+ and LBBAP–

Parameters	LBBAP+ (n = 52)	LBBAP– (n = 18)	P Value
Clinical characteristics			
Male, n (%)	18 (34.6)	8 (44.4)	.457
Age (years)	66.42 ± 12.87	70.28 ± 9.34	.248
Diabetes, n (%)	10 (19.2)	9 (50)	.175
Hypertension, n (%)	34 (65.4)	13 (72.2)	.594
CAD, n (%)	9 (17.3)	2 (11.1)	.805
Paroxysmal AF, n (%)	11 (21.2)	4 (22.2)	1.000
Persistent AF, n (%)	14 (26.9)	4 (22.2)	.936
Lead extraction, n (%)	5 (9.6)	6 (33.3)	.405
Indications for pacemaker			
SN dysfunction, n (%)	17 (32.7)	4 (22.2)	.403
AF with long intervals, n (%)	3 (5.8)	0 (0)	.564
AF with a slow ventricular rate, n (%)	4 (7.7)	2 (11.1)	.643
AVB, n (%)	31 (59.6)	14 (77.8)	.166
Electrocardiographic characteristics			
QRSd (ms)	92.81 ± 8.85	96.28 ± 10.44	.176
LVAT (ms)	42.00 ± 5.98	43.19 ± 11.55	.578
Self QRS axis (°)	18.66 ± 35.23	25.74 ± 27.18	.441
Echocardiographic characteristics			
LVEDD (cm)	5.19 ± 0.47	5.00 ± 0.46	.178
LVESD (cm)	3.70 ± 0.50	3.47 ± 0.35	.100
LVEF (%)	55.03 ± 7.03	55.70 ± 5.75	.730
AVVTI (cm)	26.51 ± 5.43	25.70 ± 5.03	.607
PASP (mm Hg)	35.39 ± 5.78	33.76 ± 7.39	.387
IVMD (ms)	6.97 ± 12.25	10.05 ± 11.46	.387
LVPSD (ms)	43.91 ± 9.24	45.26 ± 10.76	.640
LVPSS (%)	–19.32 ± 1.95	–18.81 ± 2.48	.418

Abbreviations: AF, atrial fibrillation; AVB, atrioventricular block; AVVTI, aortic valvular velocity time integral; CAD, coronary artery disease; IVMD, interventricular mechanical delay; LBBAP+, patients with left bundle branch potential; LBBAP–, patients without left bundle branch potential; LVAT, activation time of left ventricle; LVEDD, left ventricular end-diastolic diameter; LVEF, ejection fraction of left ventricle; LVESD, left ventricular end-systolic diameter; LVPSD, peak systolic dispersion of left ventricle; LVPSS, left ventricular peak systolic strain; PASP, pulmonary artery systolic pressure; QRSd, QRS duration; SN, sinus node.

decreased, indicating the loss capture of the anode. We recorded the threshold at which anode capture lost and found it did not differ obviously between the two groups. The distribution of mapping methods differed significantly between the two groups. Twenty (38.46%) patients in LBBAP+ and seven (38.89%) patients in LBBAP– injured right bundle branch (RBB) during the operation. By following up on the ECG after the operation, we found that all the RBB injuries were recovered.

3.3 | Electrical synchronization

We used QRSd to evaluate the electrical synchronization between the ventricles and used LVAT to evaluate the electrical synchronization of the left ventricle. Figure 2 shows the comparison between the intrinsic

and paced status. The QRSd and the LVAT in unipolar 10 V pacing were wider than that of its intrinsic status (Figure 2A, LBBAP: 124.57 ± 10.92 ms vs 93.70 ± 9.33 ms, $P < .0001$, LBBAP+: 124.27 ± 11.33 ms vs 92.81 ± 8.85 ms, $P < .0001$, LBBAP–: 125.44 ± 9.89 ms vs 96.28 ± 10.45 ms, $P < .0001$, Figure 2B, LBBAP: 70.90 ± 11.02 ms vs 42.30 ± 7.72 ms, $P < .0001$, LBBAP+: 67.71 ± 10.02 ms vs 42.00 ± 5.98 ms, $P < .0001$, LBBAP–: 80.11 ± 8.44 ms vs 43.19 ± 11.55 ms, $P < .0001$). The QRSd when 3830 lead located on the right side of the interventricular septum before fixation (endocardial status) was wider than the QRSd in LBBAP (Figure 2C, 124.57 ± 10.92 ms vs 150.84 ± 10.33 ms, $P < .0001$). Table 3 shows the interventricular electrical synchronization and left ventricular electrical synchronization in LBBAP+ and LBBAP–. No significant differences were found in QRSd between the two groups. The LVAT was significantly shorter in LBBAP+ than in LBBAP–.

TABLE 2 Intraoperative characteristics in LBBAP+ and LBBAP–

	LBBAP+(n = 52)	LBBAP-(n = 18)	P Value
Procedure duration (min)	91.06 ± 22.85	93.94 ± 25.56	.656
Fluoroscopy duration (min)	14.56 ± 2.45	15.11 ± 1.71	.379
LBBp-V (ms)	19.56 ± 8.01	–	–
LBB injury current, n(%)	27 (51.92)	–	–
Mapping method			
Pacing mapping method, n (%)	7 (13.46)	10 (55.56)	.001
HIS potential mapping method, n (%)	45 (86.54)	8 (44.44)	.001
RBB injury, n (%)	20 (38.46)	7 (38.89)	.974
Ventricular extrasystole in RBBB pattern, n (%)	5 (9.62)	1 (5.56)	1.000
Anode capture, n (%)	20 (38.46)	7 (38.89)	.974
Threshold of anode capture (V)	2.93 ± 0.94	4.33 ± 0.75	.006
Threshold of ring (V)	1.54 ± 1.6	2.01 ± 1.74	.513

Abbreviations: HIS, his bundle; LBB, left bundle branch; LBBAP+, patients with left bundle branch potential; LBBAP–, patients without left bundle branch potential; LBBp-V, the width from the starting of left bundle branch potential to the starting of QRS wave; RBB, right bundle branch; RBBB, right bundle branch block.

TABLE 3 Electrocardiographic characteristics and echocardiographic characteristics in LBBAP+ and LBBAP–

Parameters	LBBAP+ (n = 52)	LBBAP– (n = 18)	P Value
Electrocardiographic characteristics			
H-QRSd (ms)	124.27 ± 11.33	125.44 ± 9.89	.697
L-QRSd (ms)	138.04 ± 14.65	132 ± 10.87	.110
BI-QRSd (ms)	125.77 ± 11.91	126.33 ± 14.43	.870
H-LVAT (ms)	67.71 ± 10.02	80.11 ± 8.44	.000013
L-LVAT (ms)	74.67 ± 12.63	91.33 ± 15.06	.000020
BI-LVAT (ms)	70.21 ± 10.15	80.56 ± 11.48	.000593
Pacing QRS axis (°)	7.13 ± 35.41	1.96 ± 39.38	.610
Echocardiographic characteristics			
LVEDD (cm)	5.18 ± 0.49	4.99 ± 0.44	.179
LVESD (cm)	3.66 ± 0.52	3.46 ± 0.37	.158
LVEF (%)	55.31 ± 6.7	56.41 ± 5.71	.560
AVVTI (cm)	26.09 ± 4.96	25.49 ± 4.95	.687
PASP (mmHg)	35.25 ± 5.4	33.65 ± 7.17	.369
IVMD (ms)	9.11 ± 9.53	7.94 ± 8.9	.672
LVPSD (ms)	45.69 ± 8.65	47.18 ± 11.19	.599
LVPS (%)	–19.59 ± 1.78*	–19.24 ± 2.49*	.559

Abbreviations: AVVTI, aortic valvular velocity time integral; BI-LVAT, bipolar paced activation time of left ventricle at 3.5 V @ 0.4 ms; BI-QRSd, bipolar paced QRS duration at 3.5V@0.4 ms; H-LVAT, unipolar high output paced activation time of left ventricle at 10 V @ 0.4 ms; H-QRSd = unipolar high output paced QRS duration at 10V@0.4 ms; IVMD, interventricular mechanical delay; L-QRSd, unipolar low output paced QRS duration at threshold; LBBAP+, patients with left bundle branch potential; LBBAP–, patients without left bundle branch potential; LVAT, activation time of left ventricle; L-LVAT, unipolar low output paced activation time of left ventricle at threshold; LVEDD, left ventricular end-diastolic diameter; LVESD, left ventricular end-systolic diameter; LVEF, ejection fraction of left ventricle; PASP, pulmonary artery systolic pressure; LVPSD, peak systolic dispersion of left ventricle; LVPS, left ventricular peak systolic strain. *compared with intrinsic status, $P < .05$.

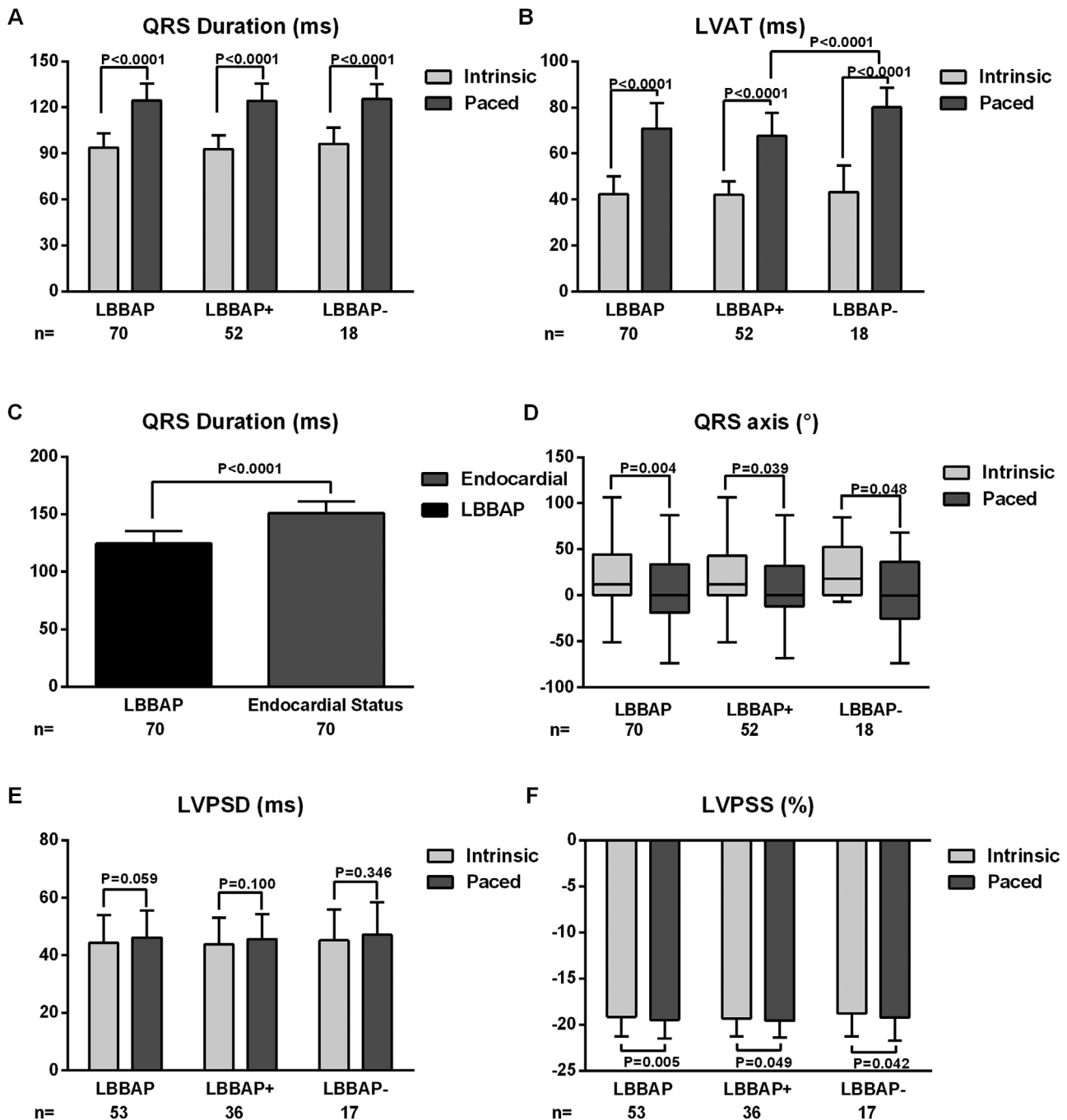


FIGURE 2 The comparison between the intrinsic status and the paced status

Abbreviations: LBBAP+, patients with left bundle branch potential; LBBAP-, patients without left bundle branch potential; LVAT, activation time of left ventricle; LVPSD, peak systolic dispersion of left ventricle; LVPSS, left ventricular peak systolic strain

3.4 | Electrical spreading

There were significant differences between intrinsic QRS axis and unipolar 10 V paced QRS axis (Figure 2D, LBBAP: 20.48 ± 33.30 ms vs 5.80 ± 36.25 ms, $P = .004$, LBBAP+: 18.66 ± 35.23 ms vs 7.13 ± 35.41 ms, $P = .039$, LBBAP-: 25.74 ± 27.18 ms vs 1.96 ± 39.38 ms, $P = .048$). In unipolar 10 V pacing status, no statistical difference

between the LBBAP+ and the LBBAP- was found (Table 3). The morphologies changed significantly in lead V1 after LBBAP (Figure 3A, $P < .0001$), however, in unipolar 10 V pacing status, no significant differences were found in the distribution of morphologies in V1 between LBBAP+ and LBBAP- (Figure 3A, $P = .394$). The pacing lead positions were defined as high positions when the main QRS wave directions of lead II, III, and AVF were positive (II+, III+, and AVF+), and




FIGURE 3 The distribution of QRS morphology in lead V1 and the distribution of the polarity in the lead II, III, and AVF. BASE = normal intrinsic QRS condition; LBBAP+ = patients with left bundle branch potential; LBBAP- = patients without left bundle branch potential. A, BASE group has four types of QRS morphology in lead V1, including five qR, 10 QS, 54 rS, and one rSR'. There are two types of QRS morphology in lead V1 in LBBAP, LBBAP+, and LBBAP- group in unipolar 10 V pacing, including 51 qR and 19 rSR' in LBBAP, 36 qR and 16 rSR' in LBBAP+ and 15 qR and 3 rSR' in LBBAP-. B, Intrinsic lead II, III, and AVF polarity includes II+III+AVF+ 37, II-III-AVF- 7, II+III-AVF+ 16, and II+III-AVF- 10. Lead II, III, and AVF polarity in LBBAP+ in unipolar 10 V pacing includes II+III+AVF+ 18, II-III-AVF- 14, II+III-AVF+ 10, and II+III-AVF- 10. Lead II, III, and AVF polarity in LBBAP- in unipolar 10 V pacing includes II+III+AVF+ 7, II-III-AVF- 2, II+III-AVF+ 7, and II+III-AVF-

were defined as low positions when the main QRS wave directions of lead II, III, and AVF were negative (II- III- AVF-). The distribution of high and low positions showed no significant differences in LBBAP+ and LBBAP- (Figure 3B, high, $P = .744$; low, $P = .293$). The characteristics of the R-wave transition in precordial leads can be seen in Figure 4. In both groups, unipolar 10 V paced R-wave transition moved forward compared with intrinsic R-wave transition (LBBAP-, $Z = -2.81$, $P = .005$; LBBAP+, $Z = -1.99$, $P = .046$). The ICC of the paced LVAT was 0.993.

3.5 | Echocardiography

Thirty-six LBBAP+ patients and 17 LBBAP- patients received echocardiography 7 days after the operation. The echocardiography was performed in intrinsic status and in LBBAP status (Figure 5). The LBBAP lead did not work in intrinsic status. The LBBAP status and its considerations were described above in Section 2.3. Figure 2 shows the comparison between these two statuses. No matter in the LBBAP group, LBBAP+ group, or LBBAP- group, the LVPSS increased obviously (Figure 2E, LBBAP: $-19.16 \pm 2.12\%$ vs $-19.48 \pm 2.02\%$, $P = .005$, LBBAP+: $-19.32 \pm 1.95\%$ vs $-19.59 \pm 1.78\%$, $P = .049$, LBBAP-: $-18.81 \pm 2.48\%$ vs $-19.24 \pm 2.49\%$, $P = .042$) while the LVPSD showed no significant changes (Figure 2F). In both statuses, the

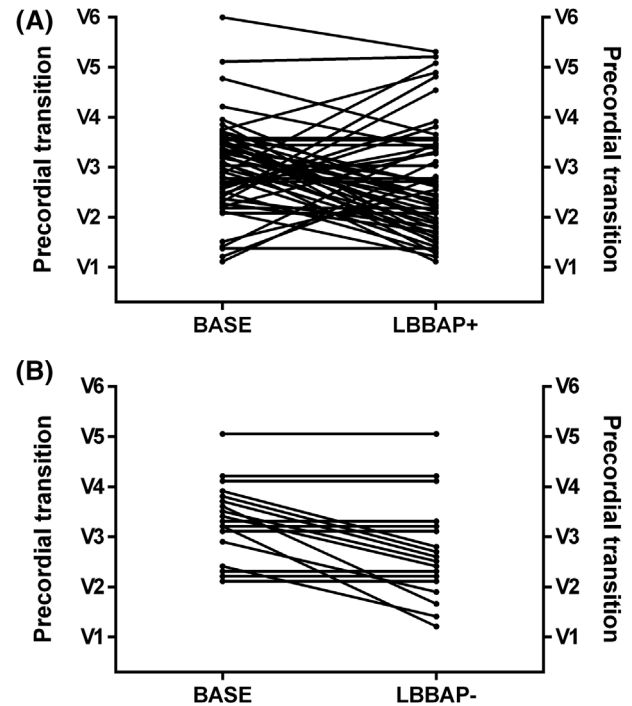


FIGURE 4 The R-wave transition in precordial leads in LBBAP+ and LBBAP-. BASE = normal intrinsic QRS condition; LBBAP+ = patients with left bundle branch potential; LBBAP- = patients without left bundle branch potential

systolic parameters, diastolic parameters as well as mechanical synchronization parameters were similar between LBBAP+ and LBBAP- groups (Table 1, Table 3). The degree of mitral regurgitation remained unchanged in intrinsic status and in LBBAP status (LBBAP+, $P = 1$; LBBAP-, $P = 1$). For the LVPSD and the LVPSS, very high interobserver reliability was derived (ICC, LVPSD >0.95 , LVPSS >0.95).

3.6 | Follow-up and complications

As shown in Figure 6, the unipolar impedance of LBBAP- group immediately after the operation was higher than that of LBBAP+ group ($702.11 \pm 129.09 \Omega$ vs $631.02 \pm 128.55 \Omega$, $P = .047$). The trends of R-wave amplitude, threshold, and impedance of the two groups were largely the same. Six months after the LBBAP operation, one asymptomatic patient in LBBAP+ group cannot detect the unipolar threshold and cannot be paced at unipolar 10 V while the bipolar threshold was increased abnormally. It was confirmed by echocardiography that the lead perforation had happened (Figure 7). The perforated 3830 lead was finally removed by hand and replaced by a 5076 lead. Other complications such as hematoma, thrombus, and broken leads were not found during the one-year follow-up.

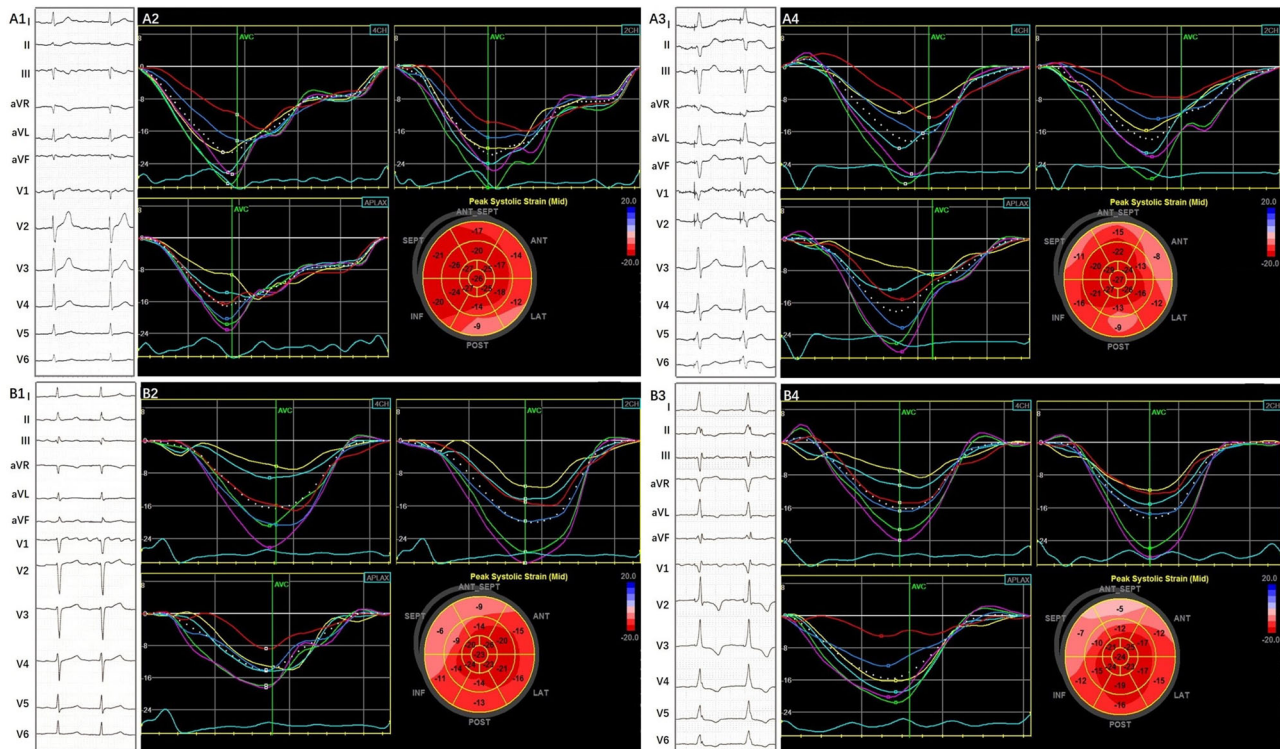


FIGURE 5 The electrocardiographic and echocardiographic manifestations in intrinsic and LBBAP status. Figure shows electrocardiogram (ECG) and two-dimensional speckle tracking echocardiography (the bull's eye plots and the left ventricular longitudinal strain curve) before and after LBBAP. Group A shows one LBBAP+ patient suffered from atrial fibrillation with a slow ventricular rate. A1 is ECG in intrinsic status, the QRS duration is 106 ms; A2 is echocardiography in intrinsic status, LVPSD is 54 ms, LVPSS is -20% . A3 is ECG in LBBAP status, the QRS duration is 118 ms; A4 is echocardiography in LBBAP status, LVPSD is 42 ms, LVPSS is -18.2% . Group B shows one LBBAP- patient suffered from atrial fibrillation with a third-degree atrioventricular block. B1 is ECG in intrinsic status, the QRS duration is 84 ms; B2 is echocardiography in intrinsic status, LVPSD is 32 ms, LVPSS is -17% . B3 is ECG in LBBAP status, the QRS duration is 118 ms; B4 is echocardiography in LBBAP status, LVPSD is 35 ms, LVPSS is ECG 16.8% . Abbreviations: LBBAP, left bundle branch area pacing; LBBAP+, patients with left bundle branch potential; LBBAP-, patients without left bundle branch potential; LVPSD, peak systolic dispersion of left ventricle; LVPSS, left ventricular peak systolic strain [Color figure can be viewed at wileyonlinelibrary.com]

4 | DISCUSSION

LBBAP emphasizes the capture of the LBB and its conduction system, which has faster and more efficient LVAT and better electrical synchronization than traditional pacing methods.¹³⁻¹⁵ However, there are no uniform criteria for assessing the capture of LBB. Li et al measured the interval from the starting of LBBp to the starting of the QRS wave. He suggested that the interval of less than 35 ms indicates only the LBB was captured.¹⁶ Hou et al thought that LBBAP should record LBBp on the basis of left ventricular septal pacing.¹⁰

In the previous studies, the LBBp suggested that the lead was close to the LBB and was a possible clue for the capture of the LBB.¹⁷ The recording rate of LBBp was related to the experience of LBBAP.¹⁰ Also, the different conditions of the patients make it difficult to identify the LBBp. Sometimes, the LBBp is too small and similar to signal interference. Sometimes, the patients are under the protection of the temporary pacemakers and the temporary pacing signal interferes with the search for the LBBp during the operation. According to all these previous studies, even in patients with the normal intrinsic conduction system, it was inevitable that LBBp could not be recorded in all the

patients.^{12,17} The recording rate of LBBp has not reached 100%.^{12,16}

The LBBAP- group lacks evidence to prove that it has captured the LBB, but it is also different from the left ventricular septal pacing (LVSP) reported in previous studies. The LBBAP- has narrower QRSd than LVSP.^{18,19} In our study, the LVAT at 10 V output in LBBAP- was wider than the LVAT at the threshold in LBBAP+. We speculated that only small branches of LBB were captured in LBBAP- or only the left ventricular deep septal pacing was obtained in LBBAP-. The cluster of ventricular extrasystole in RBB block pattern and the RBB injury during the operation were reported in previous studies as the clues of LBBAP lead implantation.¹⁶ However, these phenomena showed no significant differences between LBBAP+ and LBBAP- in our study. We found that it was easier to find the LBBp by the HIS potential mapping method than by the pacing mapping method. The LBBAP- group needs further studies to figure out its electrophysiological characteristics.

In the absence of a unified criterion for assessing LBB capture and a standardized procedure for LBBAP lead implantation, previous studies have shown different LBBAP characteristics. The paced LVAT varied greatly in different articles.^{8,10} In our study, we found that the pacing electrical performances in LBBAP were diverse and

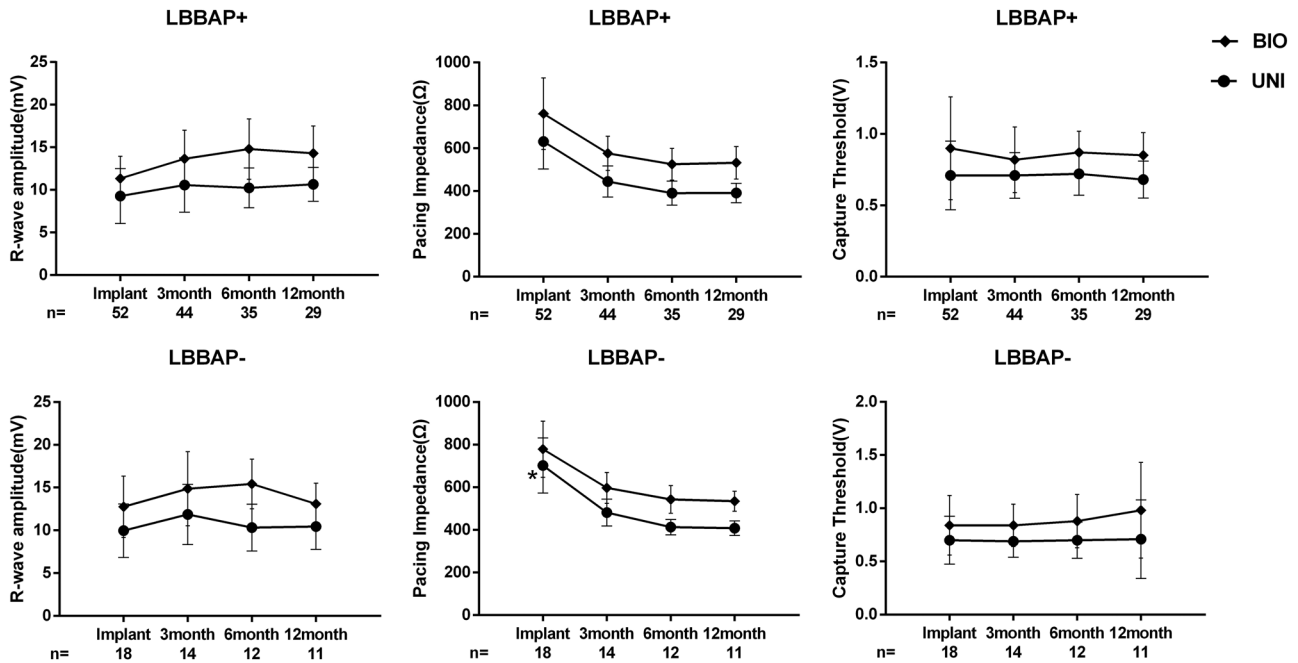


FIGURE 6 The lead parameters in LBBAP+ and LBBAP- patients. Abbreviations: LBBAP+, patients with left bundle branch potential; LBBAP-, patients without left bundle branch potential. *compared with LBBAP+, $P < .05$

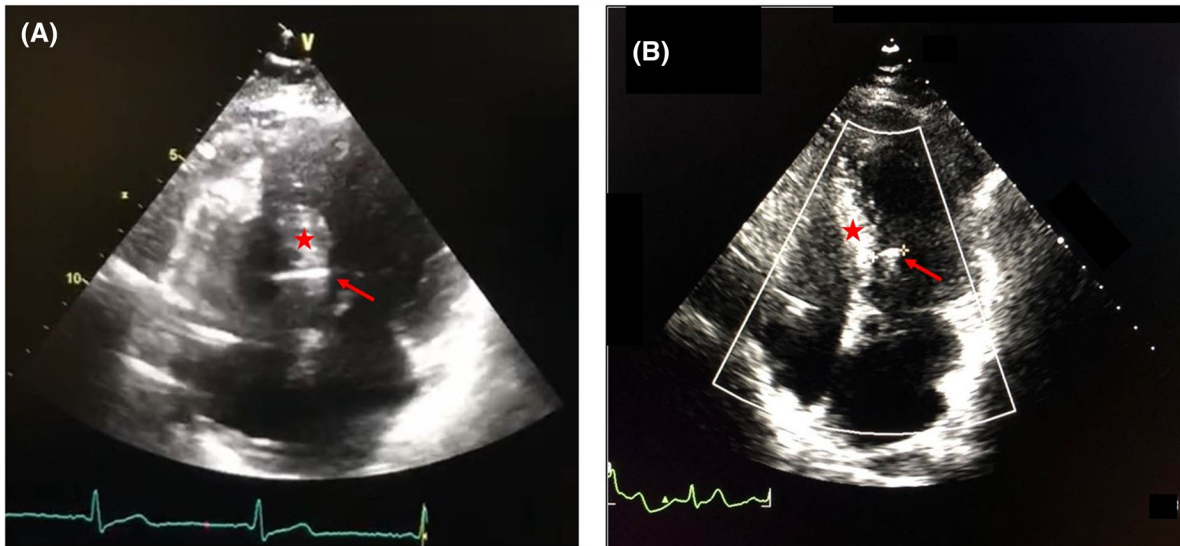


FIGURE 7 LBBAP lead perforation in one LBBAP+ patient. A, LBBAP+ patient with third degree atrioventricular block had asymptomatic lead perforation 6 months after the operation. Her intrinsic QRSd was 90 ms, and intrinsic LVAT was 44 ms. The patient had a LBB injury current. The unipolar 10 V paced QRSd was 112 ms. The unipolar paced QRSd at threshold was 126 ms. The unipolar paced LVAT was unchanged and was 54 ms. Her unipolar impedance immediately after the operation was 518 Ω and dropped to 306 Ω after 6 months. Her unipolar threshold immediately after the operation was 0.4 V @ 0.4 ms and cannot be measured after 6 months. The bipolar impedance immediately after the operation was 608 Ω and decreased to 489 Ω after 6 months. The bipolar threshold abnormally increased from 0.4 V @ 0.4 ms to 2.25 V @ 1 ms after 6 months. The red star shows the interventricular septum. The red arrow shows the tip of the LBBAP lead. A, The tip of the LBBAP lead is in the left ventricular endocardium 7 days after the operation. B, The tip of the lead enters the left ventricular cavity 6 months after the operation. Abbreviations: LBBAP+, patients with left bundle branch potential; LBB, left bundle branch; LVAT, activation time of left ventricle; QRSd, QRS duration

[Color figure can be viewed at wileyonlinelibrary.com]

the positions of LBBAP lead in the interventricular septum had many types. Fortunately, even though the electrical characteristics were complex, there were no statistical differences in important hemodynamic characteristics measured by echocardiography in LBBAP+ and LBBAP−.

The results of our study indicate that since there is no statistical difference in mechanical synchronization between LBBAP+ and LBBAP− under the LBBAP status, we speculate that the clinical benefits of LBBAP in patients with and without LBBp may not be significantly different. We think that it may not be necessary to take a long time to find and confirm the LBBp when it is difficult to detect the LBBp or screw the lead too deep when the LVAT is wide during the LBBAP operation. These behaviors during the operation may prolong the operation time and increase the risk of lead perforation.¹⁷ However, this study is short-term efficacy evaluation and lacks long-term follow-up of mechanical synchronization. Also, the long-term clinical effect caused by the difference in left ventricular electrical synchronization between the two groups needs further study. We believe that long-term follow-up of the synchronization of LBBAP+ and LBBAP− will have significance in guiding the operation accuracy of LBBAP.

There are other important findings in this study. Although LBBAP has been reported that it can narrow the QRSd and improve the electrical synchronization in patients with HF and LBBB,²⁰ we found that, in patients with normal intrinsic QRSd, the QRSd and LVAT increased as well as the frontal QRS axis, the morphologies of V1 and the R-wave transition in precordial leads changed after LBBAP. The morphologies of V1 (right bundle branch block like, qR dominated), the QRS axis deviation (leftward shift), and the R-wave transition in precordial leads (forward shift) indicate that the pacing sites are mostly at left posterior fascicle of the LBB. The pacing sites were similar in LBBAP+ and LBBAP−. The increasing QRSd suggests that the interventricular electrical synchronization becomes worse after LBBAP. The intervals from the paced stimulation to the LBB conduction system were included in the paced LVAT because of our measurement method of the paced LVAT. It might be a reason for that the paced LVAT is wider than the intrinsic LVAT in this study. According to the echocardiographic analysis, systolic strain (LVPSS) was changed while the systolic synchronization (LVPSSD) showed no significant differences after the LBBAP.

There are some difficulties in fixing the leads to the proximal left bundle branches during the LBBAP operation. At the beginning of learning LBBAP, the possibilities of fixing the leads to the lower positions in septum or to the distal left bundle branches are high for the operators. The main QRS wave directions of lead II, III, and AVF were analyzed to roughly evaluate the lead position in the septum, and no obvious differences were found between LBBAP+ and LBBAP−.

We followed up the lead parameters and found that one patient (1.92%) in LBBAP+ had abnormal lead parameters which was finally confirmed as lead perforation, while the other LBBAP patients had low and stable capture threshold, sensing amplitude, and lead impedance. We think that the excessive pursuit of the capture of the LBB conduction system and the short LVAT may lead to excessive lead rotation

and increase the risk of myocardial perforation. Although there are no serious adverse events of LBBAP reported at present, we believe that the safety of the operation should be the absolute priority. Preoperative echocardiography should be performed to evaluate the degree of myocardial looseness and the thickness of interventricular septum so as to exclude patients who are not suitable for LBBAP. After the patients are discharged from the hospital, the unipolar and bipolar parameters of LBBAP lead should be followed up to rule out the complications of LBBAP such as lead perforation.

Our study confirms that LBBAP has a good feasibility and application prospect in patients with normal intrinsic QRSd, and it needs to be standardized and further studied to make patients obtain more physiological pacing experience.

5 | LIMITATION

This study is a single center, small sample size study, and there is a possibility of making a type II error, which will result in false negative outcomes. The parameters of 12-lead ECG and echocardiography may have inevitable measurement errors. Noise signals may influence the collection of ECG. The parameters we used to describe the electrical spreading were inaccurate, although they were easy to obtain. AFI technique was used for echocardiographic analysis and can reduce the dependence on the echocardiographers' experience. However, echocardiographic images may be affected by the underlying diseases, age, and obesity of the patients. The validity of conclusions needs to be further demonstrated by expanding the sample size and using more accurate technology in the future. Echocardiography is performed in a short period after the operation, and whether there are any changes in the long-term results of mechanical synchrony in LBBAP needs to be further explored. More efforts should be taken to confirm the long-term complications and long-term safety of LBBAP.

6 | CONCLUSION

LBBAP changes electrical and mechanical characteristics and has good safety in patients with normal intrinsic QRSd. LBBAP+ and LBBAP− show no significant differences in mechanical synchronization and interventricular electrical synchronization. The LBBAP+ group shows better left ventricular electrical synchronicity.

AUTHOR CONTRIBUTIONS

Study concept and design: Wei Xu. Analysis and interpretation of data: Shaoxian Wang, Yuan Gao, and Ning Zhang. Drafting of the article: Rongfang Lan and Shaoxian Wang. Critical revision of the manuscript for important intellectual content: Wei Xu, Jia Zheng, and Ning Zhang. Approval of the article: Xiang Wu, Jian Bai, Xinyue Xu, and Tianqi Wang.

CONFLICT OF INTEREST

The authors declare that there is no conflict of interest that could be perceived as prejudicing the impartiality of the research reported.

ORCID

Shaoxian Wang MD  <https://orcid.org/0000-0002-8602-792X>

Jia Zheng MD  <https://orcid.org/0000-0002-9544-8064>

REFERENCES

- Jastrzębski M, Baranchuk A, Fijorek K, et al. Cardiac resynchronization therapy-induced acute shortening of QRS duration predicts long-term mortality only in patients with left bundle branch block. *Europace*. 2019;21:281-289.
- Carita P, Corrado E, Pontone G, et al. Non-responders to cardiac resynchronization therapy: insights from multimodality imaging and electrocardiography. A brief review. *Int J Cardiol*. 2016;225:402-407.
- Huang W, Su L, Wu S, et al. Long-term outcomes of His bundle pacing in patients with heart failure with left bundle branch block. *Heart*. 2019;105:137-143.
- Kronborg MB, Mortensen PT, Poulsen SH, Gerdes JC, Jensen HK, Nielsen JC. His or para-His pacing preserves left ventricular function in atrioventricular block: a double-blind, randomized, crossover study. *Europace*. 2014;16:1189-1196.
- Abdelrahman M, Subzposh FA, Beer D, et al. Clinical outcomes of His bundle pacing compared to right ventricular pacing. *J Am Coll Cardiol*. 2018;71:2319-2330.
- Bhatt AG, Musat DL, Milstein N, et al. The efficacy of His bundle pacing: lessons learned from implementation for the first time at an experienced electrophysiology center. *JACC Clin Electrophysiol*. 2018;4:1397-1406.
- Lustgarten DL, Crespo EM, Arkhipova-Jenkins I, et al. His-bundle pacing versus biventricular pacing in cardiac resynchronization therapy patients: a crossover design comparison. *Heart Rhythm*. 2015;12:1548-1557.
- Chen K, Li Y, Dai Y, et al. Comparison of electrocardiogram characteristics and pacing parameters between left bundle branch pacing and right ventricular pacing in patients receiving pacemaker therapy. *Europace*. 2019;21:673-680.
- Cai B, Huang X, Li L, et al. Evaluation of cardiac synchrony in left bundle branch pacing: insights from echocardiographic research. *J Cardiovasc Electr*. 2020;31:560-569.
- Hou X, Qian Z, Wang Y, et al. Feasibility and cardiac synchrony of permanent left bundle branch pacing through the interventricular septum. *Europace*. 2019;21:1694-1702.
- Gao MY, Tian Y, Shi L, et al. Electrocardiographic morphology during left bundle branch area pacing: characteristics, underlying mechanisms, and clinical implications. *Pacing Clin Electrophysiol*. 2020;43(3):297-307.
- Li Y, Chen K, Dai Y, et al. Left bundle branch pacing for symptomatic bradycardia: implant success rate, safety, and pacing characteristics. *Heart Rhythm*. 2019;16:1758-1765.
- Zhang J, Wang Z, Cheng L, et al. Immediate clinical outcomes of left bundle branch area pacing vs conventional right ventricular pacing. *Clin Cardiol*. 2019;42(8):768-773.
- Huang W, Chen X, Su L, Wu S, Xia X, Vijayaraman P. A beginner's guide to permanent left bundle branch pacing. *Heart Rhythm*. 2019;16:1791-1796.
- Chen X, Wu S, Su L, Su Y, Huang W. The characteristics of the electrocardiogram and the intracardiac electrogram in left bundle branch pacing. *J Cardiovasc Electrophysiol*. 2019;30(7):1096-1101.
- Li X, Li H, Ma W, et al. Permanent left bundle branch area pacing for atrioventricular block: feasibility, safety, and acute effect. *Heart Rhythm*. 2019;16:1766-1773.
- Su L, Xu T, Cai M, et al. Electrophysiological characteristics and clinical values of left bundle branch current of injury in left bundle branch pacing. *J Cardiovasc Electr*. 2020;31(4):834-842.
- Vijayaraman P, Subzposh FA, Naperkowski A, et al. Prospective evaluation of feasibility and electrophysiologic and echocardiographic characteristics of left bundle branch area pacing. *Heart Rhythm*. 2019;16:1774-1782.
- Mafi-Rad M, Luermans JGLM, Blaauw Y, et al. Feasibility and acute hemodynamic effect of left ventricular septal pacing by transvenous approach through the interventricular septum. *Circ Arrhythm Electrophysiol*. 2016;9(3):e003344.
- Zhang W, Huang J, Qi Y, et al. Cardiac resynchronization therapy by left bundle branch area pacing in patients with heart failure and left bundle branch block. *Heart Rhythm*. 2019;16:1783-1790.

How to cite this article: Wang S, Lan R, Zhang N, et al. LBBAP in patients with normal intrinsic QRS duration: Electrical and mechanical characteristics. *Pacing Clin Electrophysiol*. 2021;44:82-92. <https://doi.org/10.1111/pace.14114>