

Unexpected Improvement of Liver Function by Intravenous Immunoglobulin in a Steroid-Experienced Severe Alcoholic Hepatitis

Kwon Yong Tak, MD¹, Pil Soo Sung, MD, PhD², Hee Chul Nam, MD¹, Jeong Won Jang, MD, PhD¹, Jong Young Choi, MD, PhD¹, and Seung Kew Yoon, MD, PhD¹

¹Department of Internal Medicine, Seoul St. Mary's Hospital, College of Medicine, The Catholic University of Korea, Seoul, Republic of Korea

²Department of Internal Medicine, Eunpyeong St. Mary's Hospital, College of Medicine, The Catholic University of Korea, Seoul, Republic of Korea

ABSTRACT

Corticosteroid is the treatment of choice for severe alcoholic hepatitis; however, it can also lead to severe life-threatening infection. We report a 28-year-old severe alcoholic hepatitis patient who did not achieve a satisfactory improvement of the liver function by corticosteroid use but obtained a significant improvement of the liver function by intravenous immunoglobulin. Intravenous immunoglobulin was administered to control infection after prolonged corticosteroid usage; however, it led to an unexpected remarkable decrease in the serum total bilirubin level and restored the responsiveness to the additional corticosteroid used after the resolution of the infection.

INTRODUCTION

Severe alcoholic hepatitis (SAH) occurs in certain cases of extensive alcohol abuse and is occasionally presented with signs of liver failure. Corticosteroid is the initial treatment of choice in SAH for its short-term survival benefit.¹ Despite its critical role, the application of corticosteroids is limited because of infection.¹ The current guideline does not propose an alternative treatment for those who develop an infection after corticosteroid therapy.² We report a patient with SAH who showed a poor response and suffered a serious infection after corticosteroid use. Intravenous immunoglobulin (IVIG) was administered to control the systemic inflammatory response but unexpectedly resulted in a significant improvement of the liver function and restoration of the responsiveness to the steroid therapy.

CASE REPORT

A 28-year-old man from Korea was admitted for abdominal discomfort and had jaundice for 2 weeks before admission. The patient drank alcoholic beverages 5 days a week in addition to 2–3 bottles of soju (99–148.6 g of alcohol) daily for 4 years. The patient did not have any relevant familial history. He appeared acutely ill with icteric sclera and a distended abdomen.

The patient's initial body temperature was 37.4°C. His laboratory results were as follows: hemoglobin 15.2 g/dL, leukocyte count 24,740/ μ L, platelet count 382,000/ μ L, aspartate aminotransferase 529 IU/L, alanine aminotransferase 111 IU/L, total bilirubin 20.69 mg/dL, direct bilirubin 16.56 mg/dL, alkaline phosphatase 304 IU/L, γ -glutamyl transferase >2,000 U/L, and albumin 3.1 g/dL. Prothrombin time was prolonged, with an international normalized ratio of 1.35. The creatinine level was 0.77 mg/dL. Viral hepatitis was ruled out as serology for hepatitis B surface antigen, immunoglobulin M antibody to hepatitis A virus, hepatitis C antibody, and human immunodeficiency virus was negative. Contrast-enhanced abdominal computed tomography (CT) revealed hepatomegaly with a small number of ascites pockets and heterogeneous enhancement of the liver parenchyma (Figure 1).

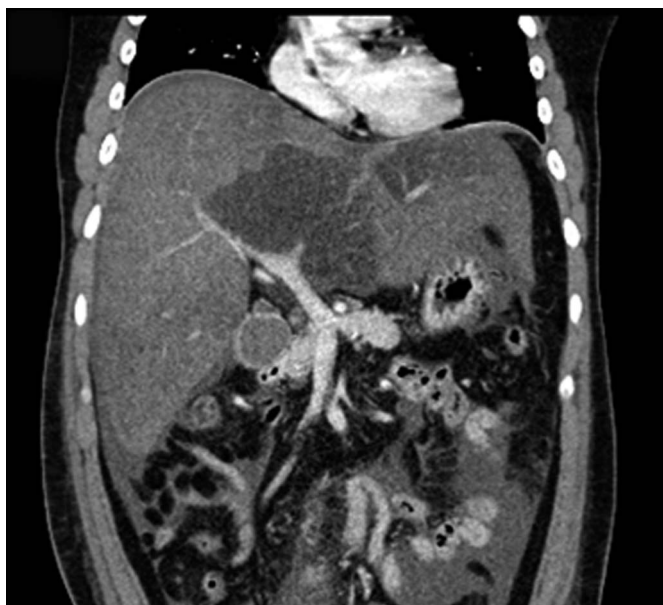

Figure 1. Abdominal computed tomography at admission showing hepatomegaly.

The patient was immediately hospitalized after diagnosed with SAH and was completely abstinent from alcohol during the hospitalization period. The initial risk score evaluated with the Maddrey discriminant function was 42.8. The patient was started on 40 mg/day prednisolone on the first day. After 7 days of corticosteroid use, evaluation for steroid response using the Lille model showed a score of 0.24, indicating continued corticosteroid treatment. After 28 days of corticosteroid use, the serum bilirubin level was 15.12 mg/dL. Corticosteroid treatment was continued, with gradual dose tapering for another 20 days. No additional stress dose of corticosteroid was administered during the treatment course.

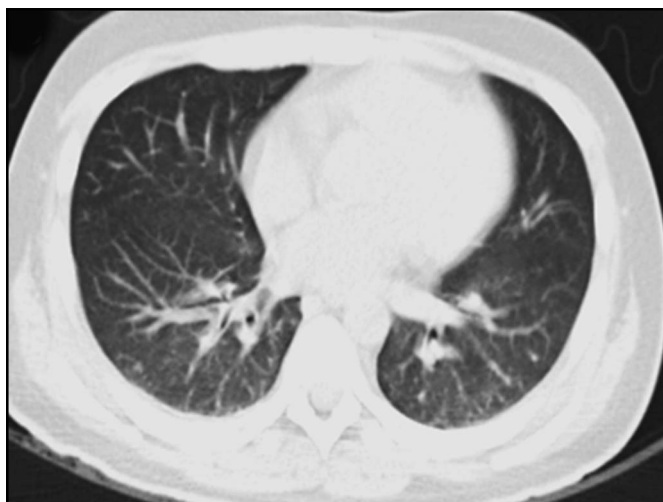

Figure 2. Thoracic computed tomography after 32 days of steroid use.

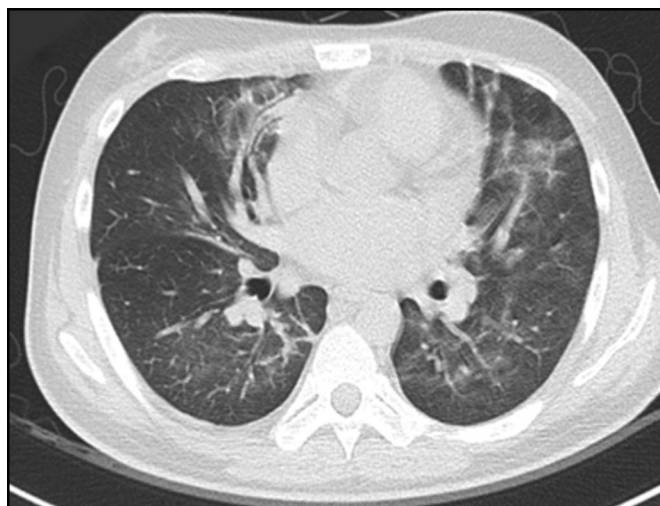

Figure 3. Thoracic computed tomography after 48 days of steroid use.

The total bilirubin level after 32 days of treatment was 13.66 mg/dL. Thoracic CT showed no sign of infection (Figure 2). After 48 days of treatment, the patient showed sudden symptoms of infection: fever reaching 38.0°C and dyspnea. Repeat thoracic CT showed atypical pneumonia, and a sputum polymerase chain reaction panel identified *Pneumocystis jirovecii* (Figure 3). At the time of infection, the patient was on 10 mg/d of prednisolone, which was immediately stopped and trimethoprim-sulfamethoxazole 4,800 mg/d was started. Despite the antibiotic use, fever persisted and hypoxemia developed, so IVIG was administered according to the sepsis protocol (500 mg/kg daily for 3 days). Soon after the IVIG treatment, signs of systemic infection alleviated within 2–3 days. Interestingly, the total bilirubin level, which was 14.37 mg/dL on the first day of IVIG, decreased to 8.20 mg/dL. The patient recovered from pneumonia, and prednisolone was resumed 21 days after its cessation and used for 9 more days. The patient was discharged without continuing oral corticosteroid. In an outpatient follow-up performed 11 weeks after discharge, the patient showed steady recovery. Laboratory results were as follows: total bilirubin 2.53 mg/dL and direct bilirubin 1.19 mg/dL, gamma-glutamyl transferase 174 U/L, and prothrombin time in international normalized ratio of 1.23. The summary of patient progress after admission is shown in Figure 4.

DISCUSSION

We report that the immunosuppressive property of IVIG may contribute to the improvement of the liver function in patients with SAH. No adverse event developed until sudden fever due to pneumocystis pneumonia occurred after 48 days of treatment. Corticosteroid was immediately stopped, and IVIG was administered. After the IVIG administration, the patient's liver function unexpectedly improved. Steroid responsiveness was also restored, and the patient showed a steady decline in the

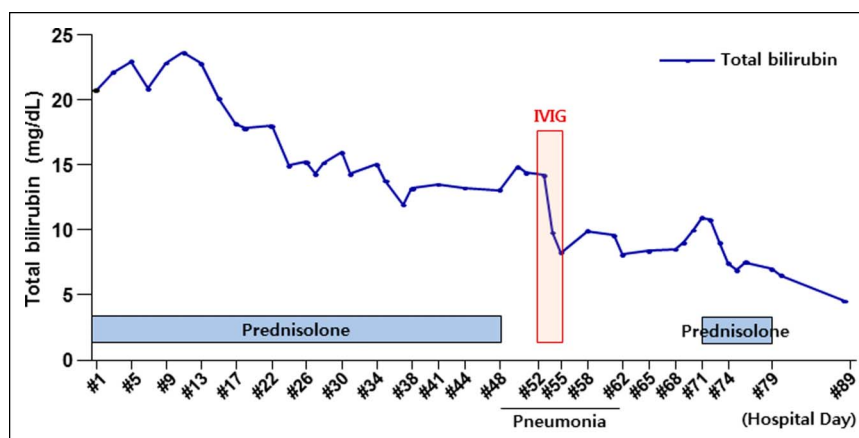


Figure 4. Summary of the patient progress after admission. IVIG, intravenous immunoglobulin.

total bilirubin level afterward. The patient is showing steady improvement in the outpatient follow-up for 3 months.

Currently, corticosteroid is the only medical treatment that improves survival in patients with SAH. Corticosteroid's broad anti-inflammatory and immunosuppressive actions are assumed effective against cytokine release and injury by immunological processes. IVIG is also known to have generalized immunoregulatory mechanisms attributed to its immunoglobulin G Fc region, including the modulation of T cell and B cell function, interaction with antigen-presenting cells, and binding to cell surface lectin receptors.³ Furthermore, IVIG has been reported to be selectively effective in intrahepatic immunomodulation.⁴ The evidence of beneficial immunomodulatory capabilities of IVIG is increasing, and liver transplant patients also benefit from immunoregulatory capabilities of IVIG.⁵

One general mechanism of IVIG action potentially links the benefits of IVIG to the response to glucocorticoids. In most of the chronic inflammatory or autoimmune diseases in which IVIG has been used, steroid therapy is usually considered to be the first-line option, although steroid-resistant disease state can develop in many clinical cases.³ IVIG's immunomodulatory and anti-inflammatory activities may work by increasing the number of corticosteroid-binding receptors in steroid-resistant states.³ IVIG may play a critical role in these disease states by improving glucocorticoid receptor binding through unknown mechanisms, thus enhancing the steroid activity and the resolution of the persisting inflammation.³

Although effective as it is, the corticosteroid can cause a life-threatening infection.⁶ Current guidelines are yet to specify second-line medical treatments after corticosteroid.² Early liver transplantation is an emerging option, although it is recommended for a highly selective group.⁷ This emphasizes the need to establish a second-line treatment for patients with a contraindication or a poor response to corticosteroids. Our case presents IVIG as a potential treatment that can be administered under such circumstances. In summary, our case demonstrates that

IVIG treatment may result in a significant improvement of the liver function and restoration of the responsiveness to the steroid.

DISCLOSURES

Author contributions: KY Tak wrote the manuscript. PS Sung edited the manuscript and is the article guarantor. HC Nam, JW Jang, JY Choi, and SK Yoon approved the final version.

Financial disclosure: The Korean Liver Foundation helped fund this case report.

Informed consent was obtained for this case report.

Received August 15, 2019; Accepted January 6, 2020

REFERENCES

- Thursz MR, Richardson P, Allison M, et al; STOPAH Trial. Prednisolone or pentoxifylline for alcoholic hepatitis. *N Engl J Med*. 2015;372(17):1619–28.
- Singal AK, Bataller R, Ahn J, Kamath PS, Shah VH. ACG clinical guideline: Alcoholic liver disease. *Am J Gastroenterol*. 2018;113(2):175–94.
- Gelfand EW. Intravenous immune globulin in autoimmune and inflammatory diseases. *N Engl J Med*. 2012;367(21):2015–25.
- Kim S, Moore J, Alonso E, et al. Correlation of immune markers with outcomes in biliary atresia following intravenous immunoglobulin therapy. *Hepatol Commun*. 2019;3(5):685–96.
- Kornberg A. Intravenous immunoglobulins in liver transplant patients: Perspectives of clinical immune modulation. *World J Hepatol*. 2015;7(11):1494–508.
- Vergis N, Atkinson SR, Knapp S, et al. In patients with severe alcoholic hepatitis, prednisolone increases susceptibility to infection and infection-related mortality, and is associated with high circulating levels of bacterial DNA. *Gastroenterology*. 2017;152(5):1068–77.e4.
- Lee BP, Mehta N, Platt L, et al. Outcomes of early liver transplantation for patients with severe alcoholic hepatitis. *Gastroenterology*. 2018;155(2):422–30.e1.

Copyright: © 2020 The Author(s). Published by Wolters Kluwer Health, Inc. on behalf of The American College of Gastroenterology. This is an open-access article distributed under the terms of the Creative Commons Attribution-Non Commercial-No Derivatives License 4.0 (CCBY-NC-ND), where it is permissible to download and share the work provided it is properly cited. The work cannot be changed in any way or used commercially without permission from the journal.