

Case Report

Clinical and radiological aspects of cerebellopontine neurinoma presenting with recurrent spontaneous bleedings

Maimone Giuseppe, Ganau Mario¹, Nicassio Nicola¹, Cambria Mauro

Department of Neurosurgery, Policlinic University of Messina, 98126 Messina, ¹Hospital "Ospedali Riuniti", 34149 Trieste, Italy

E-mail: *Maimone Giuseppe - gmaimone@hotmail.com; Ganau Mario - mariaganau@gmail.com; Nicassio Nicola - nicknave@yahoo.it;
Cambria Mauro - cambriam@unime.it

*Corresponding author

Received: 10 November 12 Accepted: 16 April 13 Published: 28 May 13

This article may be cited as:

Giuseppe M, Mario G, Nicola N, Mauro C. Clinical and radiological aspects of cerebellopontine neurinoma presenting with recurrent spontaneous bleedings. *Surg Neurol Int* 2013;4:67.

Available FREE in open access from: <http://www.surgicalneurologyint.com/text.asp?2013/4/1/67/112605>

Copyright: © 2013 Giuseppe M. This is an open-access article distributed under the terms of the Creative Commons Attribution License, which permits unrestricted use, distribution, and reproduction in any medium, provided the original author and source are credited.

Abstract

Background: Neurinomas are benign, usually encapsulated, tumors growing in peripheral nerve sheath with a high incidence in the cerebellopontine angle.

Case Description: We report a case of vestibular neurinoma (VN) with a "biphasic" pattern of intratumoral hemorrhage presenting with cephalalgia along with progressive ipsilateral mild impairment of both VII and VIII cranial nerves. A thorough preoperative magnetic resonance imaging study better characterized the patchy pattern of the round shaped lesion, resulting in three different intensity signals, due to the peculiar characteristics of the tumoral mass and the recurrent bleedings, respectively. Postoperatively, histological examination confirmed the diagnosis of neurinoma.

Conclusion: Hemorrhagic VN are rare tumors; from the first case described in 1974 only 43 more have been reported in the literature so far. Noteworthy, "biphasic" bleedings are even rarer. From an accurate review of the literature we collected and thus emphasized the radiological and clinical features of this rare entity. Eventually, we suggest that the early surgical removal of clots and tumor is essential to provide the best chance of neurological improvement.

Key Words: Biphasic bleeding, cerebellopontine angle, intratumoral hemorrhage, patchy pattern, vestibular Schwannoma

Access this article online

Website:

www.surgicalneurologyint.com

DOI:

10.4103/2152-7806.112605

Quick Response Code:

INTRODUCTION

Neurinomas are benign, usually encapsulated, tumors growing in peripheral nerve sheath with high incidence in the cerebellopontine angle (CPA). As most of benign tumors, their presence is suspected by the onset of neurological signs in a slow-growing fashion caused by vascular or nervous conflicts.^[26,20] Spontaneous intracranial hemorrhage occurs in 3.9% of all brain tumors,^[27] especially in aggressive ones, such as metastatic tumors or malignant gliomas. Apart from high-vascularized tumors,

as choroid plexus papillomas and pituitary adenomas, spontaneous intracranial hemorrhage associated with a benign lesion is an even more uncommon condition.

CASE REPORT

We report a case of vestibular neurinoma (VN) associated with a radiological "biphasic" pattern of intratumoral hemorrhage (ITH). A 65-year-old woman came to our attention complaining of sudden headache and progressive oral rhyme deviation. Neurological

examination showed mild ipsilateral VII cranial nerve palsy and hearing loss. A computed tomography (CT) scan showed a 3 cm hyperdense mass occupying the CPA cistern with compression on adjacent cerebellar parenchyma [Figure 1]. No obstructive hydrocephalus was evident on imaging. A thorough preoperative magnetic resonance imaging (MRI) study better characterized the patchy pattern of the round shaped lesion, resulting in three different intensity signals. In T1-weighted images the roughly ovular mass appeared formed by an isointense inner core surrounded by a hypointense ring [Figure 2a], the latter compatible with hemosiderin signal. This hypointense ring was even more evident in T2-weighted images [Figure 2b], which highlighted also a clear hyperintense signal in an adjacent area expression of a recent bleeding (thick arrow). Cerebral angiography ruled out the presence of arteriovenous malformations (AVMs) or pathologic vasculatures.

The patient underwent surgical removal of the lesion performed by a suboccipital approach. Macroscopically, the tumor appeared as a soft, grayish mass surrounded by multiple clots. Histological examination confirmed diagnosis of VN type Antoni A. The patient's neurological status improved gradually with mild persistence of VII and VIII cranial nerve deficits.

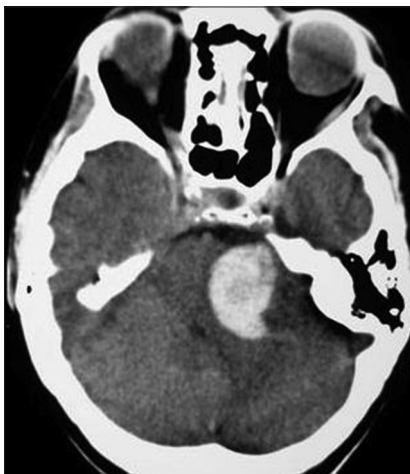

Figure 1: CT scans reveal an hyperintense lesion occupying the CPA cistern with compression of adjacent parenchyma

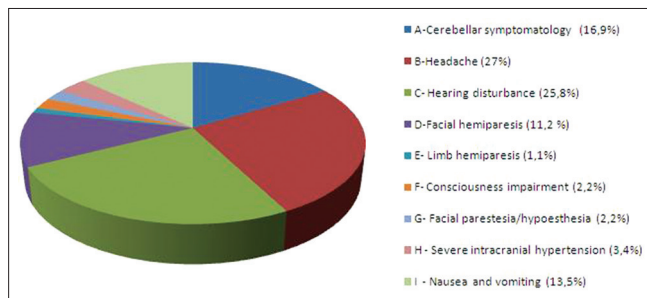


Figure 3: List of the main symptoms related to an acute onset of hemorrhagic VN reported in literature

DISCUSSION

Hemorrhagic CPA mass lesions have been rarely reported in literature,^[3] and to the best of current knowledge neurinomas represent the rarest ones. The first case of hemorrhagic VN was reported by McCoyd *et al.*^[18] in 1974, and only 43 more cases have been reported in the literature so far. Clinical presentation of neurinomas with hemorrhagic findings has been sporadically described also in other locations such as trigeminal,^[24] accessory,^[4] and hypoglossal nerves,^[2,21] or even in cervical junction^[8] and in the spinal cord.^[23]

At time of presentation, patients are on average aged in their fifties (range from 15 to 71 years) with a slight male predominance (M/F: 1/3). The most frequently reported clinical symptoms are: Headache (27%), hearing disturbance (25.8%), cerebellar symptoms (16.9%), nausea, and vomiting (13.5%) [Figure 3]. The mean maximum diameter demonstrated by CT or MRI scans is 3.3 cm (range from 1 to 5.8 cm). Lesion diameter is calculated using the equivalent tumor diameter formula^[22] [Figure 4]. This data could confirm an increased bleeding tendency in lesion bigger than 3 cm, as described in previous reports^[7,15] (For an accurate analysis of the cases described to date in literature, we report the main clinical and histopathological features of hemorrhagic VN in Table 1).

Hemorrhagic VN presents with two basic kind of bleeding: Intratumoral and subarachnoid ones. The first form accounting for the 86.4% of cases (38 out of 44) consists in a hemorrhage inside the substance of the tumor

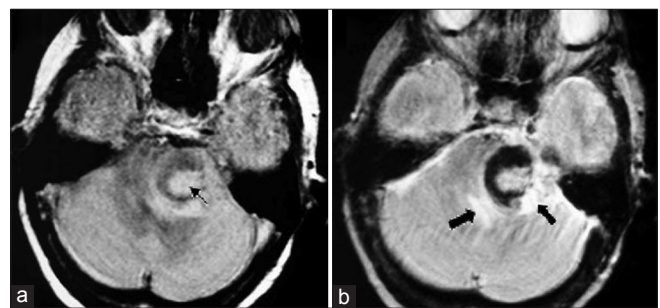


Figure 2: (a) T1 WI shows an isointense part (light arrow) surrounded by an hypointense part. (b) T2 WI shows a more evident hypointense ring and the presence of a hyperintense area surrounding the lesion (thick arrows)

$$\sqrt[3]{2 \cdot (D_1 \cdot D_2 \cdot D_3)}$$

Figure 4: The above formula indicates the equivalent diameter consisting in the cubic root extrapolation of the doubled volume calculated from the lesion major diameters

itself.^[1,6,9,10,17] The mechanism is not fully understood but some histological reports describe focal sinusoidal dilatation and hyaline thickening of the walls that could facilitate spontaneous thrombosis, subsequent necrosis, and hemorrhage.^[27,12] A summary of tumor hemorrhage mechanisms is shown in Table 2. The second kind of bleeding consists in subarachnoid hemorrhage (SAH) reported in 50% of hemorrhagic VN (22 out of 44); thus only in 36.4% of cases the two forms were found concomitantly.

Generally speaking, neurinomas present a characteristic MRI signal pattern consisting in a slight hypointensity or isointensity on T1-weighted image and an increased signal in T2-weighted images. Whenever an intratumoral bleeding occurs, a decreased signal can be noted in correspondence of the center of the acute hematoma, due to the T2 shortening effects of deoxyhemoglobin. In subacute hematomas instead a peripheral hyperintensity extending inward is evident in both T1-weighted and T2-weighted images, explained by a T1 shortening effects of proton electron dipole-dipole secondary to methemoglobin interactions. Finally, in chronic hemorrhages a peripheral hypointensity is noted, and hemosiderin laden macrophages are considered responsible of this pattern.^[4,16,25] In our case, the presence of a peripheral hyperintensity mixed with a

patchy hypointense core reflecting an acute bleeding in the context of a previous one. To this regard, Sprickler *et al.*^[25] suggest that MRI without gadolinium enhancement could be more sensitive to hemorrhage due to the interference of hemoglobin degradation products (methemoglobin and deoxyhemoglobin).

Among the cases described in the literature, most of them showed at the time of histological examination a mixed Antoni A/B pattern (18 out of 24, 75%), whereas only a few exhibited Antoni A pattern, suggesting that the mixed type are the most at risk of bleeding. A recent paper on a cohort of 67 VN patients^[10] found a correlation between immunoistochemical inflammation marker (CD68) and microvessel density suggesting that the intensity of inflammatory reaction could facilitate neovascularization and, in turn, tumoral growth and hemorrhagic tendency.

The case herein described shows a radiologically evident biphasic hemorrhage that could confirm the hypothesis of recurrent bleedings along tumoral growth. Subsequent hemorrhages within the tumor mass seem to be quite rare and only four cases are reported in literature.^[9,13,14,17] Kim *et al.*^[13] described a case of sudden occurrence of headache, nausea, and vomiting in a patient with a hemorrhagic neurinoma previously diagnosed with CT scan; following this clinical exacerbation the patient underwent a second CT showing an enlargement of the intratumoral hemorrhage. Kurata *et al.*^[14] described a progressive hearing loss with episodes of headache; a CT scan, performed 1 year after the onset of symptoms, showed a multi-cystic neurinoma filled with a xanthochromic fluid. Collignon *et al.*^[9] reported a patient presenting with recurrent intraventricular hemorrhage and associated SAH, despite a negative cerebral angiography, in which an intracranial schwannoma was found responsible of those subsequent bleedings.

In our case the second bleeding coincided with a sudden cephalalgia in a clinical history of progressive mild impairment of both VII and VIII cranial nerves. From a review of the literature, headache results as a predominant symptoms (27%, as shown in Table 3) considerably higher when compared with nonhemorrhagic ones if we rule out the cases with increased intracranial pressure (ICP). The sudden onset in a picture of mild symptoms could indeed indicate an acute tumor bleeding as suggested by other authors.^[9,13,14,17]

In contrast, since a subtle clinical presentation is often the only finding in patients with hemorrhagic VN,^[1,5,11,19,21] even the minimal sign of neurologic impairment should alert clinicians about possible hemorrhagic events in patients harboring a VN (Table 3 shows the most common signs and symptoms reported).

Hemorrhagic VN surely represent a very rare entity. The literature review herein presented highlighted the

Table 1: Clinical symptomatology and neuroradiological signs before the acute onset more frequently reported in literature

Clinical signs and symptoms
Headache history
History of seizures or previous neurological deficit
Absence of arterial hypertension
Papilledema due to previous intracranial hypertension
Neuroradiological criteria
Atypical (cerebellar hemispheric) location of the hemorrhage
High or low density tumor core
Extensive surrounding edema
Positive peritumor enhancement
Identification of abnormal vasculature with cerebral angiographic study

Table 2: Histopathological mechanisms of tumor hemorrhage

Foci of small, abnormal, thin-walled vessels in the tumor
Tumor infiltration and weakening of surrounding cerebral vessels
Peritumoral cerebral infarct and edema
Abnormalities of intratumor hemostasis
Mechanical stress on veins near the tumor
Biological tendency of some tumors to invade the walls of vessels
Various combinations of the preceding mechanisms

Table 3: Summary of hemorrhagic vestibular neurinomas reported in literature

Author	Age year/sex	No cases	Size (cm)	ITH	SAH	Symptomatology	Antoni type	Op.	Outcome
McCoyd <i>et al.</i> (1974)	64/F	1	3,4	Y	Y	A, E, I	A, B	N	Death
Fine <i>et al.</i> (1977)	21/F	1	NR-L	Y	Y	B, C	A, B	Y	Good
Gleeson <i>et al.</i> (1978)	54/F	1	4	N	Y	B, C	A	Y	Good
Kasantikul (1979)	64/M	1	NR	N	Y	NR	NR	N	Death
Baba <i>et al.</i> (1980)	71/F	1	NR	Y	N	B, D, I	A, B	Y	Death
Shepard <i>et al.</i> (1981)	37/M	2	NR-L	N	Y	C, F	NR	Y	Good
	66/M		3	N	Y	C, D	NR	Y	Good
Castillo <i>et al.</i> (1982)	61/M	1	3	Y	Y	A, C, I	A	Y	Good
Yonemitsu (1983)	49/M	1	5,8	N	Y	A, B, C, I	A, B	Y	Good
Ihara <i>et al.</i> (1984)	54/M	1	NR	Y	Y	A, B, C, F	A, B	Y	Good
Sasaki <i>et al.</i> (1985)	33/F	1	4,1	Y	Y	B, C, D, I	A, B	Y	Good
Goetting <i>et al.</i> (1987)	19/M	1	3,2	Y	Y	C, D, I	A, B	Y	Good
Arienta <i>et al.</i> (1988)	NR	1	NR	N	Y	NR	NR	NR	NR
Yamamoto (1989)	60/M	1	NR	Y	N	A, B, I	A	Y	Good
Lee and Wang (1989)	65/M	1	5	Y	N	A, B, G, I	A, B	Y	Good
Kurata <i>et al.</i> (1989)	56/M	1	4,9	Y	N	B, C, D	A, B	Y	Good
Fuse <i>et al.</i> (1989)	39/M	1	3	Y	N	B, C, F	A, B	Y	Good
Spickler <i>et al.</i> (1991)	70/M	4	NR-L	Y	N	A, B, C, I	NR	Y	NR
	42/F		3	Y	Y	A	NR	Y	NR
	66/F		2,3	Y	N	A, C	NR	Y	NR
	23/M		4	Y	N	H	NR	NR	NR
Asari <i>et al.</i> (1992)	45/F	4	3,6	Y	N	A, B, C, I	A, B	Y	Good
	31/M		2,9	Y	N	B, C, G	A, B	Y	Good
	63/F		3,6	Y	N	A, C, D, I	A, B	Y	Good
	54/M		2,9	Y	N	A, B, C	A, B	Y	Good
Lessin <i>et al.</i> (1993)	NR	1	NR-L	Y	N	NR	NR	NR	NR
Brady <i>et al.</i> (1994)	70/M	1	NR-L	Y	N	A, C, D, I	NR	Y	Good
Misra <i>et al.</i> (1995)		7	NR						
Chou <i>et al.</i> (1998)	36/M	1	2,5	Y	N	B, C	NR	Y	Good
Kim <i>et al.</i> (2002)	56/M	1	NR	Y	N	B, H	A, B	Y	Good
Collignon <i>et al.</i> (2002)	15/F	1	1	Y	Y	B, D, I	NR	Y	Good
Schlieter <i>et al.</i> (2005)	49/F	1	1,5	Y	N	A, B, C	A	Y	NR
Sarsam <i>et al.</i> (2006)	68/M	1	NR	Y	N	B, C, D	A, B	Y	Good
Chou <i>et al.</i> (2007)	45/F	1	Bil.	Y	N	B, C	A, B	Y	Good
Mandl <i>et al.</i> (2009)	59/F	1	3,3	Y	N	B, H	NR	Y	Good
Gavra <i>et al.</i> (2010)	18/F	1	NR	Y	Y	C	A, B	Y	Good
Mathew <i>et al.</i> (2010)	66/M	1	2,5	Y	N	A, B, I	A	Y	Good
Present case	65/F	1	3	Y	N	BCD	A	Y	Good

A: Cerebellar symptomatology, B: Headache, C: Hearing disturbance, D: Facial hemiparesis, E: Limb hemiparesis, F: Consciousness impairment, G: Facial paresthesia/hypoesthesia, H: Severe neurological impairment due to cerebral compression, I: Nausea and vomiting, NR: Not reported, NR-L: Not reported but described in the article as large

following risk factors for tumoral bleeding: large size, mixed Antoni type, and secondary vascular changes, like increased/dilated vessels and vascular architecture resembling telangiectasia.

The present case and the few similar ones described in literature suggest that subsequent bleedings of VN are associated with a higher morbidity rate. A radiological evidence of hemorrhagic neurinoma should therefore prompt a rapid surgical intervention, even in case of mild presenting symptoms, since only early removal of clots and tumor may provide the best chances of neurological improvement.

REFERENCES

1. Arienta C, Caroli M, Crotti FM. Subarachnoid haemorrhage due to acoustic neurinoma. Case report and review of the literature. *Neurochirurgia (Stuttgart)* 1988;31:162-5.
2. Asari S, Katayama S, Itoh T, Tsuchida S, Furuta T, Ohmoto T. Neurinomas presenting as spontaneous intratumoral hemorrhage. *Neurosurgery* 1992;31:406-11.
3. Bonneville F, Sarrazin JL, Marsot-Dupuch K, Iffenecker C, Cordoliani YS, Doyon D, *et al.* Unusual lesions of the cerebellopontine angle: A segmental approach. *Radiographics* 2001;21:419-38.
4. Caputi F, de Sanctis S, Gazzeri G, Gazzeri R. Neuroma of the spinal accessory nerve disclosed by a subarachnoid hemorrhage: Case report. *Neurosurgery* 1997;41:946-50.

5. Carlson ML, Driscoll CL, Link MJ, Inwards CY, Neff BA, Beatty CW. A hemorrhagic vestibular schwannoma presenting with rapid neurologic decline: A case report. *Laryngoscope* 2010;120 Suppl 4:S204.
6. Castillo R, Watts C, Pulliam M. Sudden hemorrhage in an acoustic neuroma. Case report. *J Neurosurg*, 1982;56:417-9.
7. Chou D, Sampath P, Brem H. Hemorrhagic vestibular schwannoma: An unusual clinical entity. Case report. *Neurosurg Focus* 1998;5:e9.
8. Ciappetta P, D'Urso PI, Colamaria A. Giant craniovertebral junction hemorrhagic schwannoma: Case report. *Neurosurgery* 2008;62:E1166.
9. Collignon FP, Friedman JA, Atkinson JL. Recurrent intraventricular and subarachnoid hemorrhage due to an intracranial schwannoma. Case illustration. *J Neurosurg* 2002;96:377.
10. De Vries M, Hogendoorn PC, Briaire-de Bruyn I, Malessy MJ, Van der Mey AG. Intratumoral hemorrhage, vessel density, and the inflammatory reaction contribute to volume increase of sporadic vestibular schwannomas. *Virchows Arch* 2012;460:629-36.
11. Gavra M, Thanos L, Pomoni M, Batakis N. Spontaneous subarachnoid haemorrhage due to acoustic neurinoma. Case report and review of the literature. *Br J Neurosurg* 2010;24:82-3.
12. Kim DG, Park CK, Paek SH, Choe GY, Gwak HS, Yoo H, et al. Meningioma manifesting intracerebral haemorrhage: A possible mechanism of haemorrhage. *Acta Neurochir (Wien)* 2000;142:165-8.
13. Kim SH, Youm JY, Song SH, Kim Y, Song KS. Vestibular schwannoma with repeated intratumoral hemorrhage. *Clin Neurol Neurosurg* 1998;100:68-74.
14. Kurata A, Saito T, Akatsuka M, Kann S, Takagi H. Acoustic neurinoma presenting with repeated intratumoral hemorrhage. Case report. *Neurol Med Chir (Tokyo)* 1989;29:328-32.
15. Lee JP, Wang AD. Acoustic neurinoma presenting as intratumoral bleeding. *Neurosurgery* 1989;24:764-8.
16. Lessin BD, Alenghat JP. Magnetic resonance imaging of hemorrhagic acoustic neuroma. *Clin Imaging* 1993;17:142-5.
17. Mandl ES, Vandertop WP, Meijer OVV, Peerdeman SM. Imaging-documented repeated intratumoral hemorrhage in vestibular schwannoma: A case report. *Acta Neurochir (Wien)* 2009;151:1325-7.
18. McCoyd K, Barron KD, Cassidy RJ. Acoustic neurinoma presenting as subarachnoid hemorrhage. Case report. *J Neurosurg* 1974;41:391-3.
19. Misra BK, Rout D, Bhiladvala DB, Radhakrishnan V. Spontaneous haemorrhage in acoustic neurinomas. *Br J Neurosurg* 1995;9:219-21.
20. Nicácio JM, Rodrigues JC, Galles MH, Faquini IV, De Brito Pereira CA, Ganau M. Cervical intramedullary schwannoma: A case report and review of the literature. *Rare Tumors* 2009;1:e44.
21. Ohba S, Inaba M, Kinoshita Y, Nakagawa T, Shimizu K, Murakami H. Hypoglossal nerve schwannoma with intratumoral hemorrhage. *Brain Tumor Pathol* 2012;29:43-6.
22. Pallud J, Taillandier L, Capelle L, Fontaine D, Peyre M, Ducray F, et al. Quantitative morphological magnetic resonance imaging follow-up of low-grade glioma: A plea for systematic measurement of growth rates. *Neurosurgery* 2012;71:729-40.
23. Parmar H, Pang BC, Lim CC, Chng SM, Tan KK. Spinal schwannoma with acute subarachnoid hemorrhage: A diagnostic challenge. *AJNR Am J Neuroradiol* 2004;25:846-50.
24. Sastri SB, Dwarakanath S, Chandramouli BA. Trigeminal schwannoma with intratumoral hemorrhage: Report of a case and review of literature. *Neurol India* 2011;59:773-5.
25. Spickler E, Lufkin R, Teresi L, Chiu L, Batzdorf U, Rand R, et al. MR of hemorrhagic acoustic neuromas. *Comput Med Imaging Graph* 1991;15:333-7.
26. Stangerup SE, Caye-Thomasen P. Epidemiology and natural history of vestibular schwannomas. *Otolaryngol Clin North Am* 2012;45:257-68.
27. Wakai S, Yamakawa K, Manaka S, Kakakura K. Spontaneous intracranial hemorrhage caused by brain tumor: Its incidence and clinical significance. *Neurosurgery* 1982;10:437-44.

Disclaimer: The authors of this article have no conflicts of interest to disclose, and have adhered to *SN*'s policies regarding human/animal rights, and informed consent. Advertisers in *SN* did not ask for, nor did they receive access to this article prior to publication.