



Multiple myeloma with central nervous system relapse

Philip A. Egan,¹ Patrick T Elder,² W. Ian Deighan,³ Sheila J.M. O'Connor⁴ and H. Denis Alexander¹

¹Northern Ireland Centre for Stratified Medicine, Ulster University, Derry/Londonderry, Northern Ireland; ²Department of Haematology, North West Cancer Centre, Altnagelvin Area Hospital, Derry/Londonderry, Northern Ireland; ³Department of Clinical Chemistry, Altnagelvin Area Hospital, Derry/Londonderry, Northern Ireland and ⁴Haematological Malignancy Diagnostic Service, St James's Institute of Oncology, Leeds, England, UK

Haematologica 2020
Volume 105(7):1780-1790

ABSTRACT

Central nervous system involvement in multiple myeloma is a rare complication but carries a very poor prognosis. We provide a review of current literature, including presentation, treatment and survival data, and describe our experience in a regional hematologic malignancy diagnosis center where, over a 15-year period, ten cases were identified. Although the median age of onset, frequently between 50-60 years, is comparatively young, those diagnosed usually have a preceding diagnosis of multiple myeloma and often have had several lines of treatment. We discuss putative underlying factors such as prior treatment and associations including possible risk factors and features suggestive of a distinct biology. Central nervous system involvement may be challenging to diagnose in myeloma, displaying heterogeneous symptoms that can be confounded by neurological symptoms caused by the typical features of myeloma or treatment side-effects. We discuss the clinical features, imaging and laboratory methods used in diagnosis, and highlight the importance of considering this rare complication when neurological symptoms occur at presentation or, more commonly, during the disease pathway. In the absence of clinical trial data to inform an evidence-based approach to treatment, we discuss current and novel treatment options. Finally, we propose the establishment of an International Registry of such cases as the best way to collect and subsequently disseminate presentation, diagnostic and treatment outcome data on this rare complication of multiple myeloma.

Correspondence:

H DENIS ALEXANDER
d.alexander@ulster.ac.uk

Received: February 3, 2020.

Accepted: April 14, 2020.

Pre-published: May 15, 2020.

doi:10.3324/haematol.2020.248518

Check the online version for the most updated information on this article, online supplements, and information on authorship & disclosures: www.haematologica.org/content/105/7/1780

©2020 Ferrata Storti Foundation

Material published in *Haematologica* is covered by copyright. All rights are reserved to the Ferrata Storti Foundation. Use of published material is allowed under the following terms and conditions:

<https://creativecommons.org/licenses/by-nc/4.0/legalcode>.

Copies of published material are allowed for personal or internal use. Sharing published material for non-commercial purposes is subject to the following conditions:

<https://creativecommons.org/licenses/by-nc/4.0/legalcode>,

sect. 3. Reproducing and sharing published material for commercial purposes is not allowed without permission in writing from the publisher.



Introduction

Extramedullary disease (EMD) occurs in up to 5% of multiple myeloma (MM) patients, arising *via* hematogenous spread or through the bone cortex into contiguous tissues.^{1,2} It can occur in the skin, lymph nodes, abdominal organs, upper airway and the central nervous system (CNS).³ Plasma cell leukemia (PCL) and extramedullary solitary plasmacytomas are biologically and prognostically distinct conditions and therefore not referred to as EMD.^{2,4} The reported incidence of EMD has increased, possibly in part due to improved survival in MM patients through the use of enhanced treatment modalities, in particular stem cell transplantation (SCT), proteasome inhibitors (PI), and immunomodulatory drugs (IMiD).² According to one study, there has been an increase in EMD detected at the time of MM diagnosis from 4% to 12% between 1971-93 and 2000-2007 patient cohorts, suggesting improved detection by modern imaging techniques.⁵ Since it represents a minority of MM cases, clinical trials have not focused on EMD or any of its subtypes such as MM with CNS involvement (CNS-MM), and thus available data come from single cases and small retrospective studies.⁶

Multiple myeloma with CNS involvement is a rare form of EMD characterized by plasma cell infiltration of the CNS, meninges or cerebrospinal fluid (CSF). It is observed in a small number of MM cases at diagnosis and around a fifth of extramedullary relapses, typically two or three years after the initial MM

diagnosis.⁷⁻¹⁰ Infiltration of the CNS or meninges is rarer in myeloma than in most other hematologic malignancies, affecting well under 1% of patients, and carries a very poor prognosis with reported median overall survival (OS) of seven months or less following its diagnosis.⁸⁻¹³ However, intracerebral plasmacytomas that develop from osseous lesions of the cranium can be treated successfully with radiation, unlike the more serious myelomatous meningitis.¹⁴

Incidence and prevalence

The reported median age of onset of CNS-MM is often younger (50-60-year old age group) than the usual median age of approximately 70 years for MM diagnosis, with up to 20-25% of cases discovered at the initial myeloma diagnosis.^{8,15} However, age at presentation varies between studies, including that of our own data (Table 1), suggesting CNS-MM may be underdiagnosed in older patients. CNS-MM can arise at any stage of MM, and although previous studies suggest a bias towards later stage disease,¹ a recent large-scale retrospective study did not find an association with MM clinical stage.³ The improved OS of MM patients is expected to lead to an increased incidence of EMD and CNS-MM, possibly due to the extra time available for mutations in residual, drug-resistant tumor cells following treatments, that alter expression of adhesion molecules, oncogenes and tumor suppressor genes.¹⁴ Furthermore, there may also be an increase in the time

from MM diagnosis to CNS involvement due to the effectiveness of high-dose chemotherapy and treatment using novel agents.¹⁰ Indeed, patients have often had several lines of treatment by the time CNS-MM is diagnosed.^{8,16}

In our own experience in a regional hematologic malignancy diagnosis center (HMDS, Leeds, UK) over a 15-year period (December 2003-March 2019), ten cases (6 female, 4 male) of CNS-MM were identified (*SO'C, 2019, unpublished data*). Two of these were at MM presentation, whilst the remainder occurred 6-108 months following MM diagnosis (Table 1). The incidence was well under 1% overall (5,238 cases of MM were investigated at HMDS during this period). A higher incidence of female (F) to male (M), and lambda (λ)-restricted to kappa (κ)-restricted, patients, to that found in newly diagnosed MM (ND-MM), was noted. Although absence of CD56 expression was more frequent (4 out of 10 cases) than seen in ND-MM, and one case showed rearranged immunoglobulin heavy chain (IGH), and one loss of 1p with gain of 1q, none of these parameters, including immunophenotypic or acquired cytogenetic aberrations, was seen in adequate numbers to be suggestive of significant association with CNS involvement. Furthermore, bone marrow (BM) interphase fluorescence *in situ* hybridization (iFISH) was not available in the earlier cases, so association of CNS-MM with cytogenetic aberrations predisposing to its development cannot be reported due to small sample size. In all cases, the immunophenotype of the CNS plasma cells was identical

Table 1. Regional hematologic malignancy diagnostic service data (SO'C, 2019, unpublished data).

Case n.	Gender	Age at CNS-MM	MM to CNS-MM (months)	CNS CD56 status	BM FISH	CNS FISH	Additional comments
1	F	76	20	CD56 ^{+/+}	*	No	
2	F	89	18	CD56	*	No	
3	M	71	15	CD56	*	IGH rearranged	Insufficient CSF sample for full FISH panel
4	F	90	0	CD56	*	No	Patient presented with CNS disease (limb weakness and cranial nerve palsy). BM aspirate not received
5	M	55	0	CD56 ^{+/+}	*	No	Patient presented with CNS disease (cranial nerve palsy), BM requested after CSF sample report
6	F	77	6	CD56 ^{+/+}	Deletion <i>TP53</i> , monosomy 13, <i>IGH-MAF</i> translocation	No	Bone plasmacytoma, myeloma diagnosed on BM; plasma cell leukemia 2 months prior to CNS disease
7	M	76	41	CD56 ^{+/+}	Insufficient sample	No	
8	F	57	28	CD56 ⁺	<i>IGH-FGFR3</i> translocation, 1q21 gain, 13q loss	No	Multiple plasmacytomas, myeloma diagnosed on BM
9	M	70	28	CD56	Hyperdiploid (Chr 5, 9, 15)	No	Concurrent plasma cell leukemia and CNS disease
10	F	65	108	CD56 ⁺	1q21.3 gain, 1p32.3 loss	1q21.3 gain, 1p32.3 loss	Identical iFISH cytogenetic abnormalities as at presentation despite 108-month separation
Mean	F:M ratio 1.5:1	73	26	4/10 CD56 ⁺ 2/10 CD56 ^{wk}	n/a	n/a	n/a

Ten multiple myeloma with CNS involvement (CNS-MM) cases were identified over a 15-year period during which 5,238 myeloma cases were assessed. Recent audit shows samples from 20% of cases are too poor to proceed to CD138⁺ plasma cell selection (short sample, hemodiluted, etc.). A neoplastic plasma cell phenotype was identified in all cases by flow cytometry; six cases were CD56⁺ and four were CD56⁻; in all cases the neoplastic phenotype of the CNS-MM plasma cells was identical to the bone marrow (BM) plasma cells. Cytogenetic testing of the central nervous system (CNS) plasma cells was limited by the low volume of cerebrospinal fluid (CSF) sample received for diagnostic workup. As these non-clinical trial samples were diagnosed in a regional diagnostic laboratory, treatment and follow-up information is not available. iFISH: interphase fluorescence *in situ* hybridization; FDG-PET: fluorodeoxyglucose positron-emission tomography; IGH: immunoglobulin heavy chain; Chr: chromosome; n/a: not available; M: male; F: female.

to the BM plasma cells. Overall, the ability to carry out iFISH or molecular testing was compromised in most instances by inadequate sample and/or myeloma cell numbers.

A summary of presentation, treatment and survival data from all papers reviewed is presented in Table 2. Although limited by variations in both the approach and incomplete data in the original manuscripts, this analysis confirms the bias towards a lower M:F ratio, and more frequent λ light chain restriction than in ND-MM without CNS involvement. Furthermore, CNS relapse 26 months following MM diagnosis is in keeping with the duration generally quoted. Because of incomplete data, definitive treatment analysis preceding and following CNS-MM relapse could not be ascertained. However, within these limitations, summary treatment data are annotated in Table 2.

Cause

Multiple myeloma with CNS involvement develops *via* hematogenous dissemination of malignant cells or contiguous spread of the tumor, often associated with PCL and cranial plasmacytoma, respectively.^{1,15} Although it has been suggested that invasion of the CNS is enabled by treatment of MM with immunomodulatory drugs (IMiD), with a report of an MM patient receiving lenalidomide prior to CNS-MM progression,¹⁷ this is not robust evidence. Data for EMD in general suggest that escape from the BM is enabled by mutations to tumor suppressor genes such as *TP53*, oncogenes such as *RAS*, and altered expression of adhesion molecules, as outlined above.¹⁸⁻²¹ These genetic changes may enable proliferation independent of stimuli provided by the BM environment. Furthermore, recent studies do not support a causal link between modern MM treatment and subsequent EMD which may rather be a consequence of longer survival of patients treated with novel agents.^{2,21-23} Additionally, recent increases in EMD prevalence have been seen at MM diagnosis as well as post treatment, and therefore may be due to improved detection.² In another study, the only risk factor for an extramedullary relapse following autologous stem cell transplant (SCT) was EMD at MM diagnosis.⁵ Further weak evidence for a causal relationship between loss of neural cell adhesion molecule (NCAM) (CD56) and CNS-MM, which has a role in cell-cell adhesion, is presented in our own data (Table 1).

Prognosis

The majority of CNS-MM cases are in patients who have received MM therapy prior to CNS involvement (Table 2) and whose survival is generally short and may depend on subsequent treatment.^{6,8,15,24} In a recent retrospective study of 172 CNS-MM patients, Jurczynszyn *et al.* found the median overall survival (OS) from the onset of CNS involvement to be seven months; multivariate analysis revealed that receiving MM therapy before CNS involvement, and having >1 cytogenetic marker of poor prognosis, were risk factors that reduced median OS from 25 months to 5.5 months when either was present, and to two months with both present.⁸ Jurczynszyn *et al.* also showed a median OS of 12 months in patients who received systemic therapy following CNS-MM diagnosis.⁸ Similarly, Chen *et al.* analyzed records for 37 patients treated between 1999-2010 and found a group of nine longer survivors with a median OS of 17.1 months from CNS-MM diagnosis, who were typically treated with

radiotherapy, intrathecal chemotherapy, and IMiD.¹⁵ Majd *et al.* studied nine CNS-MM patients treated between 2008-2013 and observed that the three longest survivors received stem cell transplant after CNS involvement was detected.²⁵ Interestingly, none of these nine patients was receiving maintenance therapy before CNS involvement was detected.²⁵

Table 2. Analysis of data from studies referenced.

Parameter	Mean of all studies (range)			
% detected at MM diagnosis	16			
Months from MM diagnosis to CNS-MM	26 (0 - 216)			
% male	57			
Age	57			
% IgG	38			
% IgA	26			
% IgD	4			
% biclonal	5			
% light chain only	21			
% lambda	50			
iFISH on CSF (compared BM at MM Dx)				
13q loss 33% (38%)				
17p loss 14% (9%)				
1q gain 10% (17%)				
t(4;14) 14% (9%)				
t(11;14) 14% (5%)				
Courses of MM treatment before CNS-MM	2.2			
OS from CNS-MM diagnosis (Months)	4.5			
MM treatment				
IMiD	Pi	SCT	XRT	CNS-MM median OS
✓	✓			2.6
✓		✓		6.0
✓	✓	✓		3.5
	✓			10.9
		✓		3.0
			✓	4.0
None of the above				1.6
CNS-MM treatment		CNS-MM median OS		
IMiD	Pi	SCT	XRT	
✓	✓			5.1
✓			✓	4.7
✓	✓		✓	7.3
		✓		5.8
			✓	2.0
	✓		✓	6.0
		✓	✓	9.0
None of the above				1.0

Summary, where data are available. Means and medians were weighted according to study size and used to calculate an overall mean. MM: multiple myeloma; CNS-MM: multiple myeloma with central nervous system (CNS) involvement; OS: overall survival. Cerebrospinal fluid (CSF) interphase fluorescence *in situ* hybridization (iFISH) data from 21 cases (3 studies) compared to that from 64 cases (12 studies) at diagnosis (Dx) of multiple myeloma (MM Dx). Treatment data obtained from 123 cases of CNS-MM. Prior to CNS-MM diagnosis, 36% of patients received one or more stem cell transplants (SCT); 27% were treated with one or more immunomodulatory drugs (IMiD); 24% received a proteasome inhibitor (PI); and 9% received radiotherapy (XRT). BM: bone marrow.

The recent study of 50 patients with intracranial myeloma by Gozzetti *et al.* illustrates the distinction of osteodural myeloma from CNS-MM, with osteodural myeloma patients showing a median OS more than three times that of patients whose CNS-MM was defined by the presence of plasma cells in CSF.²⁶ Dias *et al.* studied 20 patients with CNS infiltration, 17 of whom had only osteodural myeloma without leptomeningeal involvement and median OS of 40.3 months from the start of CNS involvement, compared to 5.8 months with leptomeningeal involvement.²⁷ Our overall analysis of CNS-MM survival data from studies cited in this review (4.5 months) (Table 2) is in accordance with these figures.

Cytogenetics

The cytogenetic risk factors of MM have been established as prognostic indicators of poor OS in CNS-MM patients. Jurczyszyn *et al.* found del(13q) (39%) and del(17p) (23%) to be the most common.⁸ del(13q) is detected at a similar frequency in CNS-MM to MM, and therefore this study concurs with an older review by Nieuwenhuizen and Biesma which found no association between CNS-MM and del(13q).¹⁸ Jurczyszyn *et al.* also observed the frequency of del(17p) in CNS-MM to be similar to that in MM.⁸ Smaller studies, however, have shown higher rates of del(13q)²⁴ and del(17p) in CNS-MM.¹⁸ A similar pattern of cytogenetic abnormalities is seen in EMD and BM-MM, apart from the t(4;14) *FGFR3/IgH* translocation and del(17p), which showed a higher frequency in EMD.⁷ A small study using immunostaining to compare EMD with BM-MM showed higher aberrant expression of p53 in EMD.²⁰ We advocate caution in the interpretation of some data providing apparently convincing evidence of association between specific acquired cytogenetic aberrations such as del17p,¹⁸ published well over a decade ago when methodologies and iFISH probe quality were questionable. In our own experience, we have failed to detect any significant association between BM iFISH results at diagnosis and co-existing or subsequent development of CNS-MM. Also, we have refined our iFISH technique during the past 15 years, including preselection of CD138 positive plasma cells, and switched to alternative iFISH probes giving clearer signals, so would include our own earlier results in this 'questionable' category.

Other associations

Associations between CNS-MM and several further parameters have been suggested, although some evidence comes from small studies. IgA myeloma represented 27% of CNS-MM cases in the multi-center study by Jurczyszyn *et al.* compared to 21% of the 1,027 newly-diagnosed MM (ND-MM) cases studied by Kyle *et al.*^{8,28} The figure of 27% is very similar to that of 26% in the summary analysis of data referenced in this review (Table 2). The review by Nieuwenhuizen and Biesma shows a higher proportion of cases of λ than κ light chain expression in CNS-MM patients, to that observed in MM.¹ Jurczyszyn *et al.* report 52% of cases expressing κ , 42% λ and 5% both κ and λ , also suggesting a higher frequency of λ -expressing myeloma in CNS-MM than in MM.⁸ Nieuwenhuizen and Biesma also observed 8.3% of CNS-MM cases expressing IgD and 7.3% showing biclonal immunoglobulin expression,¹ both of which are around 2% in ND-MM.²⁸ Other studies suggest a higher likelihood of IgD and light chain

myeloma in CNS-MM.^{25,29} According to Jurczyszyn *et al.*, however, 2% of CNS-MM cases were IgD and 1% had biclonal immunoglobulins; the proportions of cases with light chain myeloma and IgG myeloma were also similar to those seen in ND-MM.^{8,28} Data from studies of EMD in general show a higher prevalence of IgD myeloma among EMD at relapse than in MM;²¹ and cases with EMD at MM diagnosis are more likely to be IgD, λ or non-secretory myeloma.⁵ Our summary analysis of studies referenced in this review identified 4% of cases expressed IgD, and 5% showed biclonal immunoglobulin expression. Overall, however, there is no consensus for associations between light chain restriction, or Ig class, and CNS-MM.

The phenomenon that CNS-MM might be seen more often in autologous SCT (ASCT)-receiving patients might be: a) by chance; b) because specifically those patients may show longer survival and may, with prolonged survival, develop extramedullary site (EM)-MM; and/or c) because EM/CNS-MM specifically homes to sites other than the BM, as has been observed after intensive therapies, such as ASCT and allogeneic-SCT.^{30,31}

Other associations seen in CNS-MM suggest features of late disease or, alternatively, distinct biology. In Nieuwenhuizen and Biesma's 2008 review, 41.3% of CNS-MM were stage 3 disease by the Durie-Salmon staging system.¹ The later study by Jurczyszyn *et al.* found only 27% to be stage 3, using the International Staging System (ISS), although 47% showed elevation of lactate dehydrogenase (LDH), one of the parameters of late-stage MM used in the ISS.⁸ The 18 cases studied by Fassas *et al.* suggest an association between CNS-MM and tumor mass, other EMD, PCL and plasmablastic morphology.³² Nieuwenhuizen and Biesma observed circulating plasma cells (cPC) in 20% of CNS-MM and postulated an association, although the Kyle *et al.* study reported cPC in the majority of ND-MM.²⁸ Some groups propose loss of the cellular adhesion molecule CD56 from the surface of malignant plasma cells as a mechanism of extramedullary spread and, hence, CNS infiltration.³³ Although our own data suggested a higher incidence of CD56 loss in CNS-MM than in ND-MM, data from some other studies do not support this or the presence of a CNS-specific immunophenotype.^{29,34-37} Studies of EMD in general have revealed a putative biological signature which includes increased LDH,^{7,38} along with evidence of a reduction in CD56 expression.^{20,39} We found no difference in features such as cytogenetics, cytology and histopathology between CNS-MM diagnosed at the time of MM diagnosis and those diagnosed at relapse. A summary of studies considered in this review is given in Table 3.

Diagnosis

Multiple myeloma with CNS involvement is difficult to diagnose as it can produce heterogeneous symptoms related to either spinal, cranial or meningeal infiltration, which can be confounded by neurological symptoms caused by the hypercalcemia, uremia, paraproteinemia and bone damage typical in MM,⁹ as well as side-effects of drug therapy and, in some cases, amyloid protein.³² In addition, clinical and laboratory findings of CNS-MM are not always MM-specific; for example, they can be similar to those of leptomeningeal metastases from other hematologic malignancies.⁴⁰ CNS-MM patients can present with impairments to sight, speech, motor and sensory functions, radicular pain, headache, confusion, dizziness and,

less frequently, seizures, vomiting, cranial nerve palsy, lethargy, fever, convulsion, vertigo, hearing loss and incontinence.^{1,8} When such symptoms are seen in MM patients, the ensuing investigations employ imaging, cytological and/or cytometric techniques. The suggested approach to diagnosis of CNS-MM is shown in Figure 1.

Cytological techniques can detect atypical plasma cells and flow cytometry can detect monoclonal CD38/CD138 expressing cells in CSF in approximately 90% of CNS-MM cases, thus confirming the disease.^{8,41} CSF cytology and flow cytometry are both particularly useful since the former can employ immunocytochemistry to identify unknown tumors,⁴² and the latter can be used to distinguish the clonal plasma cells found in MM from polyclonal plasma cells present in CSF in other conditions.⁴³ Furthermore, the presence of a paraprotein, including clonal free light chains (FLC), in CSF obtained from a clean lumbar puncture, can be diagnostic. Minute or undetectable concentrations of paraprotein in the parallel analysis of serum is strong evidence that monoclonal immunoprotein detected in CSF originates from plasma cells in the CNS rather than BM.

In the study of 172 CNS-MM patients by Jurczynszyn *et al.*, magnetic resonance imaging (MRI) of the brain and/or spine showed evidence of CNS involvement in 93% of cases, while computed tomography (CT) scans showed evidence in 81%.⁸ In the patients who underwent imaging, leptomeningeal involvement was found in over half, intracranial mass in approximately half, and both in

approximately 20%.⁸ Fluorescence *in situ* hybridization can reveal EMD and is therefore potentially useful for detection of CNS-MM.^{44,45} Diagnosis of CNS-MM is confirmed using imaging and by detection of monoclonal immunoprotein and/or clonal plasma cells in CSF (Figure 2), with the last of these especially useful for leptomeningeal involvement.^{25,35} Imaging techniques are effective in most cases, although studies estimate a 10% false negative rate.⁸ Detection of plasma cells in CSF provides strong evidence of CNS-MM, although these can be absent when infiltration of parenchymal CNS has occurred.^{8,46}

Treatment of multiple myeloma with CNS involvement: current approaches and future directions

The optimal approach to treatment of CNS-MM is not currently known. The relatively small numbers of patients presenting with this complication means that there is no high quality, prospective clinical trial data to inform an evidence-based approach to therapy. The current approach mirrors those treatment modalities used in lymphoproliferative disease infiltrating the CNS, namely, systemic therapy, intrathecal (IT) therapy, and CNS irradiation, often in combination.

Systemic therapy

Drug therapies successfully employed in MM might be ineffective in CNS-MM due to: tumor resistance after previous therapy,⁸ because they require interaction with the

Table 3. Studies considered in this review.

Reference	Study dates	CNS-MM	Topic of study	Reference	Study dates	CNS-MM	Topic of study
Nieuwenhuizen L and Biesma DH. 2008 ¹	1968-2007	109*	Literature review – diagnosis and treatment	Fassas AB <i>et al.</i> 2002 ³²	1990-2002	18*	Features associated with CNS-MM including cytogenetic
Varga G <i>et al.</i> 2018 ⁸	2007-2017	13	Imaging, CSF analysis, treatment, survival	Chang H <i>et al.</i> 2005 ³³	2005	8	CSF plasma cell, CD56
Jurczynszyn A <i>et al.</i> 2016 ⁸	1995-2014	172	Multicenter study of pathology, imaging and survival	Liu XJ <i>et al.</i> 2015 ³⁴	2015	1	Case description
Paludo J <i>et al.</i> 2016 ⁹	1998-2014	29	Plasma cell detection in CSF	Marini A <i>et al.</i> 2014 ³⁵	2014	1	Flow cytometry for rapid diagnosis, CD56
Gangatharan SA <i>et al.</i> 2012 ¹⁰	2001-2010	7	CNS-MM and novel agents	Lopes AC <i>et al.</i> 2017 ³⁶	2017	1	CD56+ CNS infiltration
Fassas AB <i>et al.</i> 2004 ¹¹	1990-2004	25**	Risk markers including cytogenetic	Kaplan JG <i>et al.</i> 1990 ⁴⁰	1990	63	Presentation and cytology
Lee D <i>et al.</i> 2013 ¹²	2000-2011	17	CSF protein, intrathecal therapy	Mendez CE <i>et al.</i> 2010 ⁴⁶	2010	1	Case study with dural involvement
Abdallah AO <i>et al.</i> 2014 ¹³	1996-2012	35	Diagnosis and treatment	Fukunaga H <i>et al.</i> 2017 ⁴⁴	2017	1	FDG-PET
Chen CI <i>et al.</i> 2013 ¹⁵	1999-2010	37	Treatment and survival	Bommer M <i>et al.</i> 2018 ⁴¹	2017	16	Cytology, flow cytometry and iFISH for diagnosis
Ruiz-Heredia Y <i>et al.</i> 2018 ¹⁷	2018	1	CNS-MM concurrent with PML	Ren H <i>et al.</i> 2017 ⁴²	2017	2	CSF cytology for diagnosis
Chang H <i>et al.</i> 2004 ¹⁸	2000-2003	9	Cytogenetics	Riley JM <i>et al.</i> 2011 ⁵⁸	2011	1	Radiotherapy
Chang WJ <i>et al.</i> 2014 ²⁴	2006-2010	8	Cytogenetics	Katodritou E <i>et al.</i> 2015 ⁵²	2000-2013	31	Treatment with novel agents
Majd N <i>et al.</i> 2016 ²⁵	1998-2012	9	Characterization	Vicari P <i>et al.</i> 2003 ⁵¹	2003*	54	Thalidomide
Gozzetti A <i>et al.</i> 2012 ²⁶	2000-2010	0	Intracranial EMD and novel therapies	Mussetti A <i>et al.</i> 2013 ⁵⁴	2009-2013	1	Pomalidomide
Dias A <i>et al.</i> 2018 ²⁷	2008-2016	3	Brazilian center	Badros A <i>et al.</i> 2017 ⁵⁵	2008-2016	2	Marizomib
Kyle RA <i>et al.</i> 2003 ²⁸	1985-1998	0***	Large-scale MM study	Kauffmann G <i>et al.</i> 2017 ⁵⁹	2017	1	Proton therapy
Marchesi F <i>et al.</i> 2016 ²⁹	2016	4	Flow cytometry	Marron TU <i>et al.</i> 2015 ⁶²	2011-2013	9	FLC measurement in CSF

*Nieuwenhuizen *et al.* (2008)¹ included 18 cases from Fassas *et al.* (2002)³² and 54 cases from Vicari *et al.* (2003).⁵¹ **Fassas *et al.* (2004)¹¹ includes 18 cases from Fassas *et al.* (2002).³² ***Multiple myeloma cases only. CNS: central nervous system; MM: multiple myeloma; CNS-MM: multiple myeloma with CNS involvement; CSF: cerebrospinal fluid; PML: progressive multifocal leukoencephalopathy; FDG-PET: fluorodeoxyglucose positron-emission tomography; FLC: serum free light chain; iFISH: interphase fluorescence *in situ* hybridization.

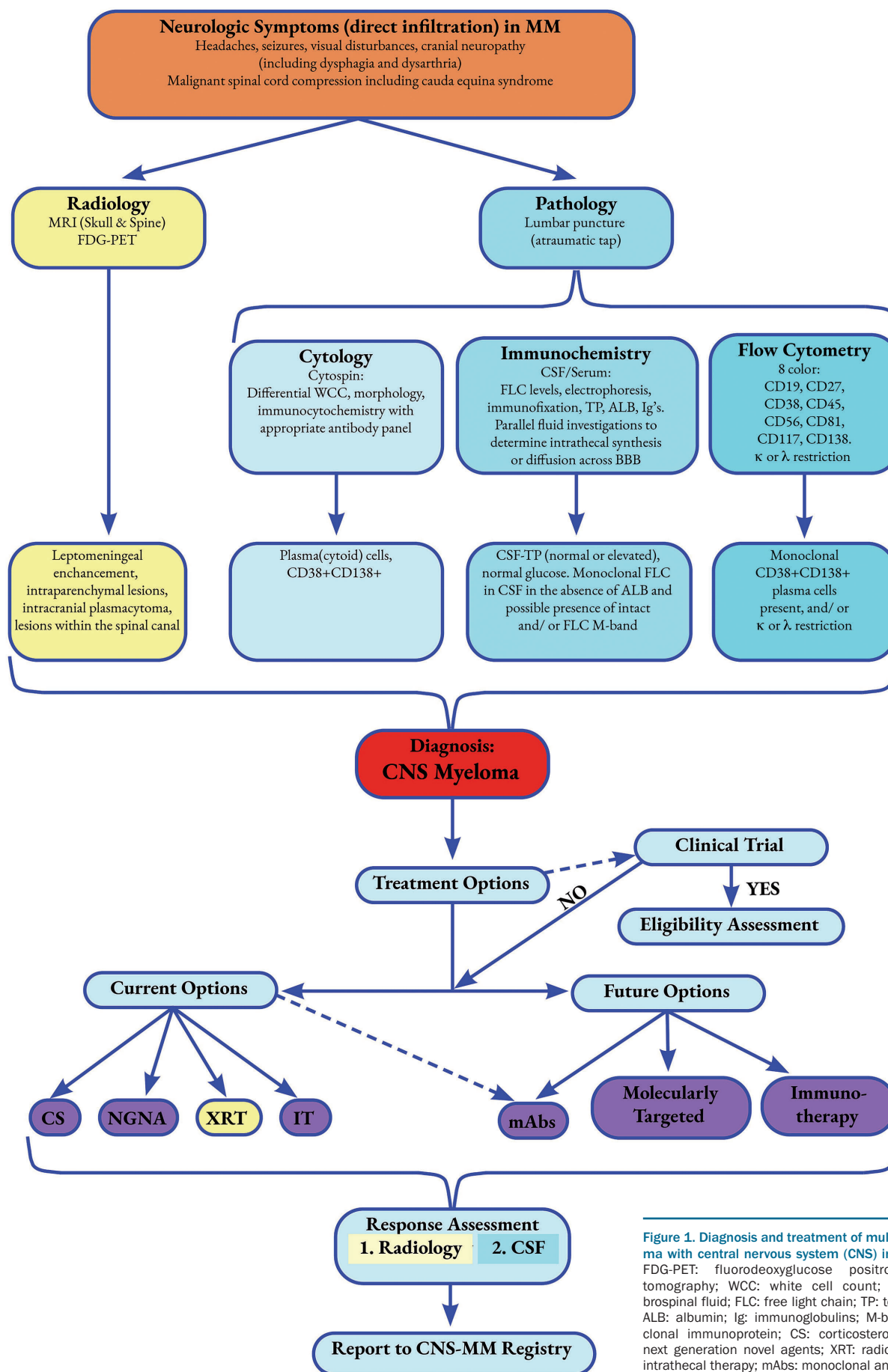


Figure 1. Diagnosis and treatment of multiple myeloma with central nervous system (CNS) involvement. FDG-PET: fluorodeoxyglucose positron-emission tomography; WCC: white cell count; CSF: cerebrospinal fluid; FLC: free light chain; TP: total protein; ALB: albumin; Ig: immunoglobulins; M-band: monoclonal immunoprotein; CS: corticosteroids; NGNA: next generation novel agents; XRT: radiotherapy; IT: intrathecal therapy; mAbs: monoclonal antibodies.

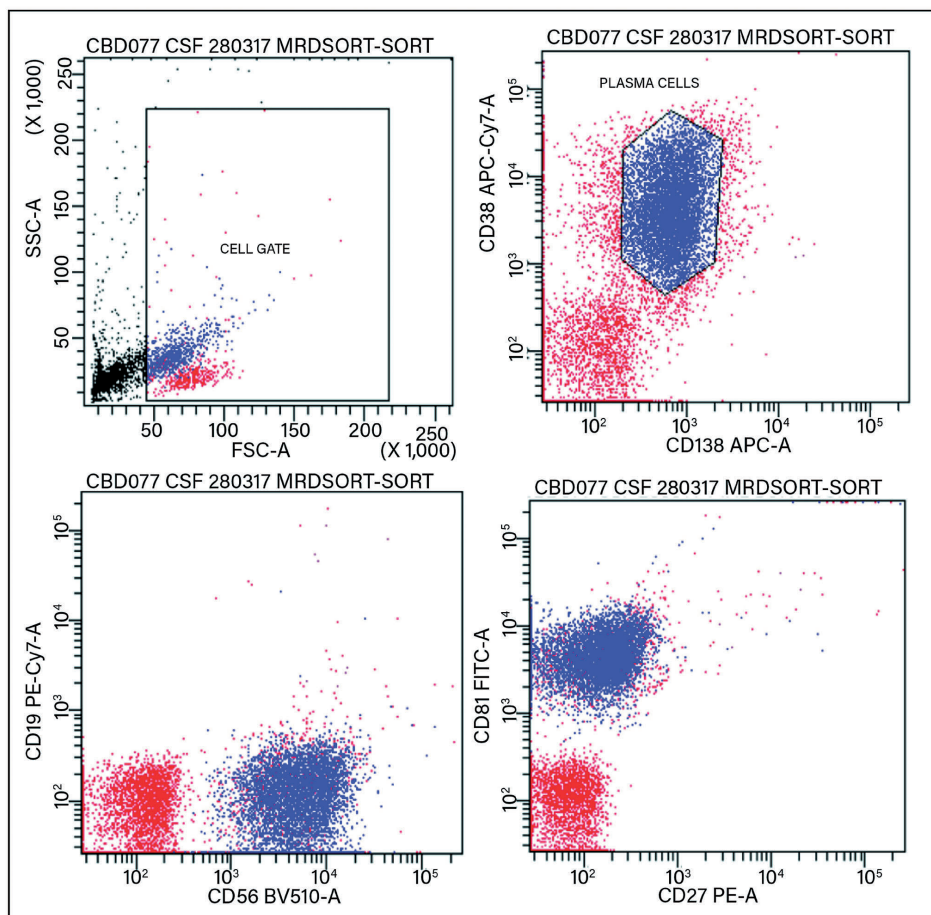


Figure 2. Detection and characterization of myeloma cells in cerebrospinal fluid by flow cytometry. Clonal plasma cells (blue) distinguished from other lymphocyte populations (red) and debris (black).

BM microenvironment,⁴⁷ or the inability to cross the blood-brain barrier (BBB).¹ It has been suggested that, by preventing access of drugs to the brain, the BBB provides a safe haven for the tumor that only radiotherapy or IT administration can overcome.¹⁴ Therefore, when considering systemic therapy, a prerequisite is that the chosen agent(s) have the potential to cross the BBB. Standard cytotoxic regimens lack efficacy in CNS-MM as they are either poor at penetrating the BBB (alkylating agents including melphalan and cyclophosphamide) or ineffective against myeloma cells (high-dose methotrexate or cytarabine). Bendamustine is capable of permeating the BBB and has shown some efficacy in two cases of leptomeningeal relapse of myeloma in combination with thalidomide, dexamethasone and craniospinal irradiation.⁴⁸ High-dose steroids are known to cross the BBB, although they are of limited benefit when used in isolation.

The retrospective analysis of 172 patients with CNS-MM published by Jurczynski *et al.* in 2016 highlighted the importance of incorporating systemic therapy into any planned treatment strategy.⁹ Ninety-seven percent of patients were treated, receiving systemic therapy (76%), radiotherapy (36%), and IT therapy (32%). The only group to have a significantly longer median OS than the untreated group received systemic treatment (OS 12 vs. 3 months), although the number of patients not given sys-

temic therapy was small. Furthermore, these data need to be interpreted with caution as it appears fair to assume that patients in whom systemic treatment could be considered were in better condition to tolerate that treatment when CNS-MM was diagnosed. Hence, this is a potential source of bias in the interpretation of the OS data.

The IMiD thalidomide and lenalidomide have been reported to penetrate the BBB in non-human primates.⁴⁹ In patients, thalidomide has been shown to cross the BBB in leptomeningeal CNS-MM;⁵⁰ however, it is not certain whether it is sufficiently fast-acting to stabilize CNS-MM disease.⁵¹ A 2015 review of 31 Greek patients with CNS-MM showed no survival benefit from the use of novel agents (including thalidomide and lenalidomide) or radiotherapy, although it should be noted that they received no high-dose systemic therapy or SCT.⁵² Chen *et al.*'s 2013 study observed 6 of 9 long-term CNS-MM survivors when treated with IMiD-based therapy (5 thalidomide; 1 lenalidomide), with concomitant multi-dosing IT therapy and cranial/spinal irradiation.¹⁵ The third-generation IMiD pomalidomide has demonstrated activity in EMD²² and good penetrance of the BBB in a murine model.⁵³ Notably, a durable CSF emission has been reported using pomalidomide-dexamethasone treatment.⁵⁴

The current PI in regular clinical use (bortezomib, carfilzomib and ixazomib) are not thought to cross the BBB. However, bortezomib has shown some efficacy when

used in combination with other agents and treatment modalities in CNS-MM.²⁶ This benefit may be due to pathological changes such as inflammation and angiogenesis increasing the permeability of the BBB, thus allowing passage of the drug. Marizomib, a newer PI which can cross the BBB, can be detected in the CNS upon systemic therapy, and has shown potential efficacy in relapsed refractory MM (RRMM), malignant glioma, and a small number of CNS-MM patients.^{16,55}

Intrathecal therapy

The typical intrathecal therapy (IT) therapy regimen administered in CNS-MM is the triplet of IT hydrocortisone, methotrexate and/or cytarabine. This is repeated until clearance of plasma cells and free light chains from the CSF. Its use is controversial as myeloma cells are not thought to be particularly susceptible to methotrexate or cytarabine and it is unlikely to penetrate parenchymal CNS lesions. In two 2013 studies, one of 17 CNS-MM cases showed longer median OS in patients given IT therapy (methotrexate and/or dexamethasone) compared to those who had not,¹² and a study of 37 patients identified a subgroup treated with radiotherapy, IMiD and IT therapy (hydrocortisone, methotrexate and/or cytarabine) who had longer median OS.¹⁵ Since patients were not randomly grouped, the effect of bias cannot be ruled out in these studies. No such positive effect was observed in a 2014 study of eight patients where IT therapy was associated with a median OS of 0.9 months,²⁴ consistent with other studies that have only shown a modest benefit of IT therapy.²⁵ Intrathecal use of rituximab [a humanized anti-CD20 monoclonal antibody (mAb)] has been shown to be safe for this method of administration in the setting of CNS lymphoma⁵⁶ which might suggest a future role for other mAb with anti-myeloma activity being administered by this route.

Cranial or cranial-spinal irradiation

Malignant plasma cells are known to be sensitive to radiotherapy and this treatment modality is the cornerstone of treatment for solitary plasmacytomas of bone and EM plasmacytomas.⁵⁷ Cranial irradiation was reported in one review to show statistically significant benefit in improving survival (median 3 vs. 0.81 months) compared to those not receiving this treatment modality.¹ Targeted radiotherapy can alleviate focal symptoms such as muscle weakness caused by intramedullary spinal cord lesions.⁵⁸ There is evidence that modern radiotherapy techniques can deliver impressive responses in parenchymal CNS-MM lesions without significant myelotoxic sequelae.⁵⁹

Stem cell transplantation

Stem cell transplantation can overcome the poor prognosis of EMD when detected at MM diagnosis,^{60,61} and can have a similar effect in extramedullary relapse as in BM relapse, contradicting the theory that EMD has its own immunological environment that will not support a graft-versus-myeloma response.² In a study of 18 CNS-MM patients, the longest survivor (25 months) had received an allo-SCT after the diagnosis of CNS-MM and had no evidence of CNS-MM relapse at the time of death, suggesting a graft-versus-myeloma effect in the CNS.³² However, unlike in EMD, SCT is not currently considered a standard salvage treatment option in most cases of CNS-MM due to their short survival time.

Current approach

Important factors in the approach to treatment of CNS-MM include the following.

- Accurate diagnosis with a clear understanding of which part of the CNS is involved in order to help target therapy and penetrate site of disease.
- Patient factors, including: a) current BM function and likelihood of being able to tolerate further systemic therapy; b) practicalities of delivering frequent IT therapy; c) potential toxicities of CNS irradiation.
- Acknowledgment of prior lines of systemic therapy, to avoid use of likely disease-resistant agent(s). However, drug resistance in the primary site of the tumor (BM) may not necessarily be replicated in the CNS due to the absence of BM mesenchymal stromal cells which may provide protection to the tumor cells in the BM environment.
- Constraints of treatment options in resource-poor countries.
- Choice of agents known to cross the BBB and with evidence of efficacy in CNS-MM.

Given the limited therapeutic evidence-base described, our current approach to patients with suspected CNS-MM is as follows: accurate diagnosis (as summarized in Figure 1) employing MRI of brain and whole spine, analysis of CSF including serum free light chain (FLC) analysis and multi-color flow cytometry to demonstrate presence of MM cells, and, less commonly, stereotactic brain biopsy as indicated; a backbone of systemic therapy incorporating IMiD and high-dose steroid, and anti-CD38 mAb (see below) depending on local funding directives; and appropriate site-directed CNS irradiation. We would acknowledge that, whilst IT therapy is controversial, it remains part of the standard of care in most centers.

Future direction

Several newer agents have demonstrated activity in B-cell neoplasms including CNS-MM. Monoclonal antibodies are of considerable interest and may play an important part in improving outcomes in CNS-MM. Daratumumab is a humanized mAb specific for CD38 and there is evidence it can cross the intact BBB, being measurable in CSF.⁶² It has shown significant activity in parenchymal CNS-MM in combination with IT therapy and radiotherapy (XRT).⁶³ Also, in a study of relapsed / refractory MM (RRMM) with CNS involvement, a patient treated systemically with daratumumab achieved a response, clearing the CSF of plasma cells, although there was concomitant use of IT therapy.⁶ Isatuximab, another anti-CD38 mAb, has shown efficacy in heavily pre-treated MM patients⁶⁴ and is currently being evaluated in phase III studies in combination with steroid and novel agents.⁶⁵ Elotuzumab is a humanized mAb directed against SLAMF7, also called CS1. SLAMF7 is expressed on most myeloma and natural killer cells, but not on normal tissues. More than 95% of BM myeloma cells have been demonstrated to express SLAMF7. Elotuzumab has been shown to have activity in RRMM in combination with IMiD and steroid.^{66,67} However, there are no current data on its use in CNS-MM.

Translocations involving chromosome 14 are a recurrent finding in MM and approximately 15% of patients demonstrate a t(11;14) (q13;q32) involving the *CCND1/IGH* genes. This juxtaposition results in *CCND1* being overexpressed, leading to kinase activation and tumor cell pro-

liferation. t(11;14) cases in MM are predicted to be BCL-2-dependent resulting in upregulation of anti-apoptotic proteins and thereby making BCL-2 a potential target in this subtype of myeloma.⁶⁸ Venetoclax is a BCL-2 inhibitor and promotes apoptosis *via* a TP53 mutation-independent pathway and is of proven efficacy in patients with chronic lymphocytic leukemia (CLL) with del(17p) and/or TP53 mutation.⁶⁹ It has also been demonstrated to cross the BBB in CLL and is therefore of potential efficacy in CNS-MM.⁷⁰ Several phase III trials are currently underway using venetoclax in patients with RRMM.

The *BRAF* gene encodes protein kinases which regulate the intracellular MAP/ERK signaling pathway involved in cell proliferation and survival. Somatic mutations arising in this gene can lead to oncogenesis. The *BRAF*^{V600E} mutation is seen in up to 10% of MM patients at diagnosis and up to 20% at relapse.^{71,72} Inhibition of this pathway using selective inhibitors of *BRAF*^{V600E} kinase such as vemurafenib, has shown some efficacy in RRMM.⁷³ Other agents targeting this pathway are currently the subject of prospective clinical trials in Europe (*clinicaltrials.gov identifier: NCT02834364*) and in the United States (*clinicaltrials.gov identifier: NCT03091257*). There is evidence such agents may cross the BBB⁷⁴ and at least one case report of a patient with *BRAF*^{V600E} positive CNS-MM relapse responding clinically and radiologically to *BRAF*-MEK inhibitors.⁷⁵

Chimeric antigen receptor-modified T-cell (CAR-T) therapy is in preclinical stages of development for patients with RRMM. The CAR-T construct targets the B-cell maturation antigen (BCMA) which is highly expressed on malignant plasma cells. Soluble BCMA levels are significantly increased in CSF in primary CNS lymphoma.⁷⁶ There is an assumption that CAR-T products cross the BBB given that neurotoxicity is a frequent but generally temporary side effect of this therapy. Its use in treating patients diagnosed with CNS-MM might be impeded by the fact that currently the time from patient leukapheresis to re-infusion with the CAR-T product is approximately four weeks. However, development of 'off-the-shelf' CAR-T products may overcome this obstacle in the future.⁷⁷ Other immunotherapy modalities that target the BCMA include bispecific antibody constructs, including BiTE[®] (bispecific T-cell engager) immuno-oncology therapies, and antibody-drug conjugates (ADC). These products, like CAR-T, have shown efficacy in RRMM.⁷⁸ However, unlike CAR-T, they have the advantage of not requiring *ex vivo* manipulation of patients' cells, therefore conferring a significantly faster time-to-treatment following diagnosis. Studies have suggested sBCMA is not just a

suitable target for drug therapy but that it may also have an important role in MM as a biomarker at diagnosis for its prognostic value, in assessment of response to therapy, and in minimal residual disease monitoring.⁷⁸⁻⁸¹

Conclusions

Prevention of CNS-MM and improved outcomes face significant challenges due to the rarity of the condition, and its rapid progression. Sensitive detection of monoclonal immunoprotein and plasma cells in CSF enables efficient diagnosis and monitoring of treatment response.^{13,82} This, together with new drugs, such as the next generation of PI, mAb and molecularly targeted and immune-oncological therapies, potentially offers improved risk stratification and treatment options. However, there remains a paucity of data to provide a clear evidence base on whether novel agents offer improved therapy for these patients, especially at relapse.^{52,83,84} Furthermore, myelosuppression is a side-effect of myeloma drug treatment, including some of the most recent novel agents such as pomalidomide,⁸⁵ although modern radiotherapy may allow targeting of CNS-MM to avoid the BM and resultant damage to hematopoiesis.⁵⁹

The difficulties in recruiting adequate numbers of patients with CNS-MM to clinical trials is acknowledged. Thus, these innovative treatment approaches may best be achieved through worldwide group efforts to determine optimum diagnostics and treatments, and offer the best evidence-based potential to improve outcomes. We therefore recommend the establishment of an International Registry of such cases as the best way to produce a database to underpin best practice recommendations for both diagnosis and treatment. The design of a 'proforma' to be submitted with each dataset registered will be of paramount importance to enable capture of this information. This approach has been used successfully in, for example, light chain (AL) amyloidosis and POEMS syndrome.

Finally, in EMD, there is evidence that poor prognosis is not linked to advanced disease alone, or to treatment received, but to tumor biology.² Therefore, an improved understanding of this would enable identification of MM cases at risk of CNS relapse. This, in turn, would allow consideration of prophylaxis in patients thus identified, as, for example, in high grade B-cell lymphoma.¹⁶ However, at present, CNS-MM confers a bleak outlook and urgently requires an innovative approach to treatment.

References

- Nieuwenhuizen L, Biesma DH. Central nervous system myelomatosis: review of the literature. *Eur J Haematol.* 2008;80(1):1-9.
- Wirk B, Wingard JR, Moreb JS. Extramedullary disease in plasma cell myeloma: the iceberg phenomenon. *Bone Marrow Transplant.* 2013;48(1):10-18.
- Tirumani SH, Shinagare AB, Jagannathan JP, Krajewski KM, Munshi NC, Ramaiya NH. MRI features of extramedullary myeloma. *AJR Am J Roentgenol.* 2014;202(4):803-810.
- Weberpals J, Fulte D, Jansen L, et al. Survival of patients with lymphoplasmacytic lymphoma and solitary plasmacytoma in Germany and the United States of America in the early 21(st) century. *Haematologica.* 2017;102(6):e229-e232.
- Varettoni M, Corso A, Pica G, Mangiacavalli S, Pascutto C, Lazzarino M. Incidence, presenting features and outcome of extramedullary disease in multiple myeloma: a longitudinal study on 1003 consecutive patients. *Ann Oncol.* 2010;21(2):325-330.
- Varga G, Mikala G, Gopcsa L, et al. Multiple Myeloma of the Central Nervous System: 13 Cases and Review of the Literature. *J Oncol.* 2018;2018:3970169.
- Rasche L, Bernard C, Topp MS, et al. Features of extramedullary myeloma relapse: high proliferation, minimal marrow involvement, adverse cytogenetics: a retrospective single-center study of 24 cases. *Ann Hematol.* 2012;91(7):1031-1037.
- Jurczyszyn A, Grzasko N, Gozzetti A, et al. Central nervous system involvement by multiple myeloma: A multi-institutional retrospective study of 172 patients in daily clinical practice. *Am J Hematol.* 2016;91(6):575-580.

9. Paludo J, Painuly U, Kumar S, et al. Myelomatous Involvement of the Central Nervous System. *Clin Lymphoma Myeloma Leuk*. 2016;16(11):644-654.
10. Gangatharan SA, Carney DA, Prince HM, et al. Emergence of central nervous system myeloma in the era of novel agents. *Hematol Oncol*. 2012;30(4):170-174.
11. Fassas AB, Ward S, Muwalla F, et al. Myeloma of the central nervous system: strong association with unfavorable chromosomal abnormalities and other high-risk disease features. *Leuk Lymphoma*. 2004;45(2):291-300.
12. Lee D, Kalff A, Low M, et al. Central nervous system multiple myeloma-potential roles for intrathecal therapy and measurement of cerebrospinal fluid light chains. *Br J Haematol*. 2013;162(3):371-375.
13. Abdallah AO, Atrash S, Shahid Z, et al. Patterns of central nervous system involvement in relapsed and refractory multiple myeloma. *Clin Lymphoma Myeloma Leuk*. 2014;14(3):211-214.
14. Gertz MA. Pomalidomide and myeloma meningitis. *Leuk Lymphoma*. 2013;54(4):681-682.
15. Chen CI, Masih-Khan E, Jiang H, et al. Central nervous system involvement with multiple myeloma: long term survival can be achieved with radiation, intrathecal chemotherapy, and immunomodulatory agents. *Br J Haematol*. 2013;162(4):483-488.
16. Harrison SJ, Spencer A, Quach H. Myeloma of the central nervous system - an ongoing conundrum! *Leuk Lymphoma*. 2016;57(7):1505-1506.
17. Ruiz-Heredia Y, Sanchez-Vega B, Barrio S, et al. Concurrent progressive multifocal leukoencephalopathy and central nervous system infiltration by multiple myeloma: A case report. *J Oncol Pharm Pract*. 2019;25(4):998-1002.
18. Chang H, Sloan S, Li D, Keith Stewart A. Multiple myeloma involving central nervous system: high frequency of chromosome 17p13.1 (p53) deletions. *Br J Haematol*. 2004;127(3):280-284.
19. Rasmussen T, Kuehl M, Lodahl M, Johnsen HE, Dahl IM. Possible roles for activating RAS mutations in the MGUS to MM transition and in the intramedullary to extramedullary transition in some plasma cell tumors. *Blood*. 2005;105(1):317-323.
20. Sheth N, Yeung J, Chang H. p53 nuclear accumulation is associated with extramedullary progression of multiple myeloma. *Leuk Res*. 2009;33(10):1357-1360.
21. Deng S, Xu Y, An G, et al. Features of extramedullary disease of multiple myeloma: high frequency of p53 deletion and poor survival: a retrospective single-center study of 834 cases. *Clin Lymphoma Myeloma Leuk*. 2015;15(5):286-291.
22. Short KD, Rajkumar SV, Larson D, et al. Incidence of extramedullary disease in patients with multiple myeloma in the era of novel therapy, and the activity of pomalidomide on extramedullary myeloma. *Leukemia*. 2011;25(6):906-908.
23. Varga C, Xie W, Laubach J, et al. Development of extramedullary myeloma in the era of novel agents: no evidence of increased risk with lenalidomide-bortezomib combinations. *Br J Haematol*. 2015;169(6):843-850.
24. Chang WJ, Kim SJ, Kim K. Central nervous system multiple myeloma: a different cytogenetic profile? *Br J Haematol*. 2014;164(5):745-748.
25. Majd N, Wei X, Demopoulos A, Hormigo A, Chari A. Characterization of central nervous system multiple myeloma in the era of novel therapies. *Leuk Lymphoma*. 2016;57(7):1709-1713.
26. Gozzetti A, Cerase A, Lotti F, et al. Extramedullary intracranial localization of multiple myeloma and treatment with novel agents: a retrospective survey of 50 patients. *Cancer*. 2012;118(6):1574-1584.
27. Dias A, Higashi F, Peres ALM, Cury P, Crusoe EQ, Hungria VTM. Multiple myeloma and central nervous system involvement: experience of a Brazilian center. *Rev Bras Hematol Hemoter*. 2018;40(1):30-36.
28. Kyle RA, Gertz MA, Witzig TE, et al. Review of 1027 patients with newly diagnosed multiple myeloma. *Mayo Clin Proc*. 2003;78(1):21-33.
29. Marchesi F, Masi S, Summa V, et al. Flow cytometry characterization in central nervous system and pleural effusion multiple myeloma infiltration: an Italian national cancer institute experience. *Br J Haematol*. 2016;172(6):980-982.
30. Greil C, Engelhardt M, Ihorst G, et al. Allogeneic transplantation of multiple myeloma patients may allow long-term survival in carefully selected patients with acceptable toxicity and preserved quality of life. *Haematologica*. 2019;104(2):370-379.
31. Zeiser R, Deschler B, Bertz H, Finke J, Engelhardt M. Extramedullary vs medullary relapse after autologous or allogeneic hematopoietic stem cell transplantation (HSCT) in multiple myeloma (MM) and its correlation to clinical outcome. *Bone Marrow Transplant*. 2004;34(12):1057-1065.
32. Fassas AB, Muwalla F, Berryman T, et al. Myeloma of the central nervous system: association with high-risk chromosomal abnormalities, plasmablastic morphology and extramedullary manifestations. *Br J Haematol*. 2002;117(1):103-108.
33. Chang H, Bartlett ES, Patterson B, Chen CI, Yi QL. The absence of CD56 on malignant plasma cells in the cerebrospinal fluid is the hallmark of multiple myeloma involving central nervous system. *Br J Haematol*. 2005;129(4):539-541.
34. Liu XJ, Wang FX, Yang L, et al. One Case of Multiple Myeloma with Central Nervous System Infiltration. *Zhongguo Shi Yan Xue Ye Xue Za Zhi*. 2015;23(3):742-745.
35. Marini A, Carulli G, Lari T, et al. Myelomatous meningitis evaluated by multiparameter flow cytometry: report of a case and review of the literature. *J Clin Exp Hematop*. 2014;54(2):129-136.
36. Lopes AC, Xavier FD, de Souza Barroso R, Gomes HR, Sales MM. Massive central nervous system infiltration by CD56-positive plasma cells in multiple myeloma. *Cytopathology*. 2017;28(2):172-174.
37. Flores-Montero J, de Tute R, Paiva B, et al. Immunophenotype of normal vs. myeloma plasma cells: Toward antibody panel specifications for MRD detection in multiple myeloma. *Cytometry B Clin Cytom*. 2016;90(1):61-72.
38. Barlogie B, Smallwood L, Smith T, Alexanian R. High serum levels of lactic dehydrogenase identify a high-grade lymphoma-like myeloma. *Ann Intern Med*. 1989;110(7):521-525.
39. Dahl IM, Rasmussen T, Kauric G, Husebekk A. Differential expression of CD56 and CD44 in the evolution of extramedullary myeloma. *Br J Haematol*. 2002;116(2):273-277.
40. Kaplan JG, DeSouza TG, Farkash A, et al. Leptomeningeal metastases: comparison of clinical features and laboratory data of solid tumors, lymphomas and leukemias. *J Neurooncol*. 1990;9(3):225-229.
41. Bommer M, Kull M, Teleanu V, et al. Leptomeningeal Myelomatosis: A Rare but Devastating Manifestation of Multiple Myeloma Diagnosed Using Cytology, Flow Cytometry, and Fluorescent in situ Hybridization. *Acta Haematol*. 2018;139(4):247-254.
42. Ren H, Zou Y, Zhao Y, et al. Cerebrospinal Fluid Cytological Diagnosis in Multiple Myeloma With Leptomeningeal Involvement: A Report of Two Cases. *Diagn Cytopathol*. 2017;45(1):66-68.
43. Peter A. The plasma cells of the cerebrospinal fluid. *J Neurol Sci*. 1967;4(2):227-239.
44. Fukunaga H, Mutoh T, Tatewaki Y, et al. Neuro-Myelomatosis of the Brachial Plexus - An Unusual Site of Disease Visualized by FDG-PET/CT: A Case Report. *Am J Case Rep*. 2017;18:478-481.
45. Durie BG, Waxman AD, D'Agnolo A, Williams CM. Whole-body (18)F-FDG PET identifies high-risk myeloma. *J Nucl Med*. 2002;43(11):1457-1463.
46. Mendez CE, Hwang BJ, Destian S, Mazumder A, Jagannath S, Vesole DH. Intracranial multifocal dural involvement in multiple myeloma: case report and review of the literature. *Clin Lymphoma Myeloma Leuk*. 2010;10(3):220-223.
47. Anderson KC. Lenalidomide and thalidomide: mechanisms of action-similarities and differences. *Semin Hematol*. 2005;42(4 Suppl 4):S3-8.
48. Nahi H, Svedmyr E, Lerner R. Bendamustine in combination with high-dose radiotherapy and thalidomide is effective in treatment of multiple myeloma with central nervous system involvement. *Eur J Haematol*. 2014;92(5):454-455.
49. Muscal JA, Sun Y, Nuchtern JG, et al. Plasma and cerebrospinal fluid pharmacokinetics of thalidomide and lenalidomide in nonhuman primates. *Cancer Chemother Pharmacol*. 2012;69(4):943-947.
50. Hattori Y, Yabe M, Okamoto S, Morita K, Tanigawara Y, Ikeda Y. Thalidomide for the treatment of leptomeningeal multiple myeloma. *Eur J Haematol*. 2006;76(4):358-359.
51. Vicari P, Ribas C, Sampaio M, et al. Can thalidomide be effective to treat plasma cell leptomeningeal infiltration? *Eur J Haematol*. 2003;70(3):198-199.
52. Katodritou E, Terpos E, Kastritis E, et al. Lack of survival improvement with novel anti-myeloma agents for patients with multiple myeloma and central nervous system involvement: the Greek Myeloma Study Group experience. *Ann Hematol*. 2015;94(12):2033-2042.
53. Li Z, Qiu Y, Personett D, et al. Pomalidomide shows significant therapeutic activity against CNS lymphoma with a major impact on the tumor microenvironment in murine models. *PLoS One*. 2013;8(8):e71754.
54. Mussetti A, Dalto S, Montefusco V. Effective treatment of pomalidomide in central nervous system myelomatosis. *Leuk Lymphoma*. 2013;54(4):864-866.
55. Badros A, Singh Z, Dhakal B, et al. Marizomib for central nervous system-multiple myeloma. *Br J Haematol*. 2017;177(2):221-225.
56. Villela L, Garcia M, Caballero R, Borbolla-

- Escoboza JR, Bolanos-Meade J. Rapid complete response using intrathecal rituximab in a patient with leptomeningeal lymphomatosis due to mantle cell lymphoma. *Anticancer Drugs*. 2008;19(9):917-920.
57. Tsang RW, Campbell BA, Goda JS, et al. Radiation Therapy for Solitary Plasmacytoma and Multiple Myeloma: Guidelines From the International Lymphoma Radiation Oncology Group. *Int J Radiat Oncol Biol Phys*. 2018;101(4):794-808.
 58. Riley JM, Russo JK, Shipp A, Alsharif M, Jenrette JM. Central nervous system myelomatosis with optic neuropathy and intramedullary spinal cord compression responding to radiation therapy. *Jpn J Radiol*. 2011;29(7):513-516.
 59. Kauffmann G, Buerki RA, Lukas RV, Gondi V, Chmura SJ. Case Report of Bone Marrow-Sparing Proton Therapy Craniospinal Irradiation for Central Nervous System Myelomatosis. *Cureus*. 2017;9(11):e1885.
 60. Lee SE, Kim JH, Jeon YW, et al. Impact of extramedullary plasmacytomas on outcomes according to treatment approach in newly diagnosed symptomatic multiple myeloma. *Ann Hematol*. 2015;94(3):445-452.
 61. Wu P, Davies FE, Boyd K, et al. The impact of extramedullary disease at presentation on the outcome of myeloma. *Leuk Lymphoma*. 2009;50(2):230-235.
 62. Vercruyssen M, El Hachem G, Maerevoet M. The Daratumumab crosses the blood brain barrier. *Clin Lymphoma Myeloma Leuk*. 2018;18:S289.
 63. Elhassadi E, Murphy M, Hacking D, Farrell M. Durable treatment response of relapsing CNS plasmacytoma using intrathecal chemotherapy, radiotherapy, and Daratumumab. *Clin Case Rep*. 2018;6(4):723-728.
 64. Martin T, Strickland S, Glenn M, et al. Phase I trial of isatuximab monotherapy in the treatment of refractory multiple myeloma. *Blood Cancer J*. 2019;9(4):41.
 65. Attal M, Richardson PG, Rajkumar SV, et al. Isatuximab plus pomalidomide and low-dose dexamethasone versus pomalidomide and low-dose dexamethasone in patients with relapsed and refractory multiple myeloma (ICARIA-MM): a randomised, multicentre, open-label, phase 3 study. *Lancet*. 2019;394(10214):2096-2107.
 66. Dimopoulos MA, Dytfeld D, Grosicki S, et al. Elotuzumab plus Pomalidomide and Dexamethasone for Multiple Myeloma. *N Engl J Med*. 2018;379(19):1811-1822.
 67. Lonial S, Dimopoulos M, Palumbo A, et al. Elotuzumab Therapy for Relapsed or Refractory Multiple Myeloma. *N Engl J Med*. 2015;373(7):621-631.
 68. Pistofidis R, Ghobrial I. Targeting a Myeloma Translocation for the First Time: The t(11;14) Journey. *The Hematologist*. 2018;15(4).
 69. Campo E, Cymbalista F, Ghia P, et al. TP53 aberrations in chronic lymphocytic leukemia: an overview of the clinical implications of improved diagnostics. *Haematologica*. 2018;103(12):1956-1968.
 70. Reda G, Cassin R, Dovrtelova G, et al. Venetoclax penetrates cerebrospinal fluid and may be effective in chronic lymphocytic leukemia with central nervous system involvement. *Haematologica*. 2019;104(5):e222-e223.
 71. Ruiz-Heredia Y, Sanchez-Vega B, Onecha E, et al. Mutational screening of newly diagnosed multiple myeloma patients by deep targeted sequencing. *Haematologica*. 2018;103(11):e544-e548.
 72. Kortum KM, Mai EK, Hanafiah NH, et al. Targeted sequencing of refractory myeloma reveals a high incidence of mutations in CRBN and Ras pathway genes. *Blood*. 2016;128(9):1226-1233.
 73. Hyman DM, Puzanov I, Subbiah V, et al. Vemurafenib in Multiple Nonmelanoma Cancers with BRAF V600 Mutations. *N Engl J Med*. 2015;373(8):726-736.
 74. Davies MA, Saiag P, Robert C, et al. Dabrafenib plus trametinib in patients with BRAF(V600)-mutant melanoma brain metastases (COMBI-MB): a multicentre, multicohort, open-label, phase 2 trial. *Lancet Oncol*. 2017;18(7):863-873.
 75. Da Via MC, Solimando AG, Garitano-Trojaola A, et al. CIC Mutation as a Molecular Mechanism of Acquired Resistance to Combined BRAF-MEK Inhibition in Extramedullary Multiple Myeloma with Central Nervous System Involvement. *Oncologist*. 2020;25(2):112-118.
 76. Thaler FS, Laurent SA, Huber M, et al. Soluble TACI and soluble BCMA as biomarkers in primary central nervous system lymphoma. *Neuro Oncol*. 2017;19(12):1618-1627.
 77. Benjamin R. Advances in off-the-shelf CAR T-cell therapy. *Clin Adv Hematol Oncol*. 2019;17(3):155-157.
 78. Shah N, Chari A, Scott E, Mezzi K, Usmani SZ. B-cell maturation antigen (BCMA) in multiple myeloma: rationale for targeting and current therapeutic approaches. *Leukemia*. 2020;34(4):985-1005.
 79. Sanchez E, Li M, Kitto A, et al. Serum B-cell maturation antigen is elevated in multiple myeloma and correlates with disease status and survival. *Br J Haematol*. 2012;158(6):727-738.
 80. Ghermezi M, Li M, Vardanyan S, et al. Serum B-cell maturation antigen: a novel biomarker to predict outcomes for multiple myeloma patients. *Haematologica*. 2017;102(4):785-795.
 81. Bujarski S, Soof C, Li M, et al. Baseline and Early Changes in Serum B-Cell Maturation Antigen Levels Predict Progression Free Survival and Response Status for Multiple Myeloma Patients in a Phase 1 Trial Evaluating Ruxolitinib, Lenalidomide and Methylprednisolone. *Blood*. 2018;132:1894.
 82. Marron TU, Ramanathan L, Chari A. Diagnostic utility of measuring free light chains in the cerebrospinal fluid of patients with multiple myeloma. *Clin Lymphoma Myeloma Leuk*. 2015;15(6):e127-131.
 83. Qu X, Chen L, Qiu H, et al. Extramedullary manifestation in multiple myeloma bears high incidence of poor cytogenetic aberration and novel agents resistance. *Biomed Res Int*. 2015;2015:787809.
 84. Gozzetti A, Cerase A, Bocchia M. Central nervous system multiple myeloma. *Ann Hematol*. 2016;95(3):519-520.
 85. Lacy MQ, Allred JB, Gertz MA, et al. Pomalidomide plus low-dose dexamethasone in myeloma refractory to both bortezomib and lenalidomide: comparison of 2 dosing strategies in dual-refractory disease. *Blood*. 2011;118(11):2970-2975.