

# Femoral Osteonecrosis after Medial Femoral Condyle Bone Graft Harvest

Jorge G. Boretto, MD\*  
 Gonzalo Altube, MD\*  
 Gerardo L. Gallucci, MD\*  
 Hector R. Narvaez, MD†  
 Pablo De Carli, MD\*

**Summary:** The medial femoral condyle vascularized graft has become a useful resource in reconstructive microsurgery due to the rate of bony union, and the low rate of complication. We report osteonecrosis of the medial femoral condyle in a 65-year-old woman after harvesting a corticocancellous medial femoral condyle graft to treat a tarsometatarsal nonunion. We were not able to define whether a vascular or mechanical disorder could be the ultimate cause. However, because of the severity of the complication, we suggest informing patients who will undergo a medial femoral condyle flap about this infrequent complication. (*Plast Reconstr Surg Glob Open* 2018;6:e1792; doi: 10.1097/GOX.0000000000001792; Published online 19 June 2018.)

The vascularized bone graft from the medial femoral condyle (MFC) was first described by Hertel and Masquelet<sup>1</sup> as a pedicled reverse-flow flap. Then in 2000, Doi et al.<sup>2</sup> described harvesting the free corticocancellous graft based on the articular branch of the descending genicular artery (DGA), which they used to treat scaphoid nonunion. Since then, many other articles report the results of the MFC flap in reconstructive surgery.<sup>3,4</sup> The versatility, rate of bony union, and the low rate of complications reported with this flap has made it one of the most commonly used vascularized bone grafts in different size osseous defects.

We report osteonecrosis of the knee after the MFC flap was harvested in a 65-year-old woman.

## CASE REPORT

A 65-year-old woman was referred 2 years after the last surgery due to a tarsometatarsal (TMT) nonunion of her left foot. She has two previously failed TMT arthrodesis.

She had recently retired and had no history of previous or chronic disease. She was not a smoker and had a body mass index (BMI) of 27. She had neither history of knee arthroscopy nor corticoid intake. Bone mineral den-

sitometry showed evidence of neither osteopenia nor osteoporosis. On the dorsum of her foot, scar coverage was observed due to the previous surgeries. The pedal pulse was absent. Angiogram showed no patency of the pedal artery.

On account of the 2 previous failed surgeries, and the scar coverage of the foot, a corticocancellous MFC graft (5×1.5×2.6 cm; Fig. 1), was in-setting in her left foot to accomplish the desired TMT arthrodesis. At postoperative day 4, bone scintigraphy showed arterial patency. Bony union was confirmed by computed tomography scan at postoperative week 8 (Fig. 2). At 1-year follow-up, the patient has no pain in her left foot or in her right knee.

At postoperative month 14, the patient presented at consultation complaining of medial pain in her left knee related to activities. She denied a history of knee trauma. Magnetic resonance imaging examination showed osteonecrosis of the medial condyle (Figs. 3, 4). At postoperative month 23, the patient was scheduled for unicompartmental knee arthroplasty. At 2-year follow-up from the arthroplasty, the patient has no pain in her knee.

## DISCUSSION

We present, to our knowledge, a complication of the MFC flap that has not been previously reported.

Although donor-site pain is relatively common, it is considered that it resolves in 4–7 weeks. However, longer period or permanent knee pain has been reported in a few cases.<sup>4,5</sup> We consider that persistent medial knee pain is related to an unnoticed injury to the saphenous nerve branches or medial cutaneous nerve.

Biomechanical studies have shown that a large MFC can be harvested safely with no risk of femur fracture in axial load application or torsional stability.<sup>6,7</sup> Contrary to the optimistic results of the biomechanical studies, a fe-

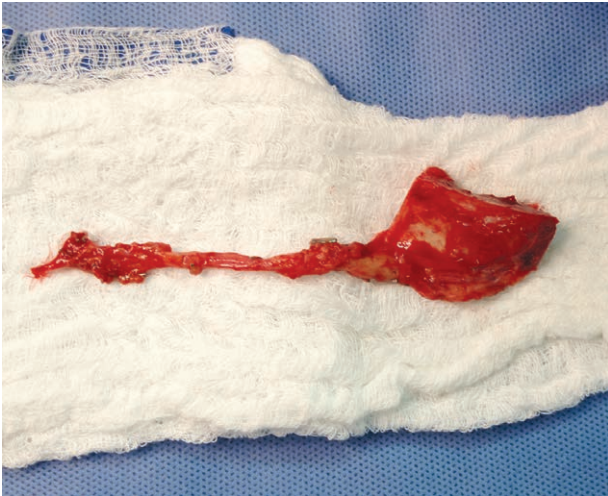From the \*Hand and Upper Extremity Surgery Department, “Dr Carlos E. Ottolenghi” Orthopaedic Institute, Hospital Italiano de Buenos Aires, Argentina, Ciudad de Buenos Aires, Argentina; and †Knee Surgery Department, “Dr Carlos E. Ottolenghi” Orthopaedic Institute, Hospital Italiano de Buenos Aires, Argentina, Ciudad de Buenos Aires, Argentina.

Received for publication February 26, 2018; accepted April 3, 2018.

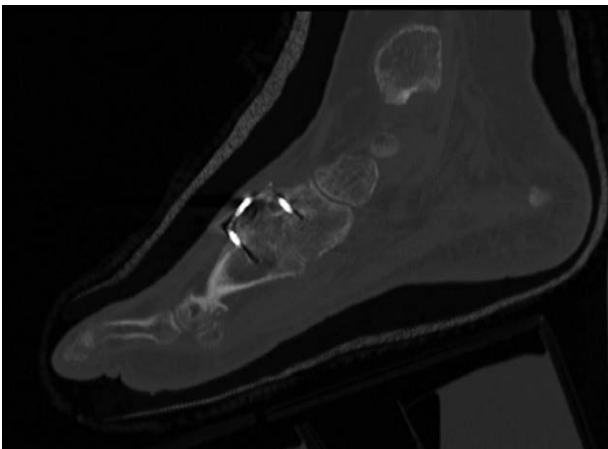
Copyright © 2018 The Authors. Published by Wolters Kluwer Health, Inc. on behalf of The American Society of Plastic Surgeons. This is an open-access article distributed under the terms of the Creative Commons Attribution-Non Commercial-No Derivatives License 4.0 (CCBY-NC-ND), where it is permissible to download and share the work provided it is properly cited. The work cannot be changed in any way or used commercially without permission from the journal.

DOI: 10.1097/GOX.0000000000001792

**Disclosure:** The authors have no financial interest to declare in relation to the content of this article. The Article Processing Charge was paid for by the authors.



**Fig. 1.** The corticocancellous MFC graft harvested with its vascular pedicle.



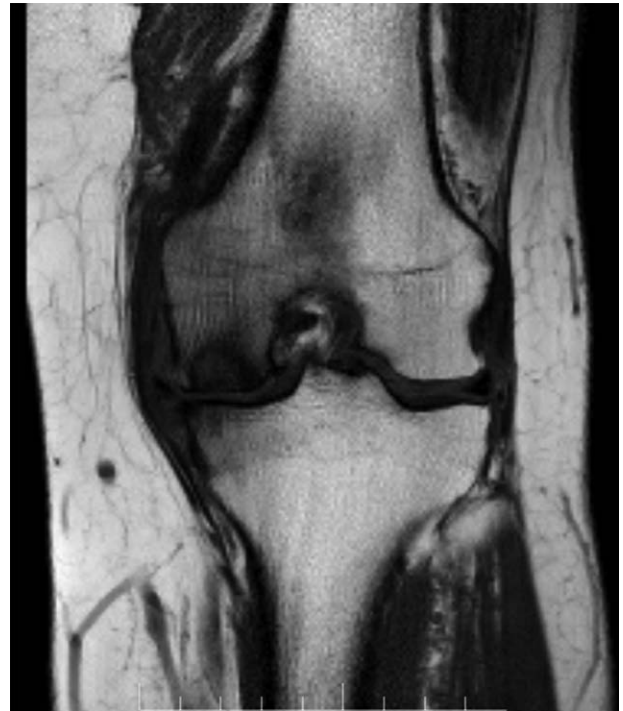**Fig. 2.** Computed tomography scan showing bone union at postoperative week 8.

mur fracture has been reported after harvesting a large flap ( $15 \times 4 \times 1$  cm).<sup>4</sup>

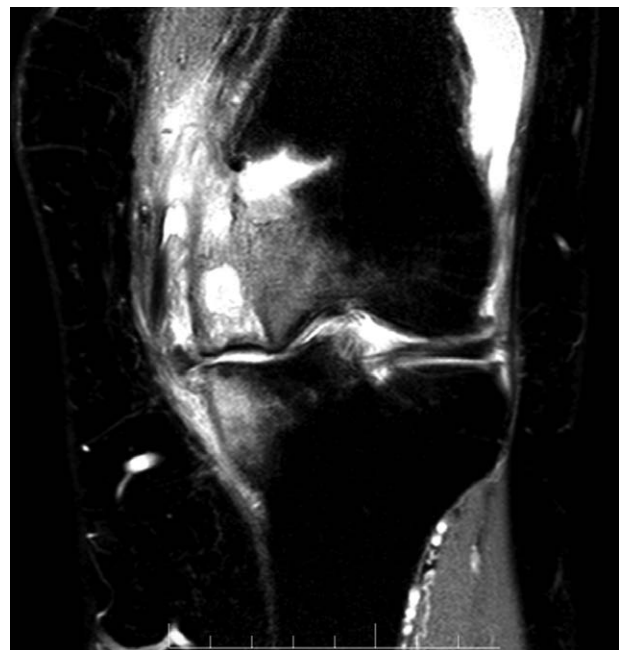With regard to the vascular anatomy, the medial condylar region has periosteal supply from the DGA and superior medial genicular artery. The interconnections of these vessels suggest that DGA harvest would not result in segmental condylar necrosis.

Spontaneous osteonecrosis of the knee, a disorder of unknown etiology, is more commonly seen in women who are 60 years or older and is typically unilateral. The predominance of MFC osteonecrosis could be explained by the study of Reddy and Fredericks<sup>8</sup> who demonstrated that the MFC has limited intraosseous blood supply with apparent watershed areas. However, Yamamoto et al.<sup>9</sup> found a plentiful intraosseous vascular supply without any watershed line.

Although osteonecrosis was thought to occur secondary to ischemia, there is evidence that it may be due to subchondral insufficiency fractures. Zanetti et al.<sup>10</sup> in a prospective study aimed to investigate the association between osteonecrosis and reduced bone mineral density



**Fig. 3.** Coronal T1-weighted magnetic resonance imaging sequence demonstrating a focal subchondral T1 hypointense abnormality with a band of lower intensity.



**Fig. 4.** Coronal Short-T1 Inversion Recovery (STIR) sequence demonstrating severe surrounding marrow edema involving greater than two-thirds the area of the MFC, and the area where the graft was harvested.

based on the fact that most affected patients are elderly, potentially osteoporotic women. They found that osteoporosis and osteopenia are commonly found in patients with osteonecrosis of the knee. They also found that two-thirds of their patients were overweight or obese, suggesting that

increased BMI may be another risk factor for mechanical overload.

In our patient, whether vascular insufficiency, subchondral fracture, or both could have occurred because of the harvested graft, we were not able to define the ultimate cause. Also, we could not discern if harvesting the graft was the sole cause or if it was a triggering factor in an at-risk patient. However, after this rare complication, we suggest informing patients who will undergo a MFC graft about this possibility. It should be noted that this suggestion is highly recommended for patients at-risk for spontaneous osteonecrosis, which includes female patients over 60 years of age mainly with osteoporosis or with an increased BMI.

**Jorge G. Boretto, MD**

Tte. Gral. Juan D. Perón 4190

C1199ABB

Ciudad Autónoma de Buenos Aires

Argentina

E-mail: jorge.boretto@hospitalitaliano.org.ar

#### REFERENCES

- Hertel R, Masquelet AC. The reverse flow medial knee osteoperiosteal flap for skeletal reconstruction of the leg. Description and anatomical basis. *Surg Radiol Anat.* 1989;11:257–262.
- Doi K, Oda T, Soo-Heong T, et al. Free vascularized bone graft for nonunion of the scaphoid. *J Hand Surg Am.* 2000;25:507–519.
- Del Piñal F, García-Bernal FJ, Regalado J, et al. Vascularised corticoperiosteal grafts from the medial femoral condyle for difficult non-unions of the upper limb. *J Hand Surg Eur Vol.* 2007;32:135–142.
- Brandtner C, Hachleitner J, Bottini GB, et al. Microvascular medial femoral condylar flaps in 107 consecutive reconstructions in the head and neck. *Br J Oral Maxillofac Surg.* 2016;54:614–618.
- Elgammal A, Lukas B. Vascularized medial femoral condyle graft for management of scaphoid non-union. *J Hand Surg Eur Vol.* 2015;40:848–854.
- Katz RD, Parks BG, Higgins JP. The axial stability of the femur after harvest of the medial femoral condyle corticocancellous flap: a biomechanical study of composite femur models. *Microsurgery.* 2012;32:213–218.
- Endara MR, Brown BJ, Shuck J, et al. Torsional stability of the femur after harvest of the medial femoral condyle corticocancellous flap. *J Reconstr Microsurg.* 2015;31:364–368.
- Reddy AS, Frederick RW. Evaluation of the intraosseous and extraosseous blood supply to the distal femoral condyles. *Am J Sports Med.* 1998;26:415–419.
- Yamamoto H, Jones DB Jr, Moran SL, et al. The arterial anatomy of the medial femoral condyle and its clinical implications. *J Hand Surg Eur Vol.* 2010;35:569–574.
- Zanetti M, Romero J, Dambacher MA, et al. Osteonecrosis diagnosed on MR images of the knee. Relationship to reduced bone mineral density determined by high resolution peripheral quantitative CT. *Acta Radiol.* 2003;44:525–531.