

# Endovascular treatment of critical lower limb ischemia caused by giant cell arteritis

Rohan H. P. McLachlan, MD, BMS,<sup>a,b</sup> Andrew F. Lennox, MBBS, MSc, FRACS,<sup>a,c</sup>  
Ramon L. Varcoe, MBBS, MS, FRACS,<sup>a,b,c</sup> and Shannon D. Thomas, BSc Med Hons, MBBS, FRACS,<sup>a,b,c</sup>  
Sydney and Kensington, New South Wales, Australia

## ABSTRACT

Giant cell arteritis (GCA) is a well-known cause of cranial vasculitis often presenting with headache and jaw claudication. Here we report the case of a woman suffering GCA who presented with critical lower limb ischemia. Despite best medical therapy, she developed progressive calf claudication and ulceration of the right foot. The findings on workup were highly suggestive of GCA involving the superficial femoral artery. The limb was successfully revascularized with angioplasty and placement of a drug-eluting stent. GCA is an important cause of lower limb ischemia and should be considered in patients without evidence of atherosclerosis. Endovascular intervention is a feasible treatment of critical limb ischemia due to GCA and has been shown to be safe in this case. (*J Vasc Surg Cases and Innovative Techniques* 2019;5:31-4.)

**Keywords:** Endovascular procedures; Balloon angioplasty; Lower limb ischemia; Critical limb ischemia; Giant cell arteritis

Giant cell arteritis (GCA) is a granulomatous vasculitis affecting medium-sized and large vessels, usually in patients older than 50 years.<sup>1</sup> Temporal arteritis is the most well known clinical phenotype, but GCA is increasingly recognized as a systemic disease with extracranial involvement and complications.<sup>2</sup> Symptomatic involvement of the lower limbs is uncommon but can be devastating, sometimes resulting in limb amputation.<sup>3</sup> Here, with consent of the patient, we describe a case of successful angioplasty and stenting of a lower limb artery affected by GCA.

## CASE REPORT

A 76-year-old woman presented to her vascular surgeon with an infected, nonhealing right foot ulcer and severe claudication. The ulcer developed from a traumatic blister and had been present for >3 months. She was able to mobilize 50 meters before developing right calf claudication.

Two years earlier, she had been diagnosed with GCA by means of an abnormal biopsy finding after presenting with temporal arteritis. Routine workup for extracranial GCA included whole body computed tomography angiography that demonstrated evidence of vasculitis in multiple locations including bilateral

lower limbs. This peripheral artery disease (PAD) was monitored with arterial duplex ultrasound (DUS) every 3 to 6 months. She had dyslipidemia but denied any history of smoking, diabetes, or stroke. Her medications included aspirin 100 mg daily, clopidogrel 75 mg daily, methotrexate 10 mg weekly, prednisone 2 mg daily, and atorvastatin 40 mg daily.

Examination demonstrated a "punched out" ulcer inferior to the medial malleolus and deep to the dorsal tendons of the foot (Fig 1). The ulcer had a sloughy base with purulent exudate and had increased in size during the preceding month. Pedal pulses were not palpable. Inflammatory markers were not elevated, with an erythrocyte sedimentation rate of 4 mm/h (normal range, 1-35 mm/h) and a C-reactive protein level of 0.5 mg/L (normal range, 0.0-5.0 mg/L). Bacterial culture of the ulcer confirmed multiorganism infection. DUS revealed a diffusely narrowed right superficial femoral artery (SFA) with several 50% to 75% long-segment stenoses and a peak systolic velocity of 305 cm/s. The number and severity of stenoses had increased compared with a DUS examination performed 2 months earlier. Ankle-brachial index measurements on the right had ranged from 0.83 to 0.98 during this period.

A number of factors implicated GCA as the cause of her PAD. Multiple imaging modalities illustrated findings that are typical of GCA.<sup>4</sup> Computed tomography angiography demonstrated high-grade stenoses and focal dilations (beading) in multiple locations including bilateral SFAs. DUS demonstrated multiple long-segment stenoses caused by concentric hypoechoic wall thickening in both SFAs with filling defects seen in some segments (Fig 2). There was no evidence of significant atherosclerotic disease on any imaging as expected in a patient with a paucity of factors for development of atherosclerosis. In addition, she had already been diagnosed with extracranial GCA after coronary angiography revealed acute severe disease involving the ostia of two coronary arteries. These lesions had been stented in the context of a myocardial infarction 2 years earlier.

Her disease had remained stable for 2 years with nonoperative management that comprised immunosuppression, antiplatelet

---

From the Department of Vascular Surgery, Prince of Wales Hospital, Sydney<sup>a</sup>; the Faculty of Medicine, University of New South Wales, Kensington<sup>b</sup>; and The Vascular Institute, Prince of Wales Hospital, Sydney.<sup>c</sup>

Author conflict of interest: none.

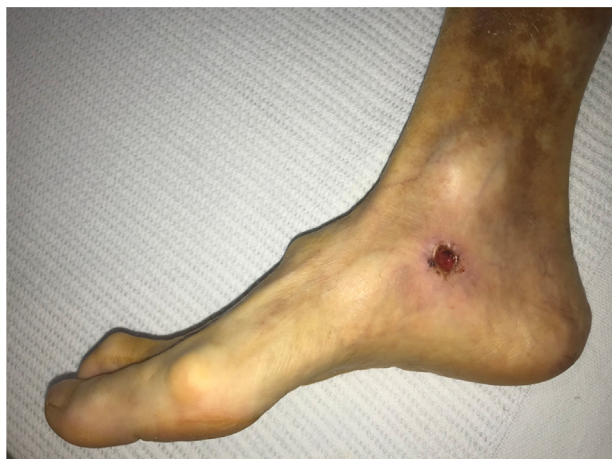Correspondence: Shannon D. Thomas, BSc Med Hons, MBBS, FRACS, Department of Vascular Surgery, Prince of Wales Hospital, Barker Ave, Randwick, Sydney, NSW 2030, Australia (e-mail: [sthomas@unsw.edu.au](mailto:sthomas@unsw.edu.au)).

The editors and reviewers of this article have no relevant financial relationships to disclose per the Journal policy that requires reviewers to decline review of any manuscript for which they may have a conflict of interest.

2468-4287

Crown Copyright © 2018 Published by Elsevier Inc. on behalf of Society for Vascular Surgery. This is an open access article under the CC BY-NC-ND license (<http://creativecommons.org/licenses/by-nc-nd/4.0/>).

<https://doi.org/10.1016/j.jvscit.2018.09.008>

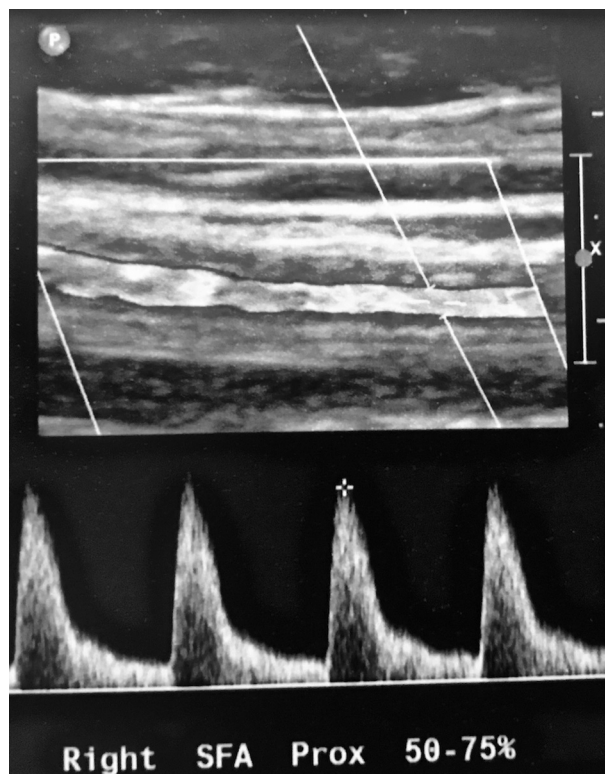


**Fig 1.** Nonhealing ulcer deep to the dorsal tendons of the foot.

therapy, and regular exercise. However, she now had critical limb ischemia with tissue loss and ultrasound evidence that her PAD had progressed. There was no evidence of an acute inflammatory flare of her GCA and therefore no role for more aggressive immunosuppression.

Given the limb-threatening situation of infection, ischemia, and immunosuppression, urgent revascularization was performed. A 5F retrograde puncture was performed in the left common femoral artery and a 6F 45-cm Flexor Ansel Guiding Sheath (Cook Medical, Bloomington, Ind) was passed into the right common femoral artery. Diagnostic angiography confirmed a diffusely diseased SFA (Fig 3, A) and proximal popliteal artery with a luminal diameter of approximately 2.5 mm. The distal popliteal, anterior tibial, and peroneal arteries were all spared of disease but diminutive with diameters of approximately 2.5 mm, 1.3 mm, and 1.5 mm, respectively. The posterior tibial artery was occluded from its origin. After systemic anticoagulation with heparin, the lesion was crossed intraluminally with a V-18 ControlWire guidewire (Boston Scientific, Marlborough, Mass), and a 3-mm SpiderFx embolic protection device (Medtronic, Minneapolis, Minn) was deployed in the distal popliteal artery. A distal filter was used because multiple filling defects seen on DUS presented a potential embolic source. SFA and popliteal artery angioplasty was performed with 3- × 200-mm and 5- × 200-mm predilation with Armada 0.018-inch balloons (Abbott Vascular, Abbott Park, Ill), then 5- × 150-mm, 5- × 150-mm, and 8- × 50-mm Lutonix drug-coated balloons (C. R. Bard, Murray Hill, NJ). Digital subtraction angiography demonstrated a new flow-limiting dissection in the distal SFA after angioplasty. A 6- × 80-mm Eluvia drug-eluting stent (Boston Scientific) was placed to cover the dissection with primary complete expansion. The filter was retrieved with multiple macroscopic pale emboli suggestive of fibrin. There was an excellent final angiographic result with no residual stenosis in the SFA (Fig 3, B).

Postoperatively, she had strong femoral, popliteal, and pedal pulses. After 2 months, the ulcer had completely healed and her claudication had resolved. DUS demonstrated a patent right

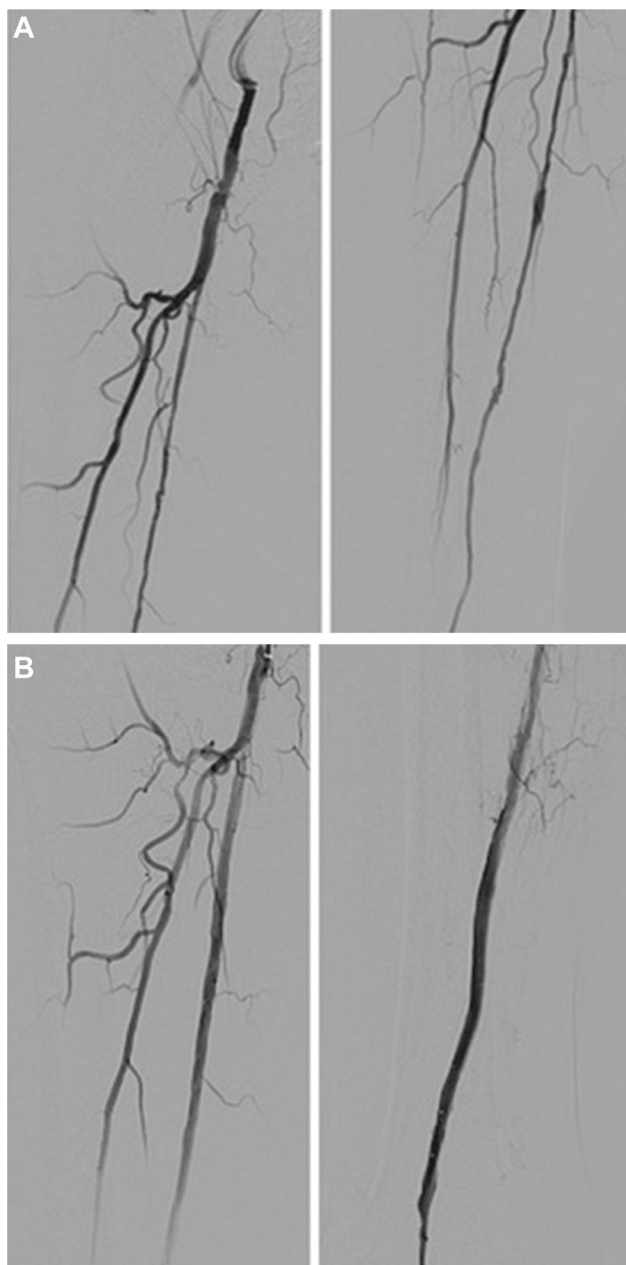


**Fig 2.** Duplex ultrasound (DUS) of the proximal superficial femoral artery (SFA) demonstrating a long-segment 50% to 75% stenosis caused by concentric hypoechoic wall thickening with monophasic flow at a velocity of 216 cm/s.

SFA and stent with no significant stenosis, and the ankle-brachial index was 1.12. She was re-examined after 6 months and reported right calf claudication after walking 100 meters. There was a new >75% stenosis just proximal to the stent and 50% to 75% restenosis at the proximal segment of the stent. This was presumed to be a result of neointimal hyperplasia from balloon trauma, given that there was no clinical or biochemical evidence of an acute inflammatory flare of GCA. The remainder of the SFA and stent appeared widely patent with no significant stenosis. Angioplasty with drug-coated balloons is planned to reduce the risk for development of in-stent thrombosis.

## DISCUSSION

Extracranial vasculitis is a well-recognized feature of GCA. In the only systematic review of extracranial GCA, the reported rate of any type of extracranial large-vessel involvement was between 68% and 83% based on two prospective studies of 35 patients<sup>5</sup> and 40 patients.<sup>6</sup> The rate of femoropopliteal involvement was 12% to 53% from the same review.<sup>7</sup> The SFA is by far the most commonly affected lower limb vessel, and involvement is almost always bilateral.<sup>3,4</sup> Symptomatic lower limb GCA appears to be a rare entity,<sup>7</sup> but when it occurs, the most common symptom is claudication, often rapid in onset, or progression as in this case.<sup>8,9</sup> Given the high



**Fig 3. A,** Widely patent common femoral artery and profunda femoris artery, long-segment stenoses of the superficial femoral artery (SFA) and popliteal artery with a small region of preserved vessel before angioplasty. **B,** Widely patent proximal SFA after angioplasty, patent distal SFA and popliteal artery after insertion of an Eluvia drug-eluting stent.

rate of lower limb involvement, GCA should be considered in patients with lower limb ischemia who have a paucity of risk factors for atherosclerosis or rapidly progressing symptoms, even in the clinical absence of cranial GCA. Conversely, patients with GCA should be screened for extracranial involvement including the lower limbs.

A reasonable first-line treatment is immunosuppressive therapy, antiplatelet therapy, and exercise.<sup>2</sup> However, it is not always successful, and in some patients the vascular response to injury characterized by intimal hyperplasia seen in large-vessel vasculitis may progress despite corticosteroids.<sup>10</sup> Progression to critical limb ischemia despite best medical therapy is an indication for operative management.

Revascularization bypass surgery should be avoided in the acute inflammatory phase because of high rates of early occlusion.<sup>11</sup> In disease that is refractory to immunosuppressive therapy, balloon angioplasty and stenting may play a role. In a series of 30 symptomatic upper limb stenoses or occlusions affected by GCA, the primary and secondary patency rates after balloon angioplasty were 65% and 90%, respectively.<sup>12</sup> We found just three cases in the literature in which endovascular stenting of known GCA lesions has been attempted, twice on the internal carotid artery<sup>13,14</sup> and once on the vertebral artery.<sup>15</sup> All three cases were deemed successful.

In this case, endovascular intervention was chosen as primary therapy for multiple reasons. Suitable vein conduit was not present, and the risk for postoperative infection was high. Drug-coated therapies were chosen for their anti-inflammatory effect, given the cause and length of the lesion. We considered the patient to be at significant risk of restenosis, given the literature experience on upper limb GCA demonstrating high recurrence rates in long-segment lesions.<sup>12</sup> Recent data strongly suggest a long-term patency benefit over plain balloon angioplasty in atherosclerotic lesions.<sup>16</sup> After 6 months, there was evidence of restenosis despite drug-coated therapies. Plain angioplasty and stenting may have resulted in more rapid and severe restenosis or even early occlusion. The flow-limiting dissection in the SFA after low-pressure angioplasty was concerning as it implies significant fragility of the vessel wall. Poor vessel wall integrity confers a susceptibility to trauma and may be a contributing factor to the restenosis seen at the locations of angioplasty 6 months earlier.

## CONCLUSIONS

GCA is a rare but treatable cause of critical limb ischemia and should be considered in patients without evidence of atherosclerosis. Endovascular angioplasty with stenting is a feasible treatment option for critical lower limb ischemia due to GCA. Embolic protection may be prudent in the context of chronic vessel wall inflammation. Close postoperative surveillance is important, given the significant risk of restenosis.

## REFERENCES

1. Calvo-Romero JM. Giant cell arteritis. *Postgrad Med J* 2003;79:511-5.
2. Tatò F, Hoffmann U. Giant cell arteritis: a systemic vascular disease. *Vasc Med* 2008;13:127-40.

3. Kermani TA, Matteson EL, Hunder GC, Warrington KJ. Symptomatic lower extremity vasculitis in giant cell arteritis: a case series. *J Rheumatol* 2009;36:2277-83.
4. Czihal M, Tato F, Rademacher A, Kuhlencordt P, Schulze-Koops H, Hoffmann U. Involvement of the femoropopliteal arteries in giant cell arteritis: clinical and color duplex sonography. *J Rheumatol* 2012;39:314-21.
5. Blockmans D, Ceuninck LD, Vanderschueren S, Knockaert D, Mortelmans L, Bobbaers H. Repetitive <sup>18</sup>F-fluorodeoxyglucose positron emission tomography in giant cell arteritis: a prospective study of 35 patients. *Arthritis Rheum* 2006;55:131-7.
6. Prieto-González S, Arguis P, García-Martínez A, Espígol-Frigolé G, Tavera-Bahillo I, Butjosa M, et al. Large vessel involvement in biopsy-proven giant cell arteritis: prospective study in 40 newly diagnosed patients using CT angiography. *Ann Rheum Dis* 2012;71:1170-6.
7. Lensen KD, Voskuyl AE, Comans EF, van der Laken CJ, Smulders YM. Extracranial giant cell arteritis: a narrative review. *Neth J Med* 2016;74:182-92.
8. Dupuy R, Mercie P, Neau D, Longy-Boursier M, Conri C. Giant cell arteritis involving the lower limbs. *Rev Rhum Engl Ed* 1997;64:500-3.
9. Le Hello C, Levesque H, Jeanton M, Cailleux N, Galateau F, Peillon C, et al. Lower limb giant cell arteritis and temporal arteritis: followup of 8 cases. *J Rheumatol* 2001;28:1407-12.
10. Weyand CM, Goronzy JJ. Medium- and large-vessel vasculitis. *N Engl J Med* 2003;349:160-9.
11. Joyce JW. The giant cell arteritides: diagnosis and the role of surgery. *J Vasc Surg* 1986;3:827-33.
12. Both M, Aries PM, Müller-Hülsbeck S, Jahnke T, Schäfer PJ, Gross WL, et al. Balloon angioplasty of arteries of the upper extremities in patients with extracranial giant-cell arteritis. *Ann Rheum Dis* 2006;65:1124-30.
13. Chausson N, Olindo S, Signate A, Cohen-Tenoudji P, Aveillan M, Saint-Vil M, et al. [Bilateral intracerebral angioplasty in a patient with stroke caused by giant cell arteritis]. *Rev Neurol (Paris)* 2010;166:328-32.
14. Guerrero AM, Sierra-Hidalgo F, Calleja P, Navia P, Campollo J, Diaz-Guzman J. Intracranial internal carotid artery angioplasty and stenting in giant cell arteritis. *J Neuroimaging* 2015;25:307-9.
15. Dementovych N, Mishra R, Shah QA. Angioplasty and stent placement for complete occlusion of the vertebral artery secondary to giant cell arteritis. *J Neurointerv Surg* 2012;4:110-3.
16. Laird JR, Schneider PA, Tepe G, Brodmann M, Zeller T, Metzger C, et al. Durability of treatment effect using a drug-coated balloon for femoropopliteal lesions: 24-month results of IN.PACT SFA. *J Am Coll Cardiol* 2015;66:2329-38.

Submitted Jul 5, 2018; accepted Sep 25, 2018.