

Gastric Metastases from Lung Adenocarcinoma Causing Gastrointestinal Bleeding

Ayman Qasrawi, MD¹, Mouhanna Abu Ghanimeh, MD¹, Sakher Albadarin, MD², and Osama Yousef, MD²

¹Internal Medicine Department, University of Missouri-Kansas City School of Medicine, Kansas City, MO

²Division of Gastroenterology, University of Missouri-Kansas City School of Medicine, Kansas City, MO

ABSTRACT

Metastases to the stomach are rare. They are commonly asymptomatic, and the diagnosis is usually established during autopsy. We present a patient known to have stage IV lung adenocarcinoma who presented with melena and shock. Endoscopy revealed multiple gastric nodules, which were proved to be metastatic deposits from her lung cancer. The possibility of gastric metastases should be kept in mind in patients presenting with gastrointestinal bleeding. Endoscopy and biopsy remain the gold standard for diagnostic testing in such patients.

INTRODUCTION

Lung cancer is a major cause of cancer-related death worldwide. It metastasizes commonly to the adrenal glands, bone, liver, brain, and kidneys, only infrequently to the digestive system.¹ Gastric metastases from lung cancer are very rare and are usually asymptomatic.² Endoscopy along with biopsy and immunohistochemistry remain the gold standard for diagnosis of stomach metastases.²⁻⁵

CASE REPORT

A 69-year-old woman with a past medical history of stage IV lung adenocarcinoma with brain metastases and extensive local invasion presented to the emergency department with hypotension and melena for 4 days. She was diagnosed with lung cancer 1 month prior to this presentation, when she presented with a 3-week history of pleuritic chest pain, dyspnea, dysphagia, and hoarseness of voice. At her initial presentation, computed tomography scan of the chest with contrast showed a large left upper lobe spiculated nodule with extensive lymphadenopathy that encased major blood vessels, the esophagus, and the trachea with impending tracheal obstruction due to intraluminal tumor mass (Figure 1). The patient underwent a bronchoscopy with endobronchial ultrasound with biopsy of the tracheal mass and level 7 lymph node. An endobronchial stent was placed. Pathology was positive for poorly differentiated tumor cells. Immunohistochemistry demonstrated diffuse positivity for thyroid transcription factor 1 (TTF-1), focal positivity for cytokeratin 7, and was negative for cytokeratin 20, which is most consistent with adenocarcinoma of lung origin. Genetic studies revealed a B-Raf proto-oncogene V600E mutation. The patient received radiotherapy and was discharged home.

At her second presentation, the patient was found to be tachycardic and hypotensive. She was admitted to the intensive care unit. Laboratory tests showed hemoglobin 7.2 g/dL, platelet count $175 \times 10^3/\mu\text{L}$, creatinine 1.4 mg/dL, and blood urea nitrogen 26 mg/dL. Coagulation and other laboratory studies were unremarkable. The patient was resuscitated with intravenous fluids and packed red blood cells, and she was started on pantoprazole infusion. Esophagogastroduodenoscopy (EGD) detected no active bleeding. A red spot that could not be washed and three nodules with overlying mucosa, which appeared inflamed and ulcerated, were found in the body of the stomach

ACG Case Rep J 2017;4:e25. doi:10.14309/crj.2017.25. Published online: February 15, 2017.

Correspondence: Ayman Qasrawi, University of Missouri Kansas City School of Medicine, 2411 Holmes St, Kansas City, MO, 64108-2792 (ahqasrawi@gmail.com).



Copyright: © 2017 Qasrawi et al. This work is licensed under a Creative Commons Attribution-NonCommercial-NoDerivatives 4.0 International License. To view a copy of this license, visit <http://creativecommons.org/licenses/by-nc-nd/4.0>.

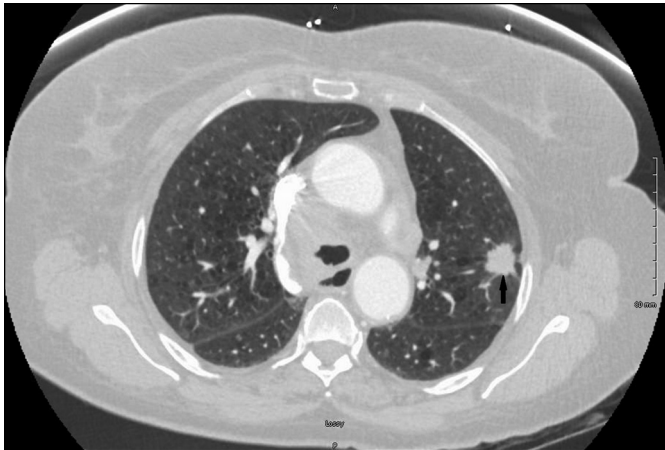

Figure 1. Chest computed tomography scan with contrast showing a left upper lobe spiculated nodule (arrow), which is consistent with primary lung cancer.

(Figure 2). The esophagus and duodenum were normal. Biopsy of the nodules revealed poorly differentiated tumor cells with a similar morphological and immunohistochemical profile to the tumor from the tracheal biopsy, therefore consistent with metastatic deposits from her poorly differentiated lung adenocarcinoma (Figure 3). The patient was stabilized, but due to her overall clinical situation and cancer history, she opted for hospice care. She succumbed to progressive disease approximately 2 weeks later.

DISCUSSION

Gastrointestinal (GI) tract involvement in lung cancer is uncommon, ranging from 0.5 to 14% of cases.²⁻⁶ In addition to lung cancer, malignant melanoma and breast cancer are

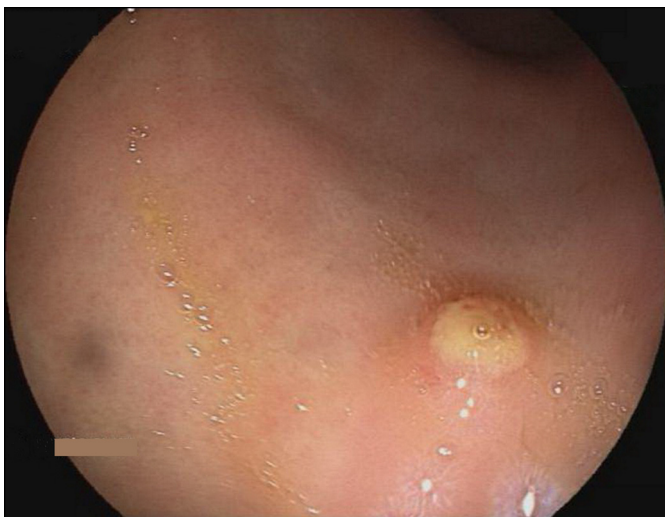


Figure 2. EGD showing 1 of 3 nodules with overlying mucosa, which appeared inflamed and ulcerated. Biopsy showed metastatic deposits from lung primary.

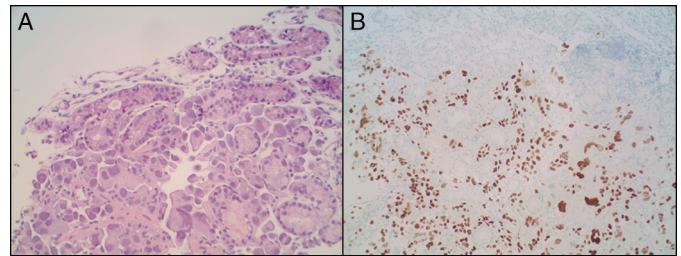


Figure 3. (A) Staining of the stomach nodule biopsy showing poorly differentiated malignant-appearing cells (hematoxylin & eosin, 20x). (B) Immunohistochemistry positive for TTF-1, indicating lung origin (10x).

common causes of GI metastases.⁴ Other malignancies that have been rarely reported to metastasize to the GI tract include osteosarcoma, renal cell carcinoma, Merkel cell carcinoma, and germ-cell tumors.⁴ Lung cancer has been shown to metastasize to almost any site within the GI tract, with reported cases of lung cancer metastases to the appendix, colon, and anus.^{2,7-9}

Hematogenous metastases to the stomach are rare, despite its rich blood supply, with a postmortem incidence of 0.2-9%.^{2,6,10,11} In most studies, breast cancer, malignant melanoma, and lung cancer were the most common malignancies metastasizing to the stomach.¹⁰⁻¹² The rarity of stomach metastases is poorly understood. One hypothesis suggests that certain cytokines may affect the organ specificity in hematogenous metastases.¹⁰ Hematogenous metastases to the stomach are usually submucosal.¹⁰ The macroscopic appearance of these submucosal gastric metastasis has been described radiographically as a bull's eye sign and endoscopically as volcano-like or umbilicated on the tip.^{3,4,10,13} These lesions are found more commonly in the upper and middle thirds of the stomach, although there are many reported cases for metastases in the lower third and even the pylorus.^{2,4,12,14} In addition to ulcerated lesions, some gastric metastases from lung cancer appear endoscopically to be diffuse with indistinct borders (type IV tumors per Borrmann's classification).^{15,16} Because most gastric metastases are submucosal, the majority remain asymptomatic.^{2,10} When symptomatic, they can cause nausea, vomiting, epigastric pain, anemia, pyloric obstruction, or even acute complications such as gastric perforation.^{2,6,14} GI bleeding was also reported.^{17,18} It can be difficult to determine whether these manifestations are due to GI involvement by the malignancy or due to other causes, such as initiation of chemotherapy.³

Endoscopy remains one of the most effective methods to diagnose GI and gastric metastases.^{2,4,12} Many studies describe a role for positron emission tomography in the diagnosis of both symptomatic and asymptomatic cases.¹² Immunohistochemistry is very useful in the diagnostic workup as well.^{3,5} Several different cytokeratins (CKs) and other

protein markers are widely used to distinguish the origin of carcinomas. The most popular are CK7, CK20, and TTF-1.⁵ TTF-1 is normally expressed in thyroid and pulmonary epithelial cells.^{5,19} Lung adenocarcinomas usually demonstrate a CK7+/CK20– immunoprofile.³ On the other hand, GI adenocarcinomas are usually CK20+ and CK7–.³ Therefore, a CK7+/CK20– pattern combined with use of a more specific marker of lung tissue origin, such as TTF-1, could be an effective tool to differentiate between lung and GI adenocarcinomas with a reasonable degree of certainty.⁵

In general, the presence of GI and gastric metastasis in lung cancer is associated with widespread disease and poor prognosis.^{3,5} Interestingly, our patient had a mutated *BRAF* gene. A large meta-analysis of 10 studies found a 3% rate of a mutated *BRAF* gene in patients with non-small cell lung cancer and a significant association with adenocarcinoma histology.²⁰ There is limited data to indicate whether this mutation can be attributed to certain clinical manifestations such as GI metastasis. Further research in this field can provide us with more answers in the future.

DISCLOSURES

Author contributions: A. Qasrawi and M. Abu Ghanimeh wrote and revised the manuscript. S. Albadarin edited the manuscript and provided the endoscopy images. O. Yousef edited the final manuscript. A. Qasrawi is the article guarantor.

Financial disclosure: None to report.

Informed consent was obtained from the deceased patient's next of kin for this case report.

Received November 6, 2016; Accepted December 8, 2016

REFERENCES

- Steinhart AH, Cohen LB, Hegele R, Saibil FG. Upper gastrointestinal bleeding due to superior mesenteric artery to duodenum fistula: A rare complication of metastatic lung carcinoma. *Am J Gastroenterol*. 1991;86(6):771-4.
- Antler AS, Ough Y, Pitchumoni CS, Davidian M, Thelmo W. Gastrointestinal metastases from malignant tumors of the lung. *Cancer*. 1982;49(1):170-2.
- Yang CJ, Hwang JJ, Kang WY, et al. Gastro-intestinal metastasis of primary lung carcinoma: Clinical presentations and outcome. *Lung Cancer*. 2006;54(3):319-23.
- Kadakia SC, Parker A, Canales L. Metastatic tumors to the upper gastrointestinal tract: Endoscopic experience. *Am J Gastroenterol*. 1992;87(10):1418-23.
- Rossi G, Marchioni A, Romagnani E, et al. Primary lung cancer presenting with gastrointestinal tract involvement: Clinicopathologic and immunohistochemical features in a series of 18 consecutive cases. *J Thorac Oncol*. 2007;2(2):115-20.
- Burbige EJ, Radigan JJ, Belber JP. Metastatic lung carcinoma involving the gastrointestinal tract. *Am J Gastroenterol*. 1980;74(6):504-6.
- Garwood RA, Sawyer MD, Ledesma EJ, Foley E, Claridge JA. A case and review of bowel perforation secondary to metastatic lung cancer. *Am Surg*. 2005;71:110-6.
- Miyazaki K, Satoh H, Sekizawa K. Metastasis to appendix from lung adenocarcinoma. *Int J Gastrointest Cancer*. 2005;36(1):59-60.
- Kawahara K, Akamine S, Takahashi T, et al. Anal metastasis from carcinoma of the lung: Report of a case. *Surg Today*. 1994;24(12):1101-3.
- Maeda J, Miyake M, Tokita K, et al. Small cell lung cancer with extensive cutaneous and gastric metastases. *Intern Med*. 1992;31(11):1325-8.
- Menuck LS, Amberg JR. Metastatic disease involving the stomach. *Am J Dig Dis*. 1975;20(10):903-13.
- Oda I, Kondo H, Yamao T, et al. Metastatic tumors to the stomach: Analysis of 54 patients diagnosed at endoscopy and 347 autopsy cases. *Endoscopy*. 2001;33(6):507-10.
- Rubin SA, Davis M. "Bull's eye" or "target" lesions of the stomach secondary to carcinoma of the lung. *Am J Gastroenterol*. 1985;80(1):67-9.
- Fletcher MS. Gastric perforation secondary to metastatic carcinoma of the lung: A case report. *Cancer*. 1980;46(8):1879-82.
- Kim MJ, Hong JH, Park ES, Byun JH. Gastric metastasis from primary lung adenocarcinoma mimicking primary gastric cancer. *World J Gastrointest Oncol*. 2015;7(3):12-16.
- Okazaki R, Ohtani H, Takeda K, et al. Gastric metastasis by primary lung adenocarcinoma. *World J Gastrointest Oncol*. 2010;2(10):395-8.
- Altintas E, Sezgin O, Uyar B, Polat A. Acute upper gastrointestinal bleeding due to metastatic lung cancer: An unusual case. *Yonsei Med J*. 2006;47(2):276-7.
- Katsenos S, Archondakis S. Solitary gastric metastasis from primary lung adenocarcinoma: A rare site of extra-thoracic metastatic disease. *J Gastrointest Oncol*. 2013;4(2):E11-E15.
- Lau SK, Luthringer DJ, Eisen RN. Thyroid transcription factor-1: A review. *Appl Immunohistochem Mol Morphol*. 2002;10(2):97-102.
- Chen D, Zhang LQ, Huang JF, et al. BRAF mutations in patients with non-small cell lung cancer: A systematic review and meta-analysis. *PLoS One*. 2016;9(6):e101354.