

# Simplified Lateral Brow Lift under Local Anesthesia for Correction of Lateral Hooding

Sergey Y. Turin, MD

Elbert E. Vaca, MD

Jennifer E. Cheesborough, MD

Sammy Sinno, MD

Thomas A. Mustoe, MD

**Background:** A limited incision lateral brow lift has been described as an alternative to the endoscopic or the bicoronal approaches. The senior author has developed a safe and effective lateral brow lift technique that can be performed in an office setting under local anesthesia.

**Methods:** We retrospectively reviewed 150 consecutive patients who underwent a brow lift by the senior author (TAM). The technique begins with an upper blepharoplasty incision which is used to divide the corrugator under direct vision, followed by a release of the periorbital retaining ligaments. The lateral temporal incision is the access point for dissection above the deep temporal fascia then connecting to the subperiosteal plane, allowing full mobility of the brow. Galea is advanced with sutures and redundant skin is excised.

**Results:** All patients treated with this technique had resolution of lateral brow hooding. Two temporary neuropraxias of the frontal branch of the facial nerve were observed with full resolution and no permanent nerve injuries occurred. The revision rate was 7% and there was a 3% incidence of delayed wound healing at the temporal incision with no infections. One hundred forty-two patients (97%) underwent this procedure with sedation, 52 of which (35%) were in the office with light oral sedation.

**Conclusions:** The limited incision lateral brow lift as described allows for safe elevation of the lateral brow. When complemented by upper blepharoplasty, this technique provides excellent and natural-appearing rejuvenation of the upper face. (*Plast Reconstr Surg Glob Open* 2019;7:e2098; doi: 10.1097/GOX.0000000000002098; Published online 12 June 2019.)

## BACKGROUND

The upper face serves as a keystone with regard to the appearance of aging as furrowing and descent of these tissues can make one seem tired, sad, or even angry. In brow ptosis, increased skin laxity, lipoatrophy of the upper eyelid, and galeal fat pad ptosis play significant roles, but that it is the force of gravity combined with the actions of the facial muscles that predominately drive the changes of the aging face.<sup>1</sup> The oblique line (temporal ligamentous adhesion) acts as a fulcrum about which the lateral

brow descends, as the upward force of the frontalis muscle does not extend to this region. As described by Knize, the transverse heads of the corrugator supercilii and the lateral aspect of the orbicularis oculi muscles play a large role in the descent of the lateral brow over the superior orbital rim.<sup>2</sup> Within the medial two thirds of the brow, the depressor forces of the corrugator and procerus muscles are counterbalanced in part by the frontalis muscle. Both these vectors drive formation of undesirable rhytids in the glabella and forehead, respectively.

Addressing the upper eyelid skin alone will remove reflex frontalis activation and even cause a worsening of brow ptosis in certain patients. Therefore, many surgeons advocate a combined approach to upper face rejuvenation with an upper blepharoplasty and a simultaneous brow lift.<sup>3</sup> This has the added benefit of permitting greater access to dissection planes through the upper blepharoplas-

*From the Northwestern University Feinberg School of Medicine, Division of Plastic and Reconstructive Surgery, Chicago, Ill.*

*Received for publication October 12, 2018; accepted November 7, 2018.*

*Presented at ASAPS 2017 San Diego, CA 4/27/17-5/1/17.*

*Copyright © 2019 The Authors. Published by Wolters Kluwer Health, Inc. on behalf of The American Society of Plastic Surgeons. This is an open-access article distributed under the terms of the Creative Commons Attribution-Non Commercial-No Derivatives License 4.0 (CCBY-NC-ND), where it is permissible to download and share the work provided it is properly cited. The work cannot be changed in any way or used commercially without permission from the journal.*

DOI: 10.1097/GOX.0000000000002098

**Disclosure:** The authors have no financial interest to declare in relation to the content of this article.

Supplemental digital content is available for this article. Clickable URL citations appear in the text

ty incision while allowing the surgeon to minimize scalp incisions. After using endoscopic techniques for many years, the senior author has found that adequate access is otherwise achievable through a temporal and an upper blepharoplasty incision<sup>1</sup> without endoscopy or extensive retraction. The lateral incision technique is also versatile in that it is appropriate for patients with foreheads of moderate or severe elongation and any severity of rhytids.<sup>4</sup>

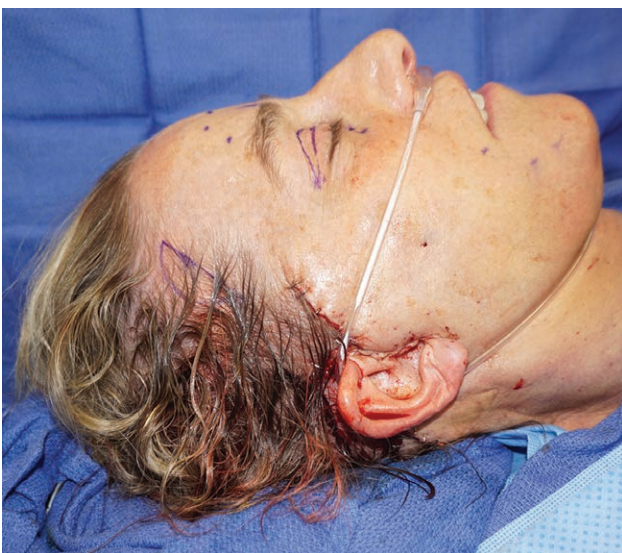The senior author most commonly uses the technique described here to correct lateral hooding, which causes a tired and aged appearance. Elevation of the brow can be more efficiently accomplished via a strictly superior vector, but the primary goal here is correction of the lateral upper eyelid and brow skin ptosis, not cephalad change in eyebrow position. Tension exerted from the superolateral vector dictated by the temporal incision specifically addresses the lateral hooding and has become the senior author's preferred method.

## MATERIALS AND METHODS

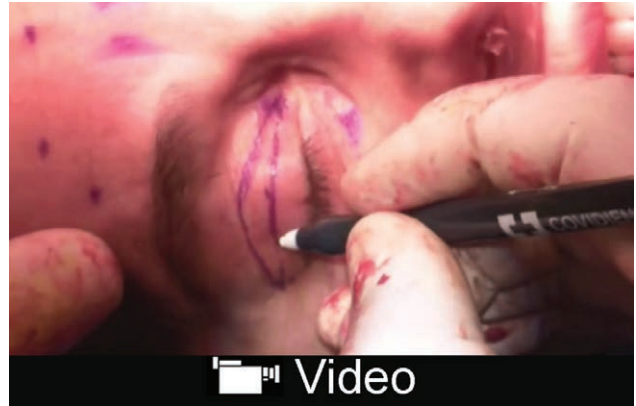The senior author's experience with the modified limited incision lateral brow lift was evaluated over a 4-year period. Two independent reviewers retrospectively reviewed 150 patients undergoing lateral brow lift procedures. Patient demographics, smoking history, diabetes, type of anesthesia, location of procedure, concomitant procedures performed, complications, and any revision procedures were all abstracted from the medical record.

## SURGICAL TECHNIQUE

This procedure can be performed in the office with minimal oral sedation and local anesthesia utilizing readily available instruments. This procedure differs from the forehead lift described by Knize by utilizing both the upper blepharoplasty incision and a lateral temporal incision. The senior author advocates a 4- to 5-cm temporal incision made parallel to the lateral brow (Figure 1; **SDC1**,



**Fig. 1.** Simplified lateral brow lift markings.



**Video graphic 1.** See video, Supplemental Digital Content 1, which displays a simplified lateral brow lift markings. This video is available in the "Related Videos" section of the Full-Text article on PRSGlobalOpen.com or available at <http://links.lww.com/PRSGO/B96>.

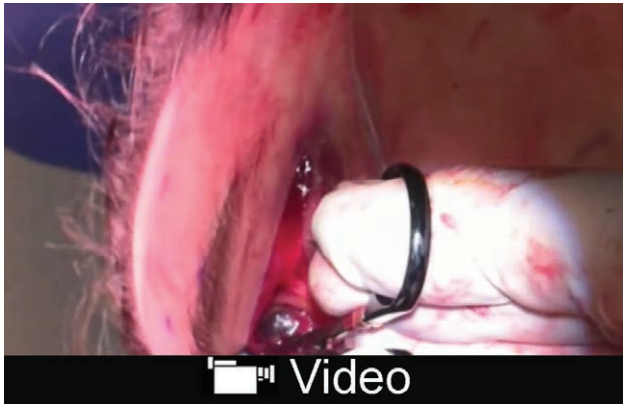see video, Supplemental Digital Content 1, which displays a simplified lateral brow lift markings, <http://links.lww.com/PRSGO/B96>).

The scalp incisions allow access to the zone of adhesion (ie, superior temporal septum) and the forehead, whereas the upper blepharoplasty incisions allow access to the medial brow depressors, the orbital ligament, periosteal/galeal attachments, and the temporal area lateral to the orbit. This approach allows safe dissection in the area of the frontal branch of the facial nerve and the deep and superficial branches of the supraorbital nerve, because all the dissection is carried out medially in the subperiosteal plane and laterally deep to the superficial layer of the deep temporal fascia with exposure of the deep temporal fat pad. The dissection can be performed precisely with meticulous hemostasis, avoiding the need for a drain. Minimal retraction is necessary, so the risk of neuropraxia of the frontal nerve branch from traction is minimized. The most important aspects of the release include undermining of the forehead and mobilization of the lateral orbital tissues inferiorly to the level of the lateral canthus and superolaterally along the oblique line to allow easy mobilization of the tissues superiorly.

After local anesthetic with epinephrine infiltration, the upper blepharoplasty incisions are made (**SDC2**, see video, Supplemental Digital Content 2, which displays a simplified lateral brow lift procedure, <http://links.lww.com/PRSGO/B97>).

From the medial portion of the upper blepharoplasty incision, access is gained to the corrugator and procerus muscles. Dissection deep to the orbicularis oculi is directed superomedially from the incision, developing a pocket to expose the corrugator supercillii. A Ragnell retractor is used to achieve visualization and protect the supraorbital artery and nerve (Fig. 2). Once the corrugator is visualized, it is divided using bipolar cautery. Some supratrochlear nerve paresthesias are expected with retraction and manipulation of the soft tissue in this area and always resolve spontaneously.

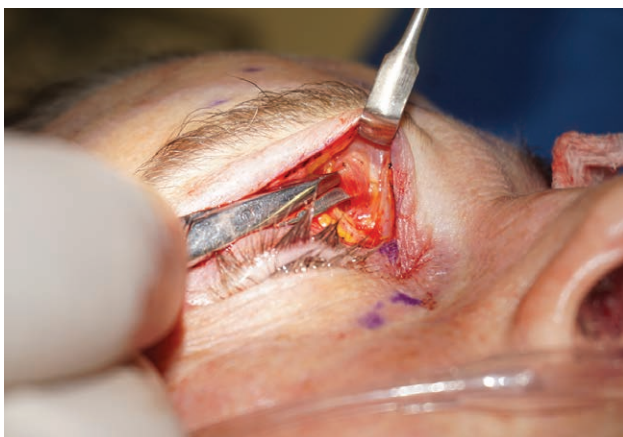Upper blepharoplasty and lateral temporal markings are made as in Figure 1. A 4- to 5-cm incision is drawn 2–3 cm posterior to the temporal hairline, outlining a cres-



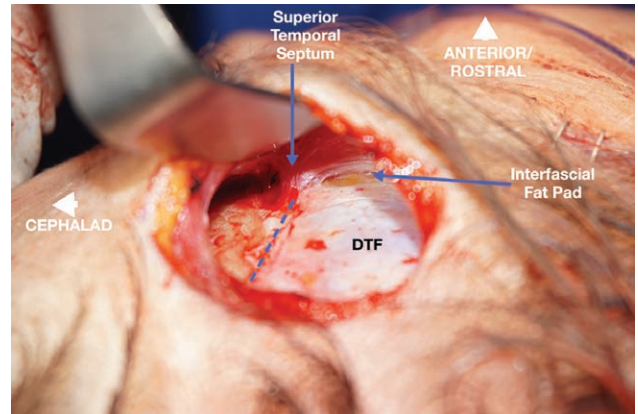
**Video graphic 2.** See video, Supplemental Digital Content 2, which displays a simplified lateral brow lift procedure. This video is available in the “Related Videos” section of the Full-Text article on PRS-GlobalOpen.com or available at <http://links.lww.com/PRSGO/B97>.

cent-shaped area of anticipated skin excision. The long axis of the marking is made parallel to the lateral brow to maximize the vector of lift. The width of the area of temple tissue excision is tailored to degree of brow ptosis, approximately in a 4:1 ratio (width of tissue excision to expected lateral brow lift effect).

The lateral temporal incision is made down to the temporalis fascia along the posterior line of the marked crescent. Dissection proceeds above the deep temporal fascia in the area caudal to the superior temporal septum. Cephalad to the superior temporal septum dissection proceeds inferomedially in the subperiosteal plane toward the lateral superior orbital rim. These 2 dissection planes are joined by fully releasing the superior temporal septum (ie, zone of adhesion). Just posterior to the lateral orbital rim, the deep layer of the deep temporal fascia is incised, exposing the interfascial fat pad (Fig. 3). The entire hemiforehead is then widely undermined in the subperiosteal plane to allow for proper redraping. To maximize lift, the orbital ligament, the supraorbital rim ligamentous adhe-



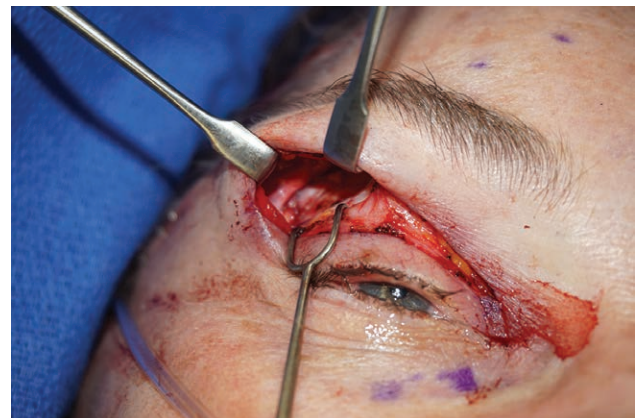**Fig. 2.** Corrugator muscle is identified over the medial brow in the suborbicularis oculi plane. Care is taken to identify and protect the supratrochlear and supraorbital nerves and vessels. The corrugator is then cauterized with bipolar cautery and sharply divided.



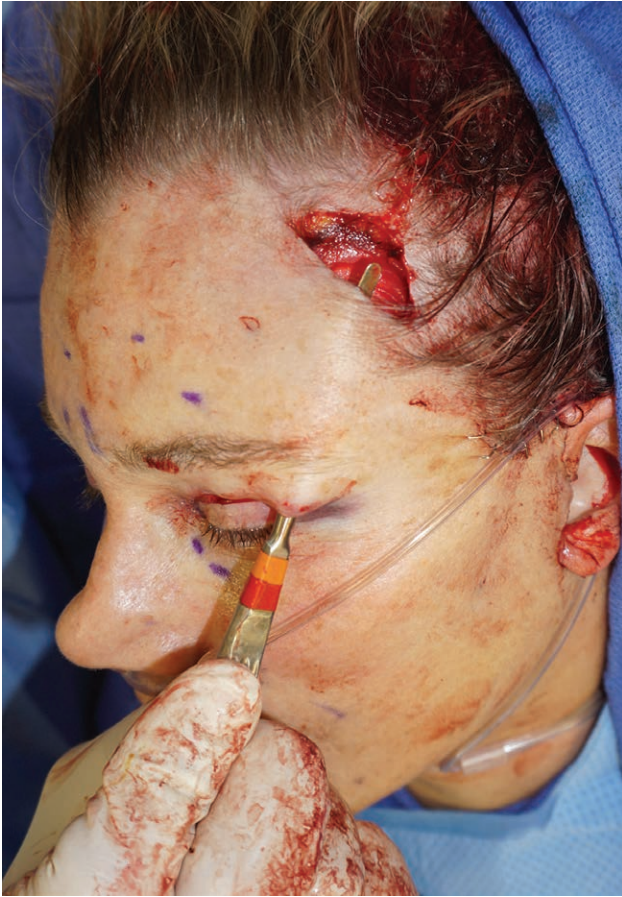**Fig. 3.** Temporal dissection. Continuity of the cephalad subperiosteal dissection plane and caudal dissection on top of the DTF is attained by dividing superior temporal septum. The superficial layer of the DTF is incised just posterior to the lateral orbital rim, exposing the interfascial fat pad. Dashed blue line indicates the superior temporal line. DTF, deep temporal fascia.

sions, and lateral orbital thickening must also be released. Attention is directed back to the upper blepharoplasty incisions to release these structures.

Via the lateral aspect of the blepharoplasty incision, the lateral superior orbital rim periosteum is incised. Dissection proceeds in the subperiosteal plane and the lateral orbital thickening is released just cephalad to the level of the lateral canthal tendon. The interfascial fat pad should be visualized—confirming continuity of the temporal and upper blepharoplasty dissection planes (Fig. 4). Dissection then proceeds superomedially to fully release the orbital ligament and supraorbital rim ligamentous adhesions, thus creating a continuous subperiosteal plane allowing full mobility of the brow (Fig. 5). Once the desired lifting effect is achieved, two to three 3–0 polydioxanone (PDS) sutures are used to secure the posterior superficial temporal fascia (ie, galea) to the anterior periosteal and superficial temporal fascia layer. The skin flap marked for



**Fig. 4.** Lateral upper blepharoplasty dissection. Subperiosteal dissection is performed and the lateral orbital thickening is released. The interfascial fat pad should be visualized from the lateral blepharoplasty incision to confirm continuity of the temporal and blepharoplasty dissection planes.



**Fig. 5.** Continuity of the temporal and upper blepharoplasty subperiosteal dissection planes is demonstrated.

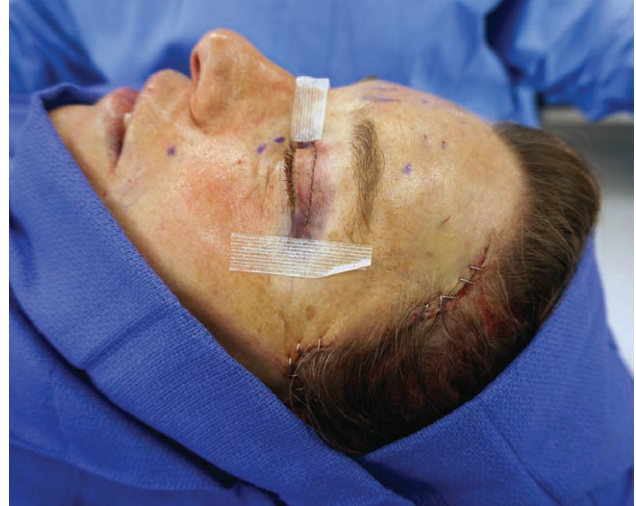excision (Fig. 1) at this point will be clearly redundant and the width of the excised crescent can be confirmed so as not to create undue tension or bunching at the incision. Approximately 1–1.5 cm of skin is excised in the vertical dimension and staples are used to close this incision in the hair-bearing temple (Fig. 6). Addition of the skin excision component has minimized the need for revision as demonstrated by the revision rate difference between the early and late cohort (Table 1). No drains are necessary.

## RESULTS

Between January 2008 and July 2010, the senior author performed 80 consecutive brow lifts and then 70 between July 2014 and June 2016. The results of the chart review are detailed in Table 1.

For the entire series, 88% of patients were female with an average age of 59.3 years (SD = 8.7), 0.7% had a history of diabetes, and 4% were active smokers. Twenty patients had previously undergone brow lifts: 3 endoscopic brow lifts, 5 lateral brow lifts, and 12 of an unspecified type. Fifteen percent of patients had previously undergone blepharoplasty and 20% had prior rhytidectomies.

Almost all cases (93%) were performed under conscious sedation (light oral sedation in the office, IV sedation administered by a nurse, or deep sedation



**Fig. 6.** Skin closure.

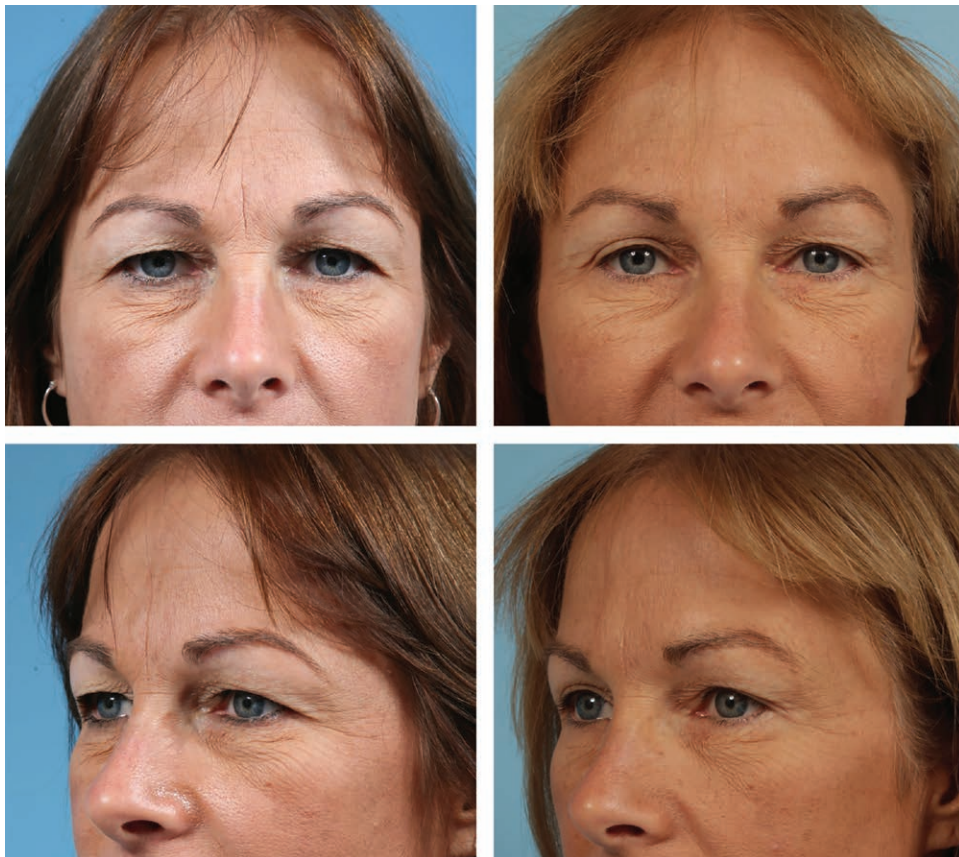administered by an anesthesiologist in the operating room), with the remainder receiving anesthesia care due to concurrent procedures. Of the total 150 patients, 130 patients (87%) underwent upper blepharoplasty in combination with the lateral brow lift. Patients who did not elect to have an upper blepharoplasty did have an upper lid incision for access purposes. All patients underwent at least 1 procedure in addition to the brow lift at the time of surgery with an average of 2.78 additional procedures performed in concert with the brow lift.

Average follow up period was 266 days (SD of 313 days, range 1–1,329 days). Nine patients chose not to return for delayed follow-up after the initial postoperative evaluation visits, as they did not have complications or complaints at that time. Complications were rare and mostly minor. No permanent frontal branch nerve injuries were noted. Two unilateral frontal branch neuropraxias were encountered, both of which resolved completely with no intervention. Four patients had asymmetric brow elevation: 2 were treated with Botox and 1 with revision surgery. As counseled, there were cases of transient supraorbital or supratrochlear paresthesias which all resolved spontaneously within a few weeks of surgery. One patient had temporary paresthesias of her unilateral forehead and another developed moderate chronic pain at her brow lift and facelift incisions which resolved over 3 months.

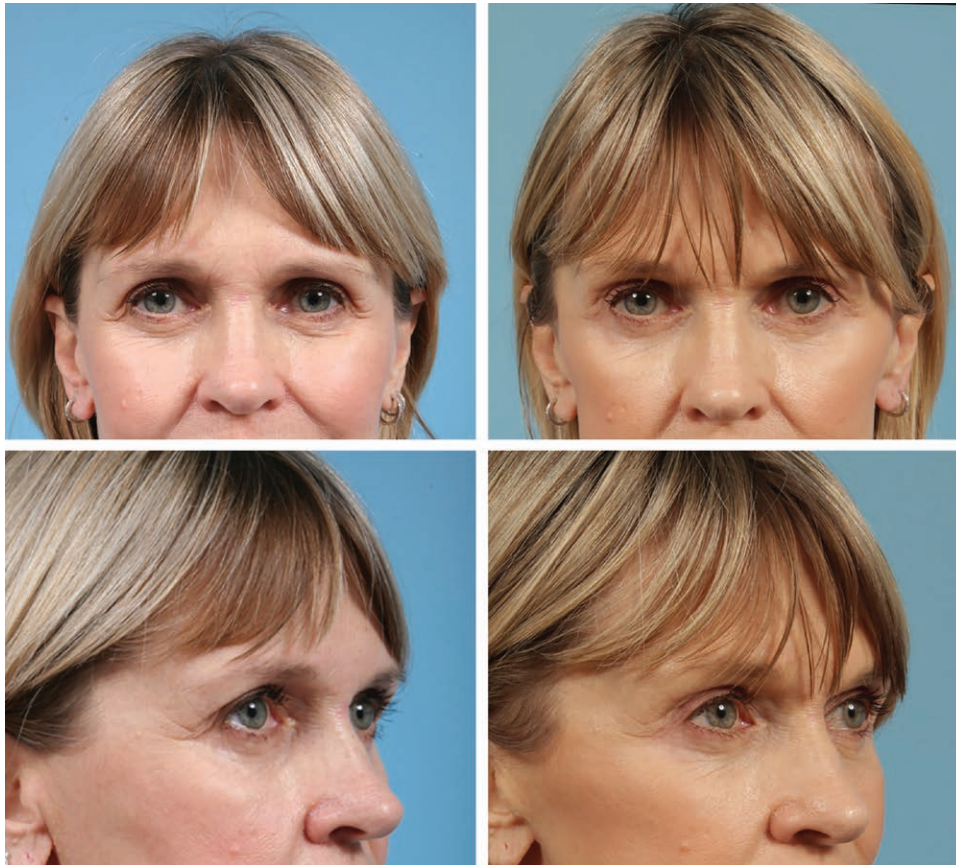The following pre- and postoperative patient photographs demonstrate the efficacy of the technique and the durability of the results. Patient A is a 51-year-old woman who presented for correction of periorbital aging. Her pre- and postsurgical appearances at 1 year follow-up after upper and lower blepharoplasty and lateral browlift bilaterally are illustrated in Figure 7A–D. Patient B is a 66-year-old woman presenting for correction of stigmata of facial aging; pre- and postsurgical appearances at 1 year follow-up after rhytidectomy and lateral browlift bilaterally are presented in Figure 8.

**Table 1. Patient Demographics and Outcomes**

	Overall	Initial Cohort (January 2008–July 2010)	Delayed Cohort (July 2014–June 2016)
No. patients	150	80	70
Demographics			
Age at time of surgery, years (SD)	59.3 (8.7)	59.7 (9.0)	58.8 (8.5)
Sex (number and percent female)	132 (88%)	69 (86%)	63 (90%)
DM (number and percent with history of diabetes)	1 (0.7%)	1 (1.3%)	0 (0%)
Smoking history (number and percent active smokers)	6 (4%)	5 (6%)	1 (1%)
Prior procedures			
Prior blepharoplasty	22 (15%)	9 (11%)	13 (19%)
Prior facelift	30 (20%)	14 (18%)	16 (23%)
Location			
Office	52 (35%)	21 (26%)	31 (44%)
Academic center operating room	51 (34%)	48 (60%)	3 (4%)
Surgicenter	47 (31%)	11 (14%)	36 (51%)
Anesthesia (number and percent undergoing general anesthesia)	5 (3%)	0 (0%)	5 (7%)
No. additional procedures (SD)	2.78 (1.16)	3.06 (1.12)	2.46 (1.13)
Simultaneous procedures			
Upper blepharoplasty	130 (87%)	68 (85%)	62 (89%)
Lower blepharoplasty	46 (31%)	26 (33%)	20 (29%)
Rhytidectomy	91 (61%)	56 (70%)	35 (50%)
Fat grafting	89 (59%)	53 (66%)	36 (51%)
Laser or dermabrasion	23 (15%)	22 (28%)	1 (1%)
Rhinoplasty	9 (6%)	6 (8%)	3 (4%)
Genioplasty	3 (3%)	3 (4%)	0 (0%)
Complications (number and percent experiencing complications)			
Recurrence or revision?	11 (7%)	9 (11%)	2 (2%)
Eye closure problem?	6 (4%)	5 (6%)	1 (1%)
Delayed wound healing or superficial infection at temporal incision	4 (3%)	1 (1%)	3 (4%)
Frontal Br. of facial nerve neuropraxia	2 (1%)	1 (3%)	1 (3%)
Incision length (SD)	3.06 (0.74)	2.90 (0.32)	4.20 (0.38)
Follow-up time	263 (314)	423 (369)	142 (152)



**Fig. 7.** Patient A is a 51-year-old woman who presented for correction of periorbital aging. Her pre- and postsurgical appearances at 1 year follow-up after upper and lower blepharoplasty and lateral browlift bilaterally are illustrated.



**Fig. 8.** Patient B is a 66-year-old woman presenting for correction of stigmata of facial aging; pre- and postsurgical appearances at 1 year follow-up after rhytidectomy and lateral browlift bilaterally are presented.

## DISCUSSION

Treatment of the upper face is vital to addressing the appearance of aging. The brow lift has evolved dramatically over the last century from Dr. Passot's original description of the brow lift in 1919 utilizing elliptical excisions on the forehead,<sup>5</sup> to Dr. Vinas' bicoronal incisions presented in 1969,<sup>6</sup> to Dr. Vasconez and Dr. Isse's descriptions of the endoscopic brow lift in 1992,<sup>7,8</sup> and to Dr. Knize's limited incision forehead lift published in 1996.<sup>9</sup> Each new technique has benefited substantially from the successes and pitfalls of its predecessors and has led to progressively smaller incisions for maximal benefit.<sup>10</sup> The senior author's (T.A.M.) technique presented in this article builds upon and attempts to simplify the technique described by Dr. Knize.

Resuspension of the brow and forehead can be an essential component of upper face rejuvenation. Patients presenting for consultation often interpret lateral hooding as an upper eyelid problem rather than a brow ptosis problem and initially may not appreciate the importance of the brow lift to the overall result. Often, they need to be educated on the importance of restoring the youthful brow position, redraping the forehead, and correction of lateral hooding to rejuvenate the upper face in harmony with any concurrent blepharoplasty and rhytidectomy procedures. However, there may be hurdles to patients ac-

cepting the inclusion of a foreheadplasty into the operative plan. These include extra cost, added operative time, possible need for general anesthesia or formal operating room setting, and perceived added complexity. Endoscopic techniques and open brow techniques justify some of these concerns given their requirement for equipment, hardware, and anesthesia.

The lateral brow lift as described above can be performed relatively quickly, without need for an assistant and without need for specialized instruments. No drains are required, which aids in patient acceptance of the procedure as conceptually an extension of an upper blepharoplasty to correct lateral hooding rather than an additional significant procedure. When these advantages of the modified lateral brow lift are discussed in consultation, the senior author has found markedly increased acceptance rate when offered to patients seeking upper face rejuvenation as the blepharoplasty and brow lift essentially become a truly combined procedure.

Discussion to this point has focused primarily on the lateral brow, but it should be noted that the medial brow also has an impact on the overall appearance of the upper face. There is rarely ptosis of the medial brow, but if present, the culprit is usually the procerus muscle. This can be verified by the presence of deep transverse dorsal nasal lines.<sup>2</sup> Although in many cases resection of a por-

tion of the procerus and corrugator muscles will alleviate glabellar frown lines, and result in subtle elevation of the medial brow, the primary focus of the brow lift should be elevation of the lateral aspect of the brow. In the present technique, the upper blepharoplasty incision is useful as it provides access to these muscles and safe dissection around the nerves of the upper face.

One of the important distinctions of the lateral brow lift approach is the low rate of temporary or permanent nerve dysfunction. There have been no permanent nerve deficits in our case series and the 2 frontal branch neuropraxias we have encountered resolved uneventfully with no need for intervention, for an overall temporary motor nerve paralysis rate of 1.33%, and a permanent paralysis rate of 0%. These compare favorably to the rates of 0.0%–6.4% reported in the literature<sup>11</sup> and the 7% motor branch injury rate reported by Dr. Knize in the follow-up to his original description.<sup>12</sup> Our 0% rate of paresthesias/dysesthesias rate is also lower than the reported overall (0.3%–5.4%) incidence rate of paresthesia/dysesthesia.<sup>11</sup> The safety of the procedure hinges on the subperiosteal dissection initiated from the temporal and blepharoplasty access points, with the frontal branch of the facial nerve and the supraorbital nerves always superficial to the plane of dissection. Dissection around the supraorbital nerve is also performed with direct visualization in our technique, leading to greater safety and likely a higher level of comfort for the less-experienced surgeon.

Moreover, there is no bony anchoring and no special equipment required, so the modified lateral brow lift can be reliably performed with basic instruments in an office setting under conscious sedation and local anesthesia, unlike the previously described techniques. Some of the alternative fixation strategies employ bony anchors, resorbable fixation devices such as Endotine (MicroAire Surgical Instruments, Charlottesville, VA), and suture fixation without skin excision. Endotine fixation is a valuable tool in the aesthetic surgeon's arsenal but carries with it an additional cost for the device itself and the extra materials and time to drill for bony fixation. Moreover, the device itself can be palpable and associated with numbness as shown in a recent series.<sup>13</sup> We feel that achieving similar or better results without needing extra instrumentation and time, while also avoiding bony manipulation, is a more patient-friendly approach. A key to adequacy of fixation is complete release of the attachments in the region of the lateral orbital rim inferiorly to the level of the lateral canthus and lateral to the orbital rim. We have found that PDS sutures are adequate, and medial fixation is unnecessary.

This technique allows the surgeon to apply tension most effectively to the lateral component of the eyebrow by virtue of where the temporal incision is placed, but certain patients present with medial eyebrow hooding that can also be addressed with a slight modification. For these cases, the senior author prefers a posttrichial skin excision in the medial portion of the anterior scalp to provide the needed amount of medial eyebrow elevation. This incision allows excellent access to connect the subperiosteal planes of dissection across the midline and elevate the entire forehead in one continuous, avascular plane.

The limitations of the study include retrospective nature and discontinuous time frame, which was imposed because of limitations of access to patient charts for the 2010–2014 period. Patient satisfaction and surgical success were measured subjectively at the follow-up visits by interviewing patients regarding the change in their appearance and assessing the degree of lateral hooding correction. Measurements were not routinely taken, as an overall aesthetically congruent brow elevation was the goal, with no specific minimal elevation targeted.

The senior author's technique as described above is a modification of Dr. Knize's approach that allows it to be performed in the office under light oral sedation using only benzodiazepines combined with local anesthesia and achieve a much lower neuropraxia rate than Dr. Knize's series. We also show a multiyear case series with long-term follow-up to demonstrate that the modified lateral brow lift can be performed safely, quickly, and reliably, thus addressing the patient's concerns and leading to a higher acceptance rate when the brow lift is offered as part of an upper face rejuvenation package. The role of the lateral browlift in the senior author's practice is to address the lateral hooding and it is explained as such to the patients, with no expectation of dramatic brow position changes. The shape of the brow and limitations of the technique in terms of brow elevation and shaping, thus, do not come into play as these are not the primary goals of the lateral browlift approach as described here.

## CONCLUSIONS

For patients desiring comprehensive correction of lateral brow hooding, the modified limited incision lateral brow lift provides a safe, cost-effective, and reliable option. The senior author has found that the reliability of this procedure in producing natural-appearing results has led to very high acceptance rates of the combined lateral brow and blepharoplasty procedure.

**Thomas A. Mustoe, MD**

Division of Plastic and Reconstructive Surgery  
Northwestern University Feinberg School of Medicine  
737N Michigan Ave #1500  
Chicago, IL 60611  
E-mail: tmustoe50@gmail.com

## REFERENCES

1. Warren RJ. The modified lateral brow lift. *Aesthet Surg J*. 2009;29:158–166.
2. Knize DM. Anatomic concepts for brow lift procedures. *Plast Reconstr Surg*. 2009;124:2118–2126.
3. Codner MA, Kikkawa DO, Korn BS, et al. Blepharoplasty and brow lift. *Plast Reconstr Surg*. 2010;126:1e–17e.
4. Guyuron B, Lee M. A reappraisal of surgical techniques and efficacy in forehead rejuvenation. *Plast Reconstr Surg*. 2014;134:426–435.
5. Passot R. La Chirurgie esthétique des rides du visage. *Presse Med*. 1919;27:258.
6. Vinas J. Plan general de la ritidoplastia y zona tabu. Paper presented at: Transactions of the 4th Brazilian Congress on Plastic Surgery October 5-8, 1965; Porto Alegre, Brazil.
7. NG I. Endoscopic forehead lift. Paper presented at: Annual Meeting of the Los Angeles County Society of Plastic Surgeons; 1992; Los Angeles, CA.

8. Vasconez L. The use of the endoscope in brow lifting. A video presentation. Paper presented at: Annual Meeting of the American Society of Plastic and Reconstructive Surgeons; 1992; Washington, DC.
9. Knize DM. Limited-incision forehead lift for eyebrow elevation to enhance upper blepharoplasty. *Plast Reconstr Surg.* 1996;97:1334–1342.
10. Paul MD. The evolution of the brow lift in aesthetic plastic surgery. *Plast Reconstr Surg.* 2001;108:1409–1424.
11. Byun S, Mukovozov I, Farrokhyar F, et al. Complications of browlift techniques: a systematic review. *Aesthet Surg J.* 2013;33:189–200.
12. Knize DM. Limited incision forehead lift for eyebrow elevation to enhance upper blepharoplasty. *Plast Reconstr Surg.* 2001;108:564–567.
13. Chowdhury S, Malhotra R, Smith R, et al. Patient and surgeon experience with the endotine forehead device for brow and forehead lift. *Ophthalmic Plast Reconstr Surg.* 2007;23:358–362.