

Case Report



Unclassified Mucinous Renal Cell Carcinoma: A Rare Histopathological Entity

Omer A. Raheem, Elana Godebu, Seth A. Cohen, Ahmed Shabaik¹, J. Kellogg Parsons

Departments of Urology and ¹Pathology, University of California, San Diego Medical Center, San Diego, California, USA

Renal cell carcinoma (RCC) with mucin production is extremely rare. We present the case of a previously healthy 76-year-old woman who underwent a robotic-assisted laparoscopic right nephrectomy for a 5-cm heterogeneously enhancing right renal mass. Pathology revealed mucin-producing epithelial RCC. We discuss the presentation and pathological features of this case and comment on its definitive treatment.

Keywords: Mucin; Renal cell carcinoma

This is an Open Access article distributed under the terms of the Creative Commons Attribution Non-Commercial License (<http://creativecommons.org/licenses/by-nc/3.0>) which permits unrestricted non-commercial use, distribution, and reproduction in any medium, provided the original work is properly cited.

Article History:

received 2 September, 2013
accepted 16 October, 2013

Corresponding Author:

Omer A. Raheem
Department of Urology,
University of California, San
Diego, 200 West Arbor Drive, San
Diego, CA 92103-8897, USA
TEL: +1-858-356-7354
FAX: +1-619-543-6573
E-mail: oraheem@ucsd.edu

INTRODUCTION

Renal cell carcinoma (RCC) with extensive mucin production is extremely rare, with only one similar case recently reported by Val-Bernal et al. [1] as mucin-secreting clear cell RCC. A possible second case was reported in 1988 by Grignon et al. [2]. Renal epithelial tumors with mucin production other than mucinous tubular spindle cell carcinoma and collecting duct carcinoma with mucin production have been placed under the category of unclassified RCC in the latest 2004 World Health Organization (WHO) classification of tumors [3]. Unclassified RCCs as a group account for 0.7% to 5.7% of all RCCs [4-7]. Unclassified RCC as a group is reportedly associated with unfavorable histological features and aggressive behavior [8,9].

CASE REPORT

A 76-year-old woman with no prior significant medical or surgical problems was referred to the University of California San Diego Medical Center for evaluation of a 5-cm right solid renal mass diagnosed on computed tomography urogram (CTU) in the evaluation of new-onset gross painless hematuria. She denied any history of tobacco smoking or illicit drug misuse. The results of a clinical examination were unremarkable for any abdominal or flank masses, organomegaly, or lymphadenopathy. Hematological and biochemical laboratory values were within the normal range

(blood urea nitrogen, 8 mg/dL; serum creatinine, 0.73 mg/dL; and glomerular filtration rate, > 60).

Preoperative CTU demonstrated a heterogeneous parenchymal right renal mass suspicious for RCC, along with right ureteral and renal pelvis filling defects (Fig. 1). Rigid urethroscopy and a right retrograde pyelogram were performed and did not demonstrate any mucosal lesions or

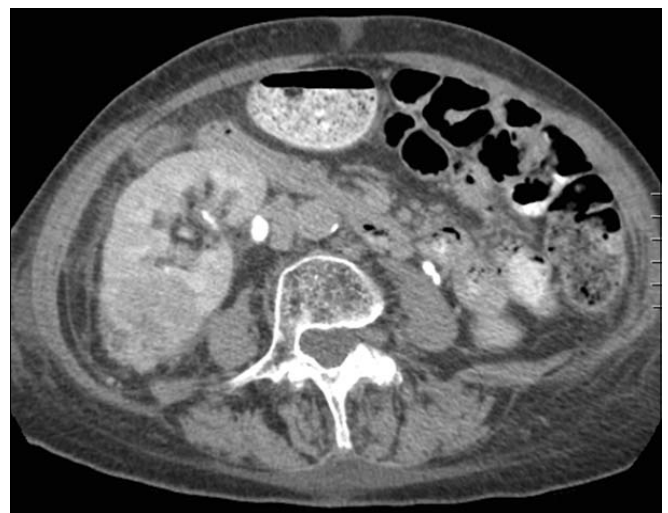

FIG. 1. Transverse section of a computed tomography urogram showing a heterogeneous parenchymal right exophytic renal mass suspicious of renal cell carcinoma.

any filling defects in the bladder, ureter, or renal pelvis. Cytology of urine obtained during cystoscopy revealed epithelial cell clusters with atypia without overt features of malignancy. Some reactive urothelial cells were noted in the background. Further imaging showed no evidence of abdominal or retroperitoneal lymphadenopathy, organomegaly, or distant metastasis.

Given the clinical presentation and imaging findings, robotic-assisted laparoscopic right nephrectomy was offered. The risks, benefits, and potential complications were discussed thoroughly with the patient. Subsequently, robotic-assisted laparoscopic right nephrectomy was successfully performed with no complications. The patient had an uncomplicated postoperative recovery course. However, on postoperative day 4, she developed a low-grade fever and productive cough consistent with an upper respiratory tract infection (URTI) secondary to testing influenza A positive. This URTI completely resolved with an oral course of azithromycin. The patient was discharged home on postoperative day 6 in a comfortable and stable condition.

Pathologically, the right kidney specimen showed unclassified RCC with extensive extracellular but intraluminal mucin production with a maximum diameter of 5 cm and with renal sinus fat involvement consistent with pT3a with negative margins of resection. Grossly, the right kidney measured 12.5 cm×10 cm×5.5 cm and contained an upper pole solid mass that when bisected had a firm whitish yellow and glistening cut surface. The mass had ill-defined borders and was present in the superior pole and encroached upon the mid aspect of the kidney. The mass measured 5 cm×4.2 cm×4 cm. It involved mainly the cortex of the kidney and appeared to extend to the superior calices, the medullary pyramids, and the renal sinus fat. The renal pelvis appeared gray-white, glistening, and uninvolved by the tumor. One of the main branches of the main renal vein appeared to contain tumor; however, the renal vein margin

was grossly clear of tumor. A smooth-lined unilocular cyst measuring 4 cm×3.5 cm×3.5 cm was found in the inferior to mid aspects of the kidney, which abutted the lateral aspect of the renal capsule and the perinephric adipose tissue. The cyst contained clear serous fluid and the lining was smooth without papillary excrescences. The wall thickness measured up to 0.1 cm. The remaining uninvolved parenchyma appeared tan-brown and smooth with a distinct corticomedullary junction, and the inferior calices appeared gray-white and glistening.

Histologically, the tumor displayed variable architectural patterns including areas of compact alveoli of clear cells consistent with clear cell carcinoma (Fig. 2). However, islands of cribriform sheets of clear cells with glandular lumens predominated. Many of the gland lumens contained blue mucin that was positive on mucicarmine and periodic

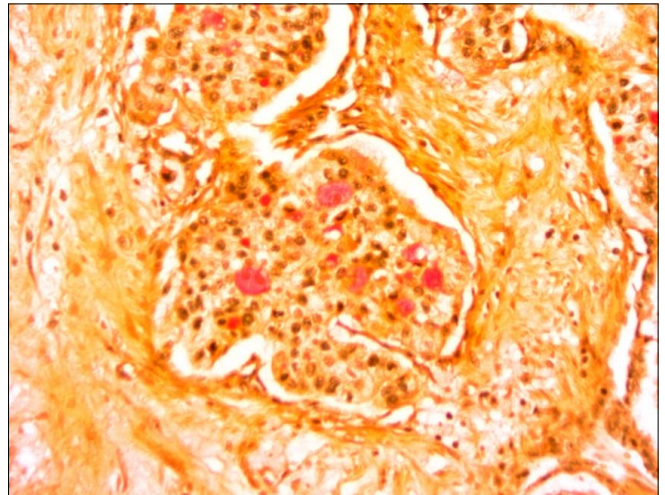


FIG. 3. Glandular lumens contained blue mucin that was positive on mucicarmine stain (×20).

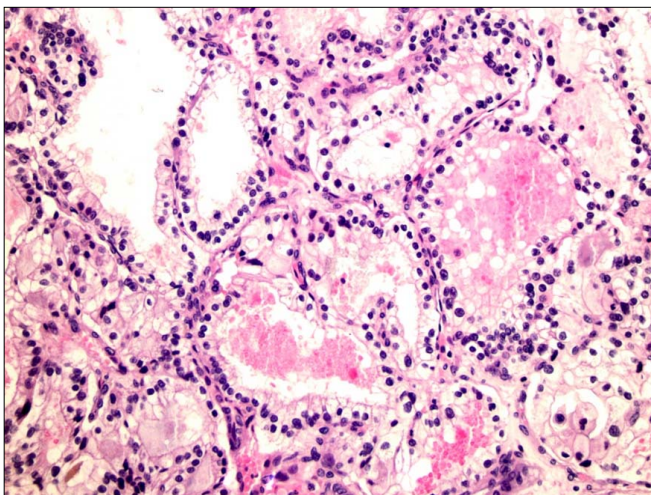


FIG. 2. The tumor displayed variable architectural patterns including areas of compact alveoli of clear cells consistent with clear cell carcinoma (×20).

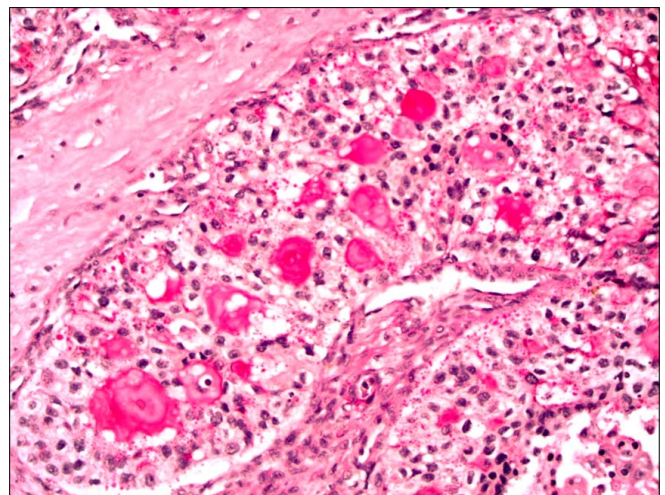


FIG. 4. Glandular lumens contained blue mucin that was positive on periodic acid-Schiff diastase stain (×20).

acid-Schiff diastase stains (Figs. 3, 4). Other areas consisted of small clusters and acini of clear cells embedded in fibrous stroma. Additional microcystic areas lined by a single layer of cuboidal clear cells were noted.

After 12 months of clinic follow-up, the patient remained clinically well and her abdominal wounds were well healed. Her renal function was preserved as indicated by blood urea nitrogen of 10 mg/dL and serum creatinine of 0.84 mg/dL. Follow-up computed tomography of the thorax, abdomen, and pelvis did not reveal any evidence of disease recurrence.

DISCUSSION

According to the 2004 WHO classification of urological tumors, there are four main types of RCC: clear-cell, papillary, chromophobe, and collecting duct carcinoma [3]. However, subtypes of RCC that do not fall into any of the common RCC types are lumped under the category of unclassified RCC [3]. By consensus, the histopathological features that might prompt assignment of an RCC to the unclassified subtype are as follows: (1) composites of recognized subtypes, (2) mucin production, (3) rare mixture of epithelial and stromal elements, (4) pure sarcomatoid morphology without recognizable epithelial elements, and (5) unrecognizable cell types [3].

Unclassified RCCs are a rare and variable type of RCC. These tumors usually account for 0.7% to 5.7% of all RCCs in large contemporary studies [4-7]. Generally, unclassified RCC tends to be heterogeneous and most often high grade with unfavorable histological features and aggressive behavior [8,9]. In a recent multi-institutional study by Lopez-Beltran et al. [4], unclassified RCC with a mucous component making up 5% to 20% of the tumor constituted approximately 7% of the total cohort of patients (4/56 cases). None of the four cases was predominantly mucinous. In Lopez-Beltran's study, the mean age at diagnosis was 63 years (range, 29-91 years). Unclassified RCC was found incidentally during evaluation for unrelated conditions in 39% of the cases. Most patients (75%) had undergone non-nephron-sparing surgery. All cases were unilateral at diagnosis but only one patient had multifocal tumors. On follow-up, the median overall survival of 56 patients was 29 months (range, 2-179 months). Tumor coagulative necrosis was present in 18 cases (32%) and microvascular invasion was seen in 18% of cases. Adding to the above conclusions, Lopez-Beltran's study highlights that unclassified RCC represents a heterogeneous group of tumors for which prognosis seems to be related to histological features known to the more common forms of RCC [4].

In this case report, the patient underwent an uncomplicated robotic-assisted laparoscopic right nephrectomy and had good functional and oncological outcomes. The patient was cancer-free at the 1-year follow-up. Pathological specimens revealed RCC with extensive extracellular mucin production (pT3a) with focal areas of clear cell carcinoma morphology. Immunohistochemical

staining demonstrated the focal presence of smooth muscle fibers within the stroma of the tumor as well as a rich vascular network surrounding the tumor cell nests, but these were not extensive enough to suggest that the tumor was a mixed epithelial-stromal tumor. In Lopez-Beltran's study, none of the 56 unclassified RCC cases was categorized as a mixture of epithelial and stromal elements [4].

Two studies have previously demonstrated that unclassified RCC is associated with distinct and highly aggressive biological behavior and poor clinical outcome [8,9]. Likewise, Crispen et al. [8] studied 38 unclassified RCCs and concluded that although unclassified RCC is more likely to present with advanced clinicopathological features compared with clear cell RCC, there were no significant differences in overall or cancer-specific survival between the unclassified RCC and clear-cell RCC groups.

In conclusion, this case report illustrates a rare subtype of mucinous RCC, which as of today is best kept in the group of unclassified RCCs. The patient was managed in the usual fashion for treating RCC with similar functional and oncological outcomes. However, the histopathological findings of unclassified RCC can represent a pathological dilemma, particularly to pathologists. Hence, extra care should be practiced by both treating urologists and pathologists when they encounter this challenging subtype of unclassified RCC.

CONFLICTS OF INTEREST

The authors have nothing to disclose.

REFERENCES

1. Val-Bernal JF, Salcedo W, Val D, Parra A, Garijo MF. Mucin-secreting clear cell renal cell carcinoma. A rare variant of conventional renal cell carcinoma. *Ann Diagn Pathol* 2013;17:226-9.
2. Grignon DJ, Ro JY, Ayala AG. Primary mucin-secreting adenocarcinoma of the kidney. *Arch Pathol Lab Med* 1988;112:847-9.
3. Eble JN, Sauter G, Epstein JI, Sesterhenn IA. *Pathology and genetics tumors of the urinary system and male genital organs*. Lyon: IARC Press; 2004.
4. Lopez-Beltran A, Kirkali Z, Montironi R, Blanca A, Algaba F, Scarpelli M, et al. Unclassified renal cell carcinoma: a report of 56 cases. *BJU Int* 2012;110:786-93.
5. Karakiewicz PI, Hutterer GC, Trinh QD, Pantuck AJ, Klatte T, Lam JS, et al. Unclassified renal cell carcinoma: an analysis of 85 cases. *BJU Int* 2007;100:802-8.
6. Fine SW, Argani P, DeMarzo AM, Delahunt B, Sebo TJ, Reuter VE, et al. Expanding the histologic spectrum of mucinous tubular and spindle cell carcinoma of the kidney. *Am J Surg Pathol* 2006;30:1554-60.
7. Lopez-Beltran A, Scarpelli M, Montironi R, Kirkali Z. 2004 WHO classification of the renal tumors of the adults. *Eur Urol* 2006;49:798-805.
8. Crispen PL, Tabidian MR, Allmer C, Lohse CM, Breaux RH, Blute ML, et al. Unclassified renal cell carcinoma: impact on survival following nephrectomy. *Urology* 2010;76:580-6.
9. Zisman A, Chao DH, Pantuck AJ, Kim HJ, Wieder JA, Figlin RA, et al. Unclassified renal cell carcinoma: clinical features and prognostic impact of a new histological subtype. *J Urol* 2002;168:950-5.