

Primary cardiac sarcoma presenting with easy bruising: a case report

Rina Mishra¹, Ealaf Shemmeri², Saroj Pani^{3*}, and Matthew Tribble ³

¹Department of Medicine, Albany Medical Center, 43 New Scotland Ave, Albany, NY 12208, USA; ²Department of Cardiothoracic Surgery, Albany Medical Center, 43 New Scotland Ave, Albany, NY 12208, USA; and ³Department of Anesthesiology, Albany Medical Center, 43 New Scotland Ave, Albany, NY 12208, USA

Received 14 October 2021; first decision 30 November 2021; accepted 9 August 2022

For the podcast associated with this article, please visit '<https://academic.oup.com/ehjcr/pages/podcast>'

Background

Primary cardiac sarcomas are rare, aggressive types of malignancies with poor prognoses and can rarely present with thrombocytopenia. Sarcomas account for 65% of primary malignant cardiac tumours. Clinical symptoms often present with constitutional symptoms such as shortness of breath, weight loss, and fatigue. In addition, the tumour's location determines treatment options and prognosis. Multimodal imaging facilitates the detection and assessment of cardiovascular tumours. This case study presents a rare primary right heart cardiac sarcoma presenting with thrombocytopenia.

Case summary

An 80-year-old male presented to the emergency department with complaints of worsening dyspnoea, ease of bruising, and chest pain. An extensive investigation into the cause of thrombocytopenia was performed. A transthoracic echocardiogram, computed tomography scan, and cardiac magnetic resonance (CMR) image revealed a large mass affecting the right atrium and right ventricle. Myocardial biopsy showed high-grade angiosarcoma. Due to his advanced age and intraventricular septal involvement of the mass, the multidisciplinary team decided to proceed with palliative chemotherapy.

Discussion

Many cardiac tumours remain asymptomatic, and the diagnosis is made at an advanced stage of the disease. Differential diagnoses of the intramural masses include haemangiomas, lipomas, rhabdomyomas, lymphomas, and sarcomas. Multiple treatment options should be considered to address thrombocytopenia. Tumour diagnosis and identification consist of laboratory tests and multimodal imaging. Complete surgical resection with neoadjuvant and adjuvant purposes is the mainstay of cardiac sarcoma therapy. A multidisciplinary, individualized care approach should be performed.

Keywords

Case report • Primary cardiac sarcoma • Thrombocytopenia • Transthoracic echo

ESC Curriculum

2.1 Imaging modalities • 2.3 Cardiac magnetic resonance • 2.2 Echocardiography • 2.4 Cardiac computed tomography • 6.8 Cardiac tumours

Learning points

- Primary cardiac sarcomas associated with thrombocytopenia are rare.
- The diagnosis is challenging and requires a team approach and multimodal imaging.
- Primary cardiac sarcoma treatment is complex and individualized, involving both surgical and medical management.

* Corresponding author. Tel: +1 518 331 4232, Fax: 518-262-2671, Email: panis@amc.edu

Handling Editor: Ching-Hui Sia

Peer-reviewers: Andriana Anagnostopoulou; Zain Ul Abideen Asad

Compliance Editor: Sara Monosilio

Supplementary Material Editor: Aiste Monika Jakstaite

© The Author(s) 2022. Published by Oxford University Press on behalf of the European Society of Cardiology.

This is an Open Access article distributed under the terms of the Creative Commons Attribution-NonCommercial License (<https://creativecommons.org/licenses/by-nc/4.0/>), which permits non-commercial re-use, distribution, and reproduction in any medium, provided the original work is properly cited. For commercial re-use, please contact journals.permissions@oup.com

Introduction

Primary cardiac sarcomas are a rare aggressive type of malignancy with an autopsy incidence of 0.001–0.030%, compared with metastatic derived cardiac tumours, which are 20 times more common. Approximately 10% of primary cardiac tumours are malignant, and 90% are benign. Sarcomas account for 65% of primary malignant cardiac tumours.^{1–4} Clinical symptoms and signs are variable; patients often present with constitutional symptoms such as shortness of breath, weight loss, and anaemia-related fatigue and malaise. The tumour's anatomic location may determine the treatment options and prognosis.⁵ The prognosis remains poor, with a median survival of 6–12 months. Complete surgical resection, combined with radiation and neoadjuvant chemotherapy, has increased survival.^{5,6} Multimodal imaging is instrumental in detecting and assessing cardiovascular tumours and can help identify primary cardiac sarcomas in the setting of coagulopathies.⁷ Thrombocytopenia associated with cardiac tumours has rarely been reported. We show a rare case of primary right heart cardiac sarcoma presenting with thrombocytopenia.

Timeline

Date	Event
November 21, 2020	<ul style="list-style-type: none"> • Patient hospitalized with worsening dyspnoea and thrombocytopenia of 47 000/μL (150 000–450 000 platelet/mcL) • Right heart primary cardiac sarcoma involving the interventricular septum without evidence of metastasis was found using multimodal imaging and myocardial biopsy
December 8, 2020	<ul style="list-style-type: none"> • Patient received immunoglobulin infusion, platelet count increased to 103/μL • Patient was considered for chemotherapy and radiation as an outpatient • Patient was discharged home
January 18, 2021	<ul style="list-style-type: none"> • Received outpatient chemotherapy treatment with Doxorubicin • Platelet count dropped to 16 000/μL (150 000–450 000 platelet/mcL) • Second cycle of chemotherapy was scheduled for February 11, 2021, which was subsequently postponed due to severe thrombocytopenia
February 18, 2021	<ul style="list-style-type: none"> • Outpatient trial of steroids with tapering off was administered without any improvement
February 24, 2021	<ul style="list-style-type: none"> • Patient was hospitalized for altered mental status • Computed tomography (CT) head and magnetic resonance imaging (MRI) brain were negative for metastasis, and infectious workup was negative • Patient received Romiplostim therapy; platelet count improved to from 13 000 to 35 000/μL
March 2, 2021	<ul style="list-style-type: none"> • After a multidisciplinary team goals of care meeting, the patient elects to be discharged home for palliative care
June 26, 2021	<ul style="list-style-type: none"> • Patient died

Case presentation

An 80-year-old male presented to the emergency department with a complaint of gradually worsening dyspnoea on exertion for the past 3 months. He had also noticed increased ease of bruising for 1 month. In addition, he reported intermittent mild to moderate chest pain radiating to the shoulder blades. Other complaints included leg swelling, significantly decreased exercise tolerance, nausea and vomiting, loose stools, and a 20-pound weight loss over 3 months. His past medical history included hypertension, hyperlipidaemia, gout, and supraventricular tachycardia treated with ablation 14 years ago. In addition, the patient's family history was significant for uterine sarcoma in his mother and breast cancer in his two daughters. At the initial evaluation, he was comfortable at rest, with a 2/6 systolic murmur over the left lower sternal border, petechiae on both shins, and 1+ bilateral pitting oedema.

Laboratory testing revealed new thrombocytopenia with increased platelet size and an initial platelet count of 47 000 per microliter (150 000–450 000 platelet/mcL), without anaemia or leucopenia. A peripheral blood smear revealed schistocytes. The lactate dehydrogenase (LDH) was elevated at 478 units/L (140–280 units/L), but haptoglobin was undetectable, and the Coombs test was negative. Thrombocytopenia workup for a nutritional deficiency and autoimmune and infectious processes were negative. Idiopathic thrombocytopenic purpura and heparin-induced thrombocytopenia were ruled out given that there was no improvement with steroids and no history of heparin exposure. There was no evidence of chronic infection or other infectious processes. The Lyme antibody test was negative. His colchicine was also held as drug-induced thrombocytopenia was considered. His platelet count did not improve despite eliminating the possibility of drug-induced thrombocytopenia. Although an underlying bone marrow disorder was on the differential, a bone marrow biopsy was not thought to change management. The working diagnosis was thrombocytopenia due to low-grade disseminated intravascular coagulation (DIC), leading to microangiopathic haemolysis and consumption (characterized by schistocytes and an elevated LDH). There was also suspicion of an underlying malignancy or paraneoplastic process. The patient received platelet transfusion with poor response. He then was given two doses of immunoglobulin with an improved platelet count to 103 per microliter. In addition, due to his thrombocytopenia, the patient was not started on therapeutic anticoagulation.

A transthoracic echocardiogram (TTE) for dyspnoea evaluation revealed a non-compressing circumferential pericardial effusion and a

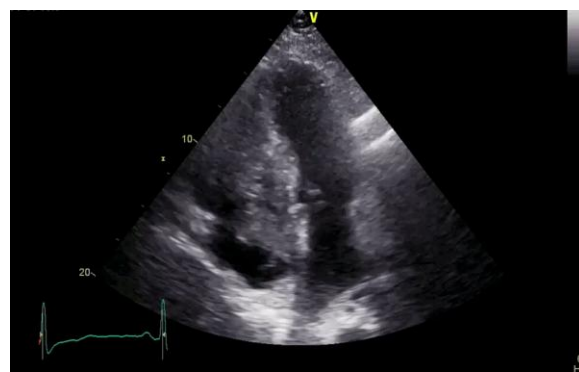

Figure 1 Transthoracic echocardiogram revealed poorly separated from the interventricular septum mass, which completely obliterated the right ventricular cavity and extended into the right atrium. TTE 4-chamber view showing right atrium mass. RA, right atrium; RV, right ventricle; LA, left atrium; LV, left ventricle. White arrow shows intra-ventricular mass.

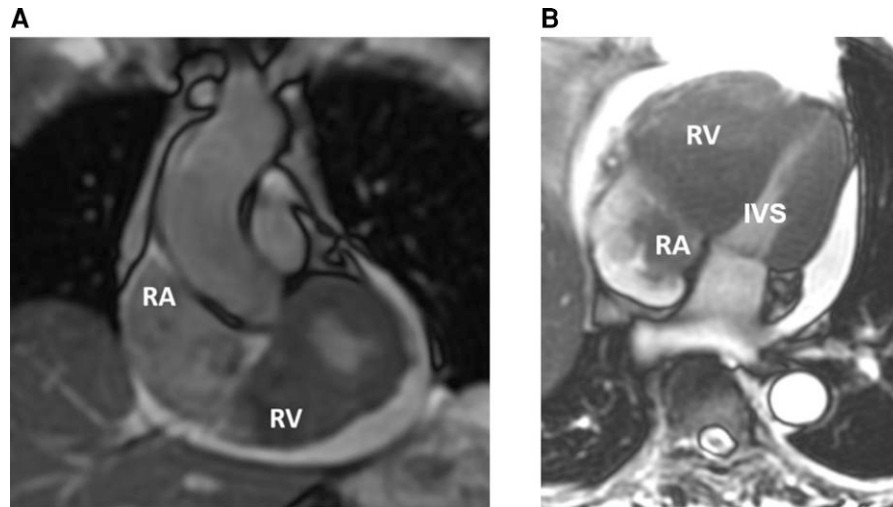


Figure 2 Cardiac magnetic resonance imaging images showing mass obliterating the right ventricular cavity and extending into the right atrium. (A) Sagittal magnetic resonance imaging image of the right ventricular mass with extension into the right atrium. (B) Coronal magnetic resonance imaging image of the right ventricular mass with extension into the right atrium and interventricular septum.

large mass that practically obliterated the right ventricular cavity (Figure 1). The mass was also seen extending into the right atrium across the tricuspid valve and was poorly separated from the interventricular septum. The right ventricular systolic function was depressed. The left ventricular systolic function was normal. A CT scan of the chest identified an 11.4 cm × 5.1 cm × 7.4 cm multilobulated, low attenuation mass in the right atrium and right ventricle. The mass appeared to arise from the atrioventricular septum, extending into the coronary sinus. Cardiac magnetic resonance (CMR) T1 weighted sequences acquired before and after contrast agent administration confirmed a large right ventricular infiltrative mass filled the right ventricle extending through the tricuspid valve into the right atrium. Part of the mass extending into the right atrium demonstrated a component of bland thrombi. The mass invaded the myocardium involving the interventricular septum and right ventricular free wall (Figures 2 and 3). Computed tomography scans of the chest, abdomen, and pelvis and a whole-body positron-emission tomography scan were otherwise negative with no evidence of metastasis. A percutaneous myocardial biopsy was performed. The histology was reported as high-grade sarcoma with an epithelioid growth pattern. The immunohistochemistry was positive for CD34 and actin markers. The epithelioid components were highlighted by CD11 with rare BCL-2 and C-MYC positive cells. IN11 was retained. Vimentin and Ki-67 were diffusely positive. The pericardial fluid's cytopathology after drainage showed only benign mesothelial cells. Given his advanced age and septal involvement of the mass, the patient was not considered for tumour resection.

The patient was discharged home and underwent outpatient chemotherapy with Doxorubicin. Subsequent sessions were scheduled but cancelled due to ongoing thrombocytopenia. The patient was also started on a Dexamethasone trial but was titrated off after no clinical improvement. After a multidisciplinary team, goals of care meeting, the patient elected to be discharged home for palliative care.

Discussion

The differential diagnosis of intracardiac masses involving the right ventricle and right atrium includes metastatic cancer, cardiac lymphomas, thrombi, and sarcomas.¹ Primary cardiac tumours are very rare

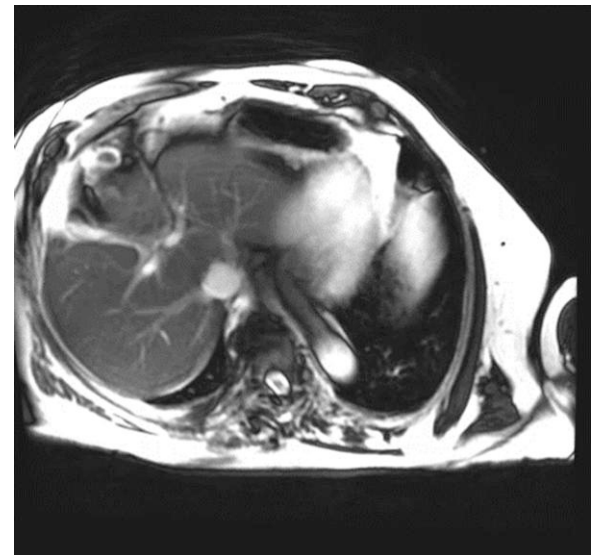


Figure 3 Cardiac magnetic resonance imaging video—four chamber FIESTA imaging revealed an 11.5 cm × 5.1 cm × 4.8 cm mass within right ventricle centred on the basal intraventricular septum. Mass fills the right ventricle cavity, extends through the tricuspid valve into the right atrium, invading the myocardium of the intraventricular septum and right ventricular free wall.

(0.02% of all cardiac tumours), and most are benign, with myxoma being the most common.¹ Incidence of primary malignant cardiac tumours is even lower (0.0017%), and 75% of these are sarcomas.^{1–3} Angiosarcomas are the most common type of sarcomas, occurring in 43% of all sarcoma cases.^{2,3} Sarcomas are typically limited to a single cardiac chamber, most commonly to the left or right atria.² In our patient, the tumour was present in the right ventricle and atrium and invaded the interventricular septum. Differential diagnoses of the

intramural masses include haemangiomas, lipomas, rhabdomyomas, lymphomas, and sarcomas.¹ The median age at presentation is 40–50 years.^{3,4} Currently, we do not have complete understanding of the behaviour of right heart sarcomas in the elderly. Symptoms of cardiac tumours are mainly due to the site of the mass. Many cardiac tumours remain asymptomatic, and the diagnosis is made at an advanced stage of the disease.³ Cardiac sarcomas have a propensity towards early metastatic dissemination to the lung, bone, soft tissue, and brain. While the right heart sarcomas have a more indolent presentation, they tend to metastasize, usually to the lungs.²

Cardiac tumours produce a variety of symptoms. The mass can obstruct intracardiac blood flow potentially interfering with valve function. Arrhythmias or pericardial effusions can occur due to local invasion.^{8,9} A right-sided tumour can embolize, causing a pulmonary embolize, while left-sided tumours can embolize into the systemic circulation, causing stroke or other end-organ damage. Some tumours can cause systemic or constitutional symptoms. Some tumours produce no symptoms and are found incidentally.¹⁰

Coagulopathy is an unusual presentation in cardiac sarcomas. Typical laboratory abnormalities include anaemia, hypergammaglobulinemia, and an elevated erythrocyte sedimentation rate.¹ The causes of these abnormalities are uncertain. Zhang *et al.* reported a primary cardiac synovial sarcoma contiguous with the mitral valve causing severe thrombocytopenia. The platelet count normalized after tumour resection.⁸ Shah *et al.* presented a 37-year-old male diagnosed with right heart synovial sarcoma arising from the tricuspid valve associated with thrombocytopenia thought to be due to an increased platelet consumption. The platelet count returned rapidly to normal after tumour excision.⁹ In our case, the temporary platelet count improvement with immunoglobulin treatment supports an autoimmune-like disorder. The presence of increased LDH and schistocytes suggests a component of mechanical destruction. Cardiac tumours can induce an autoimmune-like disorder with antibodies against target antigens on platelets leading to thrombocytopenia. Mechanical forces such as friction and shearing stress may damage blood components. Also, the tumour may cause turbulent flow, which may lead to platelet activation and consumption.

Tumour diagnosis and identification typically start with multimodal non-invasive imaging. A two-dimensional echocardiography evaluation is done initially, followed by CT and/or cardiac MRI imaging. The information obtained includes size, morphology, anatomical location, attachment, and tumour mobility. Vascular supply, pericardial effusion, pulmonary or venacaval obstruction, and local invasion can also be assessed using these modalities. Cardiac magnetic resonance imaging is the best non-invasive diagnostic tool, as it allows for better soft tissue characterization. On MRI, a sarcoma typically has a heterogeneous appearance on T1 imaging and a slightly hyperintense signal in T2 weighted imaging. A CT scan assesses the lungs, pleura, and mediastinal involvement. Calcifications may be seen in fibromas, myxomas, and teratomas.⁸

The standard of care for a cardiac sarcoma includes induction chemotherapy, followed by interval evaluation for tumour response to therapy, and provides a median survival of 6–12 months.^{11,12} Chemotherapy is used for neo-adjuvant and adjuvant purposes to increase the chances of complete resection and reduce metastatic dissemination. The combination of Doxorubicin and Ifosfamide is the most widely adopted chemotherapy regimen. Surgical resection is reserved for patients responding well to chemotherapy and who have disease isolated to the right heart, pulmonary artery, or left atrium. Tumours of the right atrium and up to 30% of the right ventricle require *en bloc* surgical resection, pericardium reconstruction, and tricuspid valve replacement. When surgery in conjunction with adequate induction therapy are utilized for right heart sarcoma, an R0 resection's success rate can be as high as 60% in one case series.¹² Those with negative resection margins had a median survival of 53 months compared with 9 months for those with residual unresected tumours. Because positive surgical margin status is an independent predictor of reduced survival,

induction chemotherapy is considered to enhance resectability and maximize the possibility of obtaining negative surgical margins.¹³ Tumours involving areas that cannot be reconstructed (the interventricular septum, left ventricle, etc.) are deemed non-resectable. The patient should continue chemotherapy and radiation therapy. Auto-transplantation is another possible strategy: the heart is excised, the tumour is resected, and the cardiac structures are reconstructed before reimplantation.¹⁴ Its perioperative mortality is 15%. A conventional heart transplant can be considered in individual cases.

Conclusion

Primary cardiac sarcomas are a rare type of malignancy compared with metastatic derived cardiac tumours. The symptoms and presentation are often non-specific; this case, presents easy bruising from coagulopathy. Cardiac tumours can induce an autoimmune-like disorder with antibodies against platelets, producing thrombocytopenia. Accordingly, the management of these cases is complex and requires a multidisciplinary team and a multimodal imaging approach. In this case, TTE, echocardiography, CMR, and CT scan were used to delineate the tumour.

The standard of care for cardiac sarcomas includes medical and surgical interventions including induction chemotherapy, followed by evaluation for tumour response to therapy. Surgical resection is reserved for patients who respond well to chemotherapy and have disease isolated to the heart's right or left atrium. A conventional heart transplant can be considered in individual cases.

The prognosis of non-resectable cardiac tumours is generally poor (approximate median survival of 6–12 months). Thus, a joint conversation must be held among everyone involved, particularly the patient and family members throughout the management. All goals of care discussions must be conducted empathetically and compassionately.

Lead author biography



She is trained in the United Kingdom and the United States. She is board-certified in Internal Medicine and is working at Albany Medical Center in New York as a hospitalist. She is interested in complex differential diagnoses, challenging cases, and resident education.

Supplementary material

Supplementary material is available at *European Heart Journal – Case Reports* online.

Slide sets: A fully edited slide set detailing these cases and suitable for local presentation is available online as Supplementary data.

Consent: The authors confirm that written consent for submission and publication of this case report including images and associated text, have been obtained from the patient in line with COPE guidance.

Conflict of interest: None declared.

Funding: None declared.

References

1. Basso C, Rizzo S, Valente M, Thiene G. Cardiac masses and tumours. *Heart* 2016;**102**:1230–1245.
2. Butany J, Nair V, Naseemuddin A, Nair GM, Catton C, Yau T. Cardiac tumours: diagnosis and management. *Lancet Oncol* 2005;**6**:219–228.
3. Andrei V, Schggi V, Stefano PL, Marchionni N. Primary cardiac sarcoma: a case report of a therapeutic challenge. *Eur Heart J Case Rep* 2020;**4**:1–6.
4. Moeri-Schimmel R, Pras E, Desar I, Krol S, Braam P. Primary sarcoma of the heart: case report and literature review. *J Cardiothorac Surg* 2020;**15**:104.
5. Vaporciyan A, Reardon MJ. Right heart sarcomas. *Methodist Debaquey Cardiovasc J* 2010;**6**:44–48.
6. Hamidi M, Moody JS, Weigel T, Kozak KR. Primary cardiac sarcoma. *Ann Thorac Surg* 2010;**90**:176–181.
7. Palaskas N, Thompson K, Gladish G, Agha AM, Hassan S, Iliescu C, Kim P, Durand JB, Lopez-Mattei JC. Evaluation and management of cardiac tumors. *Curr Treat Options Cardiovasc Med* 2018;**20**:29.
8. Zhang G, Gao Q, Chen S, Chen Y. Primary cardiac synovial sarcoma that was continuous with the mitral valve caused severe thrombocytopenia. *J Cardiothorac Surg* 2019;**14**:30.
9. Shah D, Gupta K, Naik D, Bhavsar N. Right atrial synovial sarcoma with thrombocytopenia: a deceptive presentation. *J Card Surg* 2021;**36**:2992–2995.
10. Vander Salm TJ. Unusual primary tumors of the heart. *Semin Thorac Cardiovasc Surg* 2000;**12**:89–100.
11. Torabi S, Arjomandi Rad A, Vardanyan R, Lopuszko AT, Van den Eynde J, Zubarevich A, Sá M, Szczechowicz M, Weymann A. Surgical and multimodality treatment of cardiac sarcomas: a systematic review and meta-analysis. *J Card Surg* 2021;**36**:2476–2485.
12. Abu Saleh WK, Ramlawi B, Shapira OM, Al Jabbari O, Ravi V, Benjamin R, Durand JB, Leja MJ, Blackmon SH, Bruckner BA, Reardon MJ. Improved outcomes with the evolution of a neoadjuvant chemotherapy approach to right heart sarcoma. *Ann Thorac Surg* 2017;**104**:90–96.
13. Kim MP, Correa AM, Blackmon S, Quiroga-Garza G, Weilbaecher D, Bruckner B, Ramlawi B, Rice DC, Vaporciyan AA, Reardon MJ. Outcomes after right-side heart sarcoma resection. *Ann Thorac Surg* 2011;**91**:770–776.
14. Ramlawi B, Leja MJ, Abu Saleh WK, Al Jabbari O, Benjamin R, Ravi V, Shapira OM, Blackmon SH, Bruckner BA, Reardon MJ. Surgical treatment of primary sarcomas: review of a single-institution experience. *Ann Thorac Surg* 2016;**101**:698–702.