

## **Intussusception in two children with SARS-CoV-2 infection in children**

Makrinioti Heidi, MD, PhD\*<sup>1</sup>, Mac Donald Alexander, MBChB\*<sup>3</sup>, Lu X., MD\*<sup>3</sup>, Wallace S., MBChB \*<sup>1</sup>, Jobson Mathew, MBChB<sup>2</sup>, Zhang F., MD<sup>3</sup>, Shao J., MD<sup>3</sup>, Bretherton J., MBChB<sup>2</sup>, Mehmood Tariq, MBChB<sup>2</sup>, Eyre E., MBChB<sup>1</sup>, Wong A., MBChB<sup>1\*</sup>, Pakkiri L., MBChB<sup>1\*</sup>, Saxena Amulya K., MD, PhD\*<sup>2</sup>, Wong G.W., MD<sup>4\*</sup>

1: West Middlesex University Hospital, Chelsea, and Westminster Hospital NHS Foundation Trust, London, UK

2: Chelsea and Westminster Hospital, Chelsea, and Westminster Hospital NHS Foundation Trust, London, UK

3: Wuhan Children's Hospital, Wuhan, Huazhong University of Science & Technology, Wuhan, China

4: Department of Paediatrics, Prince of Wales Hospital, Chinese University of Hong Kong, China

\*: these authors contributed equally to the publication

### **corresponding author:**

Heidi Makrinioti, e-mail [heidimakrinioti@gmail.com](mailto:heidimakrinioti@gmail.com)

## **Abstract**

This report compares intussusception as likely associated with SARS-CoV-2 infection in infants that presented in Wuhan and London. While the intussusception was reduced by enemas in Wuhan, the outcome was fatal. Whereas the intussusception was not reduced by enemas in London and required surgery, the outcome was favourable.

**Key Words:** intussusception, SARS-CoV-2, gut, gastrointestinal, case report

Accepted Manuscript

## **Introduction**

Based on the data so far, severe acute respiratory syndrome coronavirus-2 (SARS-CoV-2) infection in children is shown to run a milder course with lower reported mortality rates (1, 2). Both Chinese and Italian epidemiological studies have shown that approximately 10% children may present with gastrointestinal symptoms, and the presence of these symptoms is associated with increased disease severity (3). However, as the definition of suspected cases does not include presentations with gastrointestinal symptoms only, there is still no clear answer to the question “should we screen for SARS-CoV-2 infection in children who require admission to hospital with gastrointestinal symptoms?”. The current advice from Public Health of England points against this direction (<https://www.gov.uk/government/publications/wuhan-novel-coronavirus-initial-investigation-of-possible-cases/investigation-and-initial-clinical-management-of-possible-cases-of-wuhan-novel-coronavirus-wn-cov-infection>). In addition to the fact that most of the presentations of the infection in children are atypical, there is very recent evidence showing that the highest viral shedding is taking place 2 to 3 days before onset of symptoms (<https://www.nature.com/articles/s41591-020-0869-5>). This evidence could potentially add on existing stress to front-line pediatricians not only around diagnosis and timely management, but also around their protection from contracting the disease. There is mounting evidence around increasing number of deaths in healthcare professionals (4). Therefore, data clarifying the definition of suspected cases is eagerly anticipated. Case studies could be valuable in providing this information while wider epidemiological data is underway.

This brief report describes two cases of intussusception in infants found to be positive with SARS-CoV-2. The first case was reported at Wuhan Children’s Hospital in Wuhan which had a lethal outcome and the second case is being reported from West Middlesex-Chelsea and Westminster Hospital in London with a favourable outcome.

## ***Description of cases***

### ***Wuhan Case***

On 2nd February 2020, a previously healthy 10-month-old girl was brought to the Emergency Department (ED) of the Wuhan Children’s Hospital. She presented with a history of 30 hours paroxysmal crying, vomiting, and passing red currant jelly stool. Ileocolic intussusception was confirmed by ultrasound examination 2 hours after admission and pneumatic reduction was successful. Abdominal X-ray after pneumatic reduction did not reveal any evidence of perforation. Two days after, due to development of progressive respiratory distress, a chest Computed Tomography (CT) scan was performed showing small dense infiltrates in both lower lung fields. Her throat swab and antibody testing were positive for SARS-CoV-2. The infant’s clinical condition continued to deteriorate with progressive distention of the abdomen and absence of bowel sounds. Abdominal CT showed signs of peritonitis, ascites, and swelling of the small intestinal wall. Two days later, a laparotomy was performed with the placement of a defunctioning ileostomy. Despite maximum support with antibiotics, inotropes, and mechanical ventilation, there was a deterioration in her condition; and with the development of disseminated intravascular coagulation, the infant passed away on 8th March.

The infant had no other underlying disease, but her father had fever and cough 5-days prior to her presentation and had recovered without having any specific investigations.

### **London case**

On 30th of March 2020, an otherwise fitting well 10-month old girl presented at the ED of the West Middlesex Hospital in poor condition. She had been unwell for 2 weeks with intermittent coryzal symptoms and bilateral conjunctivitis and followed by abdominal symptoms for which she had visited the ED twice before the latter presentation. She presented with 2 days of bilious vomiting and red currant jelly stool. During her last presentation she was lethargic, had poor peripheral perfusion, and was unresponsive to pain (including interosseous access). Following resuscitation, and suspicion of intussusception she was transferred to Chelsea and Westminster Hospital. Due to failure of air enema reduction management, a surgical reduction was undertaken during which a malrotation was also identified for which a Ladd's procedure was performed. After full recovery, the infant was discharged on 5th of April. Her nasopharyngeal and throat swabs on 30th of March and on 4th of April tested positive in SARS-CoV-2. Extended virus detection panel by PCR did not reveal co-infection with other viral agents.

In the history, mother was identified to have a flu-like illness 3 weeks before. The family isolated as per Public Health of England advice, but mother was never tested for SARS-CoV-2 due to unavailability of mass testing in the United Kingdom. One week after the onset of the mother's illness, the other sibling also got unwell with mild respiratory symptoms and fever.

**Figure 1** describes the timeline of events in both cases and provides ultrasound pictures of the intussusception site in both children.

Blood investigations performed on admission were not suggestive of any abnormalities, consistent with epidemiological data described in most children in the Chinese cohort (1). Inflammatory markers were not raised (C-reactive protein level was 13.8 mg/L in Case 1 and below 5 mg/L in Case 2, white cell counts level was  $5.68 \times 10^9/L$  and  $13.2 \times 10^9/L$  in Case 2). There was no derangement in results of renal and liver investigations. Lymphopenia, that has been described in cases of children who deteriorated and required Extracorporeal Membrane Oxygenation (ECMO), was not noted in any of the two cases (5). The absolute number of lymphocytes was  $4.57 \times 10^9/L$  in Case 1 and  $5.6 \times 10^9/L$  in Case 2.

### **Discussion**

This report describes two infants with intussusception and SARS-CoV-2 infection. There is a case report recently published highlighting similar association ([https://journals.lww.com/pec-online/Citation/2020/06000/COVID\\_19\\_Infection\\_Is\\_a\\_Diagnostic\\_Challenge\\_in.24.aspx](https://journals.lww.com/pec-online/Citation/2020/06000/COVID_19_Infection_Is_a_Diagnostic_Challenge_in.24.aspx)). The first case developed respiratory symptoms during hospitalization and underwent a chest CT scan that revealed changes, whilst the second case had preceding mild respiratory symptoms, therefore did not undergo chest imaging as per current standards of care. Abnormal CT findings have been reported even in children with no respiratory symptoms, but this did not alter their management

course (6). Although both infants presented with symptoms suggestive of intussusception, their disease course differed. Whereas, the Wuhan case had successful reduction of intussusception but was troubled by respiratory and non-respiratory complications, the outcomes in the London case on the other hand was favourable though this infant had failure of air enema reduction and required urgent surgery for the reduction of the intussusception.

These cases describe possible association between SARS-CoV-2 infection and intussusception and the first case is closer to describe causality as rectal swabs tested positive for SARS-CoV-2. However, this finding needs to be described with caution, as recent data show that although SARS-CoV-2 can be detected up to 9 days in stool samples, there is no potential for viral shedding (7, 8). Rectal swab for detection of SARS-CoV-2 was not part of the standard of care provision at the National Health Service (NHS) at that time of the pandemic. In the second case, the child was incidentally found to have undiagnosed malrotation of the bowel. Waugh's syndrome has been described in toddlers who present with signs of chronic intussusception and malrotation of the bowel. In these cases, malrotation of the bowel consists a structural risk factor rather than a trigger for intussusception (9, 10).

The suggested mechanisms underlying include either gut epithelial cells' infection with local reactive mesenteric adenitis that can trigger intussusception or mesenteric adenitis secondary to upper respiratory tract infection with SARS-CoV-2. Back in 1992, the association between adenovirus and intussusception has been documented (11). Adenovirus-2 (Adv-2) serotype, most frequently described as a respiratory pathogen, was the most detected pathogen in children with intussusception (12). Angiotensin-converting enzyme 2 (ACE2) receptor is the functional receptor for SARS-CoV-2. Immunohistochemistry in human tissues revealed the surface expression of ACE2 protein on enterocytes of the small intestine, functioning as a co-receptor for nutrient uptake such as amino acid resorption from food (13). These finding highlights that the gut might also be an important entry site for SARS-CoV-2 infection. However, there is still no evidence of viral replication in gut epithelial cells (14). Many asymptomatic patients undergoing procedures are being found to be SARS-CoV-2 positive and association with underlying problem (intussusception, appendicitis) is unclear and requires further study (15). In adults, evidence of asymptomatic infection on admission for elective surgical procedure was associated with evidence of increased inflammatory response and more adverse outcomes (4).

In conclusion, this brief report aims to urge front-line pediatricians to consider SARS-CoV-2 infection when managing a child with intussusception and to consider taking appropriate precautions, being also aware of any possible respiratory deterioration. For future management and prevention strategies, it is also crucial to understand whether SARS-CoV-2 can infect gut epithelial or endothelial cells and whether susceptibility to gastrointestinal infection is associated with differential innate immune responses of the host. Also, a probabilistic model like the one set up for the associations between rotavirus vaccine and incidence of intussusception, would be particularly helpful (16).

Figure 1a. timeline of events in Wuhan case (Case 1) and in London case (case 2)

Figure 1b. ultrasound images showing similarities in intussusception for Case 1 (left) and Case 2 (right)

## References

1. Lu X, Zhang L, Du H, Zhang J, Li YY, Qu J, et al. SARS-CoV-2 Infection in Children. *N Engl J Med*. 2020.
2. Wu Z, McGoogan JM. Characteristics of and Important Lessons From the Coronavirus Disease 2019 (COVID-19) Outbreak in China: Summary of a Report of 72314 Cases From the Chinese Center for Disease Control and Prevention. *JAMA*. 2020.
3. Caselli D, Arico M. 2019-nCoV: Polite with children! *Pediatr Rep*. 2020;12(1):8495.
4. Lei S, Jiang F, Su W, Chen C, Chen J, Mei W, et al. Clinical characteristics and outcomes of patients undergoing surgeries during the incubation period of COVID-19 infection. *EClinicalMedicine*. 2020:100331.
5. Henry BM. COVID-19, ECMO, and lymphopenia: a word of caution. *Lancet Respir Med*. 2020;8(4):e24.
6. Xia W, Shao J, Guo Y, Peng X, Li Z, Hu D. Clinical and CT features in pediatric patients with COVID-19 infection: Different points from adults. *Pediatr Pulmonol*. 2020.
7. Zhang T, Cui X, Zhao X, Wang J, Zheng J, Zheng G, et al. Detectable SARS-CoV-2 Viral RNA in Feces of Three Children during Recovery Period of COVID-19 Pneumonia. *J Med Virol*. 2020.
8. Wolfel R, Corman VM, Guggemos W, Seilmaier M, Zange S, Muller MA, et al. Virological assessment of hospitalized patients with COVID-2019. *Nature*. 2020.
9. Breckon VM, Hadley GP. Waugh's syndrome: a report of six patients. *Pediatr Surg Int*. 2000;16(5-6):370-3.
10. Zavras N, Tsilikas K, Vaos G. Chronic Intussusception Associated with Malrotation in a Child: A Variation of Waugh's Syndrome? *Case Rep Surg*. 2016;2016:5638451.
11. Bhisitkul DM, Todd KM, Listernick R. Adenovirus infection and childhood intussusception. *Am J Dis Child*. 1992;146(11):1331-3.
12. Selvaraj G, Kirkwood C, Bines J, Buttery J. Molecular epidemiology of adenovirus isolates from patients diagnosed with intussusception in Melbourne, Australia. *J Clin Microbiol*. 2006;44(9):3371-3.
13. Hamming I, Timens W, Bulthuis ML, Lely AT, Navis G, van Goor H. Tissue distribution of ACE2 protein, the functional receptor for SARS coronavirus. A first step in understanding SARS pathogenesis. *J Pathol*. 2004;203(2):631-7.
14. Guzzi PH, Mercatelli D, Ceraolo C, Giorgi FM. Master Regulator Analysis of the SARS-CoV-2/Human Interactome. *J Clin Med*. 2020;9(4).
15. Pan X, Chen D, Xia Y, Wu X, Li T, Ou X, et al. Asymptomatic cases in a family cluster with SARS-CoV-2 infection. *Lancet Infect Dis*. 2020;20(4):410-1.
16. Desai R, Parashar UD, Lopman B, de Oliveira LH, Clark AD, Sanderson CF, et al. Potential intussusception risk versus health benefits from rotavirus vaccination in Latin America. *Clin Infect Dis*. 2012;54(10):1397-405.

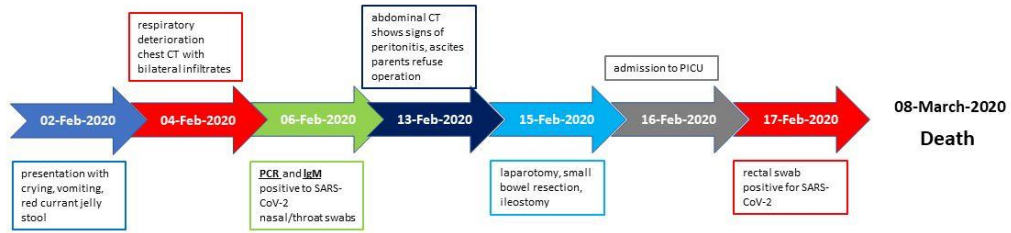
Figure 1a. timeline of events in Wuhan case (Case 1) and in London case (case 2)

Figure 1b. ultrasound images showing similarities in intussusception for Case 1 (left) and Case 2 (right)

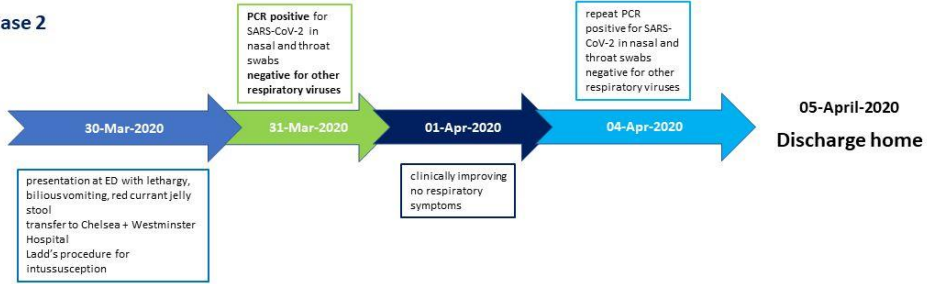
Accepted Manuscript

Figure 1a

Case 1



Case 2



Accepted Manuscript



Figure 1b

