

C A S E R E P O R T

HIV-related non-Hodgkin Lymphoma. Case report and review of the literature

Davide Giordano¹, Andrea Castellucci¹, Francesco Merli², Elisa Garlassi³, Carmine Pernice¹

Azienda USL-IRCCS di Reggio Emilia, Reggio Emilia, Italy: ¹Otolaryngology Unit, Department of Surgery; ²Hematology Unit, Department of Oncology; ³Infectious Diseases Unit, Department of Internal Medicine

Summary. *Background:* HIV-related Burkitt's lymphoma with initial oropharyngeal presentation is rarely reported. The aim of this paper is to report the clinical findings of an unusual case of a patient with extranodal oropharyngeal Burkitt's lymphoma as presenting disease of an unknown HIV positivity and acquired immunodeficiency syndrome. *Methods:* We reported the case of a hispanic patient with extranodal oropharyngeal Burkitt's lymphoma as presenting disease of an unknown HIV positivity and acquired immunodeficiency syndrome. We describe the diagnostic work-up and treatment of this rare case of extranodal oropharyngeal Burkitt's lymphoma. *Results:* Histological exam on oropharyngeal incision biopsy documented a Burkitt's lymphoma. The patient underwent highly active antiretroviral therapy and chemotherapy. After two years of follow-up the patient shows no signs of recurrence from disease. *Conclusions:* HIV-related Burkitt's lymphoma presenting with primary oropharyngeal involvement is rare, with rapidly progressing dysphagia, and does not respond to antibiotherapy. Patients should undergo incision biopsy to rule out a malignancy. In young adults, diagnosis of Burkitt's lymphoma should suggest HIV infection. The importance of a prompt diagnosis in such cases is essential to correctly adequately staging the disease to start highly active antiretroviral therapy and chemotherapy as soon as possible. (www.actabiomedica.it)

Key words: Burkitt's lymphoma, dysphagia, HIV, Highly active antiretroviral therapy

Introduction

Patients with human immunodeficiency virus (HIV) infection are more prone to developing a number of viral-induced malignancies. Along with Kaposi sarcoma, non-Hodgkin lymphoma (NHL) is an AIDS-defining cancer, whose rate is 100-folds higher than in general population (1). Immunosuppression is considered the most relevant factor in promoting oncogenesis in HIV population. Although the prognosis of HIV-related NHL remains poor, introduction of highly active antiretroviral therapy (HAART) for HIV combined with high-dose chemotherapy allows a substantial number of these patients to be cured (2, 3).

The major HIV-related NHL subtypes include Burkitt's lymphoma (BL) and diffuse large B-cell lymphoma. Other rare subtypes, such as primary effusion lymphoma and plasmablastic lymphoma of the oral cavity, are typically Epstein-Barr (EBV) and human herpesvirus-8 positive and found in severely immunocompromised individuals, and thus not limited to HIV infection (2). HIV-related BL with initial oropharyngeal presentation has been rarely reported.

The aim of this paper is to report the clinical findings of an unusual case of a patient with extranodal oropharyngeal BL as presenting disease of an unknown HIV positivity and acquired immunodeficiency syndrome.

Case report

A 24-year-old hispanic man presented with progressive severe dysphagia unresponsive to repeated cycles of antibiotics prescribed by his physician. Inspection of the oropharynx showed a large ulcerating mass involving the right tonsillar region and the soft palate (Figure 1, blue asterisk). An incisional biopsy under local anesthesia revealed the presence of inflammatory tissue. After no improvement of symptoms after 48 hours of intravenous broad-spectrum antibiotherapy, oral biopsy was repeated under general anesthesia. Histological exam documented a malignant population of monomorphic B-cells, strongly positive to CD20, CD10, and C79a. Macrophages interspersed with lymphoid cells gave a “starry sky” histologic pattern that is typical of BL. T-cell markers were negative. In situ hybridization showed EBV positivity. A total body 18-fluorodesossiglucose (^{18}F -FDG) PET/CT scan was performed, which showed a high uptake of ^{18}F -FDG in the right oropharyngeal region with a $\text{SUV}_{\text{max}}=26.6$, corresponding to the primary tumor (Figure 2, arrowhead). Additional secondary low-density lesions were described in several sites of skeleton (Figure 2, continuous arrows) and right adrenal gland (Figure 2, dotted arrow), with a SUV_{max} ranging

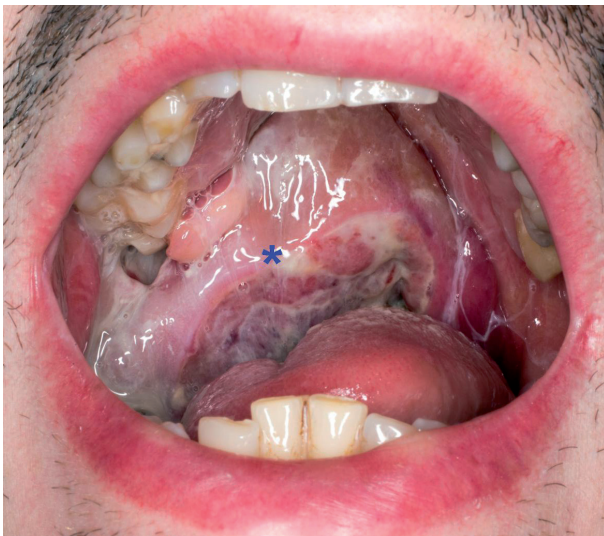

Figure 1. Patient's oropharynx showing a large ulcerating mass involving the right tonsillar region and the soft palate (blue asterisk)

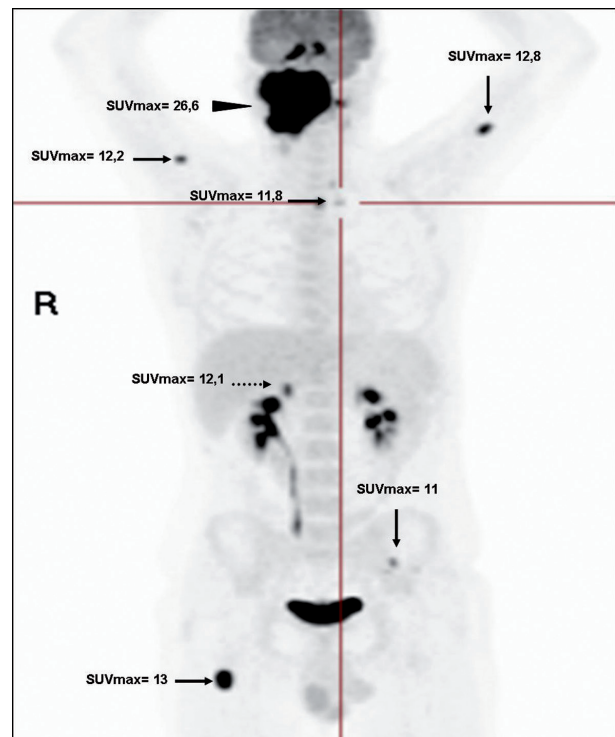

Figure 2. Patient's ^{18}F -FDG PET scan showing a high uptake in the right oropharyngeal region, corresponding to the primary tumor (arrowhead); additional secondary low-density lesions are visible in several sites of skeleton (continuous arrows), and in the right adrenal gland (dotted arrow)

from 11 to 13. Spinal puncture showed no involvement of the central nervous system. Lymphoma was classified as stage IV according to the revised Lugano staging system. Serologic investigations documented an HIV infection, with a CD4 T-lymphocyte count of 589 cells/ μL (23%). HIV infection was then staged as C3 AIDS, according to the U.S. Centers for Disease Control and Prevention (CDC) classification system. Venereal disease research laboratory (VDRL) test and Treponema pallidum Hemoagglutination Assay (TPHA) were positive for syphilis infection. The patient then underwent antineoplastic therapy with two cycles of R-CODOX-M regimen, alternating with 2 cycles of R-IVAC regimen, associated with eight intrathecal methotrexate/cytarabine injections. Concomitant combined antiretroviral therapy with tenofovir/emtricitabine plus raltegravir for HIV infection was started, obtaining a rapid virologic suppression. For syphilis infection, the patient underwent penicil-

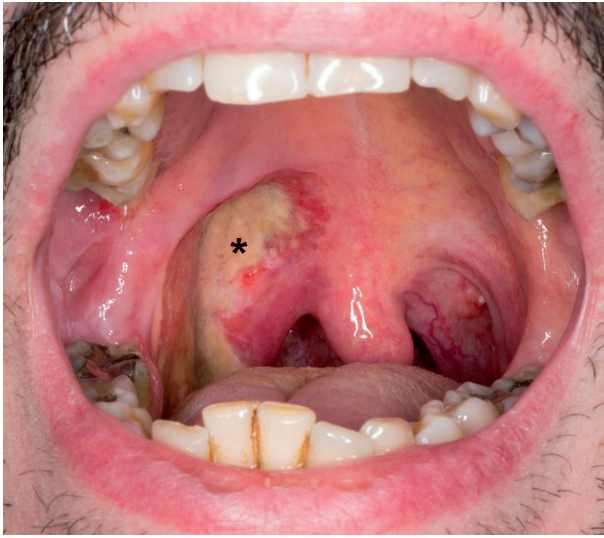


Figure 3. Patient's oropharynx a few weeks after treatment showing a fibrin-filled ulcer of the right tonsillar region, in the site of prior lymphoma localization (black asterisk)

lin G benzathine 2.4 million UI/week for three weeks. Soon after treatment started, the patient's dysphagia improved to complete resolution of symptoms. Oropharynx showed a fibrin-filled ulcer of the right tonsillar region, in the site of prior lymphoma localization (Figure 3, black asterisk). After two years of follow-up, the patient shows no signs of recurrence from BL. Currently, immunological status is satisfactory, with a CD4 T-lymphocyte count of 345 cells/ μ L (30%), and a suppressed viremia.

Discussion

Burkitt lymphoma is an aggressive subtype of NHL, with a high tendency to rapid growth and dissemination. Epidemiologically, BL can be divided in three subtypes: endemic BL, mainly affecting sub-Saharan population; sporadic BL, mostly seen in Western Europe and the United States; AIDS-related BL, which is common in patients affected by HIV infection.

The link between HIV infection and BL is not yet completely understood, although it seems due mainly to the effects of immunosuppression. The main molecular hallmark of BL is given by the MYC proto-oncogene 8q24 translocation, which promotes oncogenesis by constitutive myc activation (4). From an

immunological point of view, several anomalies have been advocated in order to explain oncogenesis, such as chronic polyclonal B-cell activation, increased B-cell turnover, hypergammaglobulinemia (5), T follicular helper cell overexpansion in lymph nodes, (6) natural killer cell defects (7), and increased lymphocyte apoptosis and cell turnover (8). The role of EBV infection is still controversial. In the present case, "in situ" hybridization on neoplastic tissue showed the presence of EBV infection. As reported by Carbone (9), AIDS-related BLs are found to be EBV-positive in about 30-60% of cases. The role of EBV in lymphomagenesis is unclear. In fact, although it is not essential in the pathogenesis of BL, its latent presence in BL cells could contribute to genetic alterations required for development of BL (10).

Generally, BL shows a higher rate in HIV-infected patients and shows more aggressive behavior than in the general population, with higher rates of genital and central nervous system involvement, and extranodal presentation (11-13). Upper aerodigestive tract is rarely reported as a site of presentation of NHL. In 1997, Delacuse (14) first reported the plasmablastic lymphoma of the oral cavity as a new entity, associated with HIV infection. This rare type of NHL typically involves the jaw and the oral cavity of HIV-infected patient, even if other sites, such as anorectum, paranasal sinuses and bones, have been described. Oropharynx is rarely reported in the literature as site of presentation of a BL (13). We here report the case of a case of a 24-year-old man with oropharyngeal BL and an unknown AIDS presented with a rapidly progressing severe dysphagia. Rapid onset of symptoms were interpreted by his physician as infective tonsillitis. First incision biopsy performed on admission showed inflammatory tissue in the specimen. Nevertheless, in such cases the loss of improvement of symptoms after 48-hours of antibiotherapy should prompt physicians to repeat incision biopsy. In this case we preferred to perform a second biopsy under general anesthesia as this would allow us to carefully inspect the oropharyngeal lesion and to collect an adequate sample of tissue to correctly identify neoplastic tissue.

The importance of a prompt diagnosis in such cases is essential to correctly staging the disease. As BL in HIV-infected patients is more aggressive and tends

to present in stage III-IV more commonly than in the general population (15), HAART should be started as soon as possible in order to improve immune status. In fact, although about 20% of HIV-infected patients do not show a response to HAART, defined by no or limited CD4 T-cell rebound to pre-HAART levels, the prognosis of patients affected by HIV-related NHL has significantly improved over time since the introduction of HAART (16). In fact, HAART rapidly suppresses viremia in most HIV patients. The marked improvement of immunological status allows a better control of the HIV infection, and reduces the rates of potentially life-threatening infections. The combination of these effects has facilitated over time the administration of standard doses of chemotherapy to a growing number of patients with HIV-related NHL, with a progressive reduction in the chemotherapy-related deaths seen in the pre-HAART era (16-17). Despite this, physicians should keep in mind that HIV/AIDS continues to be related to a higher of death in patients with lymphoma in the HAART era (18). In particular, Burkitt's type shows poor prognosis and outcomes if compared to other NHL subtypes (19).

Conclusions

HIV-related BL presenting with primary oropharyngeal involvement is rare. Patients with rapidly progressing dysphagia who do not respond to antibiotherapy should undergo incision biopsy in order to rule out a malignancy. In young adults, the diagnosis of BL should suggest HIV infection. The importance of a prompt diagnosis in such cases is essential to correctly staging the disease and to starting HAART and chemotherapy as soon as possible.

Contributors

All authors contributed to patient care and to writing of the report. Written consent to publication was obtained.

Acknowledgements

The authors would like to thank Jacqueline Costa for her valuable contribution in English language editing.

References

1. Wolf T, Brodt HR, Fichtlscherer S, Mantzsch K, Hoelzer D, Helm EB, Mitrou PS, Chow KU. Changing incidence and prognostic factors of survival in AIDS-related non-Hodgkin's lymphoma in the era of highly active antiretroviral therapy (HAART). *Leuk Lymphoma* 2005; 46: 207-15.
2. Carroll V, Garzino-Demo A. HIV-associated lymphoma in the era of combination antiretroviral therapy: shifting the immunological landscape. *Pathog Dis* 2015 Oct; 73(7).
3. Weiss R, Mitrou P, Arasteh K, Schuermann D, Hentrich M, Duehrsen U, Sudeck H, Schmidt-Wolf IG, Anagnostopoulos I, Huhn D. Acquired immunodeficiency syndrome-related lymphoma: simultaneous treatment with combined cyclophosphamide, doxorubicin, vincristine, and prednisone chemotherapy and highly active antiretroviral therapy is safe and improves survival-results of the German Multicenter Trial. *Cancer* 2006; 106: 1560-8.
4. Pannone G, Zamparese R, Pace M, Pedicillo MC, Cagiano S, Somma P, Errico ME, Donofrio V, Franco R, De Chiara A, Aquino G, Bucci P, Bucci E, Santoro A, Bufo P. The role of EBV in the pathogenesis of Burkitt's Lymphoma: an Italian hospital based survey. *Infect Agent Cancer* 2014; 9: 34.
5. Haas A, Zimmermann K, Oxenius A. Antigen-dependent and - independent mechanisms of T and B cell hyperactivation during chronic HIV-1 infection. *J Virol* 2011; 85: 12102-13.
6. Crotty S. Follicular helper CD4 T cells (TFH). *Annu Rev Immunol* 2011; 29: 621-63.
7. Glennie MJ, French RR, Cragg MS, et al. Mechanisms of killing by anti-CD20 monoclonal antibodies. *Mol Immunol* 2007; 44: 3823-37.
8. Moses A, Nelson J, Bagby GC, Jr. The influence of human immunodeficiency virus-1 on hematopoiesis. *Blood* 1998; 91: 1479-95.
9. Carbone A. AIDS-related non-Hodgkin's lymphomas: from pathology and molecular pathogenesis to treatment. *Human Pathol* 2002; 33: 392-404.
10. Kamranvar SA, Gruhne B, Szeles A, Masucci MG. Epstein-Barr virus promotes genomic instability in Burkitt's lymphoma. *Oncogene* 2007; 26: 5115-23.
11. Navarro JT, Vall-Llovera F, Mate JL, Morgades M, Feliu E, Ribera JM. Decrease in the frequency of meningeal involvement in AIDS-related systemic lymphoma in patients receiving HAART. *Haematologica* 2008; 93: 149-50.
12. Dozzo M, Carobolante F, Donisi PM, Scattolin A, Maino E, Sancetta R, Viero P, Bassan R. Burkitt lymphoma in adolescents and young adults: management challenges. *Adolesc Health Med Ther* 2016; 8: 11-29.
13. García Callejo FJ, Morant Ventura A, Tormos MM, Marco Algarra J. Upper dysphagia due to a chemotherapy resistant Burkitt's lymphoma in a lingual tonsil. *Acta Otorrinolaringol Esp* 2003; 54: 109-12.
14. Delecluse HJ, Anagnostopoulos I, Dallenbach F, Hummel M, Marafioti T, Schneider U, Huhn D, Schmidt-Westhausen A, Reichart PA, Gross U, Stein H. Plasmablastic lymphoma

- phomas of the oral cavity: a new entity associated with the human immunodeficiency virus infection. *Blood* 1997; 15; 89: 1413-20.
15. Chao C, Xu L, Abrams D, Leyden W, Horberg M, Towner W, Klein D, Tang B, Silverberg M. Survival of Non-Hodgkin Lymphoma Patients with and without HIV-Infection in the Era of Combined Antiretroviral Therapy. *AIDS* 2010; 24: 1765-70.
 16. Lim ST, Karim R, Tulpule A, et al. Prognostic factors in HIV-related diffuse large-cell lymphoma: Before versus after highly active antiretroviral therapy. *J Clin Oncol* 2005; 23: 8477-82.
 17. Castillo JJ, Echenique IA. Rituximab in combination with chemotherapy versus chemotherapy alone in HIV-associated non-Hodgkin lymphoma: a pooled analysis of 15 prospective studies. *Am J Hematol* 2012; 87: 330-3.
 18. Han X, Jemal A, Hulland E, Simard EP, Nastoupil L, Ward E, Flowers CR. HIV Infection and Survival of Lymphoma Patients in the Era of Highly Active Antiretroviral Therapy. *Cancer Epidemiol Biomarkers Prev* 2017; 26: 303-11.
 19. Xiao J, Du S, Dai G, Gao G, Yang D, Zhao H. Efficacy and tolerability of chemotherapy in Chinese patients with AIDS-related Burkitt lymphoma and diffuse large B-cell lymphoma: An observational study. *Sci Rep* 2017; 7: 1905.
-
- Received: 19 July 2017
Accepted: 28 August 2017
Correspondence:
Davide Giordano, MD, Otolaryngology Unit,
Department of Surgery,
Azienda USL-IRCCS di Reggio Emilia,
Viale Risorgimento 80, 42123 Reggio Emilia, Italy
Tel. 0039 0522 296273
Fax 0039 0522 295839
E-mail: Davide.Giordano@ausl.re.it