

Received: 2018.02.18
Accepted: 2018.04.26
Published: 2018.07.02

e-ISSN 1941-5923
© Am J Case Rep, 2018; 19: 773-777
DOI: 10.12659/AJCR.909545

A Challenging Case of Retroperitoneal Abscess in a Post-Partum Crohn's Disease Patient

Authors' Contribution:
Study Design A
Data Collection B
Statistical Analysis C
Data Interpretation D
Manuscript Preparation E
Literature Search F
Funds Collection G

ABCDEF 1 **Mohamed Elshazzly**
ACDEF 2 **Fuad Bashjawish**
ABCDE 1 **Muhammad A. Shahid**
DE 2 **Dana A. Marrero**
AD 3 **Joel Horowitz**

1 Campbell University School of Osteopathic Medicine, Lillington, NC, U.S.A.
2 Department of Internal Medicine, Cape Fear Valley Hospital, Fayetteville, NC, U.S.A.
3 Department of General Surgery, Cape Fear Valley Hospital, Fayetteville, NC, U.S.A.

Corresponding Author: Mohamed Elshazzly, e-mail: Meelshazzly0201@email.campbell.edu
Conflict of interest: None declared

Patient: Female, 29
Final Diagnosis: Retroperitoneal abscess
Symptoms: Flank bruising • flank pain
Medication: —
Clinical Procedure: Incision • drainage • debridement of the necrotizing soft-tissue infection
Specialty: Infectious Diseases

Objective: Unusual clinical course





Background: Crohn's disease (CD) is an inflammatory bowel disease affecting approximately 1 in 3000 people in the United States. Since the inflammation of CD is transmural, patients are at risk for fistula and abscess formation. Retroperitoneal abscesses are one type of which physicians must be aware.

Case Report: We present the case of a 29-year-old woman with CD who complained of right hip and flank pain that began when she was 6-months pregnant. After delivery, she continued to complain of severe right flank pain and was admitted to the hospital 1 month later. CT scan imaging revealed a complicated retroperitoneal and right flank abscess, possibly due to a colonic intramural fistula. She developed severe acute necrotizing soft-tissue infection requiring 13 days of intensive care. She required debridement of the necrotizing infection of the right flank, drainage of the abscess, and washout for intraperitoneal sepsis. The patient tolerated the procedures well and was discharged 1 month later.

Conclusions: Given that the clinical manifestation of retroperitoneal fistula with abscess is insidious and its formation is less common than intraperitoneal abscesses, we hope healthcare providers learn from this case to avoid morbidity and mortality. When presented with a pregnant CD patient complaining of nonspecific abdominal symptoms, providers should consider fistulization and/or abscess formation. The option to evaluate pregnant patients using noninvasive methods, such as ultrasound or low-dose CT scan, can decrease radiation exposure to the fetus and prevent delays in diagnosis and treatment.

MeSH Keywords: Abdominal Abscess • Crohn Disease • Fistula • Obstetrics • Pregnancy • Retroperitoneal Space

Full-text PDF: <https://www.amjcaserep.com/abstract/index/idArt/909545>

 2018  1  1  20



Background

Patients with Crohn's disease (CD) may report nonspecific symptoms such as fatigue, bloody or non-bloody diarrhea, abdominal pain, and/or weight loss [1]. In certain CD patients, transmural bowel inflammation triggers the development of sinus tracts that can connect to other epithelial-lined organs, leading to the formation of fistulas. According to population-based studies, 14% to 38% of CD patients have a lifetime risk of developing a fistula [2,3]. These fistulas can connect to bowel (enteroenteric), to skin (enterocutaneous), to bladder (enterovesical), to the vagina (enterovaginal), or to the retroperitoneum. However, fistulas that extend posteriorly through the retroperitoneum and iliopsoas space are rare and we will discuss that type here [4].

The diagnosis of retroperitoneal abscess, in the peri- and post-partum period, raises significant challenges due to frequent overlap of nonspecific symptoms and concerns regarding the safety of imaging studies. There still remains much to learn regarding the impact of pregnancy on CD and the impact of usual treatment on the developing fetus. We report the case of a post-partum patient who was found to have a large retroperitoneal abscess that required 14 days of intensive medical and surgical care.

Case Report

Our patient was a gravida I para I, 29-year-old woman who presented to us 3 weeks post-partum with right hip and flank pain and right flank bruising. The pain initially started 4 months prior when she was 6-months pregnant. She had an uncomplicated spontaneous vaginal delivery of a healthy son. After the

delivery, she continued to complain of severe right flank pain. Our patient's past medical history was significant for a 5-year opioid addiction for which she was on Methadone, and Crohn's disease diagnosed at the age of 17. Since her diagnosis, she was on Azathioprine 100 mg twice a day for immunosuppression of her CD. Two years prior to this admission to the hospital, she started to experience acute flares that included severe abdominal pain, vomiting, and bloody diarrhea. She started receiving Infliximab infusions monthly, which successfully suppressed the acute flares. Six months prior to her hospital admission, she stopped getting the Infliximab infusions due to financial concerns, although she continued to have mild acute flares. She was also discharged from 2 separate GI practices due to noncompliance with recommended therapy. She treated the flares before and during the pregnancy with oral prednisone 80 mg. Our patient's contraception of choice prior to her pregnancy was a copper intrauterine device, and she reported no history of sexually transmitted diseases.

Vital signs upon admission showed fever of 100.9°F (38.3°C), pulse 177 bpm, and blood pressure 106/62 mmHg. Admission lab results revealed a white blood cell count of 50 000 cells/mm³, elevated platelet count of 717 mcL, and hemoglobin of 6.0 g/dL (Table 1). Serum chemistries were within normal limits, except for a lactic acid level of 5.2 mmol/L. Liver function tests revealed an elevated alkaline phosphatase of 207 unit/L. Chest X-ray upon admission revealed no acute abnormalities. Non-contrast computerized tomography (CT) scans of the abdomen and pelvis revealed a large complex air-fluid collection within the right flank, right retroperitoneum, and right lateral abdominal wall just superior to the right iliac crest (Figure 1).

The patient was diagnosed with severe sepsis due to retroperitoneal abscess based on her clinical presentation, lab results,

Table 1. Blood monitoring during the first 11 days of hospitalization.

	Day 1	Day 2	Day 3	Day 4	Day 5	Day 6	Day 7	Day 8	Day 9	Day 10	Day 11
White blood cell count	49.8	32	40.4	30	24	25	62.8	48	43	32	–
Red blood cell count	2.4	2.2	3.4	3.4	3.5	4	4.6	4.5	3.5	3.2	–
Hemoglobin	6	5.7	8.7	9	9.3	10.4	12.2	12	9.5	8.3	–
Platelet count	717	388	436	499	436	510	650	631	411	461	–
Lactic acid	5.2	–	–	–	–	–	4.3	2.2	–	–	1.9
Sodium	134	143	140	–	141	137	140	137	140	139	137
Potassium	3.3	3.3	4.8	–	3.7	3.2	3.3	3.4	3.1	2.5	3.3
Calcium	8.7	7.1	8.3	–	7.4	7.8	7.3	7.9	7.7	8	7.6
Albumin	1.4	0.9	1	–	–	–	1.2	–	1	1	1
Alkaline phosphatase	207	148	128	–	–	–	77	–	85	105	120

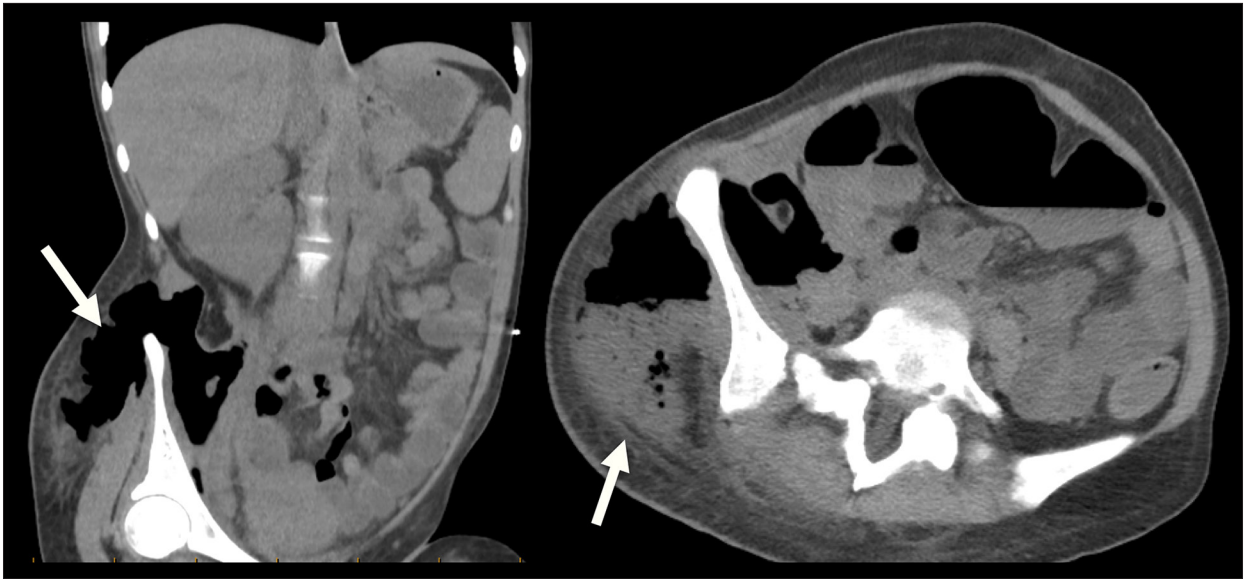


Figure 1. Preoperative CT scan of the abdomen and pelvis without IV and PO contrast reveals large complex air-fluid collection within the right flank, right retroperitoneum, and right lateral abdominal wall just superior to the right iliac crest (see arrows). Air extends through the right retroperitoneum infiltrating the iliopsoas space.

and CT scan findings, and she was quickly taken to the operating room (OR). In the OR, our patient was found to have a complicated pelvic inguinal and right flank abscess secondary to a colonic intramural retroperitoneal fistula that emanated from the cecum. Incision, drainage, and debridement of the necrotizing soft-tissue infection in the area of the right flank were performed. Additionally, the patient had an ileal perforation for which an ileal resection was performed. She was transferred to the intensive care unit (ICU) intubated in stable condition for close postoperative monitoring. OR cultures grew *Escherichia coli* and *Beta Hemolytic Group C Streptococcus* (GCS). The patient was started on IV Meropenem 500 mg daily for treatment of *E. coli*, IV Vancomycin 1000 mg daily for coverage of GCS, and IV Clindamycin 900 mg TID for its anti-toxin effect.

On post-op day 1, the patient was taken back to the OR for additional debridement and irrigation of the necrotizing soft-tissue infection. The area was washed out with 3000 mL of saline fluid and a wound vacuum-assisted closure (VAC) device was placed in the area of the right flank. Her sepsis improved as evidenced by her laboratory results (Table 1) and she was transferred to the medical floor on hospital day 4.

On hospital day 7, the patient was transferred back to the ICU for worsening sepsis with tachycardia, tachypnea, fever, and leukocytosis of 62 000 cells/mm³. Additionally, the patient developed acute respiratory failure requiring 4 liters oxygen via nasal cannula. On hospital day 9, she was taken back to the OR and underwent an exploratory laparotomy, which revealed formation of an intraperitoneal abscess and transverse colon staple line leak with purulence. Drainage of the abscess and

repair of the leak with an omental patch were performed. The pathology findings supported CD as the final diagnosis due to the presence of transmural chronic inflammation, serosal fibrous adhesions with granulation, and peri-colonic abscesses.

Cultures from her second operation grew *Enterococcus faecalis* susceptible to Vancomycin, and light growth of *Candida albicans*. Vancomycin was continued along with Micafungin 100 mg daily. Blood cultures revealed no growth throughout the patient's course. On hospital day 11, she was transferred to the medical floor, where she continued to improve. On hospital day 14, she was discharged to long-term acute care for continued IV antibiotic therapy and aggressive wound management. She left the long-term care facility 4 weeks later.

Discussion

Crohn's disease predisposes patients to spontaneous abscess formation and potential subsequent fistulization. In our literature review, we found that CD patients are known to form enterovesical [5] and ileovesical fistulas [6], and more rarely, enterouterine fistulas [7]. A study examining worldwide variations in etiology of pyogenic psoas abscesses, a type of retroperitoneal abscess, found that CD is the most frequent cause of secondary pyogenic abscess formation worldwide. This finding highlights the importance of keeping such a complication high in the differential for CD patients presenting with insidious onset of abdominal pain, especially in pregnancy, where there are many confounding factors for such symptoms. Previous case reports have reported CD patients presenting with unique

clinical manifestations of retroperitoneal abscesses. One CD patient presented with sudden onset of leg claudication due to a psoas abscess and fistula [8]. Another presented with back pain and was found to have a retroperitoneal abscess with formation of a fistula between the abscess and colon [9].

Our patient experienced a 4-month delay in diagnosis from the onset of symptoms. One reason may have been her physician's anchoring bias: the physician attributed the patient's complaints to drug-seeking behavior due to her history of opioid addiction. The second reason could be attributed to the insidious onset of CD symptoms and their waxing and waning course. It is likely that, particularly during her final months of pregnancy, the pain was attributed to pre-natal symptoms. The third reason may be related to the lack of awareness of rare complications of CD, such as retroperitoneal abscess and hesitation to expose the pregnant patient to radiation for the sake of diagnostic testing. Studies show that it takes 12.7 days on average to establish the diagnosis of retroperitoneal abscess [10,11], so although our patient eventually did well, her delay in care was well outside the expected range. In the above-mentioned study examining worldwide variation in retroperitoneal abscess formation, all 7 patients who died from their infections received delayed care [8].

It is important to know at the beginning of pregnancy if a CD patient has active bowel disease, as she will likely have a milder course during pregnancy if her disease is quiescent at conception [10]. It is recommended that pregnant CD patients have sigmoidoscopy, rectal mucosal biopsy, and stool examination to document nonspecific inflammatory bowel disease as opposed to a specific treatable infection capable of causing bowel inflammation [12]. Should these patients have flares of abdominal pain during gestation, they may receive appropriate doses of prednisone or sulfasalazine to suppress any inflammation and to prevent complications. The decision to use tumor necrosis factor-alpha inhibitor therapy (e.g., Infliximab) in pregnant patients with CD is complex: it seems to be safe if used short-term but may have detrimental effects on the fetus's immune system if used during the 2nd and 3rd trimester, where transfer of the drug from mother to fetus is maximized [13,14]. Therefore, the decision should be made on an individual basis and should favor minimizing fetal exposure to the drug.

It is difficult to make a definitive association between our patient's pre-partum back pain and the post-partum retroperitoneal abscess. CD is known for its waxing and waning course and we suspect that our patient suffered from active bowel disease early in her pregnancy course, with active inflammation playing a role in the fistulization and abscess formation. The chronic transmural inflammation, as evidenced by the pathology report, coupled with the cessation of her Infliximab

infusions, might have contributed to the fistulization process and subsequent penetration of the psoas muscle into the retroperitoneum. Unfortunately, in our patient's case, none of the appropriate imaging studies were performed early enough during pregnancy to detect active inflammation.

The current recommendation is that non-urgent radiologic testing should be avoided in pregnant patients [15]. However, radiologic testing is permitted in pregnant patients who require acute medical care, as it will likely affect the management of the disease in a substantial way [15]. Given our patient's history of CD and the known complications of CD as discussed above, the use of noninvasive ultrasound should be considered. If the results are inconclusive, then 3-way films of the abdomen or low-dose CT scan [<0.05 Gy] are recommended [16]. Moreover, after approximately 20 to 25 weeks of gestation, the fetus is relatively resistant to teratogenic effects of ionizing radiation [16]. Given that our patient presented at 28 weeks of gestational age, a low-dose CT scan would have been justified given her overall clinical presentation.

Regarding the treatment for retroperitoneal abscess, the standard of care involves surgical drainage followed by diversion, and, ultimately, definitive resection [4]. The most successful approach for any perinephric, musculoskeletal, or upper-retroperitoneal infection is a retroperitoneal flank incision with dependent drainage [11]. Medical management of these infections is aimed at treating mixed aerobic and anaerobic bacterial infections with common enteric organisms [14,17]. The combination of an aminoglycoside, penicillin, and clindamycin are recommended in the medical literature, although we note our patient had a penicillin allergy and treatment was adjusted accordingly [14,17]. In addition to drainage of the retroperitoneal abscess, she underwent an ileal resection for her ileal perforation. According to studies done by Regueiro et al. and Yoshida et al., there is strong evidence that starting TNF- α inhibitor therapy within 6 months after an ileocecal resection prevents postoperative recurrence of CD [18,19]. However, the duration of TNF- α inhibitor maintenance post-operatively still remains a subject for future study. Furthermore, it is recommended that all patients should have endoscopic monitoring within the first year after surgery [20].

Conclusions

Our case report provides important medical, surgical, and obstetric considerations in the management of a pregnant Crohn's disease patient. It is important to note that further long-term research is needed to exclude fetal injury from prednisone or sulfasalazine use. Additionally, further research on the effects of exposure of TNF- α inhibitor therapy on the fetus is warranted. Whenever active bowel disease is suspected in pregnant

patients, evaluation with ultrasound, X-rays, and/or low-dose CT scan is indicated. If any intra-abdominal complication occurs during pregnancy and warrants intervention, surgery should not be delayed, as the benefits greatly outweigh the possible risks of operating while gravid. Our patient's critical illness on presentation, prolonged ICU stay, and need for multiple operations highlight the importance of early diagnosis of retroperitoneal abscesses. Our hope is that healthcare providers learn

from this case to avoid serious complications from inadequate pre- and peri-natal medical management of CD and diagnostic delay of its surgical sequelae.

Conflicts of interest

None.

References:

1. Mekhjian HS, Switz DM, Melnyk CS et al: Clinical features and natural history of Crohn's disease. *Gastroenterology*, 1979; 4 pt 2: 898–906
2. Schwartz DA, Loftus EV Jr, Tremaine WJ et al: The natural history of fistulizing Crohn's disease in Olmsted County, Minnesota. *Gastroenterology*, 2002; 122(4): 875–80
3. Hellers G, Bergstrand O, Ewerth S, Holmström B: Occurrence and outcome after primary treatment of anal fistulae in Crohn's disease. *Gut*, 1980; 21(6): 525–27
4. Greenstein AJ, Dreiling DA, Aufses AH Jr.: Crohn's disease of the colon. V. Retroperitoneal lumbococcal abscess in Crohn's disease involving the colon. *Am J Gastroenterol*, 1975; 64(4): 306–18
5. Kawakami S, Yamada T, Watanabe T, Negishi T: Enterovesical fistula complicating Crohn's disease: Report of two cases. *Hinokika Kiyō*, 1992; 38(1): 71–75
6. Mizugaga M, Uchida A, Park YC et al: Ileovesical fistula complicating Crohn's disease: A case report. *Hinyokika Kiyō*, 1989;35(7): 1223–27
7. Wulfeck D, Williams T, Amin A, Huang TY: Crohn's disease with unusual enterouterine fistula in pregnancy. *J Ky Med Med Assoc*, 1994; 92(7): 267–69
8. Moon SB: Successful conservative management of a retroperitoneal abscess with a sinus to the colon: a case report. *Int Surg*, 2016; 101(3): 133–36
9. Christodoulou D, Tzambouras N, Katsanos K et al: Psoas fistula and abscess in a patient with Crohn's Disease presenting as claudication and hip arthritis. *Annals of Gastroenterology* 2001; 14(4): 314–18
10. Donaldson R Jr.: Management of medical problems in pregnancy – inflammatory bowel disease. *N Engl J Med*, 1985; 312: 1616–19
11. Richards RJ: Management of abdominal and pelvic abscess in Crohn's disease. *World J Gastrointest Endosc*, 2011; 3(11): 209–12
12. Ricci MA, Rose FB, Meyer KK: Pyogenic psoas abscess: Worldwide variations in etiology. *World J Surg*, 1986; 10(5): 834–43
13. Gisbert JP, Chaparro M: Safety of anti-TNF agents during pregnancy and breastfeeding in women with inflammatory bowel disease. *Am J Gastroenterol*, 2013; 108(9): 1426–38
14. Skomsvoll JF, Wallenius M, Koksvik HS et al: Drug insight: anti-tumor necrosis factor therapy for inflammatory arthropathies during reproduction, pregnancy and lactation. *Nat Clin Pract Rheumatol*, 2007;3 (3): 156–64
15. Toppenberg KS, Hill DA, Miller DP: Safety of radiographic imaging during pregnancy. *Am Fam Physician*, 1999; 59(7): 1813–18, 1820
16. De Santis M, Di Gianantonio E, Straface G et al: Ionizing radiations in pregnancy and teratogenesis: A review of literature. *Reprod Toxicol*, 2005; 20(3): 323–29
17. Feagins LA, Holubar SD, Kane SV et al: Current strategies in the management of intra-abdominal abscesses in Crohn's disease. *Clin Gastroenterol Hepatol*, 2011; 9(10): 842–50
18. Regueiro MG, Wolfgang SC, Leonard BO et al: Infliximab prevents Crohn's disease recurrence after ileal resection. *Gastroenterology*, 2009; 136(2): 441–50
19. Yoshida K, Fukunaga K, Ikeuchi H et al: Scheduled infliximab monotherapy to prevent recurrence of Crohn's disease following ileocolic or ileal resection: A 3-year prospective randomized open trial. *Inflamm Bowel Dis*, 2011; 18(9): 1617–23
20. Domènech E, Mañosa M, Lobatón T et al: Optimizing post-operative Crohn's disease treatment. *Ann Gastroenterol*, 2014; 27(4): 313–19