



Original research

Tripolar Constrained and Dual Mobility Liners Are Both Successful When Cemented Into Tantalum Acetabular Revision Shells in Complex Revision Total Hip Arthroplasty

Joaquin Valenzuela, MD ^{a, b, *}, Neil R. Bergman, MBBS, FRACS ^c,
Richard Hiscock, MBBS, FANZCA, MBIostat ^d

^a Department of Orthopaedic Surgery. Complejo Asistencial Dr. Sotero del Rio, Santiago, Chile

^b Department of Orthopaedic Surgery. Clínica Universidad de Los Andes, Santiago, Chile

^c Orthopaedic Specialists Melbourne, Victoria, Melbourne, Australia

^d Department Obstetrics and Gynaecology. University of Melbourne, Parkville, Victoria, Australia

ARTICLE INFO

Article history:

Received 12 July 2021

Received in revised form

19 December 2021

Accepted 30 December 2021

Available online xxx

Keywords:

Revision hip

Dual mobility

Tripolar constrained

TMARS

ABSTRACT

Background: Instability is a common complication after revision total hip arthroplasty. Tripolar constrained (TC) and dual mobility (DM) liners cemented into tantalum acetabular revision (TM) shells are established alternatives that reduce instability risk. This study compares outcomes of TC and DM liners cemented into TM shells in complex revision hip replacements.

Methods: Fifty cases using a TM shell and a TC or DM cemented liner with at least 12 months of follow-up were identified. There were 25 TC and 25 DM liners. Clinical, radiographic, and patient-reported outcomes were collected. Reasons for re-revision and failures were analyzed.

Results: The average age was 73 years in the TC group and 75 years in the DM group. The median follow-up duration was 50 months (23 - 96) and 13 months (12 - 21) for the TC and DM groups, respectively. The mean Harris Hip Score improved from 37 to 61 for the TC group and from 51 to 73 in the DM group at the last review. Two TC cases required revision for wear and liner failure. One DM insert was changed at reoperation for periprosthetic femur fracture. There were no failures of cement fixation in either group and no revisions for cup loosening.

Conclusions: In complex revision hip replacement with a history of instability or judged to have a high risk of instability postoperatively, TC and DM liners cemented into tantalum revision shells are both successful, giving acceptable results. The improved arc of movement with DM liners, minimizing impingement, makes them preferable except when there is a global abductor deficiency or severe joint laxity.

© 2022 The Authors. Published by Elsevier Inc. on behalf of The American Association of Hip and Knee Surgeons. This is an open access article under the CC BY-NC-ND license (<http://creativecommons.org/licenses/by-nc-nd/4.0/>).

Introduction

Although total hip arthroplasty (THA) is extremely successful [1,2], dislocation remains a problem, with an incidence from 0.2% to

10% in primary THA and from 10% to 28% after revision THA (rTHA) [3]. Berry et al. [4] reported that in primary hip arthroplasty, the cumulative risk of dislocation is 1% at 1 month and 1.9% at 1 year and rising at a constant rate of approximately 1% every 5 years to 7% at 25 years. Many are single episodes that do not require a revision. Surgery is indicated when recurrent, or where a surgically correctable error has been identified.

Instability is the most common indication for re-revision after rTHA (Re-rTHA), accounting for 20%-35% of all re-revisions [3,5-7]. The Australian Orthopedic Association National Joint Replacement Registry 2020 annual report identifies dislocation as the most common reason for re-revision comprising 33.7% of second

One or more of the authors of this paper have disclosed potential or pertinent conflicts of interest, which may include receipt of payment, either direct or indirect, institutional support, or association with an entity in the biomedical field which may be perceived to have potential conflict of interest with this work. For full disclosure statements refer to <https://doi.org/10.1016/j.artd.2021.12.011>.

* Corresponding author. Plaza 2501, Las Condes. Santiago. Chile. 7620001. Tel.: +56 9 92356567.

E-mail address: jvalenzuelav@gmail.com

<https://doi.org/10.1016/j.artd.2021.12.011>

2352-3441/© 2022 The Authors. Published by Elsevier Inc. on behalf of The American Association of Hip and Knee Surgeons. This is an open access article under the CC BY-NC-ND license (<http://creativecommons.org/licenses/by-nc-nd/4.0/>).

revisions [8]. Multiple factors are related to dislocation after revision hip replacement. These include age [9], number of prior revisions [3,9], reason for current revision, component orientation, and status of the abductor mechanism [9,10].

Large heads, constrained liners, unconstrained tripolar constructs, tripolar constrained (TC) liners, and dual mobility (DM) liners have all been used in an attempt to minimize the risk of instability after rTHA [11–13].

Tantalum trabecular metal (TM) acetabular revision shells, with and without augments, have performed well, particularly in moderate to severe acetabular defects [14–17].

A reduction in dislocation risk is seen after rTHA using DM and TC liners [18,19]. We have cemented them into TM shells in complex revision surgeries since 2003. To our knowledge, there are no studies directly comparing TC and DM cemented liners in either rTHA or Re-rTHA.

The aim of this single-surgeon retrospective observational cohort study was to evaluate and compare clinical and radiographic outcomes, as well as reoperation and revision of TC and DM liners cemented into TM shells in complex revision hip replacement.



Figure 1. Avantage DM liner.

Material and methods

This is a single-surgeon (N.R.B.), single-institution retrospective case series study. An analysis of prospectively collected data from our Human Research Ethics Committee-approved outcome database was performed. Informed consent was obtained from every patient. Between November 2003 (first cemented TC liner) and January 2019, 52 hip revision procedures (in 50 patients) were identified that had used a combination of a TM shell, with or without augmentation (Trabecular Metal Acetabular Revision System; Zimmer Biomet, Warsaw, IN) and either a cemented DM liner (Avantage; Zimmer Biomet, Warsaw, IN) (Fig. 1) or a cemented TC liner (Trident Constrained Acetabular Insert; Stryker, Mahwah, NJ) (Fig. 2) and had ≥ 1 year of follow-up. Two patients were excluded from analysis. One died before the 12-month review, from an unrelated cause. The other patient was lost to follow-up before 12 months but died 10 years later with the implants unrevised.

All patients underwent revision of the acetabular cup, liner and head, with or without revision of the femoral component. The outcome database (<http://socratesortho.com>), medical records, and radiographs were reviewed. Age at surgery, side, indication for revision, previous surgery, body mass index, and Charnley class were recorded. The Harris Hip Score (HHS) [20] was used as a hip-specific outcome. Data were collected preoperatively, at each postoperative review, and at the latest follow-up. All radiographs were reviewed for this analysis.

Operative details included the side and duration of surgery, components revised, and implants used. Acetabular bone defects were categorized according to Paprosky classification [21]. After the acetabular reconstruction was performed, empty holes and screw heads were filled with bone wax. Antibiotic-loaded (gentamicin) acrylic cement was hand-mixed in all cases and inserted early into the shell followed by the acetabular liner (TC or DM). Liner position was adjusted during cementation to accommodate any minor shell malposition (Figs. 3–7).

We identified postoperative complications, reoperations, and revision procedures. The Australian Orthopedic Association National Joint Replacement Registry was queried to identify patients who may have undergone unidentified re-revision THA elsewhere, or who were deceased.

A history of instability, the presence of abductor deficiency (soft tissue or bony), as well as global capsular deficiency were definite indications for cemented TC or DM inserts. Two-stage revision for

infection has a higher incidence of instability after reimplantation [22], and TC or DM liners were often used.

Summary characteristics are presented using mean (minimum, maximum), median (lower and upper quartiles), and number (percent). Between-group comparisons of continuous variables using unpaired t test or difference in medians according to distribution and of categorical variables using likelihood ratio Chi-squared test were performed. Results are presented as point estimate of difference (95% confidence interval [95% CI]) and the associated *P* value. Significance level was two-sided and set at 0.05. No adjustment was made for within-subject correlation where multiple procedures were performed on the same patient, nor for multiple comparisons. Stata v1 6 statistical software was used to perform the analysis (StataCorp. 2019. *Stata Statistical Software: Release 16*; College Station, TX) and the *bpmedian* program [23].



Figure 2. Tripolar constrained liner.

Results

Fifty complex revision hip procedures using a TM shell and a TC or DM cemented liner were analyzed. Two patients had bilateral, but staged, revision procedures: One received TC liners (interval 7 months), and one received DM liners (interval 3 months). There were 25 cemented TC and 25 cemented DM liners that completed a minimum of 12 months of follow-up. The median follow-up duration was 50.0 (23.0 – 96.3) months in the TC group and 13.2 (12.0 – 21.4) months in the DM group; median difference 36.9 (95% CI 8.2 to 65.6, $P = .02$) months. Follow-up was significantly longer in the TC group.

Nine unrelated deaths occurred during the follow-up period, 6 in the TC and 3 in the DM group. None had been Re-revised. Patient characteristics are presented in Table 1. There was no significant difference between groups in sex, age, and body mass index or number of previous arthroplasty procedures. A trend toward a higher number of arthroplasty procedures was seen in the TC group, although not significant.

The acetabular component was revised in all 50 hips. The femoral component was revised in only 29 cases (58%); 17 of 25 (68%) in the TC group and 12 of 25 (48%) in the DM group. Indications for revision surgery included a history of instability in 8 (16%) and infection in 15 (30%). Table 2 summarizes the surgical details.

All patients had improved HHS at follow-up. Raw data means (see Table 3) and associated pointwise 95% confidence limits are presented in Figure 1. The HHS were different preoperatively, with a mean difference of 14 (95% CI -1 to 27, $P = .03$) higher in the DM group. Unadjusted for baseline scores, the mean postoperative HHS score at 12 months was 13 (4 to 21, $P = .005$) points higher in patients who received a DM liner.

The restricted cubic spline regression model indicates that the estimated mean HHS is 14.1 (95% CI 2.2 to 26.0, $P = .02$) points higher in patients with DM liners (Fig. 2).

Two patients in each group underwent early reoperation: 1 for acute infection with a new organism and another for a sterile hematoma in the TC group and 2 for sterile hematomas in the DM group.

Three patients underwent rerevision of components. One DM case had a polyethylene insert change at revision for periprosthetic femur fracture. Two patients in the TC group required late revision

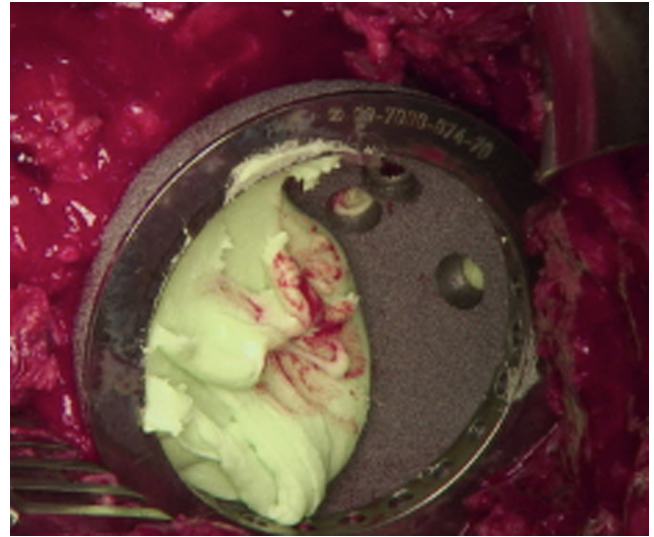


Figure 4. Cement into cup.

for wear and liner failure after 7 and 9 years. One of these had subluxation without dislodging the constraining ring. Radiographic review showed no cup migration, no mechanical breakage, and no progression of radiolucent lines. There was no cemented liner loosening.

Discussion

Instability is the most frequent postoperative complication after revision THA [6] with a cumulative risk after 15 years of up to 35% [7,8]. With increasing numbers of primary procedures, and increasing life expectancy, revision surgery numbers are expected to increase over time [24]. Despite all improvements, dislocation continues to be a devastating complication after rTHA.

Some risk factors have been identified. Abductor deficiency (soft tissue or bony), capsular laxity or deficiency, number of previous surgeries, history of instability, infection, and Paprosky acetabular defect type 3 have all been implicated [7,10,22,25]. This informs

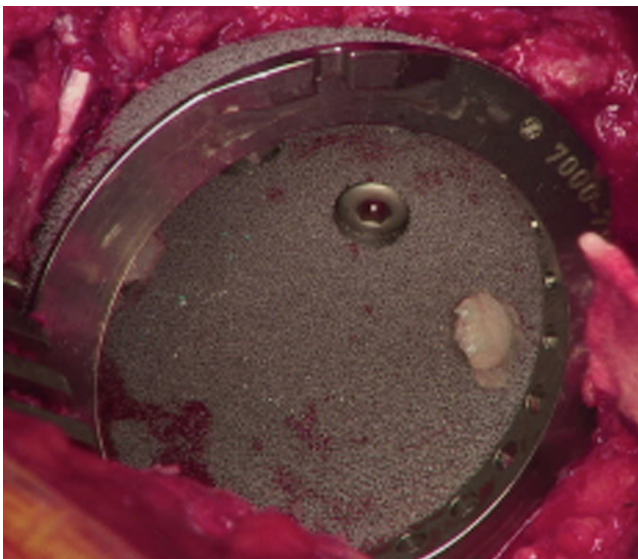


Figure 3. Implanted Trabecular Metal Acetabular Revision System (TMARS).



Figure 5. Cemented DM liner.

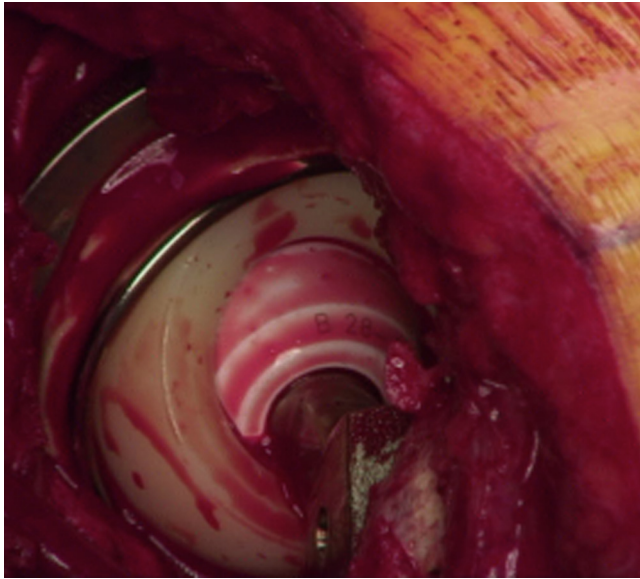


Figure 6. DM reconstruction.

choice at rTHA. Eight patients (16%) in our study had instability as the indication for revision, whereas 15 (30%) cases were 2-stage revisions for periprosthetic infection. This latter has a high risk of instability, with a 9% probability at 1 year [22].

The use of large femoral heads, constrained liners, unconstrained tripolar articulations, and DM and TC liners has been reported to address instability risk. Each liner type has its advantages and disadvantages [11–13,18,19,26].

Constrained acetabular liners (CAL) capture the femoral head [13]. This results in greater forces transmitted to the implant–bone interface, increasing loosening. CAL have a reduced arc of movement. As a result, impingement, resulting in mechanical damage to polyethylene and the locking ring, is another failure mechanism [27]. Poor results and catastrophic failures of the CAL [13,28–30] prompted the TC acetabular liner (Fig 3a and 3b), first reported by

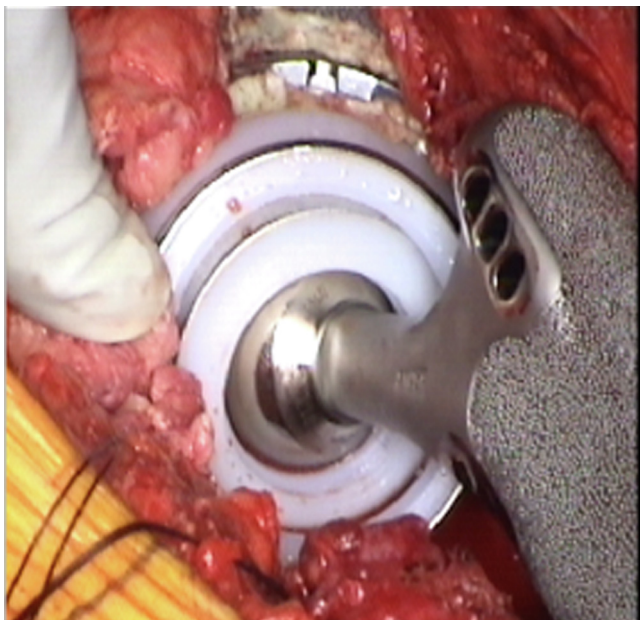


Figure 7. TC reconstruction.

Table 1
Preoperative patient characteristics.

Patient characteristics	Tripolar constrained	Dual mobility	P value
	N = 25	N = 25	
Age (y)	73 (42, 91)	75 (43–88)	.57
Gender (male)	13 (52.0%)	12 (48.0%)	.78
Body Mass Index (kg/m ²)	31.6 (21.1–51.6)	28.8 (17.8–66.6)	.32
Normal	6 (26.1%)	5 (20.0%)	
Over weight	3 (13.0%)	10 (40.0%)	
Obese	12 (52.2%)	7 (28.0%)	
Morbidly obese	2 (8.7%)	2 (8.0%)	
Super obese	0 (0.0%)	1 (4.0%)	
Previous arthroplasty procedures	3 (2–4)	2 (1–3)	.07
1	6 (24.0%)	9 (36.0%)	
2	5 (20.0%)	8 (32.0%)	
3	7 (28.0%)	5 (20.0%)	
4	3 (12.0%)	1 (4.0%)	
5	2 (8.0%)	1 (4.0%)	
7	0 (0.0%)	1 (4.0%)	
8	1 (4.0%)	0 (0.0%)	
12	1 (4.0%)	0 (0.0%)	

Data are given as mean (minimum, maximum), median (lower quartile – upper quartile), and number (%).

Capello et al. [31,32]. A bipolar component is constrained in a polyethylene liner [33]. This results in a larger diameter articulation and an increased range of motion.

DM implants have a larger range of motion than TC bearings. They have emerged as an alternative in the management and prevention of hip prosthesis instability (Fig 4a and 4b). The DM liners have a larger diameter (>36 mm). Cementing into the TM shell allows adjustment to accommodate shell position. Restoration

Table 2
Surgery details.

Surgical variables	Tripolar constrained	Dual mobility	P value
	N = 25	N = 25	
Duration (mins)	275 (235 - 345)	230 (210 - 270)	.10
Side (right)	16 (64.0%)	19 (76.0%)	.35
Charnley Class			
A	3 (12.0%)	2 (8.0%)	
B1	1 (4.0%)	3 (12.0%)	
B2	2 (8.0%)	6 (24.0%)	
C1	14 (56.0%)	0 (0.0%)	
C2	1 (4.0%)	9 (36.0%)	
C3	4 (16.0%)	5 (20.0%)	
Components replaced			
Partial	8 (32.0%)	13 (52.0%)	.15
All	17 (68.0%)	12 (48.0%)	
Diagnosis at revision			
Infection	9 (19.1%)	6 (10.2%)	
Cup loosening	15 (31.9%)	11 (18.6%)	
Dislocation	4 (8.5%)	4 (6.8%)	
Fracture	2 (4.3%)	2 (3.4%)	
Implant breakage	2 (4.3%)	6 (10.2%)	
Pain	9 (19.1%)	13 (22.0%)	
Subsidence	3 (6.4%)	8 (13.6%)	
Wear, no loosening	3 (6.4%)	9 (15.2%)	
Acetabular defect (Paprosky)			
1	0 (0.0%)	1 (4.0%)	
2a	6 (24.0%)	9 (36.0%)	
2b	1 (4.0%)	0 (0.0%)	
2c	1 (4.0%)	3 (12.0%)	
3a	9 (36.0%)	6 (24.0%)	
3b	8 (32.0%)	6 (24.0%)	
Acetabular shell (mm)	66 (56, 78)	66 (58, 80)	.80
Acetabular augments	13 (52%)	12 (48%)	.78
Cup–cage construct	6 (24%)	4 (16%)	.48

Data are given as mean (minimum, maximum), median (lower quartile – upper quartile), and number (%).

Table 3
Outcomes by liner type.

Outcome	Tripolar constrained	Dual mobility	P value
Reoperation			.83
Minor	2 (8.0%)	2 (8.0%)	
Revision	2 (8.0%)	1 (4.0%)	
Loosening	0	0	
HHS			
Preoperative	37 (21, 78)	51(21, 98)	.03
12-mo Postoperative	61 (31, 92)	73 (77, 98)	.005
Deceased	6 (24.0%)	3 (12.0%)	.26

HHS, Harris Hip Score.

Data are given as mean (minimum, maximum), median, (lower quartile – upper quartile), and number (%).

of offset and tension in the abductor mechanism are facilitated [33]. In our DM group, there were no dislocations and no re-revisions. This corroborates the findings of Brüggemann A. et al. [34].

This study demonstrates that both DM and TC bearings are successful at short and midterm follow-up, with low risk of complications and a very low risk of instability (2%), providing good alternatives for addressing cases of complex rTHA and Re-rTHA where there is a high risk of instability. The TM revision acetabular shell is a reliable substrate into which these liners are cemented. No loosening or migration of the cup was seen even in patients with failed liners.

Both groups had similar characteristics. Their follow-up, however, was significantly different ($P = .002$). The TC group had a mean follow-up duration of 59.36 months (12 - 132) compared with 17.32 months (12 - 45) in the DM group. A cemented DM option was not readily available in the early years, so the TC liner was used. As cemented DM liners appeared, they were used more frequently. As a result, the TC follow-up is longer.

The HHS is a reliable tool for assessing clinical outcome in rTHA [35]. Both groups improved, but there was no significant difference, between groups, in that improvement. The DM group had higher preoperative HHS than the TC group. The difference in HHS between groups is entirely accounted for by the baseline (preoperative) difference.

Both groups showed a mean Minimal Clinically Important Improvement in their mean HHS at 12 months compared with the mean baseline scores, according to Singh et al. [36]. Five patients in each group had moderate improvement. These findings suggest that both TC and DM liners in complex revision THA allow a significant clinical improvement.

The higher preoperative HHS in the DM group was examined. There were fewer previous revisions, and less complex revision surgeries were needed in the DM group (Table 1) TC cases were more likely to have a global abductor deficiency. This affects adversely the HHS functional score.

TC liners are successful at 10 years in revision THA for patients with a high risk of instability [37]. Longer follow-up was possible in this group. TC cases had, overall, more complex surgeries. There were 2 late revisions because of wear and liner failure at 7 and 9 years. Although numbers are small, we suggest that TC liners cemented into TM revision cups are reliable.

This is the only report published to date attempting to compare DM to TC liners in complex revisions. Several limitations are acknowledged. The small number of patients in each group makes it impossible to make some statistically significant conclusions. The decision on bearing type used was made on a case-by-case basis. TC patients undergo usually more complex surgeries, and this introduces a selection bias to the disadvantage of the TC group. There was a preference for TC liners in cases with severe abductor deficiency or generalized capsule laxity.

With a longer and similar follow-up for each group, data on more complications, specifically dislocations, may have been collected.

Conclusion

In conclusion, this study supports the use of both DM and TC liners cemented into trabecular metal acetabular revision shells as safe alternatives for patients undergoing complex revision hip replacement.

Institutional Review Board statement

This study was approved by the local institutional review board.

Conflicts of interest

N. R. Bergman is the President of Arthroplasty Society of Australia and the Chair of AOA National Joint Replacement Registry Committee.

References

- [1] Lavernia CJ, Iacobelli DA, Brooks L, Villa JM. The Cost-Utility of total hip arthroplasty: Earlier Intervention, improved Economics. *J Arthroplasty* 2015;30(6):945.
- [2] Austin MS, Higuera CA, Rothman RH. Total hip arthroplasty at the rothman institute. *HSS J* 2012;8(2):146.
- [3] Carter AH, Sheehan EC, Mortazavi SM, Purtill JJ, Sharkey PF, Parvizi J. Revision for recurrent instability: what are the predictors of failure? *J Arthroplasty* 2011;26(6 Suppl):46.
- [4] Berry DJ, von Knoch M, Schleck CD, Harmsen WS. The cumulative long-term risk of dislocation after primary Charnley total hip arthroplasty. *J Bone Joint Surg Am* 2004;86(1):9.
- [5] Springer BD, Fehring TK, Griffin WL, Odum SM, Masonis JL. Why revision total hip arthroplasty fails. *Clin Orthop Relat Res* 2009;467(1):166.
- [6] Jo S, Jimenez Almonte JH, Sierra RJ. The cumulative risk of Re-dislocation after revision THA performed for instability increases Close to 35% at 15years. *J Arthroplasty* 2015;30(7):1177.
- [7] Yoshimoto K, Nakashima Y, Aota S, et al. Re-dislocation after revision total hip arthroplasty for recurrent dislocation: a multicentre study. *Int Orthop* 2017;41(2):253.
- [8] Australian Orthopaedic Association National Joint Replacement Registry (AOANJRR). Hip, knee & shoulder arthroplasty: 2020 annual report. Adelaide: Australian Orthopaedic Association National Joint Replacement Registry; 2020.
- [9] Guo L, Yang Y, An B, et al. Risk factors for dislocation after revision total hip arthroplasty: a systematic review and meta-analysis. *Int J Surg* 2017;38:123.
- [10] Alberton GM, High WA, Morrey BF. Dislocation after revision total hip arthroplasty : an analysis of risk factors and treatment options. *J Bone Joint Surg Am* 2002;84(10):1788.
- [11] Hummel MT, Malkani AL, Yakkanti MR, Baker DL. Decreased dislocation after revision total hip arthroplasty using larger femoral head size and posterior capsular repair. *J Arthroplasty* 2009;24(6 Suppl):73.
- [12] Hartzler MA, Abdel MP, Sculco PK, Taunton MJ, Pagnano MW, Hanssen AD. Otto Aufranc Award: dual-mobility constructs in revision THA reduced dislocation, rerevision, and reoperation compared with large femoral heads. *Clin Orthop Relat Res* 2018;476(2):293.
- [13] Jones SA. Constrained acetabular liners. *J Arthroplasty* 2018;33(5):1331.
- [14] Jafari SM, Bender B, Coyle C, Parvizi J, Sharkey PF, Hozack WJ. Do tantalum and titanium cups show similar results in revision hip arthroplasty? *Clin Orthop Relat Res* 2010;468(2):459.
- [15] Löchel J, Janz V, Hipfl C, Perka C, Wassilew GI. Reconstruction of acetabular defects with porous tantalum shells and augments in revision total hip arthroplasty at ten-year follow-up. *Bone Joint J* 2019;101-B(3):311.
- [16] Lingaraj K, Teo YH, Bergman N. The management of severe acetabular bone defects in revision hip arthroplasty using modular porous metal components. *J Bone Joint Surg Br* 2009;91(12):1555.
- [17] Jenkins DR, Odland AN, Sierra RJ, Hanssen AD, Lewallen DG. Minimum five-year outcomes with porous tantalum acetabular cup and augment construct in complex revision total hip arthroplasty. *J Bone Joint Surg Am* 2017;99(10):e49.
- [18] Wegrzyn J, Tebaa E, Jacquel A, Carret JP, Béjui-Hugues J, Pibarot V. Can dual mobility cups prevent dislocation in all Situations after revision total hip arthroplasty? *J Arthroplasty* 2015;30(4):631.
- [19] Brown TS, Tibbo ME, Arsoy D, et al. Long-Term outcomes of constrained liners cemented into Retained, well-Fixed acetabular components. *J Bone Joint Surg Am* 2019;101(7):620.
- [20] Söderman P, Malchau H. Is the Harris hip score system useful to study the outcome of total hip replacement? *Clin Orthop Relat Res* 2001;(384):189.

- [21] Paprosky WG, Perona PG, Lawrence JM. Acetabular defect classification and surgical reconstruction in revision arthroplasty. A 6-year follow-up evaluation. *J Arthroplasty* 1994;9(1):33.
- [22] McAlister IP, Perry KI, Mara KC, Hanssen AD, Berry DJ, Abdel MP. Two-stage revision of total hip arthroplasty for infection is associated with a high rate of dislocation. *J Bone Joint Surg Am* 2019;101(4):322.
- [23] Newson R. BPMEDIAN: Stata module to compute Bonett-Price confidence intervals for medians and their contrasts. Statistical software components S457051. Boston College Department of Economics; 2009. revised 13 Oct 2013. (accessed 10 October 2020).
- [24] Kurtz S, Ong K, Lau E, Mowat F, Halpern M. Projections of primary and revision hip and knee arthroplasty in the United States from 2005 to 2030. *J Bone Joint Surg Am* 2007;89(4):780.
- [25] Wetters NG, Murray TG, Moric M, Sporer SM, Paprosky WG, Della Valle CJ. Risk factors for dislocation after revision total hip arthroplasty. *Clin Orthop Relat Res* 2013;471(2):410.
- [26] Goldman AH, Thompson JC, Berry DJ, Sierra RJ. Tripolar articulations as a "high Stability bearing" for revision total hip arthroplasty: Success rates and risk factors for failure. *J Arthroplasty* 2020;35(8):2188.
- [27] Yamaguchi M, Akisue T, Bauer TW, Hashimoto Y. The spatial location of impingement in total hip arthroplasty. *J Arthroplasty* 2000;15(3):305.
- [28] Van Eecke E, Vanbiervliet J, Dauwe J, Mulier M. Comparison of constrained acetabular components and dual mobility cups in revision total hip arthroplasty: a Literature review. *Hip Pelvis* 2020;32(2):59.
- [29] Chalmers BP, Arsoy D, Sierra RJ, Lewallen DG, Trousdale RT. High failure rate of modular Exchange with a specific Design of a constrained liner in high-risk patients undergoing revision total hip arthroplasty. *J Arthroplasty* 2016;31(9):1963.
- [30] Guyen O. Constrained liners, dual mobility or large diameter heads to avoid dislocation in THA. *EFORT Open Rev* 2017;1(5):197.
- [31] Goetz DD, Capello WN, Callaghan JJ, Brown TD, Johnston RC. Salvage of a recurrently dislocating total hip prosthesis with use of a constrained acetabular component. A retrospective analysis of fifty-six cases. *J Bone Joint Surg Am* 1998;80(4):502.
- [32] Callaghan JJ, O'Rourke MR, Goetz DD, Lewallen DG, Johnston RC, Capello WN. Use of a constrained tripolar acetabular liner to treat intraoperative instability and postoperative dislocation after total hip arthroplasty: a review of our experience. *Clin Orthop Relat Res* 2004;429:117.
- [33] Lachiewicz PF, Watters TS. The use of dual-mobility components in total hip arthroplasty. *J Am Acad Orthop Surg* 2012;20(8):481.
- [34] Brüggemann A, Mallmin H, Hailer NP. Do dual-mobility cups cemented into porous tantalum shells reduce the risk of dislocation after revision surgery? *Acta Orthop* 2018;89(2):156.
- [35] Shi HY, Chang JK, Wong CY, et al. Responsiveness and minimal important differences after revision total hip arthroplasty. *BMC Musculoskelet Disord* 2010;11:261.
- [36] Singh JA, Schleck C, Harmsen S, Lewallen D. Clinically important improvement thresholds for Harris Hip Score and its ability to predict revision risk after primary total hip arthroplasty. *BMC Musculoskelet Disord* 2016;17:256.
- [37] El-Husseiny M, Masri B, Duncan C, Garbus DS. Long-term results of tripolar constrained total hip arthroplasty in revision hip arthroplasty: a minimum follow-up of ten years. *Bone Joint J* 2019;101-B(6_Supple_B):123.