

## Recurrent high-grade invasive mucoepidermoid carcinoma of larynx: a case report and review of the literature

Whitney King,<sup>1</sup> Stephen Ko,<sup>2</sup> Daniel Miller<sup>2</sup>

<sup>1</sup>William Carey University College of Osteopathic Medicine, Hattiesburg, MS;

<sup>2</sup>Department of Radiation Oncology, Mayo Clinic Hospital, Jacksonville, FL, USA

### Abstract

Recurrent invasive high-grade mucoepidermoid carcinoma of the larynx and hypopharynx is a rare occurrence. These tumors have been commonly associated with salivary gland tumors, most commonly the parotid gland. The patient usually presents with the following symptoms: hoarseness (if larynx is involved), or changes in voice character, sore throat, cough, odynophagia, dysphagia, otalgia, difficulty breathing, weight loss, lymphadenopathy. Here we present a case of a recurrent invasive high-grade mucoepidermoid carcinoma of larynx and hypopharynx. The patient was a 67-year-old male that originally presented in 2006. At that time he underwent a wide field laryngectomy, right thyroid lobectomy, and biopsy of the right digastric node. He was a clinical stage III, pT3N0M0. No adjuvant radiation therapy was given at that time. The patient remained asymptomatic until February 2014, when he presented with dysphagia and neck swelling. Positron emission tomography/computed tomography showed evidence of recurrence. The patient was treated with definitive intensity modulated radiation therapy (IMRT) with concurrent chemotherapy. Treatment for this disease is gathered by scattered case reports. If surgery is a possibility it is considered as first line therapy. Post-surgical radiation is then offered. However, in this case the recurrent tumor was located near the carotid artery, and thus surgery was not a possibility. Therefore, concurrent chemotherapy and radiation with IMRT and weekly cis-platinum was given. While the optimum combination of treatment has not yet been established because of the rarity of this cancer's location site, the current patient appeared to have an excellent response from the definitive IMRT and chemotherapy treatment.

### Introduction

The following is a case that describes recur-

rent high-grade invasive mucoepidermoid carcinoma of the larynx. Mucoepidermoid carcinomas (MEC) are mainly known as being associated with salivary gland cancers. However, mucoepidermoid carcinoma is much more rarely seen in the larynx.<sup>1</sup> Mucoepidermoid carcinomas are made up of three cell types. The cell types include: epidermoid cells, mucus secreting cells, and intermediate cells. Intermediate cells are predominate, and their appearance ranges from small basal cells with basophilic cytoplasm to large oval cells with eosinophilic cytoplasm. The mucous cells occur in singles or clusters with pale or foamy cytoplasm, with peripherally placed nuclei. These mucous cells often form lining of cysts or ducts. Epidermoid cells have eosinophilic cytoplasm, and rarely have keratin pearl formation or dyskeratosis. High-grade tumors show atypia with a high mitotic frequency, areas of necrosis, and are more likely to show perineural invasion. Stroma hyalinization is also common.<sup>2</sup>

Symptoms of MEC of the larynx include: persistent hoarseness, (the most common symptom), dysphasia, dyspnea, otalgia, cough, and presence of a neck mass. In this particular case the patient presented with dysphagia as his main symptom. This patient's MEC tumor involved each of the three compartments of the larynx.<sup>3</sup> In the supraglottic region of the larynx the bilateral arytenoids were involved. In the glottis region of the larynx the MEC tumor involved the true cords. Finally the cricoid cartilage, which is part of the subglottic region of the larynx, was seen to have MEC tumor present. High-grade mucoepidermoid carcinoma of the larynx is a very aggressive tumor.

### Case Report

A 76-year-old male, initially presented in 2006 with dysphagia, was subsequently diagnosed with invasive high-grade mucoepidermoid carcinoma of the larynx. In March 2006 the patient underwent a wide field laryngectomy, right thyroid lobectomy, and biopsy of the right upper digastric jugular node. Pathology revealed invasive high-grade mucoepidermoid carcinoma measuring 3×2.5×1.5 cm involving the bilateral arytenoids, right glottis, and cricoid cartilage. Computed tomography (CT) shows the initial mass (Figure 1). Perineural invasion was seen. The surgeon was able to obtain negative margins. One lymph node was negative for malignancy. The patient was initially given a stage of pT3N0M0. The patient did not receive any adjuvant radiation therapy at that time. The patient was having regular follow-up by Otolaryngology. The patient underwent routine follow-up with positron emission tomography/computed tomography

Correspondence: Whitney King, Department of Radiation Oncology, Mayo Clinic Hospital Jacksonville, PO Box 18733, Hattiesburg, MS 39404, FL, USA.

E-mail: wkgk2015@gmail.com

Key words: Mucoepidermoid carcinoma; larynx; hypopharynx; tumor.

Contributions: the authors contributed equally.

Conflict of interest: the authors declare no potential conflict of interest.

Received for publication: 14 September 2015.

Revision received: 18 January 2016.

Accepted for publication: 20 January 2016.

This work is licensed under a Creative Commons Attribution NonCommercial 4.0 License (CC BY-NC 4.0).

©Copyright W. King et al., 2016

Licensee PAGEPress, Italy

Rare Tumors 2016; 8:6204

doi:10.4081/rt.2016.6204

(PET/CT) in April of 2008, which was negative except for some mild hypermetabolic activity at the base of the tongue on the right side. PET/CT in September 2008 showed no worrisome hyper metabolic activity.

The patient presented to Otolaryngology in 2009 with stage I, mucosa-associated lymphatic tissue (MALT) lymphoma of the gastric fundus, which was unresponsive to antibiotic therapy. The patient underwent definitive image guided intensity modulated radiation therapy (IMRT) treatment to a dose of 3000 cGy in 20 fractions, delivered to the stomach and surrounding lymph nodes completed in February 2009. In September of 2012 the patient underwent a speech and swallow test that was normal. The patient presented again in February 2014 with dysphagia, swelling in the left neck, and concerns for possible lymphadenopathy. The patient denied pain anywhere else. In February of 2014 a PET/CT showed an enlarged level II nodal mass in the left measuring 5.2×3.0 cm with a maximum standardized uptake value (SUV) of 4.6. Also present was a smaller level II lymph node on the right that measured approximately 1 cm with a maximum SUV of 4.4. Findings were noted to be consistent with nodal metastatic disease. At the site of the prior laryngectomy site there was an irregular soft tissue mass deep to the stoma that had a maximum SUV of 4.2. His case was presented at the multidisciplinary head and neck tumor board, and the surgeon felt that the patient's neck disease was unresectable given the proximity to the carotid artery. The surgeon recommended

definitive radiation therapy at that time. PET/CT shows the location of the tumor in relation to the carotid artery (Figure 2). The tumor completely encased the carotid artery making it an unresectable tumor.

In March of 2014 a CT of neck showed abnormal bilateral lobulated inhomogeneously enhancing cervical soft tissue masses at the level of the submandibular gland, more extensive on the left than the right, this was concerning for metastatic lymphadenopathy. The mass on the left measured 5.0 (SI)  $\times$  4.8 (AP)  $\times$  3.1 (RL) cm in maximum. The mass displaced the left submandibular gland anteriorly, left carotid artery medially and posteriorly, and the sternocleidomastoid muscle (SCM) lateral-

ly. There was partial obliteration of the fat plane between mass and submandibular gland, left carotid artery, and left SCM. The lesion extended superior to the left mandibular angle. The lesion was hypermetabolic on PET/CT.

The right cervical lesion measured 1.5 $\times$ 1.3 $\times$ 1.3 cm in maximum dimensions. It was located posteriorly to the right submandibular gland, lateral to right common carotid artery, and anterior to the right internal jugular vein and fat planes laterally. There was hypermetabolic activity noted on PET/CT. Diffuse soft tissue prominence was also noted at the superior aspect of the tracheal stoma which was hypermetabolic on PET/CT scan. Based on these findings tumor recurrence

could not be excluded. Given the location of the tumor and the maximum SUV of greater than 4 at both nodal levels, it was consistent with metastatic disease and treatment for recurrence was initiated.

The patient received definitive chemo-radiation therapy from March 2014 to May 2014, using image guided IMRT to a dose of 7000 cGy in 35 fractions, with weekly cis-platinum. Towards the end of radiation therapy weekly cis-platinum (40 mg/m<sup>2</sup>) was stopped, and carboplatinum was administered because of possible ototoxicity.

In August of 2014 a CT of the neck and PET/CT showed a good response to treatment. There was one persistent level II lymph node in the left neck, which remained at 1.4 cm in size. PET/CT showed minimal metabolic activity. His case was then again presented at the multidiscipline head and neck tumor board and the decision was made to monitor this closely. PET/CT shows these findings (Figure 3).

In September 2014 a follow up CT of neck showed stability in left sided level II lymph node, and the decision to biopsy was made. An ultrasound guided biopsy of left sided level II lymph node was performed. Pathology was negative for metastatic cancer; however, polymorphous low-grade lymphoproliferative disorder could not be excluded.

The patient's level II lymph node decreased in size, but remained contrast enhancing on CT with a size greater than 1 cm. The patient underwent esophageal dilatation, which greatly improved his dysphagia. The patient remained concerned regarding the swelling in his neck and possible lymphadenopathy, but denied any odynophagia.

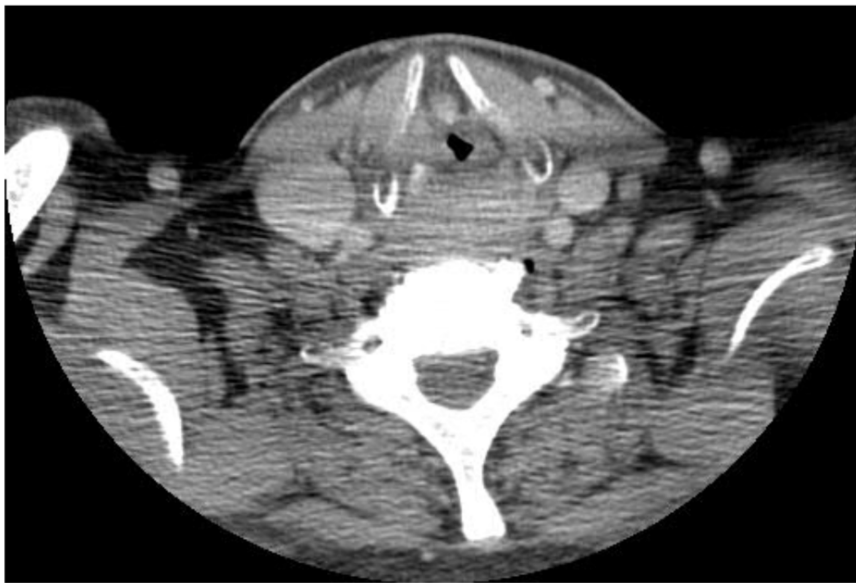


Figure 1. Computed tomography. Initial tumor presented (2006). At this point a wide field laryngectomy, right thyroid lobectomy, and biopsy of the right upper digastric jugular node were performed. Final pathology revealed high-grade mucoepidermoid carcinoma.

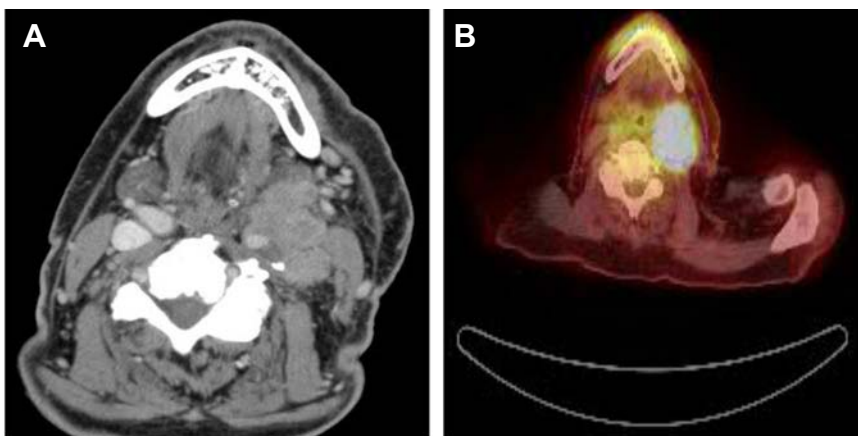


Figure 2. Positron emission tomography/computed tomography (PET/CT). February 2014: A) Image shows right sided tumor completely encasing the common carotid artery, thus making this tumor unresectable; B) Image shows PET/CT scan with hypermetabolic activity. Also shown is the enlarged large level II nodal mass in the left neck.

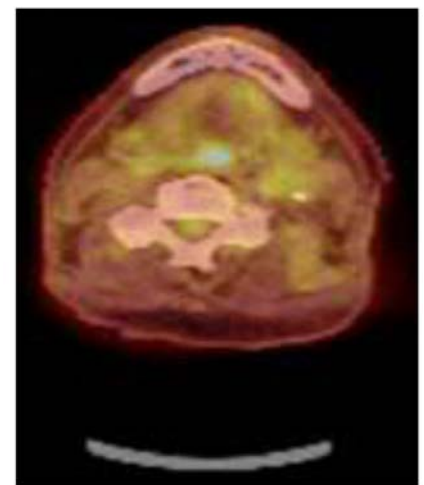


Figure 3. Positron emission tomography/computed tomography. August 2014. Post definitive intensity modulated radiation therapy and chemotherapy, shows patients significant response to treatment.

In November 2014 a fine needle aspiration of the left cervical level II node was performed. Pathology was non-diagnostic, showing only benign fibro-adipose tissue. He continued to report persistent dysphagia, but denied odynophagia. He still has to chew his pills before he is able to swallow. He is following up with Gastroenterology concerning this issue. The final impression was after definitive IMRT and chemotherapy he still had a persistent left sided level II lymph node, but after biopsy there was no evidence of metastatic disease. We will continue to follow up every three months to continue to watch this level II node.

## Discussion and Conclusions

Mucoepidermoid carcinoma of the larynx/hypopharynx is a very rare tumor. These types of cancers are more known to affect the parotid gland. Some sources suggest that the mainstay treatment for this type of cancer is surgery with adjuvant radiation and chemotherapy.<sup>4,6</sup> In most cases of laryngeal MEC it is recommended to use >2 Gy/fraction for Tis and T1-2N0 glottis tumors. In cases of T1 disease where all the gross tumor has been surgically removed 60 Gy may be used. If Chemo-RT is chosen for definitive treatment of laryngeal MEC then a typical dose of 70 Gy in 35 fractions is recommended. If the patient for some reason cannot receive chemotherapy a fractionated dose of greater than or equal to 72 Gy may be used. Radiation therapy for larynx early stage 2.0-2.5 Gy/fraction to 63-66 Gy. For more advanced stage, the dose is also increased to 72 Gy if the patient cannot tolerate chemotherapy. Postoperative RT is given at 1.8-2 Gy per fraction to 50-54 Gy, and then boosted to 60-66 Gy in high-risk areas. Or IMRT can be used postoperatively with the following fraction schemes: CTV1 (high risk): 2/60-66 Gy, CTV2 (elective neck): 1.6-2/≥50-56 Gy.<sup>4</sup>

MEC of the larynx are so rare that there are literally only a few case reports that have identified this type of tumor. Out of those few cases, most of those were in patients who had T0 or T1 tumors. Two of the patients did have high grade MEC of the larynx but those were

initially misdiagnosed, and thus only on failed therapy did the diagnosis of MEC present. A study titled, *Salivary gland carcinomas of the larynx: A national study in Denmark* looked at two patients that had MEC of the larynx. One patient that presented with laryngeal carcinoma was initially misdiagnosed as having squamous cell carcinoma of the larynx. The patient was treated, and failed therapy. He presented with recurrence and it was at that time that he was then correctly diagnosed as having MEC of the larynx.

The first case was a 72-year-old male that presented in 1995 with hoarseness as his major complaint. He was diagnosed with MEC of the glottis region of the larynx with a T1N0M0 stage. He was treated with laser excision and adjuvant RT. The surgeon was able to obtain negative margins. The patient had regular follow up out as far as 60 months. Currently this patient is reported as being alive without evidence of disease. The second case that presented was in a 51-year-old male in 1994. His major complaint was dysphagia and odynophagia. He was found to have high grade MEC of the supraglottic region. Stage was T3N0M0. This patient was treated with RT as the single therapy. The patient subsequently recurred at 8 months at the tumor site. Patient was followed for a little over a year, and he died from the disease.<sup>7</sup>

There was also a Japanese study done titled, *Mucoepidermoid carcinoma of larynx: A case which responded completely to radiotherapy and a review of the literature*. In this study one patient was studied that was diagnosed with MEC of bilateral vocal cords. The patient was an 81-year-old male, and so even though surgical intervention was recommended the patient declined because of his age. He had T1bN0M0 disease. Radiation therapy was given by accelerated hyperfractionation, 55 Gy was given b.i.d. over three weeks. The dose was 1.7 Gy/fraction daily with a minimum interval of 6 hours in between treatments. It was reported that the tumor completely responded to accelerated hyperfractionation radiation therapy, and has been reported a live greater than 6 years.<sup>8</sup> In the case of our patient further surgery was precluded based on the location of the tumor with involvement of the carotid artery. He underwent definitive IMRT to a dose of

7000 cGY in 35 fractions, and had a significant positive outcome. He responded well and currently has only one persistent level II lymph node which is being watched. Biopsy of this node showed no evidence of metastatic disease. Therefore, while this is still a rare tumor that does not have sufficient treatment data we have shown significant benefit in this patient following definitive IMRT at 7000 cGY in 35 fractions. He currently remains disease free. We will continue to follow up with the patient every three months to monitor the persistent level II lymph node, to ensure that no recurrence is seen.

## References

1. Mokhtari S, Mokhtari S. Clinical features and differential diagnoses in laryngeal mucoepidermoid carcinoma. *Clin Med Insights Pathol* 2012;5:1-6.
2. The Oral Cancer Foundation. Mucoepidermoid carcinoma. 2014. Available from: <http://www.oralcancerfoundation.org/facts/rare/mc/>.
3. National Cancer Institute at the National Institutes of Health. Laryngeal cancer treatment. 2014. Available from: [http://www.cancer.gov/cancertopics/pdq/treatment/laryngeal/HealthProfessional/page1#\\_299\\_toc](http://www.cancer.gov/cancertopics/pdq/treatment/laryngeal/HealthProfessional/page1#_299_toc)
4. Hansen E, Roach M, III. Handbook of evidence-based radiation oncology. Berlin: Springer; 2007. pp 112-23.
5. Raghavan D, Martin L, Bretcher D, et al. Textbook of uncommon cancer, 3rd Ed. Hoboken: Wiley; 2006. pp 106-8.
6. Beyzadeoglu M, Ozyigit G, Ebruli C. Basic radiation oncology. Berlin: Springer; 2010. pp 239-47.
7. Nielsen TK, Bjørndal K, Krogdahl A, et al. Salivary gland carcinomas of the larynx: a national study in Denmark. *Auris Nasus Larynx* 2012;39:611-4.
8. Shonai T, Hareyama M, Sakata K, et al. Mucoepidermoid carcinoma of the larynx: a case which responded completely to radiotherapy and a review of the literature. *Jpn J Clin Oncol* 1998;28:339-42.