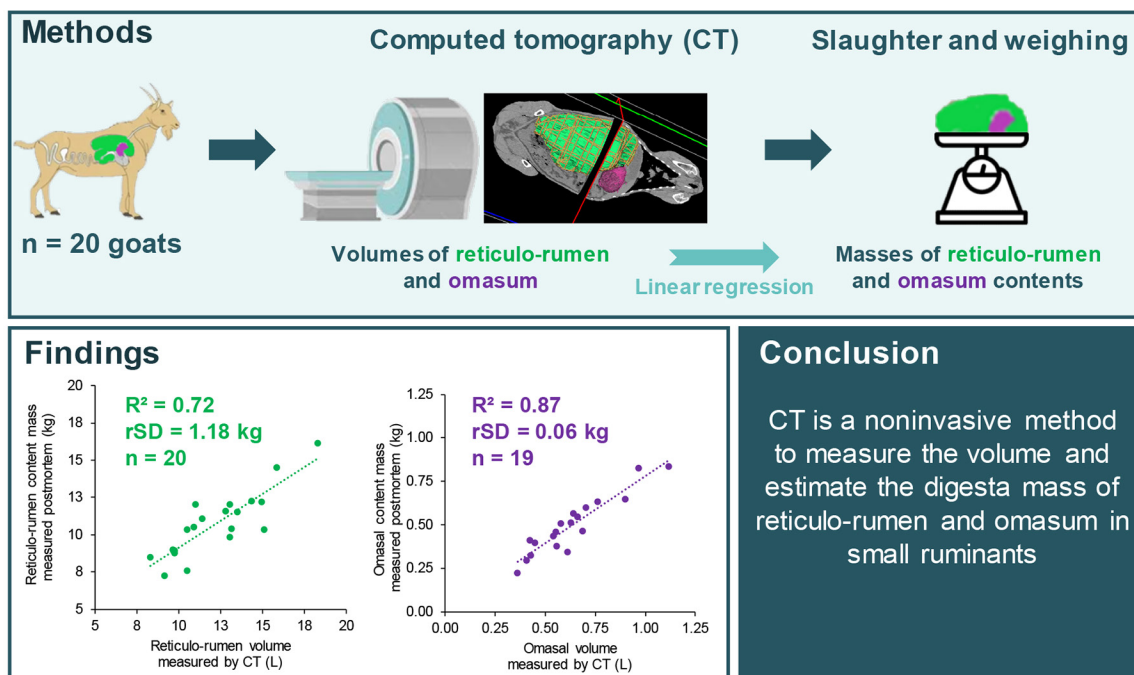


# The use of computed tomography for in vivo estimation of reticulo-rumen and omasum contents in Alpine goats

J. A. A. Pires,<sup>1\*</sup> M. Monziols,<sup>2</sup> P. Lamberton,<sup>3</sup> C. Huau,<sup>4</sup> A. De La Torre,<sup>1</sup> and S. Lerch<sup>5</sup>

## Graphical Abstract




## Summary

Quantification of reticulo-rumen content (volume and mass) is required in ruminant nutrition research but has traditionally relied on rumen-cannulated animals. The use of computed tomography (CT) is compatible with small ruminants. We compared the reticulo-rumen and omasum volumes measured by CT in vivo with the corresponding digesta masses measured postmortem in Alpine goats ( $n = 20$ ). Reticulo-rumen and omasum volumes determined by CT were significantly and linearly regressed against the corresponding digesta masses measured postmortem ( $R^2 = 0.72$  and  $0.87$ , respectively), thus demonstrating the potential of CT to measure volume and estimate digesta masses of reticulo-rumen and omasum contents in goats.

## Highlights

- Goats were CT scanned, and the reticulo-rumen and omasum digesta weighed.
- Reticulo-rumen and omasum CT volumes allowed estimation of their digesta masses.
- CT may be a noninvasive alternative to rumen cannulation for estimating digesta masses.



<sup>1</sup>INRAE, Université Clermont Auvergne, Vetagro Sup, UMRH, 63122, Saint-Genès-Champanelle, France, <sup>2</sup>IFIP Institut du Porc, 35650 Le Rheu, France, <sup>3</sup>PEGASE, INRAE, Institut Agro, 35590 Saint Gilles, France, <sup>4</sup>GenPhySE, Université de Toulouse, INRAE, ENVT, 31326 Castanet-Tolosan, France, <sup>5</sup>Ruminant Nutrition and Emissions, Agroscope, 1725 Posieux, Switzerland. \*Corresponding author: [jose.pires@inrae.fr](mailto:jose.pires@inrae.fr). © 2024, The Authors. Published by Elsevier Inc. on behalf of the American Dairy Science Association®. This is an open access article under the CC BY license (<http://creativecommons.org/licenses/by/4.0/>). Received November 06, 2023. Accepted January 19, 2024.

The list of standard abbreviations for JDSC is available at [adsa.org/jdsc-abbreviations-24](https://adsa.org/jdsc-abbreviations-24). Nonstandard abbreviations are available in the Notes.

# The use of computed tomography for in vivo estimation of reticulo-rumen and omasum contents in Alpine goats

J. A. A. Pires,<sup>1\*</sup> M. Monziols,<sup>2</sup> P. Lamberton,<sup>3</sup> C. Huau,<sup>4</sup> A. De La Torre,<sup>1</sup> and S. Lerch<sup>5</sup>

**Abstract:** Precise in vivo measurement of reticulo-rumen content (volume and mass) is required for the study of digestive processes. Rumen-cannulated animals have been classically used for this purpose, and less invasive alternatives are currently investigated to meet the replacement, reduction, and refinement (3Rs) ethical considerations in animal science. The objective was to compare in vivo reticulo-rumen and omasum volumes assessed by computed tomography (CT) scan with postmortem measurement of their respective digesta masses in dairy goats. Twenty Alpine dairy goats were scanned by CT, and the volumes of the reticulo-rumen and omasum were measured by CT image postprocessing. Goats were slaughtered immediately after CT scan and the masses of reticulo-rumen and omasum digesta were measured. Simple linear regressions were performed between volumes measured in vivo by CT and the corresponding digesta wet masses measured postmortem. Reticulo-rumen and omasum volumes determined by CT were significantly and linearly regressed against the corresponding digesta masses measured postmortem ( $R^2 = 0.72$  and  $0.87$ , residual standard deviation =  $1.18$  and  $0.06$  kg, and residual coefficient of variation =  $11\%$  and  $12\%$ ,  $n = 20$  and  $19$ , respectively). The use of CT is a promising noninvasive method to measure volume and estimate digesta masses of reticulo-rumen and omasum in small ruminants.

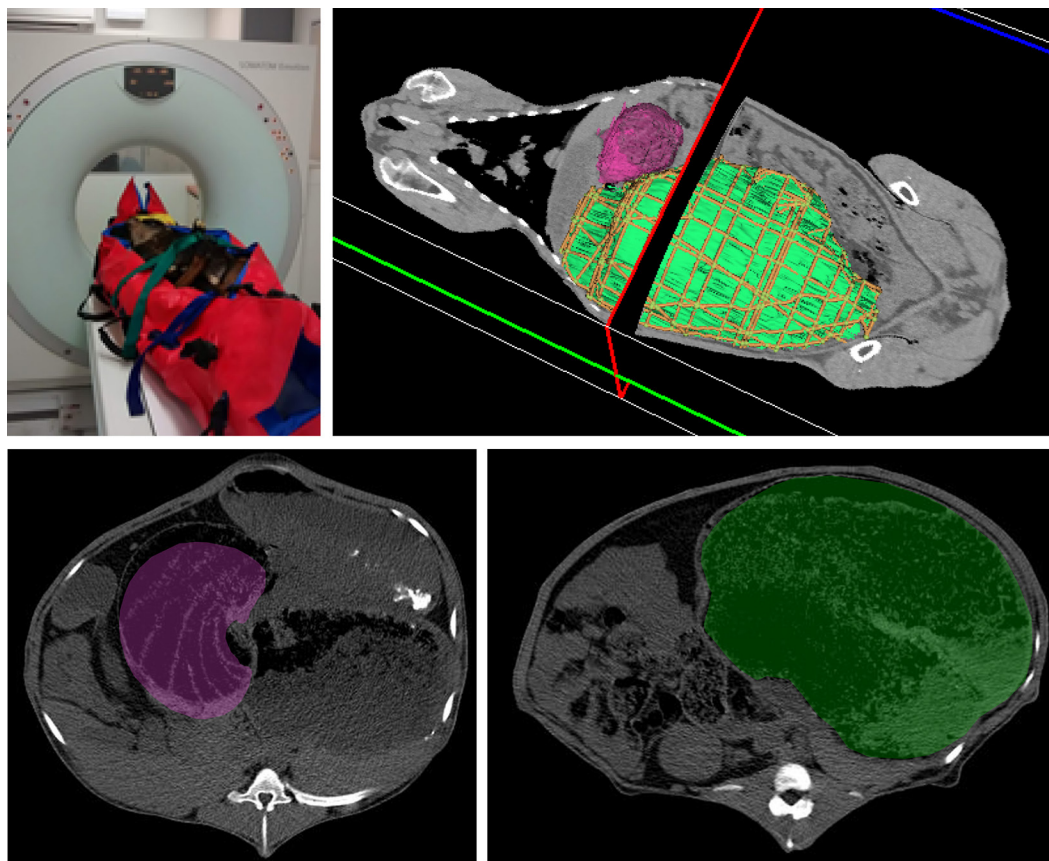
Quantification of reticulo-rumen content (volume and digesta mass) is required in ruminant nutrition to study adaptations to lactation stage, to study the effects of diet and environment on rumen fill and metabolism, to model digestive processes, and ultimately to determine the nutritional value of feeds and diets (Dann et al., 1999; Reynolds et al., 2004; Bannink et al., 2016). These measurements and estimates have been made for decades using rumen-cannulated animals and tracer dilution techniques. Animal scientists are continuously refining experimental procedures by developing less invasive and more accurate techniques, in accordance with the principles of the 3Rs (replacement, reduction, and refinement). For this purpose, the body size of small ruminants is compatible with the use of computed tomography (CT), which has been most commonly used to estimate body composition in vivo (Scholz et al., 2015; Lerch et al., 2021), and to study the dynamics of fat mobilization and accretion during lactation (Dønnem et al., 2011; Eknæs et al., 2017). Detailed anatomical studies of internal organs have been conducted and validated by comparing in vivo CT imaging with postmortem transverse body sections of frozen goats and calves, including reticulo-rumen and omasum (Braun et al., 2011, 2014). Recently, CT has also been used to investigate associations between reticulo-rumen volume and several phenotypes of interest in sheep. For example, reticulo-rumen volume measured by CT scan is moderately heritable (Lambe et al., 2022), and is positively correlated with methane production (Goopy et al., 2014; Waite et al., 2019), but not with residual feed intake in sheep (Lambe et al., 2023).

We hypothesized that reticulo-rumen and omasum digesta masses could be estimated from their respective internal volumes measured by CT image analysis in Alpine goats. Therefore, the objective was to compare reticulo-rumen and omasum internal volumes determined in vivo by CT with postmortem measurements of reticulo-rumen and omasum digesta masses in Alpine goats.

Twenty Alpine dairy goats ( $3.0 \pm 0.6$  [SD] yr old;  $226 \pm 9$  DIM) with BW ranging from 47 to 72 kg were housed in a freestall barn, had ad libitum access to hay and water, were offered 0.75 kg/d of concentrate, and were milked once a day ( $1.07 \pm 0.32$  kg/d) in the morning. All goats were part of a study comparing methods for body composition estimation (Lerch et al., 2021). For practical reasons, goats were blocked by BW and allocated randomly to 4 groups of 4 to 6 animals, and studied in 4 successive calendar days. Blocking was used to ensure a wide range of BW among goats each calendar day, and therefore minimize potential confounding between day of slaughter and goat body size and body composition, which would be a concern for the previous study (Lerch et al., 2021).

Goats were studied within 3 h of being transported from the barn to slaughter facility. During this period goats had access to water, but not feed. Anesthesia, CT scan, and slaughter were performed sequentially within 15 min. We spaced the CT scan between each goat to allow for postmortem procedures as described in Lerch et al. (2021). Goats were anesthetized ( $0.05$  mL/kg BW i.v. of  $100$  mg/mL of ketamine; Imalgene 1000, Merial, Lyon, France) and placed on an inflatable mattress (Corben, Le Havre, France) to

<sup>1</sup>INRAE, Université Clermont Auvergne, Vetagro Sup, UMRH, 63122, Saint-Genès-Champagnelle, France, <sup>2</sup>IFIP Institut du Porc, 35650 Le Rheu, France, <sup>3</sup>PEGASE, INRAE, Institut Agro, 35590 Saint Gilles, France, <sup>4</sup>GenPhySE, Université de Toulouse, INRAE, ENVT, 31326 Castanet-Tolosan, France, <sup>5</sup>Ruminant Nutrition and Emissions, Agroscope, 1725 Posieux, Switzerland. \*Corresponding author: [jose.pires@inrae.fr](mailto:jose.pires@inrae.fr). © 2024, The Authors. Published by Elsevier Inc. on behalf of the American Dairy Science Association®. This is an open access article under the CC BY license (<http://creativecommons.org/licenses/by/4.0/>). Received November 06, 2023. Accepted January 19, 2024.



**Figure 1.** Illustrative figure of Alpine goat immobilization and image acquisition. The internal volumes of reticulo-rumen (green) and omasum (violet) were measured by CT scan (horizontal image section in the top-right panel and vertical image slices in the bottom panels), based on approximately 150 to 200 images per goat, and analyzed semi-automatically.

minimize movements before CT scan (Figure 1). Goats were positioned in dorsal recumbency to minimize distortion of the abdomen and internal organs, as previously reported by Braun et al. (2014) when goats were placed in sternal recumbency for CT scan. The CT scan was performed using a Siemens emotion duo CT scanner (Siemens, Erlangen, Germany) with the following acquisition parameters: tube tension 130 kV, tube current 40 mAs, slice thickness 3 mm, FoV 500 mm × 500 mm, matrix 512 × 512, and convolution kernel B30s (soft tissue). Between 400 and 500 whole-body images were generated per goat, of which approximately 150 to 200 images corresponding to the reticulo-rumen and omasum location were analyzed semi-automatically. External image features (i.e., CT table, and parts of the mattress) were removed by binarization, connected component labeling, and by keeping the largest label functions of the MorphoLibJ plugin for the ImageJ software (Legland et al., 2016), and the remaining inaccurate voxels were removed manually. The internal volumes of reticulo-rumen and omasum, excluding their walls, were determined separately from the entire goat image sets using TurtleSeg software (<https://www.medicalimageanalysis.com/software/turtleseg>; Top et al., 2011; Figure 1). The software allows one to manually draw the boundaries on a subset of the images in the 3 planes (20–30 images in the axial plane, 5–10 images in the sagittal and coronal planes). These boundaries are considered as landmarks by the software, which

generates then a 3-dimensional interpolation of the segmented volume. Additional measurements of empty body soft tissue, fatty tissue, and bone volumes were reported elsewhere (Lerch et al., 2021).

Each goat was slaughtered within 15 min after anesthesia followed by CT scan, still under anesthesia and according to legally defined procedures (i.e., electronarcosis followed by exsanguination). In less than 30 min after slaughter, the reticulo-rumen and omasum were separated from the viscera, and omental adipose tissue removed. Each of the forestomach compartments was further weighed full, and reweighed after being emptied from digesta. Reticulo-rumen and omasum digesta masses were obtained by the difference (Lerch et al., 2021). Data for omasum digesta mass from one goat had to be excluded from the statistical analysis due to a recording error. The error was confirmed by comparison with the records of its omasal digesta sample used to determine its water content in a previous study (Lerch et al., 2021).

The GLM procedure of SAS 9.4 (SAS Institute Inc., Cary, NC) was used to test simple linear regressions between reticulo-rumen or omasum volumes measured in vivo with CT and their respective digesta masses measured postmortem.

All procedures performed on animals were approved by the Ethics Committee on Animal Experimentation and the French Ministry of Higher Education, Research and Innovation

**Table 1.** Descriptive statistics of reticulo-rumen and omasum internal volumes measured in vivo by CT and respective digesta masses measured postmortem in Alpine late-lactation goats

Item	n	Mean	SD	Minimum	Maximum	Q1 <sup>1</sup>	Median	Q3 <sup>1</sup>
BW (kg)	20	54.7	6.6	45.6	66.9	49.4	53.4	58.9
Total body volume by CT (L)	20	56.6	6.7	47.5	68.9	52.3	56.4	60.8
Reticulo-rumen								
Digesta mass (kg)	20	10.76	2.19	7.27	16.18	9.00	10.46	12.03
Volume by CT (L)	20	12.21	2.59	8.29	18.27	10.28	12.05	13.66
Omasum								
Digesta mass (kg)	19	0.495	0.164	0.224	0.833	0.387	0.466	0.582
Volume by CT (L)	20	0.624	0.196	0.360	1.119	0.487	0.595	0.689

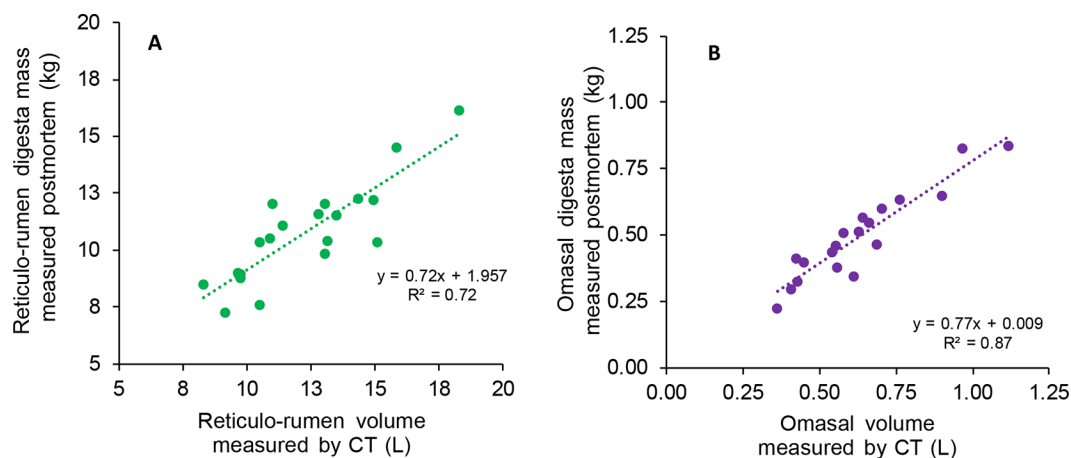
<sup>1</sup>Q1 = first quartile; Q3 = third quartile.

(APAFiS#15681–2018062622272488\_v2). The experiment was conducted in the IEPL (PEGASE, INRAE, Institut Agro, Saint Gilles, France) and 3P facilities (INRAE, 2018, Pig Physiology and Phenotyping Experimental Facility, <https://doi.org/10.15454/1.5573932732039927E12>).

Descriptive statistics of reticulo-rumen and omasum digesta volumes measured in vivo by CT scan, and corresponding digesta masses measured postmortem, are presented in Table 1. The apparent density (mass of digesta/internal volume of the forestomach compartment) was numerically lower in the omasum than in the reticulo-rumen ( $0.74 \pm 0.20$  and  $0.89 \pm 0.11$  kg/L, respectively). This could be explained in part by the inclusion of the omasum laminae into the total omasum volume determined by CT, whereas those were not included when measuring the omasum digesta mass postmortem. Although we were able to exclude the volume of outer omasum walls by image analysis, the estimated internal organ volume includes both the digesta and the omasum laminae, which are intricately associated (Figure 1), as previously demonstrated in goats by comparing in vivo CT-scan images with corresponding postmortem transverse body sections (Braun et al., 2011)

Reticulo-rumen and omasum volumes determined by CT scan were good estimators of digesta mass measured postmortem (Figure 2,  $R^2 = 0.72$  and  $0.87$ , residual standard deviation [rSD] = 1.18 and 0.06 kg, and residual coefficient of variation [rCV] =

11% and 12%;  $n = 20$  and  $19$ , respectively). For practical reasons, we measured the digesta masses of reticulo-rumen and omasum postmortem, whereas the corresponding digesta volumes were measured in vivo by CT scan, by excluding the organ walls from image analyses. Because all goats were offered the same forage and the same amount of concentrate, we hypothesized that digesta volume and mass would be highly correlated in this study, which was confirmed. Nonetheless, in vivo volume of reticulo-rumen may be influenced by the volume of the gas and other complex liquid and solid phases it contains (Goopy et al., 2014). The gas contribution to the total digesta volume would be difficult to measure accurately postmortem, or even in vivo in cannulated animals. A variable proportion of gas in the reticulo-rumen may explain in part why the  $R^2$  was lower for reticulo-rumen compared with omasum regression ( $0.72$  vs.  $0.87$ , respectively). Individual differences in feeding behavior, water intake, rumen fill, particle size distribution, and passage rate may have also contributed to residual error of regression estimations in this study. We further explored the possibility of estimating the volume occupied by gas in the reticulo-rumen using image pixel analysis as follows: The density of each pixel was examined using the Hounsfield units (HU). These are a measure of tissue density based on the X-ray attenuation characteristics. The lowest Hounsfield value in a CT image is  $-1,024$  HU, while air is calibrated at  $-1,000$  HU. Pixels



**Figure 2.** Linear regressions between (A) the reticulo-rumen internal volume measured in vivo by CT scan and the reticulo-rumen digesta mass measured postmortem ( $R^2 = 0.72$ , rSD = 1.18 kg,  $n = 20$ ), and (B) the omasum internal volume measured in vivo by CT scan and the omasum digesta mass measured postmortem ( $R^2 = 0.87$ , rSD = 0.06 kg,  $n = 19$ ) in Alpine late-lactation goats.



corresponding to gas were considered as having between  $-1,024$  and  $-900$  HU as some ruminal gas Hounsfield values are below the air value. All pixels with this signal were summed and then multiplied by the pixel volume ( $2.86 \text{ mm}^3$ ) for each reticulo-rumen. This calculation allows estimation of the gas volume, which can be deducted from the total internal reticulo-rumen volume, and determination of digesta volume excluding the gas phase. Gas volume estimated in this way was  $0.153 \pm 0.128$  L (mean  $\pm$  SD) and ranged from  $0.093$  to  $0.683$  L (first quartile =  $0.099$ ; third quartile =  $0.151$ ; median =  $0.119$  L). Subtracting the estimated gas volume from total digesta volume did not improve regression with the digesta mass measured postmortem ( $R^2 = 0.72$ ). Because this method to estimate gas volume could not be validated by a direct comparison, we decided not to report this regression.

The use of CT is a promising noninvasive method for measuring volumes and estimating digesta masses of reticulo-rumen and omasum in small ruminants. Further research is warranted to test the ability of this technique to discriminate gas versus liquid and solid phases of reticulo-rumen, the effects of dietary treatments that induce differential rumen fill, and to explore associations between reticulo-rumen and omasum volumes and phenotypes of interest to the dairy industry, such as enteric methane production, feed efficiency, and adaptation to changing nutritional environments.

## References

- Bannink, A., H. J. van Lingen, J. L. Ellis, J. France, and J. Dijkstra. 2016. The contribution of mathematical modeling to understanding dynamic aspects of rumen metabolism. *Front. Microbiol.* 23:1820. <https://doi.org/10.3389/fmicb.2016.01820>.
- Braun, U., M. Irmer, H. Augsburg, R. Jud, and S. Ohlerth. 2011. Computed tomography of the abdomen in Saanen goats: I. Reticulum, rumen and omasum. *Schweiz. Arch. Tierheilkd.* 153:307–313. <https://doi.org/10.1024/0036-7281/a000210>.
- Braun, U., C. Schnetzler, S. Ohlerth, L. Hatz, and H. Augsburg. 2014. Computed tomography of the abdomen of calves during the first 105 days of life: I. Reticulum, rumen, omasum and abomasum. *Schweiz. Arch. Tierheilkd.* 156:217–225. <https://doi.org/10.1024/0036-7281/a000581>.
- Dann, H. M., G. A. Varga, and D. E. Putnam. 1999. Improving energy supply to late gestation and early postpartum dairy cows. *J. Dairy Sci.* 82:1765–1778. [https://doi.org/10.3168/jds.S0022-0302\(99\)75407-X](https://doi.org/10.3168/jds.S0022-0302(99)75407-X).
- Dønnem, I., M. Eknæs, and Å. T. Randby. 2011. Energy status, measured by computer tomography (CT)-scanning, and milk quality of dairy goats fed rations with various energy concentrations. *Livest. Sci.* 142:235–244. <https://doi.org/10.1016/j.livsci.2011.07.018>.
- Eknæs, M., Y. Chilliard, K. Hove, R. A. Inglingstad, L. Bernard, and H. Volden. 2017. Feeding of palm oil fatty acids or rapeseed oil throughout lactation: Effects on energy status, body composition, and milk production in Norwegian dairy goats. *J. Dairy Sci.* 100:7588–7601. <https://doi.org/10.3168/jds.2017-12768>.
- Goopy, J. P., A. Donaldson, R. Hegarty, P. E. Vercoe, F. Haynes, M. Barnett, and V. H. Oddy. 2014. Low-methane yield sheep have smaller rumens and shorter rumen retention time. *Br. J. Nutr.* 111:578–585. <https://doi.org/10.1017/S0007114513002936>.
- Lambe, N. R., A. McLaren, K. McLean, J. Gordon, and J. Conington. 2022. Variation in reticulo-rumen volumes between and within sheep breeds and genetic relationships with production traits. *Anim. Prod. Sci.* 62:610–621. <https://doi.org/10.1071/AN21423>.
- Lambe, N. R., A. McLaren, K. A. McLean, J. Gordon, and J. Conington. 2023. Effects of sire and diet on rumen volume and relationships with feed efficiency. Page 1034 in Proc. 74th Annual meeting of the European Federation of Animal Science (EAAP). Wageningen Academic Publishers, Lyon, France.
- Legland, D., I. Arganda-Carreras, and P. Andrey. 2016. Morpholibj: Integrated library and plugins for mathematical morphology with ImageJ. *Bioinformatics* 32:3532–3534. <https://doi.org/10.1093/bioinformatics/btw413>.
- Lerch, S., A. De La Torre, C. Huau, M. Monziols, C. Xavier, L. Louis, Y. Le Cozler, P. Faverdin, P. Lambert, I. Chery, D. Heimo, C. Loncke, P. Schmidely, and J. A. A. Pires. 2021. Estimation of dairy goat body composition: A direct calibration and comparison of eight methods. *Methods* 186:68–78. <https://doi.org/10.1016/j.ymeth.2020.06.014>.
- Reynolds, C. K., B. Dürst, B. Lupoli, D. J. Humphries, and D. E. Beever. 2004. Visceral tissue mass and rumen volume in dairy cows during the transition from late gestation to early lactation. *J. Dairy Sci.* 87:961–971. [https://doi.org/10.3168/jds.S0022-0302\(04\)73240-3](https://doi.org/10.3168/jds.S0022-0302(04)73240-3).
- Scholz, A. M., L. Bünger, J. Kongsro, U. Baulain, and A. D. Mitchell. 2015. Non-invasive methods for the determination of body and carcass composition in livestock: Dual-energy X-ray absorptiometry, computed tomography, magnetic resonance imaging and ultrasound: Invited review. *Animal* 9:1250–1264. <https://doi.org/10.1017/S1751731115000336>.
- Top, A., G. Hamarneh, and R. Abugharbieh. 2011. Spotlight: Automated confidence-based user guidance for increasing efficiency in interactive 3D image segmentation. Pages 204–213 in Proc. Medical Computer Vision. Recognition Techniques and Applications in Medical Imaging. Springer, Berlin, Germany.
- Waite, S. J., J. Zhang, J. E. Cater, G. C. Waghorn, W. E. Bain, J. C. McEwan, and V. Suresh. 2019. Development of an in situ procedure to evaluate the reticulo-rumen morphology of sheep selected for divergent methane emissions. *Animal* 13:542–548. <https://doi.org/10.1017/S1751731118001854>.

## Notes

J. A. A. Pires  <https://orcid.org/0000-0002-3773-9293>

S. Lerch  <https://orcid.org/0000-0003-0957-8012>

This research was funded in part by the Department of Animal Physiology and Livestock Production Systems (PHASE) of INRAE (Paris, France).

The authors thank A. Eveno, J. Y. Thébault, A. Chauvin, M. Texier-Quenouillère, and the team of the “Installation Expérimentale en Production du Lait” of the UMR (INRAE, Méjusséaume, France) for animal care; and J. Liger, J. F. Rouaud, and M. Alix of the Pig Physiology and Phenotyping Experimental Facility (INRAE, 2018, <https://doi.org/10.15454/1.5573932732039927E12>) for slaughter procedures.

All procedures performed on animals were approved by the Ethics Committee on Animal Experimentation and the French Ministry of Higher Education, Research and Innovation (APAFiS#15681–2018062622272488\_v2).

The authors have not stated any conflicts of interest.

**Nonstandard abbreviations used:** CT = computed tomography; HU = Hounsfield units; rCV = residual coefficient of variation; rSD = residual standard deviation.