

Original Article

Skin flap complications after decompressive craniectomy and cranioplasty: Proposal of classification and treatment options

Alessandro Di Rienzo, Pier Paol Pangrazi¹, Michele Riccio¹, Roberto Colasanti, Ilaria Ghetti, Maurizio IacoangeliDepartment of Neurosurgery, Polytechnic University, ¹Department of Plastic and Reconstructive Surgery, Operative Unit of Hand Surgery and Microsurgery, Polytechnic University, Ancona, Marche, ItalyE-mail: *Alessandro Di Rienzo - alessandrodirienzo1@gmail.com; Pier Paol Pangrazi - pierpaolo.pangrazi@ospedaliriuniti.marche.it; Michele Riccio - michele.riccio@ospedaliriuniti.marche.it; Roberto Colasanti - roberto.colasanti@gmail.com; Ilaria Ghetti - ilaria.illa88@hotmail.it; Maurizio Iacoangeli - neurotra@tiscali.it
*Corresponding author

Received: 24 October 15 Accepted: 10 March 16 Published: 09 November 16

Abstract

Background: The list of complications reported after decompressive craniectomy (DC) and cranioplasty is progressively increasing. Nonetheless, the exact incidence of these events is still ill-defined. Problems affecting skin flaps after DC and cranioplasty have never been accurately analyzed in papers and their impact on patients' prognosis is largely underestimated.

Methods: In a 10-year time, we treated by DC 450 patients, 344 of whom underwent cranioplasty, either with autologous bone or artificial implants (hydroxyapatite, polyetheretherketone, titanium, polymethylmethacrylate). Complications involving skin flaps and requiring re-surgery were observed and treated in 38 cases. We classified three main types of lesions: (1) dehiscence, (2) ulcer, and (3) necrosis. In all cases surgical decision making was performed in cooperation with plastic surgeons, to select the best treatment option.

Results: Dehiscence was reported in 28 cases, ulcer in 6, and necrosis in 4. Surgeries included flap re-opening and re-suturing, Z-plasty, rotational, advancement, or free flaps. Treatment complications required further surgical procedures in six patients.

Conclusions: In our experience, complications involving skin flaps after DC and post-DC cranioplasty cannot be considered a minor event because of their potential to further compromise the yet fragile conditions of these patients. Their management is complex and requires a multidisciplinary approach to get the better results.

Key Words: Cranioplasty, decompressive craniectomy, dermal graft, free flap, necrosis, skin flap

Access this article online

Website:www.surgicalneurologyint.com**DOI:**

10.4103/2152-7806.193724

Quick Response Code:

INTRODUCTION

In last years, some reports focused attention on complications occurring after decompressive craniectomy (DC) and postdecompressive cranioplasty.^[3,4,7] The interest for this topic raises from the progressively increasing number of decompressive and reconstructive procedures performed by neurosurgeons in their daily practice, an increase related to the lack of an effective medical

This is an open access article distributed under the terms of the Creative Commons Attribution-NonCommercial-ShareAlike 3.0 License, which allows others to remix, tweak, and build upon the work non-commercially, as long as the author is credited and the new creations are licensed under the identical terms.

For reprints contact: reprints@medknow.com

How to cite this article: Di Rienzo A, Pangrazi PP, Riccio M, Colasanti R, Ghetti I, Iacoangeli M. Skin flap complications after decompressive craniectomy and cranioplasty: Proposal of classification and treatment options. *Surg Neurol Int* 2016;7:5737-45.

<http://surgicalneurologyint.com/Skin-flap-complications-after-decompressive-craniectomy-and-cranioplasty:-Proposal-of-classification-and-treatment-options/>

treatment for “malignant” intracranial hypertension. Initially suggested for severe head trauma (HT), indications to DC have been extended to a larger spectrum of lesions, including brain ischemia, spontaneous supratentorial intracerebral hemorrhage (ICH), subarachnoid hemorrhage (SAH), malignant brain edema from intrinsic brain tumors, massive intratumoral bleeding, and meningoencephalitis.^[1,8]

Despite completed and ongoing trials, until now the only certainty about DC relies on its capacity of restoring normal levels of intracranial pressure (ICP), which, according to detractors, seems to result in an enhanced survival with no improvement of prognosis. With the increasing experience, the list of complications affecting patients undergoing DC and post-DC cranioplasty is growing up.^[5] Either frequent adverse events (infection, hydrocephalus, cerebrospinal fluid [CSF] leak, bone resorption, epidural hematoma, subdural hematoma, and brain contusions) and rare ones (paradoxical brain herniation and sinking flap syndrome) have been reported.^[2,4,6] Even though in most cases their etiopathogenesis is quite indisputable, some conditions are still far away from finding a plain explanation. This may be troublesome when considering that complications, especially those furtively occurring like hydrocephalus, play a crucial role in DC patients’ prognosis, potentially leading to sudden clinical deterioration and death even in yet improving subjects. Finally, even the few available papers giving an esteem of the incidence of specific complications, do not give any clue about eventual strategies needed to minimize or prevent their occurrence.

Starting from the above considerations, the small interest for troubles affecting skin flaps overlying decompressed brains comes as no surprise. Neurosurgeons’ expertise in this field may be considered, at least, “inadequate.” Moreover, traditional beliefs, including the idea that when a cranioplasty gets exposed, it must absolutely be removed, should be re-discussed, in light of the large availability of powerful antibiotics, the improvement of surgical techniques and the introduction of preformed implants realized in re-sterilizable materials. Here, we present our 10-year experience in this field, result of a continuous side-to-side collaboration with plastic surgeons. Relying on the complete lack of information which could be gathered from the literature, we tried to propose a scheme of classification of the observed lesions, aimed to select the best treatment options according to specific situations, to improve results and minimize patients’ risks of further surgeries.

MATERIALS AND METHODS

In a 10-year time, from January 2001 to December 2011, 450 DCs were performed at our institution for various etiologies. Two hundred and thirty-five patients underwent decompression because of severe HT, 110 for ICH,

67 for SAH, 14 for hemorrhagic tumors, 11 for massive ischemic brain damage, 9 for meningoencephalitis, 4 for brain abscesses, 5 for bleeding inside arteriovenous malformations, and 5 for brain swelling in malignant brain tumors. Unilateral hemicraniectomy was performed in 362 patients, bifrontal craniectomy in 79, and bilateral hemicraniectomy in 9. Cranioplasty was performed in 344 patients. Autologous bone (AB) was repositioned in 307 cases; artificial implants were used in 37 cases because of AB unavailability (comminuted bone fracture, bone exposure, and bone infection). Polymethylmethacrylate (PMMA), titanium meshes, three-dimensional modeled titanium, and polyetheretherketone (PEEK).

Medium time interval from craniectomy to cranioplasty was 67 days, the shortest time being 27 days, and the longest 158 days. Complications affecting skin flaps were recorded in 38 patients. Standard protocol in all cases included:

- a. Preoperative laboratory examinations: Complete blood count, erythrocyte sedimentation rate, C-reactive protein, and renal and liver function
- b. Preoperative computed tomography (CT) scan without and with contrast enhancement, to disclose the presence of subcutaneous, epidural, or intradural (subdural and intraparenchymal) purulent collections, ependymitis, signs of bone, or cranioplasty involvement after reconstruction (osteomyelitis, erosion, and contrast enhancement)
- c. 48 h postoperative CT scan.

Antibiotic treatment was distinguished in prophylactic and therapeutic. Prophylaxis (ceftriaxone 1 g 2 h preoperatively, then 6 h after surgery) was used in all cases where no signs of infection could be clearly preoperatively evidenced at the laboratory or instrumental examinations.

Large spectrum therapy (meropenem 1 g 3 times a day, teicoplanin 400 mg as starting dose, then 200 mg two times a day) was started in the immediately postoperative period in cases of inflammatory indexes positivity, clinical evidence of purulent collections, autologous/artificial cranioplasty involvement at neuroradiological examinations, to allow intraoperative sampling for identification of the causative agent. Treatment modifications were decided on the following positivity. Targeted therapy was preoperatively started in the two only patients affected by multiresistant bacteria (*Acinetobacter baumannii*, *Pseudomonas aeruginosa*) and prolonged for at least 2 weeks after surgery. On the basis of their appearance, skin flap lesions were classified into three main types, according to a simplified scheme:

1. Dehiscence: Defined as a diastase of facing flap borders occurring along the line of suture, with different degrees of exposure of underlying tissues: 28 cases [Figure 1a]
2. Ulcer: Defined as a loss of substance occurring inside the skin flap, usually distant from the line of

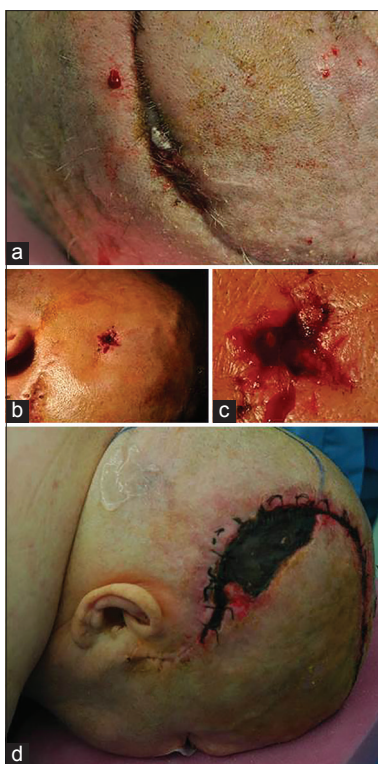

Figure 1: Three different kinds of flap lesions may be observed in patients undergoing decompressive craniectomy or postdecompressive cranioplasty, flap dehiscence, flap ulceration, and flap necrosis. (a) Dehiscence occurring along a left fronto-temporo-parietal decompressive craniectomy. (b) Ulceration occurring in the middle of a left fronto-temporo-parietal flap. (c) In detail, bone is clearly visible under the ulcer. (d) Large necrosis in the temporo-parietal area of a left hemispheric flap

suture, constantly presenting with underlying tissues exposure: 6 cases [Figure 1b and c]

3. Necrosis: Defined as a large, discolored area of complete loss of skin viability, both on flap contour and on the surrounding skin border, never associated to the exposure of subjacent tissues, always occurring after cranioplasty in unilateral craniectomy, preferentially on the temporo-parietal region: 4 cases [Figure 1c and d].

RESULTS

Dehiscence occurred after DC procedures in 17 cases [Table 1]. It presented 2–6 weeks after stitches removal. Relying on lesion dimensions and the degree of exposure of underlying tissues, treatment was performed either by a limited or a full flap re-opening. The appearance of dehiscence was attributed to CSF leak in 5 cases, early resurgery for short-term postoperative complications in 3, extreme flap tension due to malignant swelling in 6, and bed sores in 3. An external CSF drainage (ventricular: 5; lumbar: 3) was used in eight cases, to treat leaks and/or to relieve pressure on flap borders. Wound borders curettage with excision of lesioned skin and resuture was

successfully performed in eight patients. In both the cases of decompression for meningoencephalitis intradural toilette was needed, followed by autologous duraplasty by fascia lata/pericranium and resuture [Figure 2]. Patients with massive postoperative brain swelling developing dehiscence were usually treated in the first instance by daily bandaging with iodine gauzes; within 2 weeks flap tension was relieved and resuturing could take place. This solution failed in two cases, requiring resurgery by an advancement flap in one case and dural re-opening followed by removal of a large portion of necrotic temporal lobe tissue (brain infarction), fascia lata duraplasty, and borders resuture in the second.

Dehiscence was also observed after AB cranioplasty (five patients), PMMA (two patients), hydroxyapatite (two patients), and preformed titanium (two patients) [Table 1]. Its development was attributed to early resurgery in two cases, flap retraction in three, multiple surgeries in three, and retraction in three. Borders toilette and resuture were successful in three patients, unsuccessful in three, leading to cranioplasty removal and new cranioplasty at 6 months. An advancement flap was performed in three cases, a free flap from the right radial forearm [Figure 3] in one, and Z-plasty in two. The development of an ulcer inside a decompressive or postcranioplasty flap is a severe and challenging condition. In our series, six patients were affected by such kind of lesion [Table 2]. Five patients had been previously treated by cranioplasty with AB and one by PMMA. Depending on the site of tissue loss, an advancement flap supplemented with a free thigh dermal graft was considered the best treatment option in four cases, Z-plasty in one, and free flap in one. Advancement flap failed in two cases, requiring free flaps from the radial forearm and the great dorsal muscle. The most complex case required four surgeries to accomplish full healing, including removal of AB and intraoperative re-sterilization of a preformed titanium cranioplasty getting exposed because of relapsing infection [Figures 4 and 5]. In our series, flap necrosis was observed in only four cases [Table 3]. It developed within the first 24 h from cranioplasty in three patients, after 72 h in one. Treatment consisted of an advancement flaps and free dermal grafts from radial forearm or thigh within 48 h from lesion appearance, supplemented by large spectrum antibiotic coverage. In three cases flap healing and graft epithelization was complete in 15–18 days, with no further complications at 1, 3, and 6 months follow-up. A subcutaneous hematoma developed 4 days after surgery in the fourth patient and required emergency evacuation [Figure 6]. Wound healing was complete 15 days after revision. One patient came back to our attention 3 months after discharge because of flap dehiscence in the frontal area and underlying bone exposure. Purulent material ran out of the flap, and at CT scan minimal dural enhancement was discovered at CT scan. At re-surgery, the repositioned bone was found eroded

Table 1: Dehiscence

Sex	Age	Surgery for	Type of craniectomy	Dehiscence etiology	CSF drainage	Cranioplasty	Lesion location	Treatment	Number of surgeries
Male	50	SAH	Left F-T-P	CSF leak	EVD	//	P	Curettage + resuture	1
Male	79	ICH	Left F-T-P	CSF leak	EVD	//	F	Curettage + resuture	1
Male	32	HT	Left F-T	CSF leak	ELD	//	T	Curettage + resuture	1
Male	46	HT	Right T-P	CSF leak	ELD	//	T	Curettage + resuture	1
Female	64	SAH	Right F-T	CSF leak	EVD	//	F	Curettage + resuture	1
Female	63	HT	Left F-T-P	Early resurg	//	//	T	Curettage + resuture	1
Male	71	HT	Right F-T-P	Early resurg	//	//	T	Curettage + resuture	1
Female	65	ICH	Right F-T-P	Early resurg	//	//	T-P	Curettage + resuture	
Female	64	ICH	Left T-P-O	Brain abscess	EVD	//	F-T	Abscess toilette + duraplasty + resuture	1
Male	51	HT	Left F-T-P	Brain abscess + ventriculitis	EVD	//	T-P	Abscess toilette + duraplasty + resuture	1
Male	59	HT	Right F-T-P	Brain swelling	ELD	//	T	Bandaging resuture in 2 week	1
Male	65	SAH	Right T-P-O	Brain swelling	//	//	O	Bandaging (failed) flap re-operative + curettage + duraplasty + resuture	1
Male	64	HT	Right F-T-P	Brain swelling	//	//	T-P	Bandaging (failed) After + dermal graft	1
Male	76	ICH	Left F-T-P	Brain swelling	//	//	T-P	Bandaging + resuture in 2 week	1
Female	19	SAH	Left F-T-P	Bed sore	//	//	F	Sore removal + resuture	1
Female	68	SAH	Right F-T-P	Bed sore	//	//	T	Sore removal + resuture	1
Female	65	ICH	Left F-T-P	Bed sore	//	//	T-P	Sore removal + resuture	1
Female	72	ICH	Right F-T-P	Early resurg	//	AB	T-P	Curettage + resuture	1
Male	63	HT	Right F-T-P	Early resurg	//	AB	T	Curettage + resuture	1
Male	51	HT	Left F-T-P	Sinking flap	//	AB	P	Curettage + resuture	1
Male	42	HT	Left F-T-P	Sinking flap	//	AB	F	Advancement flap	1
Female	33	HT	Right F-T-P	Sinking flap	//	AB	F	AB removal PEEK (6 months)	1
Female	81	ICH	Right F-T-P	Multiple surgeries	//	PMMA	F	Flap re-operative + Z-plasty	1
Male	47	HT	Left F-T-P	Multiple surgeries	//	PMMA	P	Cranioplasty removal curettage + resuture HA (6 months)	2
Male	54	HT	Right F-T-P	Sinking flap	//	HA	F	Curettage + resuture (failed) Advancement flap	2
Male	17	M-E bifrontal abscess	Bicoronal	Sinking flap	//	HA	V	Free flap (radial) flap revision (haematoma)	2
Female	16	HT	Left F-T-P	Multiple surgeries	//	3D tit	T-P	Curettage + resuture	1
Male	18	HT	Right F-T-P	Sinking flap	//	3D tit	F-T	Advancement flap	1

F: Frontal, T: Temporal, P: Parietal, O: Occipital, F-T: Fronto-temporal, T-P: Temporo-parietal, P-O: Parieto-occipital, V: Vertex, EVD: External ventricular drainage, ELD: External lumbar drainage, HA: Hydroxyapatite, 3D tit: Three-dimensional titanium, ICH: Intracerebral hemorrhage, SAH: Subarachnoid hemorrhage, HT: Head trauma, M-E: Meningoencephalitis, AB: Autologous bone, PMMA: Polymethylmethacrylate, PEEK: Polyetheretherketone, CSF: Cerebrospinal fluid, //: Not performed

and toilet of the dural layer was needed. Six months after bone removal a preformed PEEK implant was positioned with no further complications.

DISCUSSION

DC effectiveness is still controversive. Though its positive impact on malignant intracranial hypertension unresponsive to maximal medical treatment is well established, there seems not be an equivalent

correlation between patient's survival rate and good outcomes. To further increase confusion, larger series in literature include patients treated by different techniques, bifrontal craniectomy, hemicraniectomy, and bilateral hemicraniectomy. Bifrontal DC is indicated in patients affected by diffuse traumatic brain injury or in cases where bifrontal contusions are causing mass effect and need prompt surgical evacuation. Hemicraniectomy (fronto-temporo-parietal or fronto-temporo-parieto-occipital) is commonly used

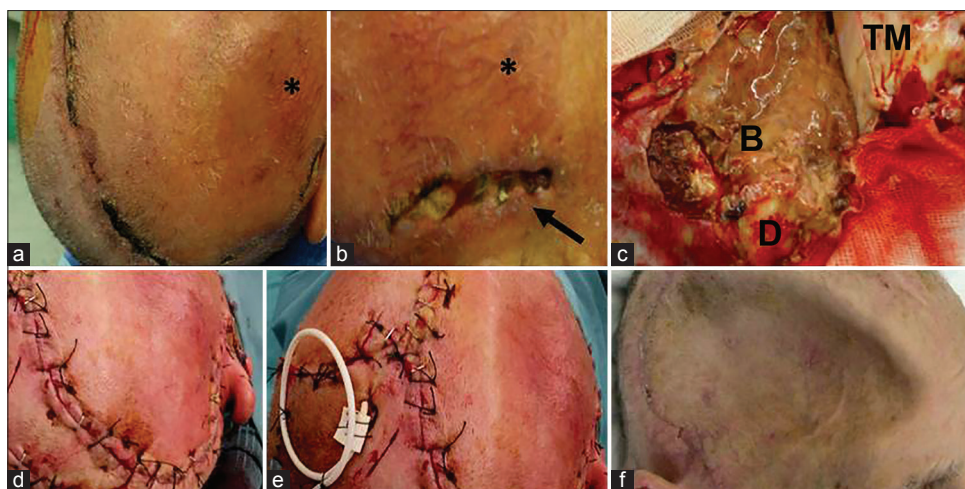


Figure 2: (a and b) 54-year-old male previously treated by the right hemispheric decompressive craniectomy for severe head trauma. Twenty-one days after surgery the flap appeared swollen, showing a reticular pattern of small vessels surrounding the area of dehiscence (black asterisk). A 3 cm long, 1 cm large dehiscence was observed along the temporal line (black arrow). (c) At flap re-opening, after lifting the temporalis muscle (TM), a purulent collection involving the brain was immediately evident (B), with partial resorption of the overlying dural membrane (D). (d) Flap re-suturing was then easily obtained. (e) Intraoperative positioning of a contralateral external ventricular shunt was needed to reduce flap tension allowing uncomplicated re-suturing. (f) One month after revision a sinking flap syndrome developed. Nonetheless, full healing of the skin flap was evident

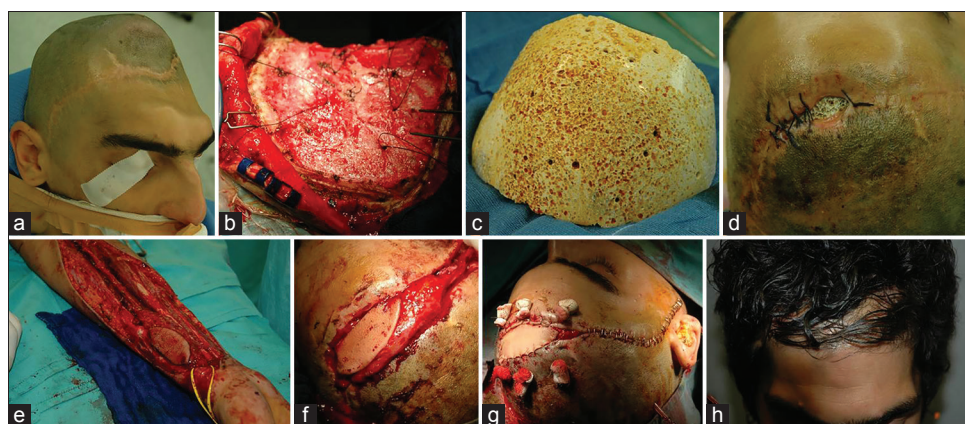


Figure 3: (a) A 21-year-old male undergoing hydroxyapatite cranioplasty after bifrontal decompressive craniectomy for meningoencephalitis. (b and c) Intraoperative images of the flap and the implant. (d) Three weeks after cranioplasty the patient came back to our attention because of a large dehiscence occurring in the middle of the bifrontal flap. (e) A free radial flap from the right forearm was prepared. (f) After performing the anastomosis with the tiro-linguo-facial trunk, the radial flap was positioned over the defect. (g) Final vision after completing flap closure. (h) Four months after surgery full flap healing was observed

Table 2: Ulcer

Sex	Age	Lesion	Type of craniectomy	Ulcer etiology	CSF drainage	Type of cranioplasty	Lesion location	Type of surgery	Number of surgeries
Female	67	ICH	Right F-T-P	Infection	//	AB	F-T	Advancement flap	1
Male	38	HT	Left F-T-P	Infection	//	AB	F-T	Advancement flap	1
Male	72	HT	Right F-T-P	Infection	//	AB	F-T	Advancement flap (failed) Advancement flap (failed) Free flap (great dorsal)	3
Male	49	HT	Bicoronal	Infection	//	AB	F	Free flap (great dorsal)	1
Female	56	HT	Right F-T-P	Infection	//	AB	P	Advancement flap (failed) AB removal titanium cranioplasty + rotation flap (failed) Free flap (radial)	4
Female	71	ICH	Right F-T-P	Infection	//	PMMA	F	Z-plasty	1

F: Frontal, T: Temporal, P: Parietal, O: Occipital, F-T: Fronto-temporal, ICH: Intracerebral hemorrhage, HT: Head trauma, AB: Autologous bone, PMMA: Polymethylmethacrylate, CSF: Cerebrospinal fluid, //: Not performed

Table 3: Necrosis

Sex	Age	Lesion	Type of craniectomy	Necrosis etiology	CSF drainage	Cranioplasty	Lesion location	Type of surgery	Number of surgeries
Female	72	ICH	Right F-T-P	Arterial support sacrifice	//	AB	T-P	Rotation flap + dermal graft	1
Male	73	ICH	Left F-T-P	Arterial support sacrifice	//	AB	T-P	Rotation flap + dermal graft	1
Male	67	ICH	Right F-T-P	Arterial support sacrifice	//	AB	F-T	Rotation flap + dermal graft	1
Male	69	HT	Left F-T-P-O	Venous congestion	//	AB	0	Rotation flap + dermal graft Flap haematoma and revision	2

F: Frontal, T: Temporal, P: Parietal, O: Occipital, F-T: Fronto-temporal, ICH: Intracerebral hemorrhage, HT: Head trauma, AB: Autologous bone, T-P: Temporo-parietal, CSF: Cerebrospinal fluid, //: Not performed

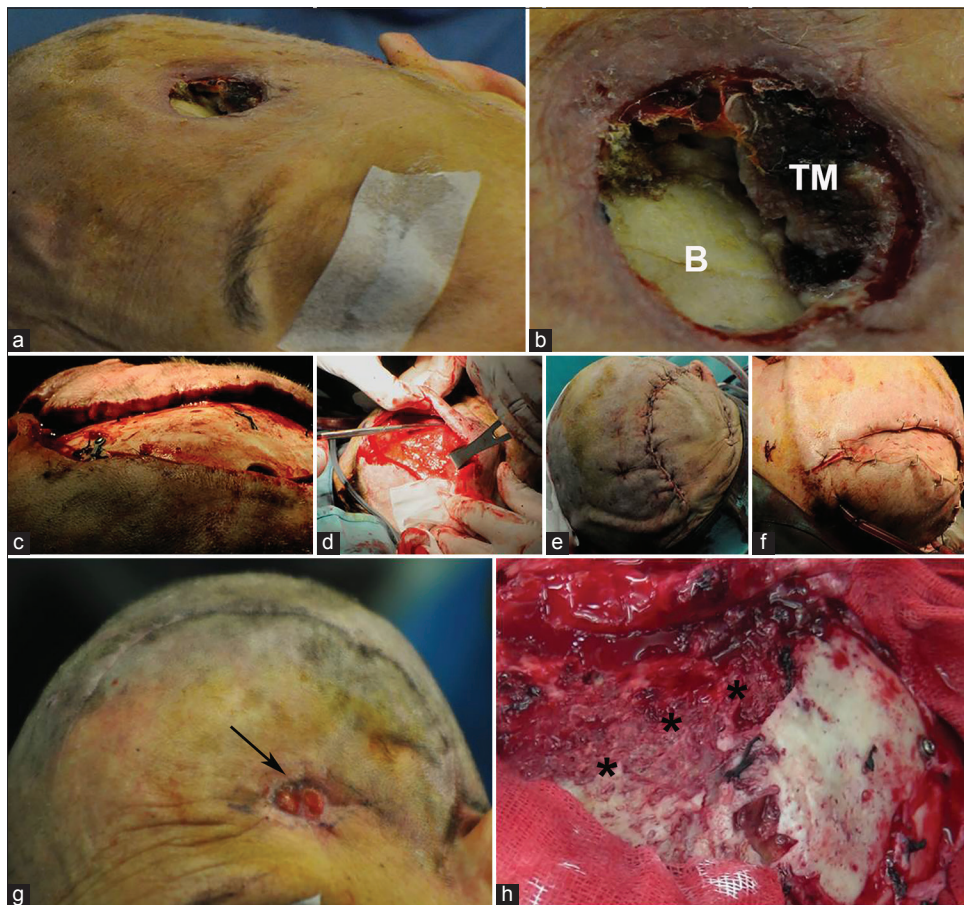


Figure 4: (a) Ulceration occurring over the left pterional region 3 months after fronto-temporo-parietal cranioplasty for severe head trauma. (b) Particular of the area of ulceration with fully exposed underlying bone and incomplete necrosis of the temporalis muscle (**B**: Bone, **TM**: Temporalis muscle). (c) After fronto-temporo-parietal flap re-opening, bone appeared well-preserved. (d) Preparation of a parieto-occipital advancement flap. (e) Full defect coverage after removal of damaged skin tissue. (f) Detail of the dermal graft needed to close the parietal defect remaining after flap advancement. (g) Three months after flap advancement, relapse of pterional ulcer (black arrow). (h) At flap re-opening evidence of diffuse bone erosion (asterisks), leading to bone removal

in patients harboring unilateral mass lesions (ICH, acute subdural hematoma, and contusions) causing contralateral midline displacement or intracerebral herniations. The use of bilateral DC is infrequent, only occasionally reported and reserved to patients presenting lesions with mass effect evolving at different stages.

Complications occurring after DC and cranioplasty

have been described quite recently in a small number of papers.^[1,3,4] The list of postdecompressive adverse events has grown with time and includes either frequently occurring phenomena, like subdural hygromas, hydrocephalus, epidural hematomas, brain lacerations, subdural hematomas, malignant brain swelling, and rarer conditions, like paradoxical brain herniation and sinking flap syndrome.^[3,8] In some of the above-mentioned

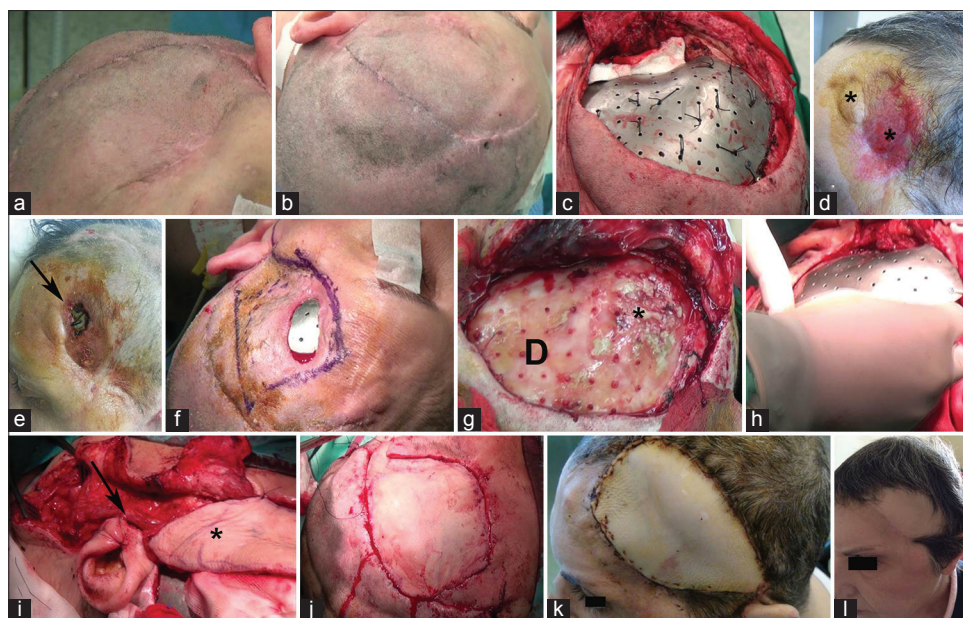


Figure 5: (a and b) Evidence of complete flap healing pretitanium cranioplasty. (c) Final aspect after titanium implant positioning. (d) Flap appearance 3 months after titanium cranioplasty. Even though still intact, a large area of the frontal skin appears thinner and introflexed (asterisks). (e) Two weeks after cranioplasty, the titanium implant got exposed (black arrow). (f) Immediately preoperative planning of skin area needing removal. (g) After cranioplasty removal, the dural layer (D) underwent an accurate curettage, especially over the frontal region, where some flogistic material (asterisk) was observed. No positivity for bacterial or fungine infection resulted from microbiological studies in the following postoperative course. (h) Cranioplasty repositioning after intraoperative sterilization. (i) After vessels anastomosis had been completed, the radial flap (asterisk) was ready to be sutured (black arrow: Site of arterial anastomosis). (j) Radial flap fully covered the defect. All of the damaged skin had been removed. (k and l) Postoperative images 3 weeks and 1 year after surgery, showing full healing

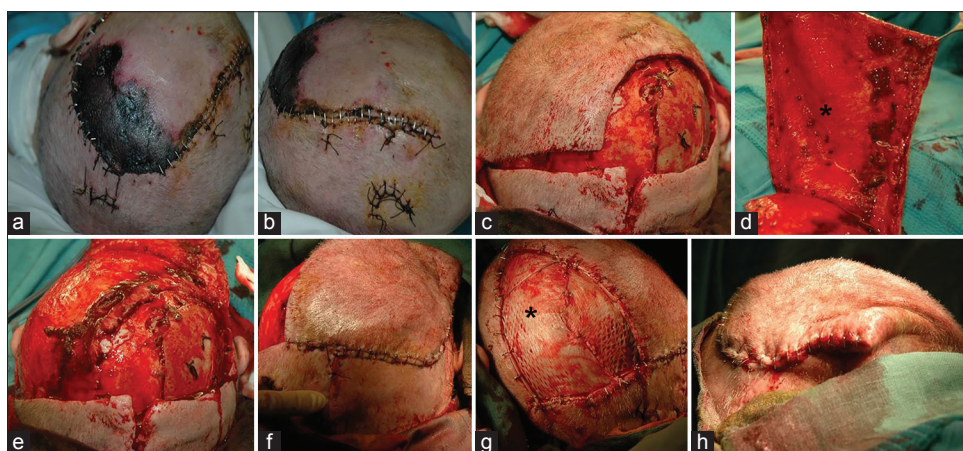


Figure 6: (a and b) A large area of necrosis developed along the temporo-parietal border of a left fronto-temporo-parietal flap 2 days after autologous cranioplasty. (c) A large area of skin flap including the necrotic tissue was removed. (d) Elevation of a parieto-occipital flap (asterisk) to cover the defect. (e) Scalp area exposed after flap elevation. (f) Flap rotation and suture over the previous area of necrosis. (g) Dermal autograft from thigh (asterisk). (h) After flap closure, a small amount of exceeding skin is observed above the ear

papers, authors also include complications taking place at the moment of postdecompressive cranioplasty, including infection, bone resorption, epidural hematomas, and bone flap displacement.^[2,5,6] The exact incidence of these complications has not been established yet and even their etiopathogenesis is sometimes hard to explain, as it happens for the sinking flap syndrome. Nonetheless, all authors agree that such complications are always a serious event and that, if underestimated, they may have a significant negative impact on patient's prognosis, leading

to further neurological deterioration (even in improving patients), and eventually to death. Wound complications have been only occasionally mentioned in literature, no paper focusing attention on this topic. It was exactly this consideration, the real lack of information on such a problem when facing the management of the first cases in our series that made us aware of the need to develop a patients' database, distinguishing the different lesions, and adopting treatment schemes according not only to the lesion itself but also to patients conditions. Actually,

clinical conditions of craniectomized patients are rarely optimal, which means that timing of major surgeries like free flaps or rotation flaps (implying a potential for major blood loss) must be accurately selected. Nonetheless, apparently minor impact procedures, like a revision of flap borders, positioning of external shunts to accelerate flap detension and healing, can be followed by complications too, especially in patients known to harbor infections from multidrug-resistant bacteria. In our experience, especially in these cases, flap healing is one of the most important elements contributing to outcome.

As summarized above, we tried to highlight the etiology of flap lesions case by case. For what is concerning to dehiscences, we observed two leading causes of flap failure after decompression: CSF circulation disturbances and malignant postdecompressive brain swelling. On the counterpart, dehiscences followed cranioplasty essentially because of poor preoperative flap conditions (sinking and multiple surgeries). Ulcers always came associated with an underlying infection of AB or cranioplasty and were never observed in craniectomized patients. In our series, necrosis was ascribed to inadvertent sacrifice of the residual arterial supply after flap reopening in three cases, to venous congestion in 1.

Even if in our experience we were able to find a direct correlation between flap incision and wound complications only in necrosis, some basic principles should be always kept in mind when performing DC. Flap shape needs to be tailored to patient's anatomy, especially in cases where vascularization may be already compromised (previous surgery on the same side of decompression, scars, irregular scalp lesions as in trauma). ICP monitors must be strategically placed. If put on the same side which could need decompression, it should ideally be placed along the theoretical flap course (frontal region, 2–3 cm lateral to the midline), rather than inside it. In cases where decompression might be required but it is not certain, it is definitely better to raise a larger flap, to avoid last minute transverse incisions, which almost inevitably lead to healing difficulties and increase the risk of breakdown at re-opening. In hemicraniectomy, flap does not need to go beyond the midline, but if a very low frontal access is required (e.g., to access fronto-basal contusions), it is better to shape a curve following the contralateral hairline than cutting a straight line going through the forehead that would presumably compromise the support from supratrochlear and supraorbital arteries. Even if time spending, isolation, and preservation of the superficial temporal artery and the surrounding veins should always be sought, It requires just a few more minutes but reduces significantly the risks of compromise of flap circulation and it is especially valuable in bifrontal DC. To this aim, when starting incision at tragus, there is no need to overrun the zygomatic arch and monopolar coagulation is to be avoided. In patients undergoing

hemicraniectomy, the temporal incision should be done 2 cm above the ear, then follow a curve line along the temporal contour at the same level. Because of the poor local vascularization, going below and behind the ear limits the possibility of mobilizing the skin and increases the risks of flap failure. The same exposure of the temporal bone can be obtained with a higher incision and then by retracting the skin by hooks or stitches. The recommended posterior extension of unilateral decompressive flaps is 2–3 cm behind the ear, but to expose enough bone it should be not <5. However, care is not needed to compromise the vascular support from the occipital artery and the posterior midline should not be reached by the incision unless the lesion to treat resides in that area.

Finally, in bifrontal flaps, the coronal portion of incision should preferably follow the coronaric suture or go 2–3 cm behind it.

Coming back to the literature, we would say complications affecting skin flaps after decompression or cranioplasty seem to occupy no space in major authors' experience, especially in larger series, where we expected the most to find some information. In the work of Honeybul and Ho, no cutaneous problems affecting decompressive flaps were mentioned.^[4] In both papers of Gooch *et al.* and Ban *et al.*, wound complications were not cited at all.^[1,3] In Walcott *et al.* paper, complications of wound healing were reported in four patients out of 57, but there was no complication description neither detail about its treatment.^[8] In the series of Schuss *et al.*, wound complications occurred in 9 patients out of 40, but even in this paper, no description of lesion type and treatment modality was given.^[6] In the work of Sobani *et al.*, three cases of superficial wound infections were reported without any mention of treatment.^[7] Why is that? Were these patients treated by other specialists? We feel that this is one of the most important points to highlight. The experience with flap complications in this peculiar group of patients was increased by the constant cooperation and case by case discussion with plastic surgeons, leading to the development of new strategies aimed at reducing the incidence of adverse events, including minimization of the use of skin clamps (we prefer hydrogen peroxide soaked gauzed wrapped along flap borders) and bipolar coagulation and no use of monopolar coagulation. We also use to relieve periodically pressure on the retracted flap during both the decompressive and reconstructive procedure, to protect flap microcirculation. Finally, we have increased the use of subcutaneous suture, minimizing skin stitches. Further observations will be needed to prove the real effectiveness of these measures. As a final consideration, it is necessary to say we feel that the classification for skin flap lesions we propose is an oversimplification and further work and an increased number of observations

will be needed to improve it. Nonetheless, it seemed to fit well all of the patients treated, helping to discriminate if re-surgery was mandatory, if it could be performed by the neurosurgeon alone or needed cooperation with a plastic surgeon, and well balancing the relationship between reoperation risks and benefits. Relying on the different presentation of the classified lesions, the proposed treatment seems to be effective in most of the cases. Dehiscences are presumed to be the easier problem we can deal with. This is a true statement if they are promptly observed and treated. Unfortunately, patients can develop dehiscences in a variable amount of time from surgery, so they can come to the attention of the neurosurgeon when they are yet complicated. On the other side, ulcers are a really challenging problem. In these patients, “closing the skin” is rarely the main problem. The decision whether or not to remove an AB getting exposed after the overlying skin flap becomes dehiscent may be troubleshooting, becoming even more difficult if a cranial prosthesis is involved. We take this decision only after an accurate case examination in cooperation with plastic surgeons. We always have to keep in mind that cranioplasty removal might expose even patients in good clinical conditions to sudden or further deterioration so that an accurate evaluation of the least possible harm should always be performed. This is particularly true in patients harboring shunts contralateral to cranioplasty (which is a quite common condition), where the potential for adverse events (subdural hematoma, hygroma, and sinking flap syndrome) related to unopposed deliquoration is extremely high. Moreover, in patients with AB exposure, the possibility of reestablishing a physiological intracranial compartment will be lost forever. Ulcer seems to be strictly associated to infection, and we all have grown with the idea that cranioplasty (either autologous or artificial) infection has to be treated by bone or implant removal until full healing of the surgical field is obtained. In the modern era, the availability of powerful antibiotics and the possibility for new cranioplasty materials to be intraoperatively resterilized have significantly reduced the need for cranioplasty removal, even in the case of synthetic implants. Paradoxically, in our experience, the major risks of surgical failure seemed to be related to exposure of AB, the sparing of which might unpredictably be a total success or a dramatic in success. In our series, flap necrosis was a rare event but also the most feared one because of the potentially related complications, including infection, overlying skin dehiscence, and bone contamination. In such patients, bone is not exposed so it could be spared, but risks of infection are extremely high so that we prefer to adopt a no-delay behavior. Problems of re-surgery are essentially related to the exceedingly short time passed from cranioplasty, to adjunctive intraoperative and immediate

postoperative blood loss and to the need to understand as soon as possible how much of the flap around the necrotic area was still viable, so to decide the extension of dead tissue removal and the dimensions of the graft required to cover the defect. Summarizing, classifying flap complications can be helpful, but treatment needs a thorough discussion case-by-case. As said above, it seems impossible to identify a solution which can perfectly fit every category of wound complication reported. Nonetheless, supported by our experience, we believe that the incidence of these complications may be significantly reduced by using a strategy based on accurate preoperative planning, adoption of intraoperative solutions aimed at the preservation of flap vascularization, accurate wound care in the immediate postdecompressive and postreconstructive period, optimized temporization of cranioplasty, full consideration of previous surgeries, especially where conditions predisposing to higher risk of complication are observed (e.g., sinking flap syndrome).

Declaration of patient consent

The authors certify that they have obtained all appropriate patient consent forms. In the form the patient(s) has/have given his/her/their consent for his/her/their images and other clinical information to be reported in the journal. The patients understand that their names and initials will not be published and due efforts will be made to conceal their identity, but anonymity cannot be guaranteed.

Financial support and sponsorship

Nil.

Conflicts of interest

There are no conflicts of interest.

REFERENCES

- Ban SP, Son YJ, Yang HJ, Chung YS, Lee SH, Han DH. Analysis of complications following decompressive craniectomy for traumatic brain injury. *J Korean Neurosurg Soc* 2010;48:244-50.
- Bobinski L, Koskinen LO, Lindvall P. Complications following cranioplasty using autologous bone or polymethylmethacrylate – Retrospective experience from a single center. *Clin Neurol Neurosurg* 2013;115:1788-91.
- Gooch MR, Gin GE, Kenning TJ, German JW. Complications of cranioplasty following decompressive craniectomy: Analysis of 62 cases. *Neurosurg Focus* 2009;26:E9.
- Honeybul S, Ho KM. Long-term complications of decompressive craniectomy for head injury. *J Neurotrauma* 2011;28:929-35.
- Santana-Cabrera L, Pérez-Acosta G, Rodríguez-Escot C, Lorenzo-Torrent R, Sánchez-Palacios M. Complications of post-injury decompressive craniectomy. *Int J Crit Illn Inj Sci* 2012;2:186-8.
- Schuss P, Vatter H, Marquardt G, Imöhl L, Ulrich CT, Seifert V, et al. Cranioplasty after decompressive craniectomy: The effect of timing on postoperative complications. *J Neurotrauma* 2012;29:1090-5.
- Sobani ZA, Shamim MS, Zafar SN, Qadeer M, Bilal N, Murtaza SG, et al. Cranioplasty after decompressive craniectomy: An institutional audit and analysis of factors related to complications. *Surg Neurol Int* 2011;2:123.
- Walcott BP, Kwon CS, Sheth SA, Fehnel CR, Koffie RM, Asaad WF, et al. Predictors of cranioplasty complications in stroke and trauma patients. *J Neurosurg* 2013;118:757-62.