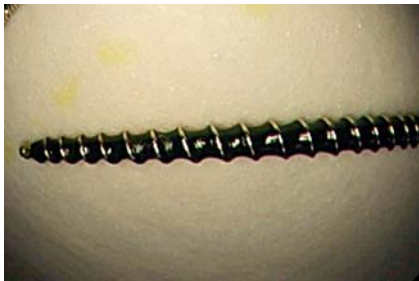

Troubleshooting with a drill dilator for the stent-in-stent technique in malignant hilar biliary obstruction

OPEN
ACCESS

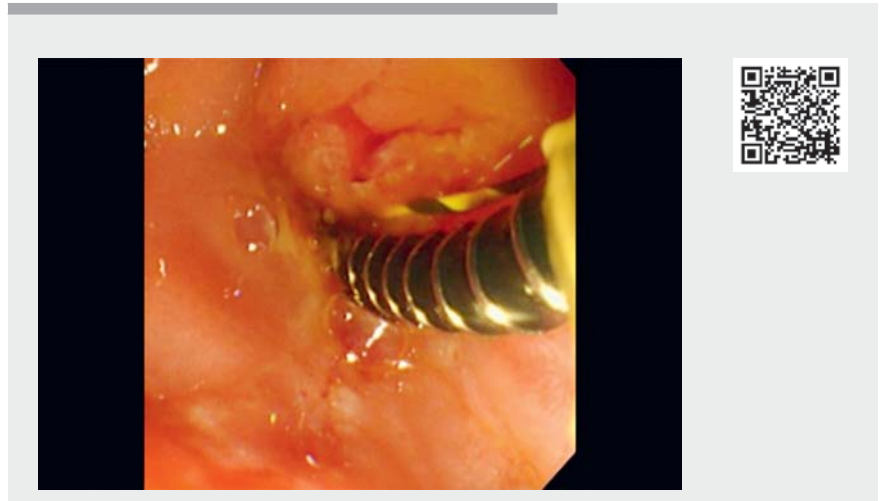


► **Fig. 1** Tornus ES is a drill dilator with hydrophilic coating and a tapered tip, which facilitate advancement through stiff stenoses.

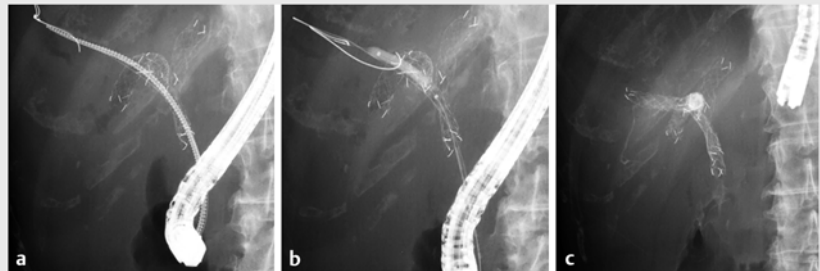
The stent-in-stent (SIS) technique is often used for endoscopic treatment of malignant hilar biliary obstruction and has a high success rate [1]. While the technique allows for placement of three or more stents, passing delivery systems through the mesh of a previously placed self-expandable metal stent (SEMS) can be difficult [1,2]. We report successful troubleshooting with Tornus ES, a drill dilator, during three-way SEMS placement (► **Fig. 1**).

A 71-year-old woman with hilar cholangiocarcinoma presented with fever and jaundice. She had three plastic inside stents placed in the left, right anterior, and right posterior bile ducts 3 weeks prior. Endoscopic retrograde cholangiopancreatography (ERCP) was performed to replace the inside stents with three nasobiliary tubes. After resolution of cholangitis, a second ERCP session was planned to implant three SEMSs using the SIS technique (► **Video 1**).

Uncovered SEMSs were first placed in the left and right posterior bile ducts. While a guidewire could be advanced through the mesh into the right anterior bile duct, an ERCP catheter, a balloon dilator, and a mechanical dilator all failed to pass through the mesh. Insertion of a nasobiliary tube also proved unsuccessful. We therefore decided to use the Tornus ES (Asahi Intec Co., Ltd., Aichi, Japan).



► **Video 1** Through-the-mesh dilation achieved with Tornus ES, a drill dilator, during three-way metallic stent placement using the stent-in-stent technique.



► **Fig. 2 a** Upon reaching the mesh, the assistant turned the drill dilator clockwise, which proceeded through the mesh with no resistance. **b** A balloon dilator could now pass through the mesh, and the mesh was successfully dilated. **c** The delivery system of the uncovered metal stent passed smoothly through the mesh, and three-way metal stent placement using the stent-in-stent technique was successfully completed.

The drill dilator advanced smoothly with clockwise rotation and was removed with similar ease using counterclockwise rotation (► **Fig. 2 a**). The balloon dilator could now pass through the mesh. After balloon dilation, an additional SEMS was successfully deployed into the right anterior bile duct (► **Fig. 2 b, c**).

Tornus ES was developed to dilate difficult strictures, and its use has been reported in pancreatic duct dilation and


in endoscopic ultrasound-guided interventions [3–5]. The spiral design allows for smooth dilation by a simple rotation of the hand grip. The drill dilator may be an attractive option for endoscopic interventions requiring through-the-mesh delivery.

Endoscopy_UCTN_Code_TTT_1AR_2AG

Competing Interest

The authors declare that they have no conflict of interest.

The authors

Manabu Yamada, Takeshi Okamoto  **Naoki Sasahira**

Department of Hepato-Biliary-Pancreatic Medicine, Cancer Institute Hospital of Japanese Foundation for Cancer Research, Tokyo, Japan

Corresponding author

Takeshi Okamoto, MD

Department of Hepato-Biliary-Pancreatic Medicine, Cancer Institute Hospital of Japanese Foundation for Cancer Research, 3-8-31, Ariake Koto-ku, Tokyo, 135-8550, Japan
takeshi.okamoto@jfc.or.jp

References

- [1] Cao Q, Sun L, Li ZQ et al. Bilateral stenting for hilar biliary obstruction: a meta-analysis of side-by-side versus stent-in-stent. *Minim Invasive Ther Allied Technol* 2022; 31: 525–530
- [2] Kaneko J, Yamada T, Fukita K et al. Endoscopic four-branched stent-in-stent deployment of self-expandable metal stents in malignant hilar biliary obstruction. *Endoscopy* 2022; 54: E482–E483. doi:10.1055/a-1638-9183
- [3] Yamada M, Hara K, Haba S et al. Endoscopic ultrasound-guided hepaticogastrostomy using a novel drill dilator. *Endoscopy* 2022. doi:10.1055/a-1838-3682
- [4] Yasuda T, Hara K, Haba S. Dilation of pancreatic duct stenosis using a newly designed drill dilator. *Dig Endosc* 2022; 34: e73–e74
- [5] Hara K, Okuno N, Haba S et al. Utility of a novel drill dilator for easier EUS-guided pancreatic duct drainage. *J Hepatobiliary Pancreat Sci* 2022. doi:10.1002/jhbp.1130

Bibliography

Endoscopy 2023; 55: E189–E190
DOI 10.1055/a-1956-1266
ISSN 0013-726X
published online 11.11.2022
© 2022. The Author(s).

This is an open access article published by Thieme under the terms of the Creative Commons Attribution-NonDerivative-NonCommercial License, permitting copying and reproduction so long as the original work is given appropriate credit. Contents may not be used for commercial purposes, or adapted, remixed, transformed or built upon. (<https://creativecommons.org/licenses/by-nc-nd/4.0/>)

Georg Thieme Verlag KG, Rüdigerstraße 14, 70469 Stuttgart, Germany



ENDOSCOPY E-VIDEOS

<https://eref.thieme.de/e-videos>



Endoscopy E-Videos is an open access online section, reporting on interesting cases and new techniques in gastroenterological endoscopy. All papers include a high quality video and all contributions are freely accessible online. Processing charges apply (currently EUR 375), discounts and waivers acc. to HINARI are available.

This section has its own submission website at <https://mc.manuscriptcentral.com/e-videos>