

# Incessant fascicular ventricular tachycardia in an infant with heart failure

Sudeep Verma<sup>1</sup>, Vejendla Gouthami<sup>1</sup>, Hygriv B. Rao<sup>2</sup>

<sup>1</sup>Department of Paediatric Cardiac Sciences, KIMS Hospital, Secunderabad, Telangana, India, <sup>2</sup>Department of Cardiology and Electrophysiology, KIMS Hospital, Secunderabad, Telangana, India

## ABSTRACT

We report an eight month old infant who presented with incessant Fascicular tachycardia and heart failure which was refractory to drugs and cardioversion. Sinus rhythm was restored by radio frequency ablation and this resulted in improvement in clinical status and cardiac function. Role of catheter ablation in this situation is discussed

**Keywords:** Incessant ventricular tachycardia, radiofrequency ablation, unstable hemodynamics

## INTRODUCTION

Sustained ventricular tachycardia (VT) is rare in infancy. We report a case of incessant drug-refractory fascicular VT in an 8-month-old infant presenting with heart failure and severe left ventricular (LV) systolic dysfunction. Catheter ablation resulted in the termination of VT and reversal of LV function.

## CASE REPORT

An 8-month-old male infant weighing 7.7 kg was referred with the diagnosis of VT and LV dysfunction. The infant presented with a history of poor oral intake and breathing difficulty of 1-week duration. There was no history of fever and no clinical or laboratory evidence of systemic infection. He was treated initially with tablet diltiazem (1 mg/kg/dose eight hourly) and subsequently with amiodarone infusion (up to 15 mcg/kg/min) with no response. At the time of admission to our unit, the heart rate was 200/min, with low-volume pulses and mean blood pressure of 40 mmHg. There were palpable congestive hepatomegaly and LV S3 with a gallop.

Chest X-ray showed a Cardio-Thoracic ratio of 0.65 and pulmonary venous congestion. Echocardiography revealed a severe LV systolic dysfunction (LV ejection fraction [EF]: 30%). Electrocardiography showed a ventricular rate of 200/min, relatively narrow QRS complexes with right bundle branch block (RBBB) morphology, right axis deviation, and Ventriculo-Atrial (V-A) Dissociation suggestive of fascicular VT [Figure 1]. A diagnosis of tachycardiomyopathy due to incessant fascicular VT was made. He was started on inotropic support and diuretics. Electrical cardioversion was tried multiple times with a dose of 2 J/kg without any success. Intravenous verapamil with a dose of 0.1–0.2 mg/kg followed by 5 mcg/kg/min and xylocard were tried without any response. In view of incessant VT unresponsive to drugs and cardioversion, radiofrequency ablation was planned. After taking informed consent from the parents, ablation was successfully performed with no further recurrence of VT. Infant improved symptomatically, and EF normalized after ablation and discharged in a stable condition. The

### Access this article online

Quick Response Code:



Website:

www.annalspc.com

DOI:

10.4103/apc.APC\_82\_19

This is an open access journal, and articles are distributed under the terms of the Creative Commons Attribution-NonCommercial-ShareAlike 4.0 License, which allows others to remix, tweak, and build upon the work non-commercially, as long as appropriate credit is given and the new creations are licensed under the identical terms.

**For reprints contact:** reprints@medknow.com

**How to cite this article:** Verma S, Gouthami V, Rao HB. Incessant fascicular ventricular tachycardia in an infant with heart failure. Ann Pediatr Card 2020;13:153-6.

**Address for correspondence:** Dr. Sudeep Verma, Department of Pediatric Cardiac Sciences, KIMS Hospitals, Secunderabad - 500 003, Telangana, India.

E-mail: drsudeep.verma@gmail.com

Submitted: 09-Jun-2019

Revised: 21-Sep-2019

Accepted: 25-Feb-2020

Published: 13-Apr-2020

child has not had a recurrence at 2 years of follow-up and is off medications.

### Details of ablation procedure

The child was brought into the electrophysiology laboratory in incessant VT, with RBBB morphology, left superior, and relatively narrow QRS with VA dissociation [Figure 1]. The procedure was done under controlled general anesthesia. Vascular access was obtained through the right femoral vein and artery and the right internal jugular vein. Catheters were placed in the coronary sinus, His bundle region and single catheter in right ventricle (RV) & Right atrium (not shown in figure). Heparin bolus of 100u/kg was administered, and activated clotting time (ACT) was maintained consistently over 300 s with repetitive heparin boluses. By retrograde approach, a 5Fr mapping catheter (nonirrigated Biosense Webster) was introduced into the left ventricle [Figure 2]. Careful mapping of the posterior LV septum was done to identify the earliest Purkinje potential (PP). Earliest PP preceded QRS by 40 ms. This area was carefully mapped to identify pre-PP or diastolic potentials [Figure 3]. Concealed entrainment with a postpacing interval-tachycardia cycle length of <10 ms was demonstrated. The delivery of radiofrequency lesion of 55 watts at 55°C, almost immediately terminated tachycardia [Figure 4]. Lesions linearly were delivered both apically and basally. Postablation sinus rhythm was restored. Programmed electrical stimulation with single and double extrastimuli from RV and LV, and burst pacing from RV and LV did not induce tachycardia. The protocol was repeated with

isoprenaline infusion without inducing VT. No further recurrence of VT occurred.

### DISCUSSION

Ventricular arrhythmia causing hemodynamic instability is rare in infantile age and usually secondary to structural and metabolic problems.<sup>[1-3]</sup> Ventricular arrhythmia with structurally normal heart is generally well tolerated and is usually focal, mostly from the RV outflow tract, left ventricular outflow tract/sinus of Valsalva, mitral valve annulus, and tricuspid valve annulus.<sup>[4,5]</sup> Another type of VT occurring in structurally normal heart is fascicular VT due to re-entry at or near fascicle on the left side referred to as idiopathic LV tachycardia (ILVT). Most of the ILVT are verapamil sensitive and this drug can be used safely in infancy for treatment.<sup>[6]</sup> In view of narrow QRS complexes, they are often misdiagnosed as supraventricular tachycardia (SVT), and sometimes, a lack of response to IV adenosine is a clue to the diagnosis. Tachycardia with RBBB, left axis deviation, and relatively narrow QRS complexes (but wider as compared to sinus) is characteristic of ILVT. If present AV dissociation and capture beats also add in differentiating it from SVT. Medical therapy is recommended as the first line of treatment with calcium channel blocker – verapamil being the drug of choice. RF ablation is considered as a class I indication for recurrent or persistent symptomatic tachyarrhythmia, or VT with hemodynamic compromise when medical therapy is either not effective or is associated with intolerable adverse effects or as an alternative to medical therapy.<sup>[1]</sup>

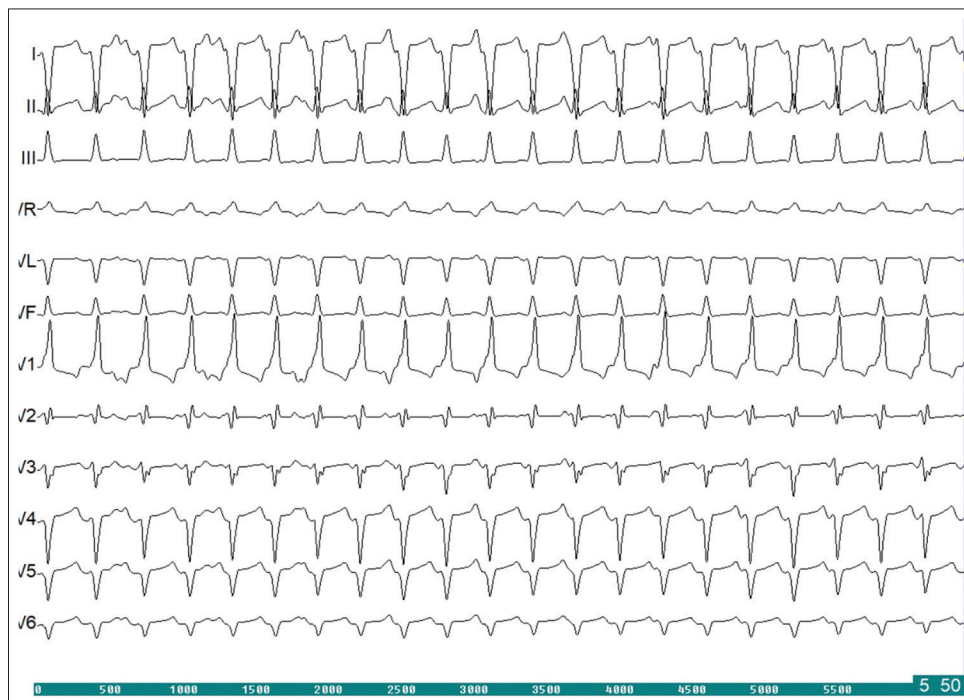


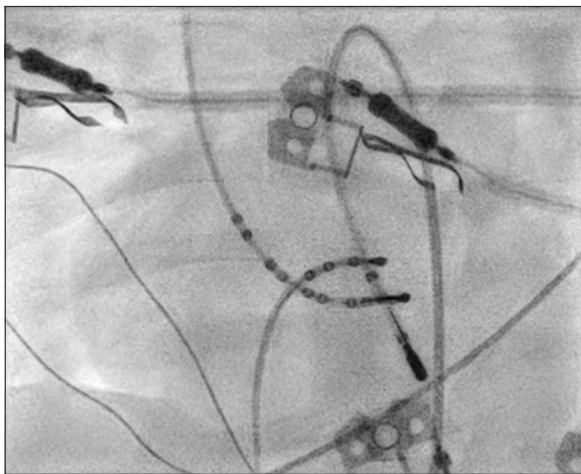
Figure 1: 12 Lead ECG of the patient showing Fascicular VT

However, studies suggested ablation in children should be deferred until the child weighs  $\geq 15$  kg.<sup>[7,8]</sup> However, no difference is observed in the success rate in small children for eliminating arrhythmias in comparison to older children.<sup>[9,10]</sup> It may be partially due to the fact that ablations in smaller children are likely to be attempted by more experienced pediatric electrophysiologists, and experience has been shown to be an important factor in successful radiofrequency ablation (RFA) procedures.<sup>[9]</sup> It is challenging to differentiate tachycardia presenting with ventricular dysfunction (tachycardiomyopathy) from primary dilated cardiomyopathy producing tachycardia.<sup>[10]</sup> This differentiation is crucial as ventricular dysfunction secondary to tachycardia is reversible. The presence of a monomorphic VT

of single morphology with LV dysfunction suggests tachycardiomyopathy.

We were faced with a situation where an infant presented with heart failure and hemodynamically unstable incessant fascicular VT refractory to drugs and cardioversion. Ablation was the only therapeutic option at that stage. Cardiac magnetic resonance imaging would have been a useful tool to exclude myocarditis but was not feasible in view of the clinical situation. We did not use three-dimensional mapping to avoid using large-caliber (8F) sheaths. Mapping and ablation were done with a smaller caliber 5F catheter. This report highlights the feasibility and importance of applying the therapeutic modality of RFA as a life-saving measure even in very young patients with incessant VT.

RFA is not commonly done in infancy in view of the potential response of arrhythmias to medications, difficulty in the availability of appropriate hardware and concern for complications. There are few reports of the use of catheter ablation for VT in infants with good outcomes.<sup>[2,8-10]</sup> To the best of our knowledge, this is the youngest infant in the literature who underwent successful RFA for incessant fascicular VT.



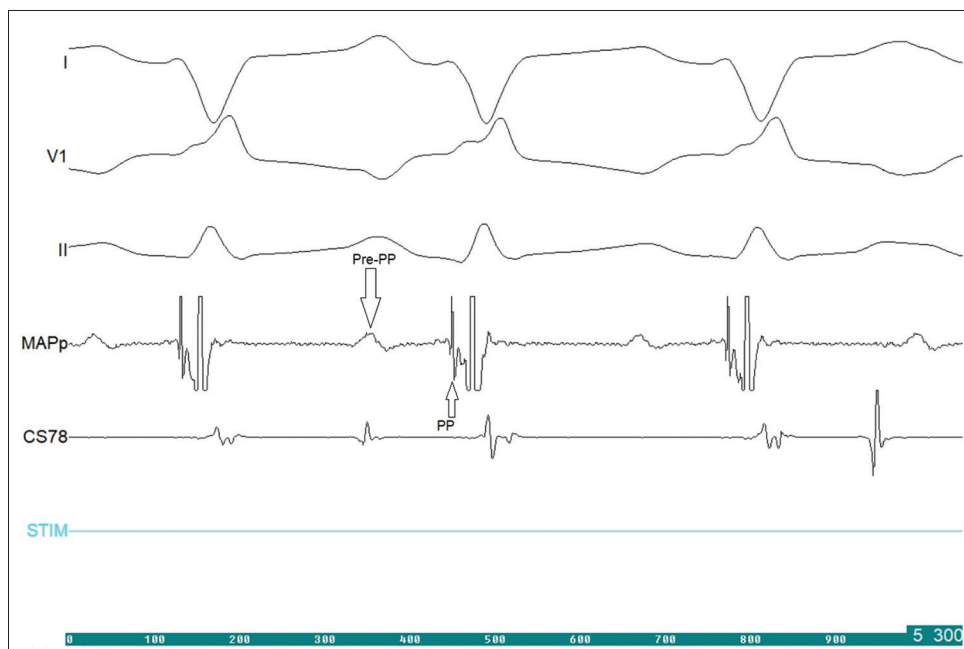
**Figure 2: Fluoroscopy position of catheters in shallow left oblique view (LAO) view**

## CONCLUSION

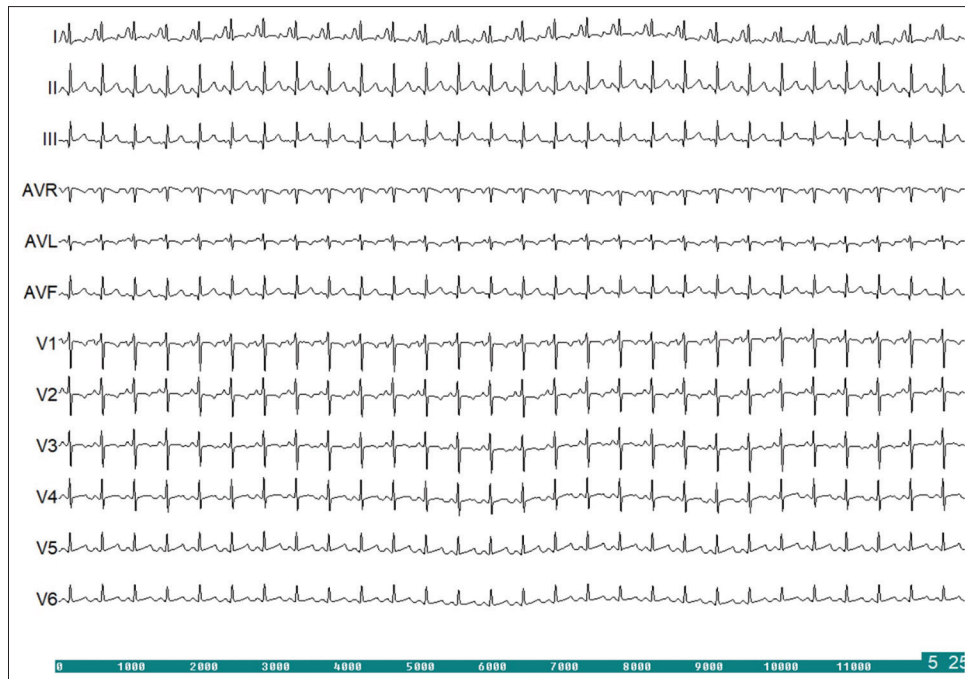
Catheter ablation can be used as a lifesaving procedure in infants with incessant fascicular VT and heart failure.

## Acknowledgment

The authors wish to acknowledge advice of Late Prof. Rajneesh Juneja, Ex Prof. AIIMS, New Delhi, in the management of this patient.



**Figure 3: Electrophysiological Tracing showing Purkinje potentials**



**Figure 4: Sinus Rhythm after Radiofrequency Ablation**

**Declaration of patient consent**

The authors certify that they have obtained all appropriate patient consent forms. In the form the patient(s) has/have given his/her/their consent for his/her/their images and other clinical information to be reported in the journal. The patients understand that their names and initials will not be published and due efforts will be made to conceal their identity, but anonymity cannot be guaranteed.

**Financial support and sponsorship**

Nil.

**Conflicts of interest**

There are no conflicts of interest.

**REFERENCES**

1. Philip Saul J, Kanter RJ, WRITING COMMITTEE, Abrams D, Asirvatham S, Bar-Cohen Y, *et al.* PACES/HRS expert consensus statement on the use of catheter ablation in children and patients with congenital heart disease: Developed in partnership with the pediatric and congenital electrophysiology society (PACES) and the heart rhythm society (HRS). Endorsed by the governing bodies of PACES, HRS, the American academy of pediatrics (AAP), the American heart association (AHA), and the association for European pediatric and congenital cardiology (AEPC). *Heart Rhythm* 2016;13:e251-89.
2. Kohli V, Mangru N, Pearse LA, Cantwell P, Young ML. Radiofrequency ablation of ventricular tachycardia in an infant with cardiac tumors. *Am Heart J* 1996;132:198-200.

3. Paul T, Laohakunakorn P, Long B, Saul JP. Complete elimination of incessant polymorphic ventricular tachycardia in an infant with MIDAS syndrome: Use of endocardial mapping and radiofrequency catheter ablation. *J Cardiovasc Electrophysiol* 2002;13:612-5.
4. Song MK, Baek JS, Kwon BS, Kim GB, Bae EJ, Noh CI, *et al.* Clinical spectrum and prognostic factors of pediatric ventricular tachycardia. *Circ J* 2010;74:1951-8.
5. Crosson JE, Callans DJ, Bradley DJ, Dubin A, Epstein M, Etheridge S, *et al.* PACES/HRS expert consensus statement on the evaluation and management of ventricular arrhythmias in the child with a structurally normal heart. *Heart Rhythm* 2014;11:e55-78.
6. Kehr J, Binfield A, Maxwell F, Hornung T, Skinner JR. Fascicular tachycardia in infancy and the use of verapamil: A case series and literature review. *Arch Dis Child* 2019;104:789-92.
7. Blaufox AD. Catheter ablation of tachyarrhythmias in small children. *Indian Pacing Electrophysiol J* 2005;5:51-62.
8. Erickson CC, Walsh EP, Triedman JK, Saul JP. Efficacy and safety of radiofrequency ablation in infants and young children <18 months of age. *Am J Cardiol* 1994;74:944-7.
9. Aiyagari R, Saarel EV, Etheridge SP, Bradley DJ, Dick M 2<sup>nd</sup>, Fischbach PS. Radiofrequency ablation for supraventricular tachycardia in children and amp; lt; or=15 kg is safe and effective. *Pediatr Cardiol* 2005;26:622-6.
10. de Filippo P. Curative ablation in a 12-month-old baby with severe ventricular systolic dysfunction and incessant ventricular tachycardia. *Europace* 2011;13:1052-5.