



Case Report

Metastatic epidural spinal column compression due to pancreatic ductal adenocarcinoma causing subacute Cauda equina syndrome: A case report

Luis Diaz-Aguilar¹, Usman Khan¹, Ronald Sahyouni¹, Nolan James Brown², Scott Olson¹, Joseph Anthony Osorio¹

¹Department of Neurological Surgery, University of California, San Diego, La Jolla, ²Department of Neurological Surgery, University of California, Irvine, California, United States.

E-mail: Luis Diaz-Aguilar - ldiazagu@health.ucsd.edu; Usman Khan - uskhan@ucsd.edu; Ronald Sahyouni - sahyouniron@gmail.com; Nolan James Brown - nolanb@uci.edu; Scott Olson - seolson@ucsd.edu; *Joseph Anthony Osorio - josorio@health.ucsd.edu



***Corresponding author:**

Joseph Anthony Osorio, MD
Department of Neurosurgery,
University of California, San
Diego School of Medicine,
9500 Gilman Drive, La Jolla,
CA - 92093, United States.

josorio@health.ucsd.edu

Received : 11 August 2020
Accepted : 20 August 2020
Published : 05 September 2020

DOI
10.25259/SNI_514_2020

Quick Response Code:



ABSTRACT

Background: Pancreatic ductal adenocarcinoma (PDAC) is the most common pancreatic malignancy, which rarely metastasizes to the spine.

Case Description: Here, we present a lytic lumbar metastatic PDAC resulting in severe epidural spinal cord compression (ESCC) with instability. The lesion required preoperative particle embolization, surgical decompression, and fusion.

Conclusion: This case report shows that PDAC may metastasize to the lumbar spine requiring routine decompression with fusion.

Keywords: Cauda equina syndrome, Decompression, Instrumentation, Pancreatic ductal adenocarcinoma, Spinal metastasis

INTRODUCTION

Pancreatic ductal adenocarcinoma (PDAC) is a rare cause of metastatic disease to the spine.^[5] PDAC, which constitutes over 95% of all pancreatic cancers, spreads to the bone in 2.2–20% of cases.^[3] When it spreads to the spine, PDAC results in pain, pathological fractures, hypercalcemia, and spinal cord compressive syndromes. As they demonstrate a high degree of radioresistance, these lesions warrant aggressive cytoreductive surgery followed by adjuvant radiosensitizing agents and ablative doses of spinal stereotactic radiosurgery (SRSS). Here, we describe a spinal metastatic epidural lumbar PDAC requiring surgical decompression and fusion, followed by SRSS.

CASE REPORT

A 60-year-old female presented with shortness of breath, ascites, and a subacute progressive cauda equina syndrome and urinary incontinence attributed to a metastatic epidural spinal cord metastasis. CT/MR both documented destructive metastatic lesion of the L4 vertebral body. On

This is an open-access article distributed under the terms of the Creative Commons Attribution-Non Commercial-Share Alike 4.0 License, which allows others to remix, tweak, and build upon the work non-commercially, as long as the author is credited and the new creations are licensed under the identical terms.

©2020 Published by Scientific Scholar on behalf of Surgical Neurology International

the MR/CT studies, there was accompanying L4 extraosseous extension into the spinal canal, spinous process, and left paraspinous musculature (7.8 × 7.1 cm), and another L3 posterior vertebral body lesion also with extension into the spinal canal (2.1 × 2.0 cm) [Figure 1]. Of note, the CT scan and bone scan also demonstrated other foci of metastatic disease to other organs (e.g., liver, lymph nodes, skull, and lumbar spine) [Figure 2]. The L3 vertebral body demonstrated a 20% posterior pathologic compression fracture/deformity with spinal canal narrowing, effacement of the left lateral recess and compression of the traversing left L4 nerve roots. These findings conferred a Spinal Instability Neoplastic Score

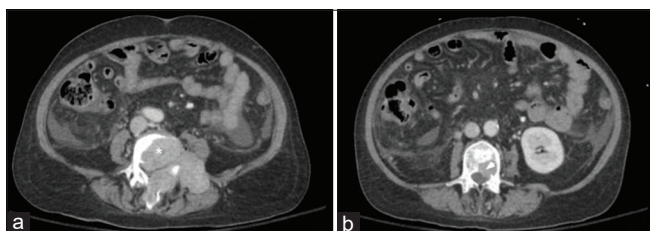


Figure 1: Axial computed tomography abdomen and pelvis demonstrating L4 vertebral body destructive metastases (*) with extraosseous extension into the spinal canal, spinous process, and left paraspinous musculature measuring 7.8 × 7.1 cm (a) and L3 posterior vertebral body metastasis (arrow head) with intraosseous extension into the spinal canal measuring 2.1 × 2.0 cm (b).

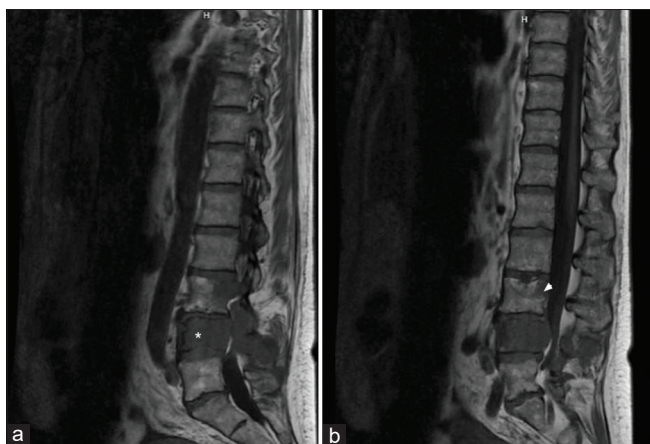


Figure 2: Sagittal magnetic resonance imaging of the lumbar spine demonstrating near-complete marrow replacement of the L4 vertebral body (*) with expansile, locally destructive soft tissue with extension into the left posterior elements and spinous process (a). Associated extra cortical extension of disease with circumferential encasement of the epidural space resulting in extremely severe spinal canal stenosis with compression of the cauda equina nerve roots. There is also replacement of the posterior aspect of the L3 vertebral body (arrow head) and associated 20 percent posterior pathological compression fracture deformity (b). Frank extra cortical disease extension at this level results in moderate spinal canal narrowing with asymmetric effacement of the left lateral recess and compression of the traversing left L4 nerve roots.

[SINS] of 13 [Figure 3]. The patient underwent a CT-guided biopsy of the paraspinous mass, which demonstrated poorly differentiated upper-gastrointestinal/pancreaticobiliary adenocarcinoma (CK7, villin, CDX-2 positive and negative for CK20, CATA-3, PAX-8, TTF-1, napsin, synaptophysin, arginase, and HSA), followed by a biopsy through an esophagogastroduodenoscopy. Before spinal surgery, the patient had an endovascular embolization of the tumor-targeting, the L3 and L4 radicular arteries [Figure 4]. The next day, through a posterolateral approach, corpectomies of both L3 and L4 with interbody arthrodesis were performed along with laminectomies at L1–L5 and L1–S2 alar-iliac (S2-AI) screw placement (e.g., placement of iliac bolts and a 4-rod construct [Figure 5]. A multidisciplinary tumor board recommended neoadjuvant chemoradiation on the basis of the mild cosmetic deformity without neurologic symptoms for the skull lesion, and the potential for immune therapy targeted toward the tumor's genetic profile [Figure 6].

DISCUSSION

Pancreatic cancer is the seventh leading cause of cancer-related deaths worldwide, with a 5-year survival rate of <5%.^[8] The decision to offer surgery for cytoreduction, decompression of the neural elements, and stabilization of the spinal column came from the application of the NOMS framework.^[6] According to the Spine Oncology Study Group (SOGS) criteria,^[2] Grades 2 and 3 define high-grade compression and unless the tumor is highly radiosensitive, surgery for decompression is recommended before radiation therapy to preserve or recover neurologic function.^[2] Contemporary oncologic management of spinal column tumors with ESCC relies on a hybrid approach of separation surgery followed by spine stereotactic radiosurgery (SSRS).

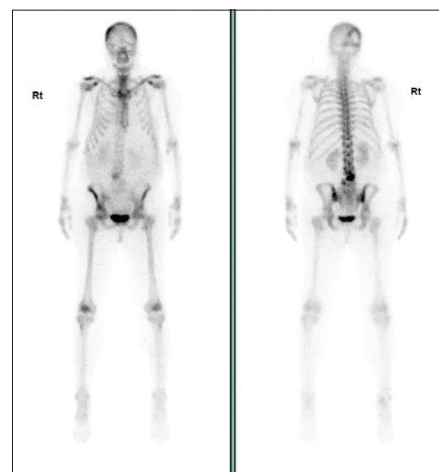

Figure 3: Nuclear medicine bone scan demonstrating a focal rim of activity is seen in the right parietal-occipital skull, intense uptake in the L3–4 level, and mild irregular uptake in the left sacroiliac joint.

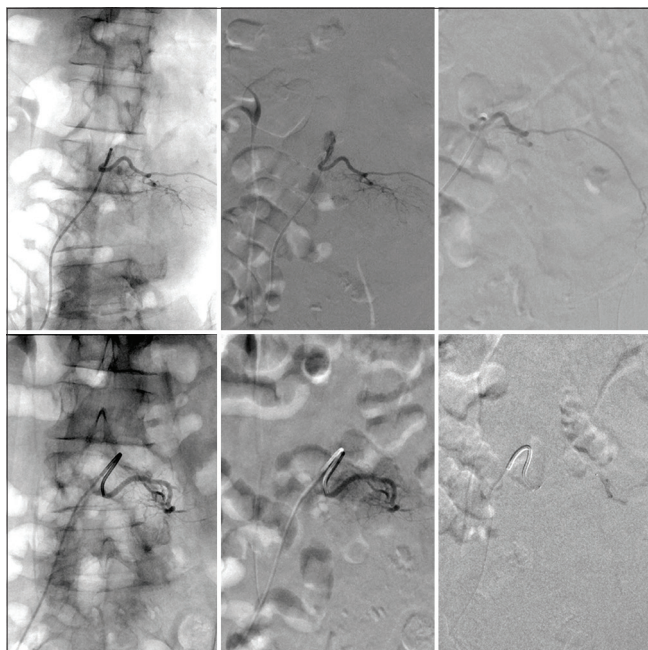


Figure 4: Top row: Source AP fluoroscopy of left L3 radicular superselective angiography (left), digital subtraction angiography of preembolization tumor supply (middle), postembolization irrigation with obliteration of flow (right). Bottom row: similar representation of the left L4 superselective angiography with near total obliteration of supply.

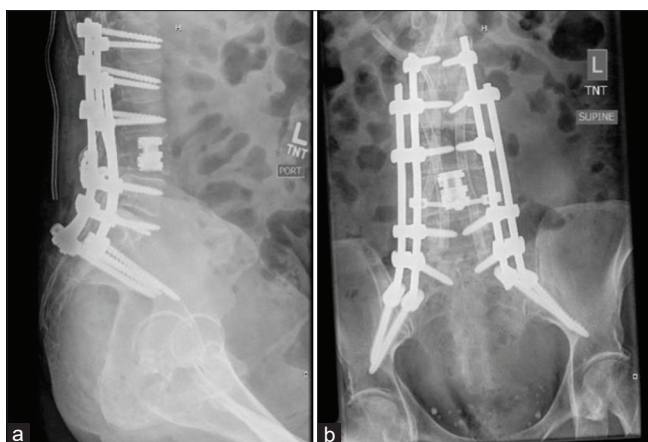


Figure 5: Lateral (a) and anterosuperior (b) X-rays of the lumbar spine demonstrating placement of a L4 corpectomy with placement of a cage and quad rod, pedicle screw instrumentation at L1, L2 and L3, L5, S1, and across the sacroiliac joints with an interlock at the L4 level.

The instability conferred by this patient's lytic lesions at L3 and L4 was an independent indication for mechanical stabilization or cement augmentation. We prefer resection and stabilization through a posterolateral approach for maximum safe resection and stabilization. Cytoreduction also afforded the opportunity to perform molecular profiling and next-generation sequencing on tumor samples to tailor

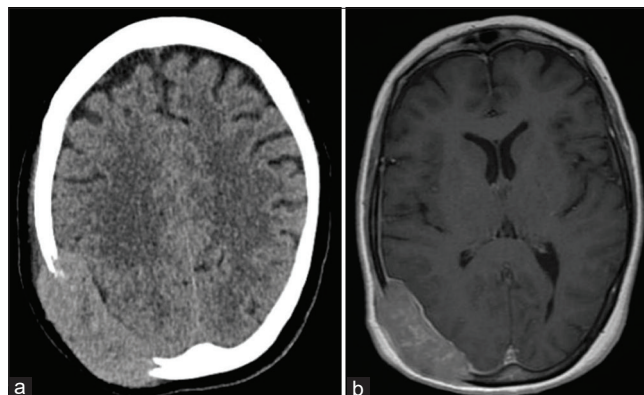


Figure 6: Computed tomography head demonstrating a large expansile transcalvarial lesion centered at the right occipital convexity measuring approximately 7.1×2.3 cm transaxially (a) with resultant sulcal effacement of the subject temporal, parietal, and occipital lobes and expansion into the adjacent scalp soft tissues. Magnetic resonance imaging of the mass is also demonstrated (b).

further therapies. In this case, the patient qualified for immunotherapy and EGFR/VEGF biologics. Preoperative embolization with polyvinyl alcohol (PVA) mitigated the risk of tumor hemorrhage and transfusion.

Treatment options for spinal metastatic disease due to PDAC

Although a number of cases of PDAC metastasizing to the skeletal system have been reported, relatively few studies specifically report metastases to the lumbar spine resulting in canal compression; only one appeared to undergo surgical intervention. One study identified seven patients from a database of 323 PDAC patients (2.2%) with skeletal metastases.^[4] In this series, 57.1% of patients were symptomatic, with the most common metastatic locations being the vertebrae, hips, and ribs. Two additional studies reported small osteoblastic L2^[9] and L3^[7] vertebral body metastatic lesions due to pancreatic adenocarcinoma in the body of the pancreas. Chih *et al.* utilized surgical intervention (percutaneous vertebroplasty) to treat a patient with an L2 lesion.^[4] Furthermore, Argentiero *et al.* reported a PDAC patient with metastatic lesions in L3, T10, T11, the right iliac wing and crest, left clavicle, and bilateral ribs,^[11] while an additional study reported a patient with severe lower back pain and osteoblastic lumbar vertebral lesions.^[7] Finally, Rades *et al.* presented data on 15 PDAC patients with metastatic epidural spinal cord compression who underwent radiotherapy alone and demonstrated improvement in motor function in three patients (20%).^[10]

CONCLUSION

PDAC carries a high mortality rate and rarely metastasizes to the skeletal system. Here, we utilized a posterolateral

approach to perform a L3–4 corpectomy and cage placement for resection of the tumor, interbody fusion (L3–4), instrumentation (L1–5), pelvic fixation with bilateral S2-AI instrumentation, and bilateral iliac bolts.

Declaration of patient consent

Patient's consent not required as patients identity is not disclosed or compromised.

Financial support and sponsorship

Nil.

Conflicts of interest

There are no conflicts of interest.

REFERENCES

1. Argentiero A, Calabrese A, Solimando AG, Notaristefano A, Panarelli MM, Brunetti O. Bone metastasis as primary presentation of pancreatic ductal adenocarcinoma: A case report and literature review. *Clin Case Rep* 2019;7:1972-6.
2. Bilsky MH, Laufer I, Fourny DR, Groff M, Schmidt MH, Varga PP, *et al.* Reliability analysis of the epidural spinal cord compression scale. *J Neurosurg Spine* 2010;13:324-8.
3. Borad MJ, Saadati H, Lakshmiathy A, Campbell E, Hopper P, Jameson G, *et al.* Skeletal metastases in pancreatic cancer: A retrospective study and review of the literature. *Yale J Biol Med* 2009;82:1-6.
4. Chih YP, Wu WT, Lin CL, Jou HJ, Huang YH, Chen LC, *et al.* Vertebral compression fracture related to pancreatic cancer with osteoblastic metastasis: A case report and literature review. *Medicine (Baltimore)* 2016;95:e2670.
5. Iguchi H, Yasuda M, Matsuo T, Sumii T, Funakoshi A. Clinical features and management of pancreatic cancer with bone metastases. *Nihon Shokakibyō Gakkai Zasshi* 2004;101:872-8.
6. Laufer I, Rubin DG, Lis E, Cox BW, Stubblefield MD, Yamada Y, *et al.* The NOMS framework: Approach to the treatment of spinal metastatic tumors. *Oncologist* 2013;18:744-51.
7. Lin CT, Tang CT, Liu MY, Ma HI. Unusual osteoblastic metastases in the spine secondary to adenocarcinoma of the pancreas. *Acta Chir Belg* 2011;111:44-5.
8. Lunardi S, Muschel RJ, Brunner TB. The stromal compartments in pancreatic cancer: Are there any therapeutic targets? *Cancer Lett* 2014;343:147-55.
9. Pneumaticos SG, Savidou C, Korres DS, Chatziioannou SN. Pancreatic cancer's initial presentation: Back pain due to osteoblastic bone metastasis. *Eur J Cancer Care (Engl)* 2010;19:137-40.
10. Rades D, Huttenlocher S, Schild SE, Bartscht T. Metastatic spinal cord compression from pancreatic cancer. *Anticancer Res* 2014;34:3727-30.

How to cite this article: Diaz-Aguilar L, Khan U, Sahyouni R, Brown NJ, Olson S, Osorio JA. Metastatic epidural spinal column compression due to pancreatic ductal adenocarcinoma causing subacute Cauda equina syndrome: A case report. *Surg Neurol Int* 2020;11:279.