



Since January 2020 Elsevier has created a COVID-19 resource centre with free information in English and Mandarin on the novel coronavirus COVID-19. The COVID-19 resource centre is hosted on Elsevier Connect, the company's public news and information website.

Elsevier hereby grants permission to make all its COVID-19-related research that is available on the COVID-19 resource centre - including this research content - immediately available in PubMed Central and other publicly funded repositories, such as the WHO COVID database with rights for unrestricted research re-use and analyses in any form or by any means with acknowledgement of the original source. These permissions are granted for free by Elsevier for as long as the COVID-19 resource centre remains active.



Contents lists available at ScienceDirect

Diabetes & Metabolic Syndrome: Clinical Research & Reviews

journal homepage: www.elsevier.com/locate/dsx

Original Article

COVID-19 associated symmetrical peripheral gangrene: A case series

Abheek Sil^a, Uddalak Chakraborty^b, Atanu Chandra^{c,*}, Surajit Kumar Biswas^a^a Department of Dermatology, Venereology, and Leprosy, RG Kar Medical College and Hospital, 1, Khudiram Bose Sarani, Kolkata, 700004, India^b Department of Neurology, Bangur Institute of Neurosciences, IPGME&R and SSKM Hospital, Annex 1, 52/1 Shambhunath Pandit Street, Kolkata, 700020, India^c Department of Internal Medicine, RG Kar Medical College and Hospital, 1, Khudiram Bose Sarani, Kolkata, 700004, India

ARTICLE INFO

Article history:

Received 8 November 2021

Received in revised form

16 November 2021

Accepted 25 November 2021

Keywords:

COVID-19

Symmetrical peripheral gangrene

Disseminated intravascular coagulation

Coagulopathy

Critical illness

ABSTRACT

Background and aims: The novel coronavirus disease (COVID-19) caused by SARS-CoV-2 has turned the world topsy-turvy since its onset in 2019. The thromboinflammatory complications of this disease are common in critically ill patients and associated with poor prognosis. Symmetrical peripheral gangrene (SPG) is characterized by symmetrical distal gangrene in absence of any large vessel occlusion or vasculitis and it is usually associated with critical illness. Our aim was to report the clinical profile and outcome of patients diagnosed with SPG associated with COVID-19. To the best of our knowledge, no such similar cases have been reported till date.

Methods: In this case series, we have discussed the clinical presentation, laboratory parameters and outcome in a series of two patients of SPG associated with COVID-19 and also compared those findings. Due to paucity of data, we also reviewed the literature on this under-diagnosed and rarely reported condition and association.

Results: Two consecutive patients (both males, age range: 37–42 years, mean: 39.5 years) were admitted with the diagnosis of COVID-19 associated SPG. Both patients had clinical and laboratory evidence of disseminated intravascular coagulation (DIC). Leucopenia was noted in both patients. Despite vigorous therapy, both patients succumbed to their illness within a fortnight of admission.

Conclusion: SPG in the background of COVID-19 portends a fatal outcome. Physicians should be aware of its grim prognosis.

© 2021 Diabetes India. Published by Elsevier Ltd. All rights reserved.

1. Introduction

Since its emergence, COVID-19 has baffled the world with its protean manifestations. Apart from the characteristic respiratory ailment, COVID-19 has wreaked havoc with its notorious thromboinflammatory complications, which are common in critically ill patients and associated with dismal prognosis [1,2]. From the cutaneous perspective, livedoid and necrotic eruptions were commonly observed finding in patients with more severe occlusive vascular disease [3]. Symmetrical peripheral gangrene (SPG) is one such dreaded complication leading to symmetrical distal gangrene in absence of any large vessel occlusion or vasculitis. It is a cutaneous harbinger of critical illness and is characterized by a triad of shock, disseminated intravascular coagulation, and depletion of

natural anticoagulants [4]. Few reports in literature have mentioned dry gangrene in non-vasculopathic patients with severe COVID-19, possibly attributable to consumption coagulopathy and shock [5]. This article encompasses two cases of SPG associated with COVID-19 and provides a comprehensive review of this under-recognized entity associated with critical illness.

2. Methods

This case series describes the clinico-demographic profiles and outcomes of two consecutive patients diagnosed with COVID-19 associated SPG. Written informed consent (from patients or their family members) and adequate ethical clearance were obtained. Data regarding demography, symptoms, clinical presentation, time course and evolution of disease, past medical history, comorbidities, vascular risk factors, addictions, drug/toxin exposure, and family history were obtained. The patients underwent thorough clinical examination and routine laboratory workup. Relevant investigations like estimation of fibrin degradation products, d-dimer

* Corresponding author. Quarters (RG Kar Medical College Campus), 1, Khudiram Bose Sarani, Kolkata, 700004, West Bengal, India.

E-mail address: chandraatanu123@gmail.com (A. Chandra).

assay, anti-nuclear antibodies, anti-phospholipid antibody screening, skin biopsy, and radiological assessment (High resolution computed tomography thorax, Doppler ultrasound) were also performed to rule out any cause. Data was compiled on MS Excel platform. Confirmation of COVID-19 was through positive reverse transcription–polymerase chain reaction (RT–PCR) for SARS-CoV-2 from oropharyngeal and nasopharyngeal swab. Symmetrical peripheral gangrene was defined as “symmetrical irreversible ischemic damage of two or more sites in the absence of any large vessel occlusion or vasculitis” [6]. Given the rarity of this presentation and its association with COVID-19, we further reviewed the literature on PubMed and Medline databases using Medical Subject Headings (MeSH) terms “Symmetrical peripheral gangrene” or “SPG” and “COVID-19” or “SARS-Cov-2”.

3. Results

3.1. Case 1

A 37-year-old immunocompetent male, without any prior comorbidity, presented to the emergency room with high grade fever, cough and dyspnea for last 10 days. Over the past week, he experienced progressive altered sensorium associated with blackish discoloration of skin involving the extremities. No history of any substance abuse or any regular medication was elicited. On admission, he was febrile (39.6 °C), pale, hypoxic (maintaining an oxygen saturation of 89% on room air), and hypotensive (blood pressure: 89/50 mm Hg) with tachycardia (pulse rate-128/min). Cutaneous examination revealed symmetrically distributed blackish discoloration of hands and feet, with a sharp line of demarcation at the ankles and proximal phalanges. Additionally, cutaneous necrosis, focal blistering, dyspigmentation, and exfoliation were noted over the palms and lower half of both legs (Fig. 1). Peripheral pulses were appreciable but feeble. Systemic examination revealed an extensor plantar response bilaterally, with coarse bi-basal crackles on chest auscultation. Reverse transcription–polymerase chain reaction (RT–PCR) for SARS-CoV-2

from oropharyngeal and nasopharyngeal swab turned out to be positive. Laboratory investigations revealed thrombocytopenia ($56 \times 10^9/l$), elevated prothrombin time (21.96s), prolonged activated partial thromboplastin time (58.9 s) along with elevated fibrin degradation products (171 mg/l, normal <10 mg/l) and D-dimer levels (11562 ng/ml; normal <500 ng/ml). High resolution computed tomography (HRCT) thorax revealed multiple patchy and confluent areas of ground glass opacities and septal thickening involving all the lobes of both lungs (CT severity score 20/25) (Fig. 3a). Skin biopsy showed microthrombi in small vessels without any evidence of vasculitis or vasculopathy. Blood culture was non-contributory. Examination of other organ systems was unremarkable. Evaluation for other infective, cardiovascular, malignant, autoimmune, drug, or miscellaneous cause was normal. A final diagnosis of SPG associated with COVID-19 was established. He was managed conservatively [intravenous meropenem at the dose of 1 gm thrice a day, enoxaparin 60 mg twice a day through subcutaneous route and intravenous methyl-prednisolone at the dose of 1000 mg/day along with other supportive measures] in the intensive care unit; however, despite our best efforts the patient succumbed to severe acute respiratory distress syndrome after 12 days of hospitalization.

3.2. Case 2

A 42-year-old gentleman presented with fever for 12 days. Fever was initially low grade and intermittent, but over last 5 days it became high grade and continuous. There was also a dry cough since the onset of febrile illness. He was feeling short of breath on minimal activity over last three days. He complained of slightly painful blackish discoloration of the skin involving the toes for last 4–5 days. Notably, he did not have any hemoptysis, chest pain, orthopnea, diarrhea and loss of smell or taste sensation. The patient did not give any history of diabetes or hypertension; no substance abuse or use of any regular medication was elicited.

On admission, he was febrile (37.8 °C) with tachycardia (pulse rate: 110/min). His blood pressure was 104/60 mmHg and

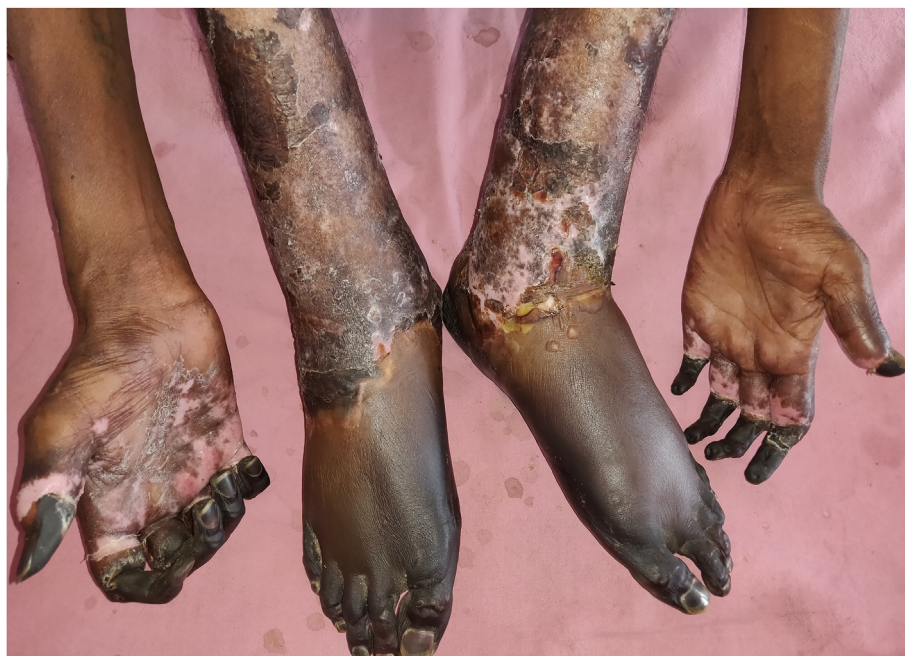

Fig. 1. Gangrenous changes involving distal extremities of hands and feet associated with focal hemorrhagic blisters, erosions and desquamation.

respiratory rate 30/minute. Pulse oximetry revealed oxygen saturation of 84% on room air. Cutaneous examination revealed dry gangrene with areas of ulceration involving the toes of both feet (Fig. 2). All the peripheral pulses were palpable. There was no clinical evidence of cardiovascular ailment. On auscultation of the chest, crackles and wheezes were audible bilaterally, most predominantly over the lung bases. Examination of other systems was unremarkable.

RT-PCR for SARS-CoV-2 from oropharyngeal and nasopharyngeal swab came positive. Laboratory workup revealed lymphopenia (absolute lymphocyte count of 990/microL) and thrombocytopenia. There was significant elevation in prothrombin time (18.8 s), activated partial thromboplastin time (44.4 s), fibrin degradation products (204 mg/l; reference value < 10 mg/l) and D-dimer levels (9356 ng/ml; reference value < 500 ng/ml). Blood culture was negative. A HRCT thorax revealed multiple areas of confluent and patchy ground glass opacities with predominant lower, peripheral and sub-pleural distribution (CT severity score 12/25) (Fig. 3b). As with our first patient, evaluation for other infective, cardiovascular, malignant and autoimmune causes was negative. Patient was started on intravenous steroids (dexamethasone at the dose of 12 mg/day in 3 divided doses), enoxaparin (60mg twice a day through subcutaneous route) along with other supportive measures. During hospitalization, patient developed progressive hypoxemia and despite our best efforts, he succumbed on day-10 of hospitalization.

The comparison between the presentation, clinical features, laboratory parameters and outcome of the two cases has been outlined in Table 1.

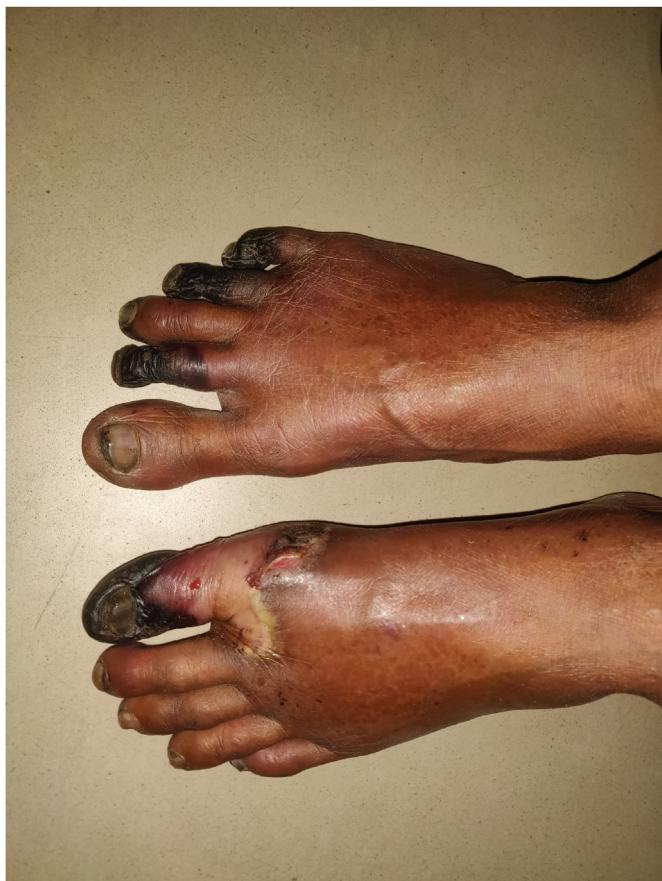

Fig. 2. Dry gangrene with areas of ulceration involving the toes of both feet.

4. Discussion

Thrombotic complications in COVID-19 bear a dismal prognosis and adverse outcomes have been reported with markedly elevated pro-inflammatory mediators and dysregulated fibrinolytic state. Jenner et al. reported around 56.3% thrombotic events in 2928 critically ill COVID-19 patients in a systematic review [7]. It is well established that severe COVID-19 associated with cytokine storm is a harbinger of dysregulated coagulation homeostasis leading to thromboinflammation and consumption coagulopathy, subsequently increasing mortality and morbidity. Although the exact mechanism of COVID-19 induced thrombosis remains elusive, increased activation of thrombocytes with coagulation cascade and decreased fibrinolysis deserve mention. Direct endothelial damage mediated by SARS-CoV-2 with subsequent exposure of collagen may lead to platelet adhesion and aggregation, followed by subsequent activation of coagulation cascade coupled with abnormal fibrinolysis [8,9]. The cytokine storm triggered by SARS-CoV-2 mediated by IL-6, interferon-gamma, and IL-2 aggravates the pro-thrombotic state and facilitates hypercoagulability [10]. Moreover, the alternative and the lectin pathways of the complement system adds additional fuel to the fire, facilitating thrombosis [11]. Microvascular and macrovascular thrombosis in COVID-19 have been reported worldwide and correlates well with severity of ailment.

SPG is a rare entity harboring significant morbidity characterized by symmetrical irreversible ischemic damage of two or more sites in the absence of any large vessel occlusion or vasculitis.⁶A wide spectrum of infective and non-infective etiologies have been attributed to cause SPG, although the pathogenesis is debatable. Disseminated intravascular coagulation (DIC) with microcirculatory occlusion is usually contributory. Schwartzman reaction, endotoxin, platelet plugging in peripheral vasculature due to hypercoagulable vasospasm and DIC are the probable pathomechanisms involved in SPG [12]. DIC contributes to the final common pathway in majority cases of SPG. Bacterial, viral, protozoal agents are common offenders aside the non-infective causes like myocardial infarction, hypovolemic/septic shock, lymphoreticular malignancies, pulmonary embolism, and vasopressors. Pain in the extremities followed by fever with or without constitutional symptoms in presence of cold, pale, cyanotic acral parts of the body is the usual presentation, which may progress to a frank dry gangrene if not reversed. The gangrene is usually symmetric, may progress proximally from distal sites, often associated with mummification and may lead to auto-amputation. SPG is not associated with any compromise of the distal pulses, however features of shock may predominate in some cases [13].

Coagulation abnormalities and thrombotic manifestations have been increasingly reported in patients with moderate to severe COVID-19 pandemic. Multisystem inflammation and thromboinflammation has provided new insights to the management of this pandemic. Purpura fulminans (PF) is one such manifestation, characterized by rapidly progressive cutaneous necrosis and hemorrhage attributable to vascular thrombosis and DIC, which have been reported in literature in association with COVID-19 [14]. Majority of patients of SPG may have preceding PF in different parts of the body. However, notable causes of acral gangrene namely thrombangitis obliterans, atherosclerotic plaque, thromboemboli, vasculitis must be ruled out to establish a diagnosis of SPG. DIC has been reported to lead to development of dry gangrene in patients with severe COVID-19 [15]. In the background of critically ill COVID-19 patients, the role of vasopressors in pathogenesis of SPG is enigmatic, however microthrombosis attributable to thromboinflammatory state in COVID-19 takes the upper hand [16].

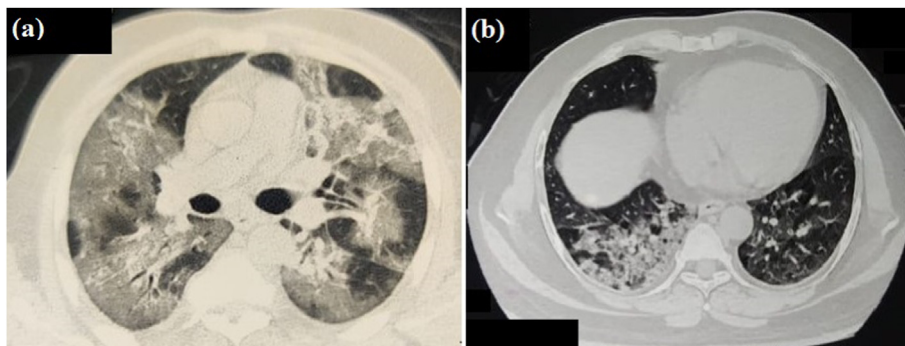


Fig. 3. High resolution computed tomography (HRCT) thorax showing multiple patchy and confluent areas of ground glass opacities in both lungs (Panel a, b).

Table 1
Clinical profile, laboratory parameters and outcome of patients of COVID-19 associated SPG.

Parameters	Patient 1	Patient 2
Age	37	42
Sex	Male	Male
Symptoms	High grade fever, cough, dyspnoea, altered sensorium, cutaneous discoloration	Fever, dry cough, blackish discoloration of toes
SARS-COV2 RT-PCR	Positive	Positive
Latency period from onset of COVID-19 symptoms and appearance of gangrenous changes (days)	4	8
Duration of hospital stay (days)	10	12
Severity of COVID-19	Severe	Severe
Comorbidities	None	Coronary heart disease
Cutaneous examination	Symmetrical peripheral gangrene involving both hands and feet	Dry gangrene involving toes of both feet with areas of ulceration
Systemic examination	Coarse bibasilar crackles, bilateral extensor plantar response	Crackles and wheeze over both lung bases
Laboratory parameters		
Total count (cells/uL)	14000	12860
ALC (cells/uL)	1050	990
Platelets (cells/uL)	59000	87640
PT (secs)	21.9	18.8
APTT (secs)	58.9	44.4
FDP (mg/L)	171	204
D-dimer (ng/mL)	11562	9356
Other triggers of SPG	None	None
Treatment received	Intravenous dexamethasone, enoxaparin, supportive care	Intravenous dexamethasone, enoxaparin, supportive care
Outcome	Expired after 12 days of hospitalization	Expired after 10 days of hospitalization

Abbreviations: ALC – absolute lymphocyte count; PT – prothrombin time; APTT – activated partial thromboplastin time; FDP – fibrin degradation products.

Therapeutic options in SPG are limited and are not evidence based; prompt recognition and early treatment of the underlying cause may be useful. Aggressive antimicrobial coverage with adequate hydration and judicious correction of DIC guided by basic tests of coagulation is the mainstay of therapy. Replenishing depleted coagulation factors in bleeding predominant disease and recombinant protein C, anticoagulants, antithrombin, plasmapheresis, intravenous immunoglobulin, continuous ultrafiltration, and continuous hemofiltration in thrombotic disease have been tried with limited success [17]. Sympathetic blockade, intravenous nitroprusside, intravenous infusion of an alpha blocker or prostaglandins are remaining options [18].

SPG is associated with a high rate of amputation among survivors as per existing literature. Mortality is considerably high in SPG with leucopenia and ischemic hepatitis (shock liver) being poor prognostic markers and most deaths occur reportedly between 5 and 21 days of the onset of gangrene [19]. Leucopenia was noted in both patients. Despite aggressive management, none of our patients survived beyond a fortnight from admission.

Limitation: Our series is limited by a small sample size. Large scale pooled data from multiple centers would further advance our knowledge on this association. We could not perform estimation of

anticoagulant proteins due to institutional non-availability. Further, post-mortem examinations of these patients were not conducted.

5. Conclusion

To conclude, we would like to draw attention of physicians to this unique clinical entity (SPG) that often remains under-recognized leading delayed etiological evaluation and ultimately high mortality. In the setting of COVID-19, SPG might invariably bear a fatal outcome. Amidst this ongoing pandemic, we advise screening for COVID-19 in patients clinically diagnosed with SPG.

Contributorship statement

AS and UC prepared the manuscript with adequate planning and execution. AC, AS and SKB contributed to patient's management, review of literature, critical revision of content and final approval of manuscript. All authors are in agreement to be accountable for all aspects of the work in ensuring that questions related to the accuracy or integrity of any part of the work are appropriately investigated and resolved.

Funding

Nil.

Declaration of competing interest

No, there are no competing interests for any author.

Acknowledgement

Nil.

References

- [1] Shibeel S, Ahmad MN. Thrombotic and hypercoagulability complications of COVID-19: an update. *J Blood Med* 2021;12:785–93.
- [2] Chandra A, Chakraborty U, Ghosh S, Dasgupta S. Anticoagulation in COVID-19: current concepts and controversies. *Postgrad Med* 2021. <https://doi.org/10.1136/postgradmedj-2021-139923>. Epub ahead of print. PMID: 33850011.
- [3] Panda M, Dash S, Behera B, Sil A. Dermatological manifestations associated with COVID-19 infection. *Indian J Dermatol* 2021;66(3):237–45.
- [4] Warkentin TE, Ning S. Symmetrical peripheral gangrene in critical illness. *Transfus Apher Sci* 2021;60(2):103094.
- [5] Novara E, Molinaro E, Benedetti I, Bonometti R, Lauritano EC, Boverio R. Severe acute dried gangrene in COVID-19 infection: a case report. *Eur Rev Med Pharmacol Sci* 2020;24(10):5769–71.
- [6] McGouran RC, Emmerson GA. Symmetrical peripheral gangrene. *Br Heart J* 1977;39:569–72.
- [7] Jenner WJ, Kanji R, Mirsadraee S, et al. Thrombotic complications in 2928 patients with COVID-19 treated in intensive care: a systematic review. *J Thromb Thrombolysis* 2021;51(3):595–607.
- [8] Ackermann M, Verleden SE, Kuehnel M, et al. Pulmonary vascular endothelialitis, thrombosis, and angiogenesis in covid-19. *N Engl J Med* 2020;383(2):120–8.
- [9] Wright FL, Vogler TO, Moore EE, et al. Fibrinolysis shutdown correlation with thromboembolic events in severe COVID-19 infection. *J Am Coll Surg* 2020;231(2):193–203.
- [10] Wang J, Jiang M, Chen X, Montaner LJ. Cytokine storm and leukocyte changes in mild versus severe SARS-CoV-2 infection: review of 3939 COVID-19 patients in China and emerging pathogenesis and therapy concepts. *J Leukoc Biol* 2020;108(1):17–41.
- [11] Iechter-Sandersjöo A, Bellander BM. Is COVID-19 associated thrombosis caused by overactivation of the complement cascade? A literature review. *Thromb Res* 2020;194:36–41.
- [12] Ghosh SK, Bandyopadhyay D. Symmetrical peripheral gangrene. *Indian J Dermatol Venereol Leprol* 2011;77(2):244–8.
- [13] Diwan AG, Mittal J, Jadhav A, Pradhan AB. Symmetrical peripheral gangrene with multifactorial origin. *J Indian Acad Geriatr* 2005;3:103–9.
- [14] Khan IA, Karmakar S, Chakraborty U, Sil A, Chandra A. Purpura fulminans as the presenting manifestation of COVID-19. *Postgrad Med* 2021;97(1149):473.
- [15] Novara E, Molinaro E, Benedetti I, Bonometti R, Lauritano EC, Boverio R. Severe acute dried gangrene in COVID-19 infection: a case report. *Eur Rev Med Pharmacol Sci* 2020;24(10):5769–71.
- [16] Kashyap R, Behl RK, Mahajan S, Jaret P, Patial RK, Kaushal SS. Symmetrical peripheral gangrene due to viral gastroenteritis. *J Assoc Phys India* 2004;52:500–1.
- [17] Davis MD, Dy KM, Nelson S. Presentation and outcome of purpura fulminans associated with peripheral gangrene in 12 patients at Mayo Clinic. *J Am Acad Dermatol* 2007;57:944–56.
- [18] Denning DW, Gilliland L, Hewlett A, Hughes LO, Reid CD. Peripheral symmetrical gangrene successfully treated with epoprostenol and tissue plasminogen activator. *Lancet* 1986;2:1401–2.
- [19] Ghosh SK, Bandyopadhyay D, Ghosh A. Symmetrical peripheral gangrene: a prospective study of 14 consecutive cases in a tertiary-care hospital in eastern India. *J Eur Acad Dermatol Venereol* 2010;24:214–8.