

Neonatal Graves disease with persistent hypoglycemia: A case report

SAGE Open Medical Case Reports
Volume 12: 1–4
© The Author(s) 2024
Article reuse guidelines:
sagepub.com/journals-permissions
DOI: 10.1177/2050313X241237433
journals.sagepub.com/home/sco



Samantha Fine^{1,2} , Michael Gottschalk^{1,2}
and Krishelle Marc-Aurele^{1,2}

Abstract

Neonatal Graves disease is the most common cause of hyperthyroidism during the newborn period. Maternal Graves disease increases the risk of intrauterine growth restriction, small for gestational age, and neonatal Graves disease. Intrauterine growth restriction and small for gestational age are associated with hypoglycemia and transient neonatal hyperinsulinism. Neonatal Graves disease with severe persistent hypoglycemia has not been well described. We present the case of a female patient born at 34 weeks and 3 days with a birth weight of 1.6 kg (fifth percentile) to a mother with recent treatment for Graves disease. Prenatal ultrasounds were significant for intrauterine growth restriction and small for gestational age. The mother did not begin hyperthyroidism medical therapy until 23 weeks and 2 days of gestation. After the infant was born, the infant not only had symptoms of hyperthyroidism such as tachycardia and abnormal thyroid values but also had persistent hypoglycemia, which could be due to maternal propranolol usage, prematurity, IUGR, increased metabolism due to neonatal Graves, and transient stress-induced hyperinsulinism. The infant was started on methimazole for hyperthyroidism and propranolol for tachycardia. She was also started on diazoxide for persistent hypoglycemia. By 6 months of age, the hyperthyroidism and hypoglycemia had resolved. This is an interesting case of neonatal Graves disease with severe persistent hypoglycemia which we suspect is due to transient neonatal hyperinsulinism induced by multiple stress responses.

Keywords

Neonatal Graves disease, hyperthyroidism, hyperinsulinism, hypoglycemia

Date received: 14 November 2023; accepted: 19 February 2024

Introduction

Neonatal Graves disease is rare and occurs in about 1–5% of infants born to mothers with Graves disease.¹ The clinical presentation of neonatal Graves disease varies widely and can present with symptoms such as hyperactivity, tachycardia, and goiter.² The clinical presentation of neonatal Graves disease largely depends on the levels of thyroid-stimulating hormone (TSH) receptor antibodies (TRAbs) with increased maternal TRAbs being associated with a greater likelihood of neonatal Graves disease.³ Maternal Graves disease increases the risk of intrauterine growth restriction (IUGR), small for gestational age (SGA), and neonatal Graves disease. IUGR and SGA are associated with hypoglycemia and transient hyperinsulinism.⁴ Neonatal Graves disease with severe persistent hypoglycemia has not been described.

Case presentation

We present an IUGR SGA female patient who was born at 34 weeks and 3 days with a weight of 1.6 kg (3.53 lbs) (5th

percentile), length of 43 cm (16.93 inches) (28th percentile), and head circumference of 29.5 cm (11.16 inches) (15th percentile) to a 24-year old G1P0 mother with prenatal care. Prenatal ultrasounds were significant for IUGR, oligohydramnios, and echogenic bowel. Fetal echocardiogram was significant for sinus tachycardia up to 170 bpm. Prenatal noninvasive cell-free DNA testing, which is a maternal blood test that can screen for fetal chromosomal abnormalities, was positive for Turner syndrome; however, the mother declined amniocentesis. The maternal karyotype was obtained to look for mosaicism and was normal.

The mother had a history of hyperthyroidism; however, she was not on medication therapy prior to becoming pregnant. She

¹Rady Children's Hospital, San Diego, CA, USA

²Department of Pediatrics, University of California San Diego Jacobs Medical Center, San Diego, CA, USA

Corresponding Author:

Samantha Fine, Department of Pediatrics, Rady Children's Hospital, 3020 Children's Way, MC 5124, San Diego, CA 92123, USA.
Email: s1fine@health.ucsd.edu



was otherwise previously healthy and did not have gestational diabetes. During the last trimester of pregnancy at 23 weeks and 2 days of gestation, she presented to the emergency room with thyrotoxicosis and was started on 30 mg/day of methimazole and 20 mg/day of propranolol for the remainder of the pregnancy. The mother's initial TRAbs were 35 IU/L (normal range is ≤ 1.75 IU/L) and her thyroid-stimulating immunoglobulin result was greater than 500% (normal is $< 122\%$).

At 34 weeks and 3 days, the mother was admitted for delivery due to fetal heart rate decelerations seen on non-stress testing (NST), which is an ultrasound-based test to assess fetal well-being.⁵ At that time, maternal heart rate ranged from 90 to 110 bpm with prior baseline heart rates ranging from 60 to 75 bpm. Her free T4 (FT4) was elevated at 2.55 ng/dL (0.93–1.70 ng/dL), and total T3 resulted as > 6.5 ng/dL (0.8–2.0 ng/dL) which was the highest laboratory value that could be reported from testing.

The infant was delivered via cesarean section due to the abnormalities seen on prenatal ultrasounds as well as decelerations on routine NST. The infant had APGARs of 8 and 9 with normal vital signs, normal physical exam without dysmorphism nor goiter, and required no initial interventions at birth. Chromosomal testing was normal and ruled out Turner syndrome. Ultrasound of the thyroid was not performed consistent with endocrinology recommendations, as diagnosis of neonatal Graves disease is made via measurements of FT4, thyroid-stimulating immunoglobulins, and TSH.²

Upon admission for prematurity, intermittent tachycardia (> 160 bpm) was noted and then severe tachycardia (> 200 bpm) occurred on day of life (DOL) 8. In the setting of maternal Graves disease, neonatal Graves disease was diagnosed by infant's blood, obtained on DOL 4, which showed elevated thyroid-stimulating immunoglobulins at 448% ($< 122\%$), elevated FT4 2.8 ng/dL (0.9–2.5 ng/dL), and low TSH at 0.1 uIU/ml (0.27–4.20 uIU/mL). The samples were run on a Roche Cobas 8000 instrument and reference ranges for normal FT4 values were 0.9–2.5 ng/dL (for ages 0–5 days) and 0.9–2.2 ng/dL (for 0–2 months).

In addition, severe hypoglycemia was noted with point-of-care glucose between 20 and 30 mg/dL starting at the first hour of life and required glucose infusion for 18 days with intermittent persistent hypoglycemia for the first 8 days of life. The glucose infusion rate (GIR) was increased daily due to persistent hypoglycemia (glucose < 50 mg/day) and at one point, the GIR reached a peak at 14.8 mg/kg/min (DOL 10). Hypoglycemia workup when glucose was 35 mg/dL in the first 48 h of life included: normal lactate, low beta-hydroxybutyrate, absent urine ketones, elevated growth hormone, and normal cortisol. The laboratory notified the team that the amount of blood sent to test for an insulin level was insufficient several days later. A repeat specimen for insulin was not re-sent because treatment with diazoxide had already been initiated. The newborn screen was normal.

Treatment

On DOL 8, methimazole was initiated at 0.5 mg/kg/day for hyperthyroidism and diazoxide was initiated at 16.5 mg/kg divided every 8 h for persistent hypoglycemia. On DOL 9, propranolol 0.5 mg/kg/day was initiated when repeat thyroid testing, per American Academy of Pediatrics (AAP) guidelines, demonstrated persistent hyperthyroidism with elevated FT4 4.67 ng/dL (0.9–2.2 ng/dL), low TSH 0.01 uIU/mL (0.27–4.20 uIU/mL), and T3 1.8 ng/mL (0.8–2.0 ng/dL). Glucose levels stabilized (> 50 mg/dL) when diazoxide was started on DOL 8 and the glucose infusion was tapered and eventually discontinued 10 days after starting diazoxide and methimazole.

Outcome and follow-up

The infant's FT4 and T3 levels normalized on DOL 27 with FT4 0.8 ng/dL (0.9–2.2 ng/dL), T3 1.0 ng/mL (0.8–2.0 ng/dL), and the patient was discharged after 1 month in the NICU on methimazole 0.5 mg/kg/day divided three times a day and diazoxide 15 mg/kg/day divided three times a day. At 6 weeks of age, because the FT4 was low at 0.44 ng/dL (0.9–2.5 ng/dL), and TSH normalized at 2.39 uIU/mL (0.27–4.20 uIU/mL), the methimazole was stopped. By 7 months of age, she had normal glucose at 73–81 ng/dL and thyroid levels of FT4 of 0.96 ng/dL, TSH 1.54 uIU/mL. Her glucose remained stable when checked at home and she did not have any hypoglycemic encephalopathy or hyperglycemic episodes. At this point, the diazoxide was discontinued as shown in Figure 1.

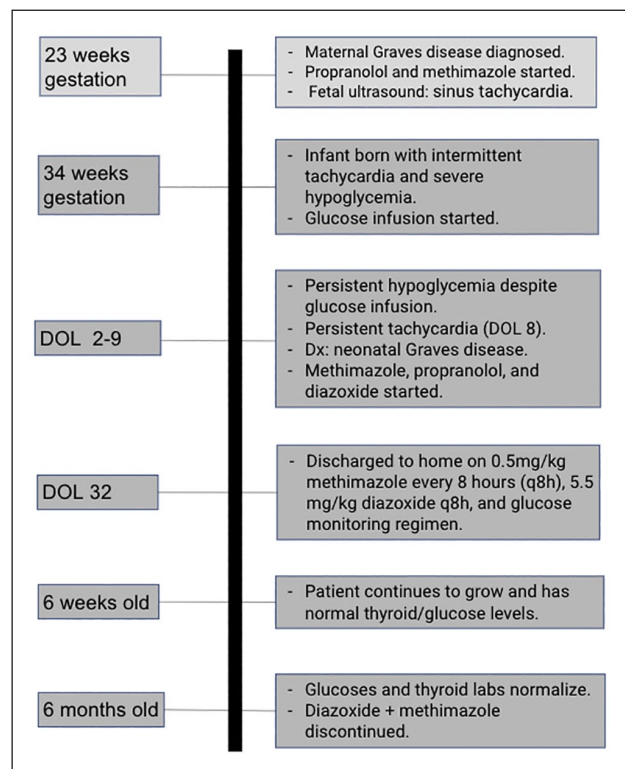


Figure 1. Timeline of events.

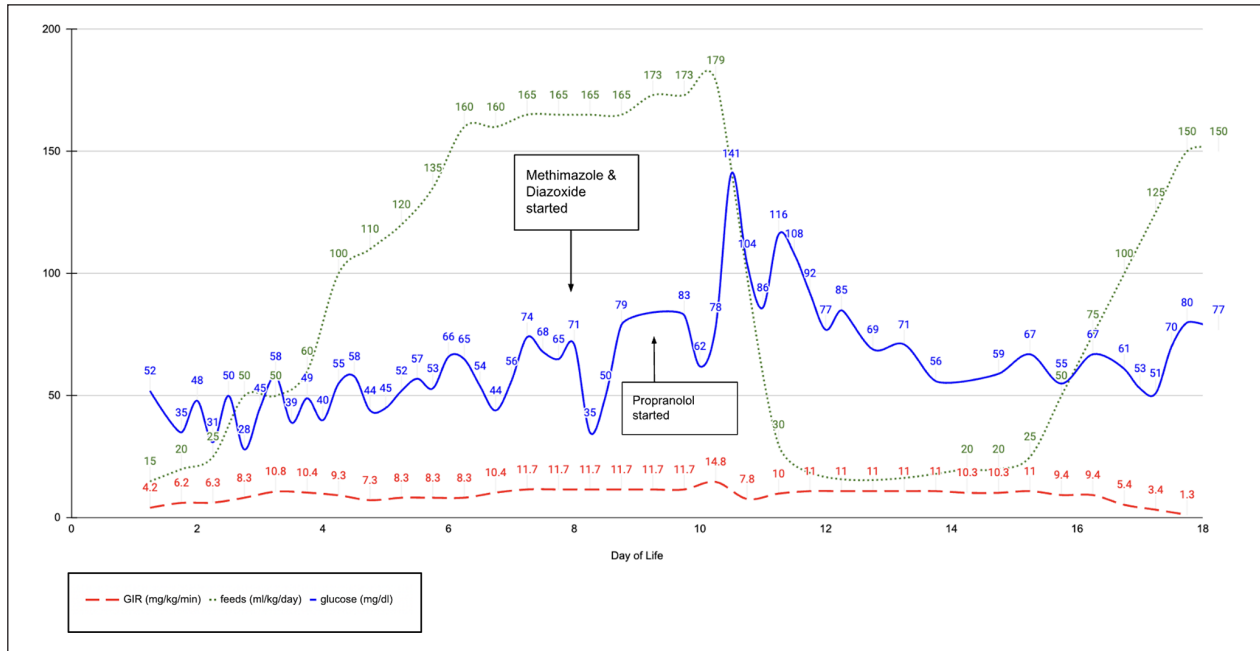


Figure 2. Comparison of GIR, glucose, and feeds in the setting of neonatal Graves disease with persistent hypoglycemia.

Discussion

Neonatal Graves disease is caused by the direct placental transfer of maternal thyroid-stimulating immunoglobulins that bind to the fetal TSH receptors, such as shown in this case. The binding to TSH receptors leads to increased production of thyroid hormones causing hyperthyroidism and in some severe cases, thyrotoxicosis.⁶ While there are case reports of rare resistance to thyroid hormone beta, typically infants with neonatal Graves present with suppressed TSH levels through a negative feedback loop.⁷ Neonatal Graves is normally transient, such as this case, and resolves within the first year of life due to clearance of maternal thyroid immunoglobulins.⁸ AAP guidelines recommend treating neonatal Graves with methimazole, and propranolol if needed, and to follow clinically at least until 3 months of age, which was done in this case.

This case is unique because neonatal Graves disease with severe persistent hypoglycemia is not well described. Maternal Graves disease can contribute to IUGR and lead to SGA, such as demonstrated in this case. Hypoglycemia in an infant is commonly seen with risk factors like prematurity, SGA, and IUGR, but symptoms normally resolve in the first few days of life. In addition, hypoglycemia can occur in neonates exposed to maternal beta-blockers; however, the hypoglycemic effects, similar to SGA and IUGR infants, are transient and resolve in the first few days of life.⁹ In this case, hyperinsulinism was a diagnosis of exclusion (i.e., no acidosis, bacteremia, or clinical signs to suggest sepsis, low beta-hydroxybutyrate which argued against cortisol and growth hormone deficiency, negative screening for fatty acid oxidation disorders on newborn

screening, and negative hypopituitarism workup). The improvement with diazoxide, and resolution within 6 months of age, favors a diagnosis of persistent hypoglycemia or transient hyperinsulinism.¹⁰ However, hyperinsulinism-specific laboratories such as molecular analysis for HNF4A and HNF1A, were not obtained.

Perinatal stress is a common cause of persistent hypoglycemia and neonatal transient hyperinsulinism.¹¹ The most plausible reason for the persistent hypoglycemia was the infant’s growth restriction, which was a result of uncontrolled maternal Graves disease, which, in turn, induced a stress response in the infant. The stress response was likely exacerbated by the unmasking of neonatal hyperthyroidism after the maternal methimazole was cleared from the infant’s system at 1 week of life. This is supported by a need to increase the infant’s GIR from 7 mg/kg/min (DOL 5) to 14.8 mg/kg/min (DOL 10) as demonstrated in Figure 2. Stress can lead to an increase in catecholamines, which has been proposed to cause dysregulated insulin secretion leading to, transient hyperinsulinism and persistent hypoglycemia.⁹

This is an interesting case of neonatal Graves disease with severe persistent hypoglycemia. Pediatricians, endocrinologists, neonatologists, obstetricians, and gynecologists need to be aware of persistent hypoglycemia and possibly transient hyperinsulinism as a potential risk with IUGR and SGA, especially in the setting of maternal Graves disease and neonatal hyperthyroidism. It is important to diagnose neonatal Graves and persistent hypoglycemia early so that life-threatening symptoms, such as tachycardia, heart failure, and in this case, hypoglycemia, can be immediately treated and managed long term.

Conclusion

Neonatal Graves disease is the most common cause of hyperthyroidism during the newborn period. This is an interesting case of neonatal Graves disease with severe persistent hypoglycemia which we suspect is due to transient neonatal hyperinsulinism induced by multiple stress responses and unmasked by neonatal hyperthyroidism.

Learning points

- Maternal Graves disease increases the risk of IUGR, SGA, and neonatal Graves disease, as demonstrated in this case.
- IUGR and SGA are associated with hypoglycemia and transient hyperinsulinism.
- For this case, we suspect the severe persistent hypoglycemia is due to transient neonatal hyperinsulinism induced by multiple stress responses, unmasked by neonatal hyperthyroidism.
- Pediatricians, endocrinologists, neonatologists, and OB/Gyns need to be aware of hypoglycemia and transient hyperinsulinism as a potential risk with IUGR and SGA.
- It is important to diagnose neonatal Graves and persistent hypoglycemia early so that life-threatening symptoms, such as tachycardia, heart failure, and in this case, hypoglycemia, can be immediately treated and managed long term.

Acknowledgements

The authors would like to thank this patient's mother for allowing us to share her daughter's clinical presentation to educate the medical community.

Author contributors

All authors made individual contributions to authorship. SF, KM, and MG were involved in the manuscript submission. KM and MG were involved in the diagnosis and management of this patient. All authors reviewed and approved the final draft.

Data availability statement

Data sharing is not applicable to this article as no datasets were generated or analyzed during the current study.

Declaration of conflicting interests

The author(s) declared no potential conflicts of interest with respect to the research, authorship, and/or publication of this article.

Funding

The author(s) received no financial support for the research, authorship, and/or publication of this article.

Ethics approval

Our institution does not require ethical approval for reporting individual cases or case series.

Informed patient consent

Written informed consent was obtained from a legally authorized representative for anonymized patient information to be published in this article.

Disclosure

None declared.

ORCID iD

Samantha Fine  <https://orcid.org/0000-0002-7461-3083>

References

1. De Groot L, Abalovich M, Alexander EK, et al. Management of thyroid dysfunction during pregnancy and postpartum: an Endocrine Society clinical practice guideline. *J Clin Endocrinol Metab* 2012; 97: 2543.
2. Polak M, Legac I, Vuillard E, et al. Congenital hyperthyroidism: the fetus as a patient. *Horm Res* 2006; 65(5): 235–242.
3. Bucci I, Giuliani C and Napolitano G. Thyroid-stimulating hormone receptor antibodies in pregnancy: clinical relevance. *Front Endocrinol (Lausanne)* 2017; 8: 137.
4. Saki F, Dabbaghmanesh MH, Ghaemi SZ, et al. Thyroid function in pregnancy and its influences on maternal and fetal outcomes. *Int J Endocrinol Metab* 2014; 12(4): e19378.
5. Umama OD and Siccardi MA. Prenatal nonstress test. [Updated 2023 Aug 7]. In: *StatPearls* [Internet]. Treasure Island, FL: StatPearls Publishing; 2023.
6. Batra CM. Fetal and neonatal thyrotoxicosis. *Indian J Endocrinol Metab* 2013; 17(Suppl 1): S50–S54.
7. Seetharaman S, Quintos JB and Salas-Lucia F. Resistance to thyroid hormone beta in a patient born to a mother with undiagnosed Graves' disease. *AACE Clin Case Rep* 2023; 9(3): 63–66.
8. Jap TS, Ho LT and Won JG. Insulin secretion and sensitivity in hyperthyroidism. *Horm Metab Res* 1989; 21(5): 261–266.
9. Thornton PS, Stanley CA, De Leon DD, et al. Recommendations from the pediatric endocrine society for evaluation and management of persistent hypoglycemia in neonates, infants, and children. *J Pediatr* 2015; 167(2): 238–245.
10. Gray KD, Dudash K, Escobar C, et al.; Best Pharmaceuticals for Children Act–Pediatric Trials Network Steering Committee. Prevalence and safety of diazoxide in the neonatal intensive care unit. *J Perinatol* 2018; 38(11): 1496–1502.
11. Hussain K, Thornton PS, Otonkoski T, et al. Severe transient neonatal hyperinsulinism associated with hyperlactataemia in non-asphyxiated infants. *J Pediatr Endocrinol Metab* 2004; 17(2): 203–209.