

Silent colonic perforation and enterocutaneous fistula by a ball point pen 13 years after ingestion in a patient with schizophrenia

Dheeraj Kattula¹, Stephen Amarjeet Jiwanmall¹, Balaji Srinivasa Sekaran¹, Somanatha Sharma²

¹Department of Psychiatry, Christian Medical College, Vellore, ²Department of Surgery, Stanley Medical College, Chennai, Tamil Nadu, India

ABSTRACT

Patients with mental illness do not get medical and surgical attention as required. Here is a case of poor, unemployed gentleman with an ulcer which was carefully evaluated and treated appropriately. The presentation is novel in many other ways. The object of size 6 × 2.5 cm usually does not cross the duodenum, but in his case an 11-cm long pen had reached the splenic flexure. It also had stayed dormant for over 13 years before causing complications. When the pen perforated the bowel, the patient is expected to present with acute abdomen, but in this case it presented as enterocutaneous fistula. This case is first of its kind in medical literature.

Keywords: Enterocutaneous fistula, foreign body ingestion, schizophrenia

Case Presentation

Mr. S is a 31-year-old, single, unemployed gentleman from a low socioeconomic Tamil-speaking background, who first came to psychiatric hospital in 2003 at the age of 17 years within 10 days of onset of symptoms of psychosis and mania. He was treated with tablet risperidone up to 4 mg/day. He responded well and even went back to school. After 9 months of regular treatment, he stopped medicines. Two months after stopping of medicines he had relapse of psychotic symptoms including Schneiderian first rank symptoms without any mood symptoms. His diagnosis was revised to paranoid schizophrenia. He failed trials of tablet risperidone 8 mg/day, tablet olanzepine 25 mg/day, a course of 10 sittings of electroconvulsive therapy, and injection fluphenazine decanoate depot 100 mg intramuscular

every month. He did not show significant improvement. He was started on tablet clozapine and the dose was gradually built up to 450 mg/day by 2007. He was on regular follow-up for 9 years during which he had fluctuations in psychiatric symptoms but was managing well without any physical health issues.

In 2016, he developed pain in the left lumbar region following trivial trauma (while using a crowbar) and later developed a swelling in the region for which incision and drainage were done at a primary health center. When the ulcer did not heal for about 3 months, he was referred to a surgical department of a teaching hospital for further management. The non-healing ulcer in the incision site of left lumbar gradually had increased in size and was associated with passage of air through the ulcer while defecating or straining. There was no history of abdominal distension, vomiting, obstipation, hematemesis, melena, or fever. Physical examination revealed a soft non-tender abdomen.

Address for correspondence: Dr. Dheeraj Kattula, Department of Psychiatry, Christian Medical College, Vellore - 632 002, Tamil Nadu, India. E-mail: askdheeraj@gmail.com

This is an open access journal, and articles are distributed under the terms of the Creative Commons Attribution-NonCommercial-ShareAlike 4.0 License, which allows others to remix, tweak, and build upon the work non-commercially, as long as appropriate credit is given and the new creations are licensed under the identical terms.

For reprints contact: reprints@medknow.com

How to cite this article: Kattula D, Jiwanmall SA, Sekaran BS, Sharma S. Silent colonic perforation and enterocutaneous fistula by a ball point pen 13 years after ingestion in a patient with schizophrenia. J Family Med Prim Care 2018;7:1093-5.

Access this article online

Quick Response Code:



Website:
www.jfmpc.com

DOI:
10.4103/jfmpc.jfmpc_132_18

Investigations

Roentgenogram of abdomen and ultrasonography investigations revealed a foreign body in the abdominal cavity just below the diaphragm without any other features of obstruction or perforation. Contrast-enhanced computer tomography and magnetic resonance imaging revealed a linear foreign body forming a fistula communicating with splenic flexure of the colon [Figure 1].

Treatment

The patient was posted for elective exploratory laparotomy. On laparotomy, an intact ball point pen of size about 11 cm in length was found to be the foreign body with its tip inside the lumen of splenic flexure and its rear end facing the external ulcer [Figure 2]. The pen was carefully delivered through the external wound and the sealed perforation of size 1 × 1 cm was closed primarily [Figure 3]. Postoperative period was uneventful and the patient was discharged on the 11th postoperative day.

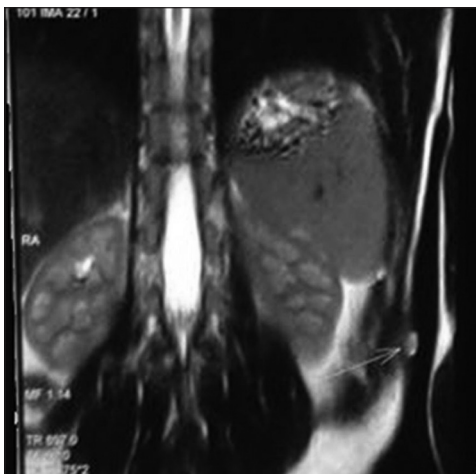


Figure 1: Magnetic Resonance of Abdomen revealed fistulous tract communicating with bowel [splenic flexure]

Outcome and follow-up

The patient recollected that he had swallowed the very same pen in 2004 when he had been very psychotic [Figure 4]. He reported that he had vague abdomen pain on and off, which he did not feel serious enough to report. There was no record of abdomen pain in the patient's case notes over the previous 13 years.

He is doing physically well and is on regular follow-up. He is not regularly employed but helps his family in household chores. He is currently on clozapine 450 mg/day, on which he has a serum level was 933 ng/mL.

Discussion

There are many cases of intentional foreign body ingestion. A retrospective case series of 292 patients with foreign body ingestion found 92% to be voluntary and 85% of them to have psychiatric diagnosis.^[1] Ingestion of foreign bodies has been seen in many cases of schizophrenia. Patients may ingest these secondary to psychosis due to delusional beliefs or command auditory hallucinations.^[2] Sometimes they may ingest them compulsively.^[3] Psychiatric patients may not give history of having swallowed foreign bodies.^[4] Even though 99% of swallowed

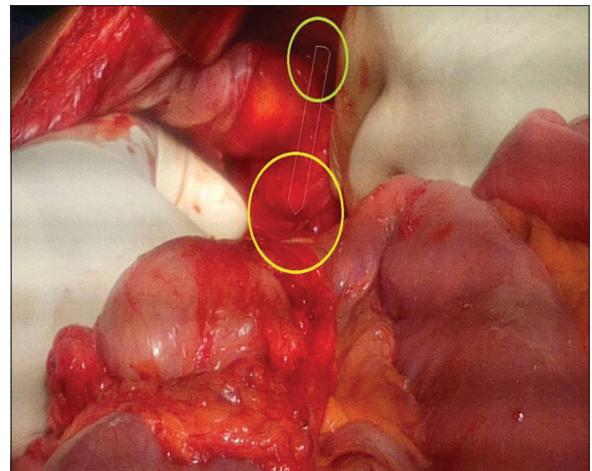


Figure 2: 11 cm long ball point pen was found to be the foreign body with its tip inside the lumen of splenic flexure and its rear end facing the external ulcer

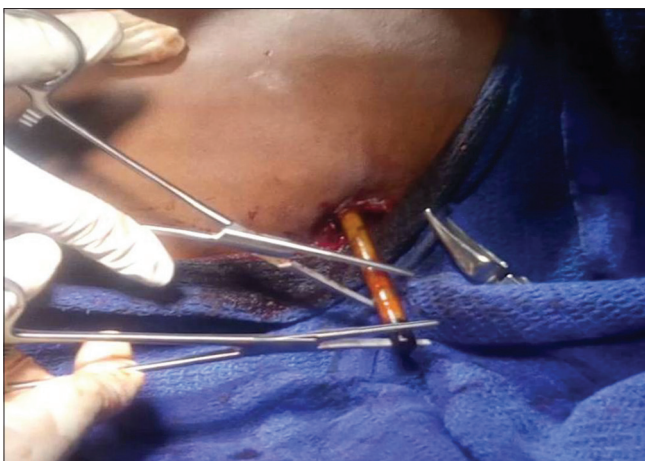


Figure 3: Delivery of pen through external wound

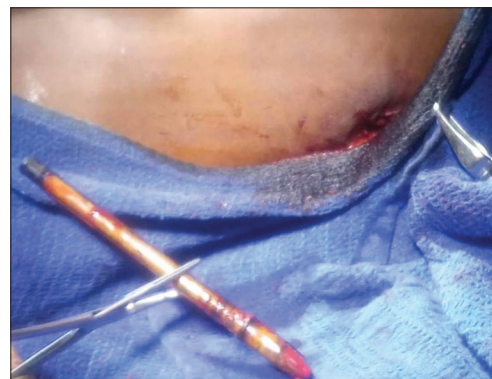

Figure 4: The foreign body after delivery- ball point pen

foreign bodies do not require surgical management,^[5] sometimes they can be fatal.^[6]

Ingested foreign bodies larger than 6 × 2.5 cm usually do not pass the stomach.^[5] The common complications encountered are obstruction, perforation, hemorrhage, sepsis, abscess, and internal fistula formation. The common sites of perforation in the descending order are oesophagus, ileum, caecum, sigmoid colon, duodenum, and stomach. There is a case of swallowed ball point pen having perforated duodenum.^[7] A patient with schizophrenia who had intestinal perforation after having swallowed a metallic skewer has also been reported.^[8] Perforation in large intestine is very rare. To the best of our knowledge, this is the first report of a case where a forgotten ingested pen stayed dormant inside the gut for 13 years caused a perforation of transverse colon but without causing symptoms of bowel perforation created an enterocutaneous fistula and presented as an ulcer on abdominal wall [Figure 5].

Learning points/take-home messages

1. The important lessons that can be learnt from the case are that physical complaints by mentally ill patients in primary health setups are not to be ignored and must be assumed to be organic till evidence to contrary is obtained
2. Ingested foreign body should be one of the differential diagnoses for patients with gastrointestinal symptoms in patients with mental illness
3. Swallowed foreign bodies can stay dormant in the body for prolonged periods of time before they cause any symptoms

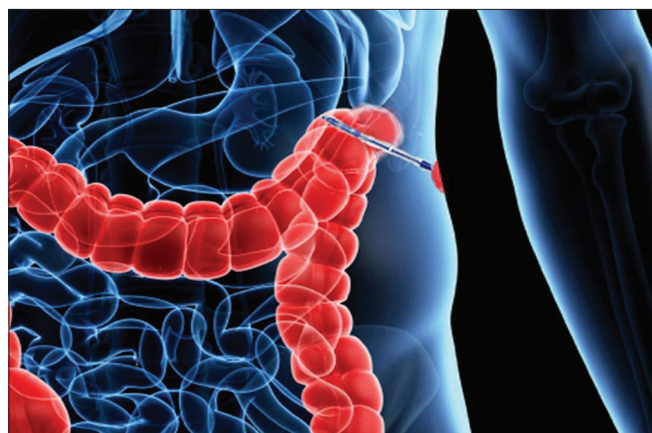


Figure 5: Schematic diagram of ball point pen causing perforation and enterocutaneous fistula at the level of splenic flexure

4. It is possible for objects as large as 11 cm to cross duodenum and reach the splenic flexure of the colon.

Declaration of patient consent

The authors certify that they have obtained all appropriate patient consent forms. In the form the patient(s) has/have given his/her/their consent for his/her/their images and other clinical information to be reported in the journal. The patients understand that their names and initials will not be published and due efforts will be made to conceal their identity, but anonymity cannot be guaranteed.

Financial support and sponsorship

Nil.

Conflicts of interest

There are no conflicts of interest.

References

1. Palta R, Sahota A, Bemarki A, Salama P, Simpson N, Laine L. Foreign-body ingestion: Characteristics and outcomes in a lower socioeconomic population with predominantly intentional ingestion. *Gastrointest Endosc* 2009;69:426-33.
2. Abraham B, Alao AO. An unusual foreign body ingestion in a schizophrenic patient: Case report. *Int J Psychiatry Med* 2005;35:313-8.
3. Han SY, McElvein RB, Aldrete JS. Compulsive ingestion of foreign bodies in a schizophrenic patient. *South Med J* 1984;77:784-6.
4. Khondker NS, Islam DN. A case of swallowed surprising foreign bodies in a young psychotic man. *Mymensingh Med J* 2013;22:578-80.
5. Ambe P, Weber SA, Schauer M, Knoefel WT. Swallowed foreign bodies in adults. *Dtsch Arzteblatt Int* 2012;109:869-75.
6. Di Nunno N, Di Nunno C, Costantinides F, Garzya V, Bernasconi P, Siciliano C, *et al.* Aorto-oesophageal fistula and intestinal infarction secondary to volvulus following ingestion of foreign bodies in a schizophrenic patient. *Med Sci Law* 2000;40:350-7.
7. Golfier C, Holguin F, Kobayashi A. Duodenal perforation because of swallowed ballpoint pen and its laparoscopic management: Report of a case. *J Pediatr Surg* 2009;44:634-6.
8. Zarei M, Shariati B, Bidaki R. Intestinal perforation due to foreign body ingestion in a schizophrenic patient. *Int J High Risk Behav Addict* 2016;5: e30127.