

[ CASE REPORT ]

## A 10-year History of a Diminutive Rectal Neuroendocrine Tumor

Katsuyuki Murai, Kenichiro Imai, Kinichi Hotta, Sayo Ito,  
Yuichiro Yamaguchi and Hiroyuki Ono

### Abstract:

A 39-year-old woman underwent a preoperative diagnostic colonoscopy for cervical cancer. A 3-mm neuroendocrine tumor (NET) was incidentally detected in the rectum. The NET was observed via 7 colonoscopies over 10 years while giving priority to treating the cervical cancer. Complete cervical cancer remission was confirmed at the 10-year follow-up examination; therefore, endoscopic treatment for the NET was subsequently performed. The NET showed almost no change in either size or morphology over the 10-year period. This case illustrates the possible very-slow progression of a small NET, suggesting its benign behavior.

**Key words:** neuroendocrine tumors, rectal tumors, colonoscopy, colonoscopic surgery

(Intern Med 57: 677-679, 2018)

(DOI: 10.2169/internalmedicine.9366-17)

### Introduction

Neuroendocrine tumors (NETs) are neoplasms that arise from cells of the endocrine and nervous system. Gastrointestinal NETs account for more than 60% of all NETs, and rectal NETs are estimated to constitute 12-36% of gastrointestinal NETs (1-3). The recent widespread application of screening colonoscopy has resulted in an increased detection rate of small, asymptomatic NETs of the rectum worldwide (3-9). Small, localized rectal NETs are considered entirely benign; however, the long-term history of NETs has not been reported.

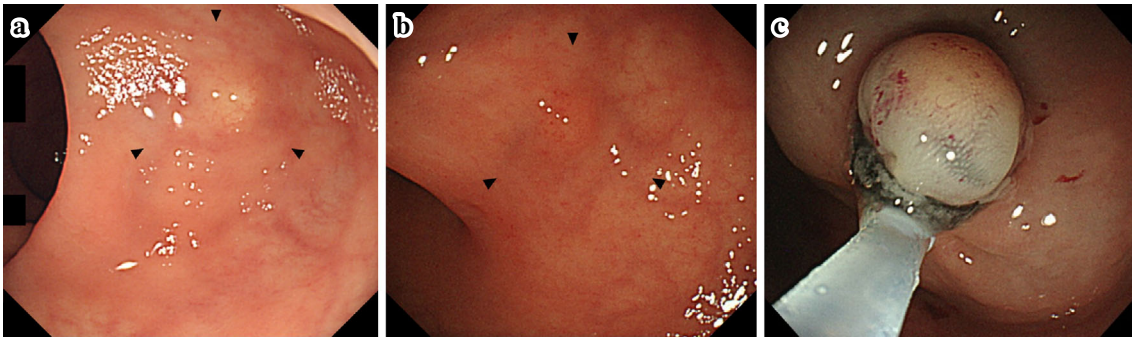
We herein report a case of rectal NET monitored in the rectum with periodic endoscopic examinations for 10 years.

### Case Report

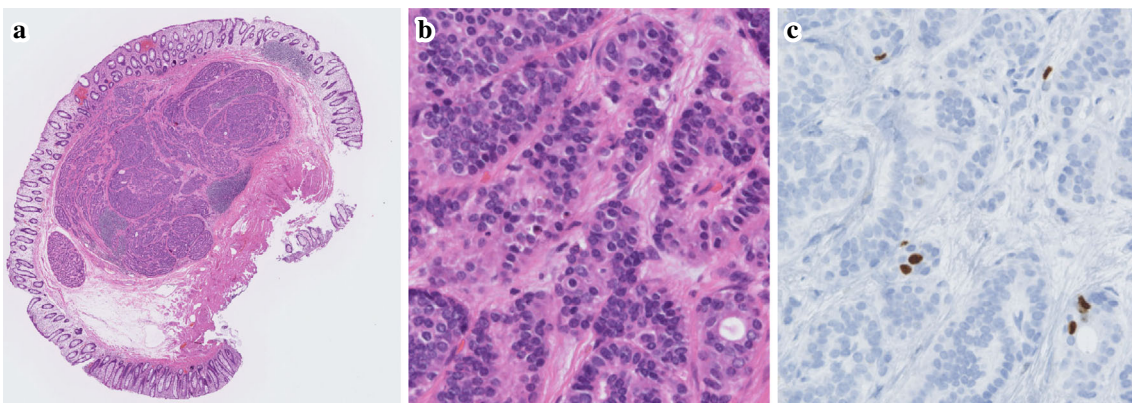
A 39-year-old woman underwent a preoperative diagnostic colonoscopy for cervical cancer. A 3-mm, smooth, round, sessile elevation covered with normal-appearing, yellowish-discolored mucosa was incidentally detected in the rectum (Fig. 1a). The histological evaluation of a biopsy specimen revealed a NET that was positive for chromogranin A, synaptophysin, and CD56. Computed tomography (CT) showed

no definite rectal lesion or metastasis. After extended hysterectomy following neoadjuvant chemotherapy (two cycles of cisplatin and irinotecan) for the cervical cancer, annual surveillance tests were performed with no adjuvant chemotherapy. During surveillance, the NET was observed via 7 colonoscopies over 10 years while giving priority to treating the cervical cancer. The NET showed almost no change in either size or morphology (Fig. 1b). Chest radiography and abdominal CT were also performed with the aim of postoperative surveillance of the cervical cancer every year. These revealed no definite rectal lesions or metastasis.

Complete cervical cancer remission was confirmed at the 10-year follow-up examination; therefore, treatment for the NET was planned. Endoscopic ultrasound (EUS) revealed that the lesion was limited to the submucosal layer; endoscopic submucosal resection with a ligation device was therefore performed (Fig. 1c). After submucosal injection, the lesion was lifted satisfactorily. In the ulcer bed, no apparent remaining tumor or perforation was observed. Resection was completed without any complications. The pathological diagnosis was NET, grade 1, 3×3 mm, pT1b, without lymphovascular permeation and with negative lateral and vertical margins. The Ki-67 index was 1.0%, and mitosis was absent (Fig. 2). The metastatic risk was considered sufficiently low, so the patient is being observed without addi-



**Figure 1.** a: White-light image at the initial colonoscopy showed a 3-mm, smooth, round, sessile elevation covered with normal-appearing, yellowish-discolored mucosa in the lower rectum (arrows). The lesion had no depression. b: The NET lesion at the 10-year follow-up colonoscopy (arrows). c: Endoscopic submucosal resection with a ligation device was performed. NET: neuroendocrine tumor



**Figure 2.** a: Microscopic image of the specimen showed a 3-mm tumor confined to the submucosa with negative lateral and vertical margins. No lymphovascular permeation was observed [Hematoxylin and Eosin (H&E) staining]. b: Mitosis was nearly absent (H&E staining). c: Ki-67 immunohistochemical stain showed few positive cells (Ki-67 index 1.0%).

tional surgery (10, 11). She has been relapse-free for more than two years at this point.

## Discussion

According to the 2010 World Health Organization (WHO) classification, NETs are classified as either NET grade 1 (G1), NET grade 2 (G2), or neuroendocrine carcinoma (12). Tumors previously diagnosed as carcinoid correspond to NET G1 and G2 (13). The rectum is the third-most common site of gastrointestinal NET, and rectal NETs are known to be less aggressive, with a 5-year survival rate of 88.3% for all stages of tumors (3). In a multicenter study of 407 cases of endoscopically resected rectal NETs, during a median follow-up period of 45.0 months, local recurrence occurred in only 3 (0.74%) patients, and there was no recurrence in the lymph nodes or distant organs (14). Small, localized rectal NETs are therefore considered entirely benign; however, the long-term history of NETs with periodic endoscopic examinations has not been reported. To our knowledge, this is the first report describing the 10-year long-term history of a localized rectal NET left in the rectum.

Unfortunately, we did not perform EUS examinations at the initial or surveillance colonoscopies. EUS was performed only just before endoscopic resection. However, the NET showed almost no change in either size or morphology on white-light images of the colonoscopies. The tumor size and morphology were considered to have minimal artifacts because no additional biopsies were performed during follow-up. In this regard, we cannot ignore the possible tumor-suppression effects of neoadjuvant chemotherapy for the patient's cervical cancer. However, any such effects are considered minimal, as it was performed for a very short term of two cycles and because NET is fundamentally considered a chemotherapy-resistant tumor. Fluorouracil, streptozocin, and doxorubicin are usually selected as chemotherapy for metastatic NETs, but there have been no comparative studies showing a significant improvement in the progression-free survival (PFS) or overall survival with this regimen. In previous studies, streptozocin was used in combination with fluorouracil, and the chemotherapy's response rate was only 15-33%, with a median PFS of 5.3-8 months (15-17).

This case showed minimal morphological changes of a

small, localized rectal NET over a 10-year period, suggesting its benign behavior. A long period of follow-up is required to clarify the details of lymph node metastasis from localized NETs in non-surgical patients. Recently, extremely low incidences of metastasis were reported within five years after resection of localized NETs (18). In another report, lymphovascular invasion was identified in 46.7% (42/90 lesions) of rectal small NETs G1 treated by endoscopic resection and confined to the submucosal layer. Although these patients were followed up without additional surgery, no metastases or recurrence were detected during the median follow-up period of 67.5 months (19). In contrast, of the 98 surgically resected NET G1 cases <10 mm in size, 9 (9.2%) had lymph node metastasis (20). With only a few years of follow-up, we may not be able to detect metastasis or recurrence clearly because NETs may grow extremely slowly even if they are metastatic. This case also suggests the need for follow-up data over a longer period to assess the true frequency of metastasis from localized NETs.

We agree with the guidelines that all NETs should be removed and be cured (21). In this case, the rectal NET was not removed but only observed, likely because the gastrointestinal endoscopists' recommendations were insufficient and the gynecologists did not recognize the need for the removal of the rectal NET lesion. First, NET in the gynecologic region is rare, with NET of the cervix accounting for 1.5% of cervical malignancies (22) and NET of the ovary for less than 0.1% of ovarian malignancies (3). Second, reported cases of NET in the gynecologic region have shown a very poor clinical survival and may correspond to neuroendocrine carcinoma (22). These findings suggest that gynecologists may not be familiar with the behavior and possible clinical course of small rectal NETs. Given the above, this case suggests that gastroenterologists should provide appropriate recommendations concerning the management of patients with small gastrointestinal NETs when the attending physician is not a gastroenterologist.

**The authors state that they have no Conflict of Interest (COI).**

## References

- Godwin JD 2nd. Carcinoid tumors. An analysis of 2837 cases. *Cancer* **36**: 560-569, 1975.
- Modlin IM, Sandor A. An analysis of 8305 cases of carcinoid tumors. *Cancer* **79**: 813-829, 1997.
- Modlin IM, Lye KD, Kidd M. A 5-decade analysis of 13,715 carcinoid tumors. *Cancer* **97**: 934-959, 2003.
- Yao JC, Hassan M, Phan A, et al. One hundred years after "carcinoid": epidemiology of and prognostic factors for neuroendocrine tumors in 35,825 cases in the United States. *J Clin Oncol* **26**: 3063-3072, 2008.
- Scherubl H. Rectal carcinoids are on the rise: early detection by screening endoscopy. *Endoscopy* **41**: 162-165, 2009.
- Ito T, Sasano H, Tanaka M, et al. Epidemiological study of gastroenteropancreatic neuroendocrine tumors in Japan. *J Gastroenterol* **45**: 234-243, 2010.
- Ellis L, Shale MJ, Coleman MP. Carcinoid tumors of the gastrointestinal tract: trends in incidence in England since 1971. *Am J Gastroenterol* **105**: 2563-2569, 2010.
- Lawrence B, Gustafsson BI, Chan A, et al. The epidemiology of gastroenteropancreatic neuroendocrine tumors. *Endocrinol Metab Clin North Am* **40**: 1-18, 2011.
- Tsai HJ, Wu CC, Tsai CR, et al. The epidemiology of neuroendocrine tumors in Taiwan: a nation-wide cancer registry-based study. *PLoS One* **8**: e62487, 2013.
- Hotta K, Shimoda T, Nakanishi Y, et al. Usefulness of Ki-67 for predicting the metastatic potential of rectal carcinoids. *Pathol Int* **56**: 591-596, 2006.
- Sugimoto S, Hotta K, Shimoda T, et al. The Ki-67 labeling index and lymphatic/venous permeation predict the metastatic potential of rectal neuroendocrine tumors. *Surg Endosc* **30**: 4239-4248, 2016.
- Bosman FT, Carneiro F, Hruban RH, et al. WHO classification of tumors of the digestive system. World Health Organization, Geneva, 2010.
- Rindi G, Petrone G, Inzani F. The 2010 WHO classification of digestive neuroendocrine neoplasms: a critical appraisal 4 years after its introduction. *Endocr Pathol* **25**: 186-192, 2014.
- Moon CM, Huh KC, Jung SA, et al. Long-term clinical outcomes of rectal neuroendocrine tumors according to the pathologic status after initial endoscopic resection: a KASID multicenter study. *Am J Gastroenterol* **111**: 1276-1285, 2016.
- Moertel CG, Hanley JA. Combination chemotherapy trials in metastatic carcinoid tumor and the malignant carcinoid syndrome. *Cancer Clin Trials* **2**: 327-334, 1979.
- Engstrom PF, Lavin PT, Moertel CG, et al. Streptozocin plus fluorouracil versus doxorubicin therapy for metastatic carcinoid tumor. *J Clin Oncol* **2**: 1255-1259, 1984.
- Sun W, Lipsitz S, Catalano P, et al. Eastern Cooperative Oncology Group. Phase II/III study of doxorubicin with fluorouracil compared with streptozocin with fluorouracil or dacarbazine in the treatment of advanced carcinoid tumors: Eastern Cooperative Oncology Group Study E1281. *J Clin Oncol* **23**: 4897-4904, 2005.
- Kim GU, Kim KJ, Hong SM, et al. Clinical outcomes of rectal neuroendocrine tumors ≤10 mm following endoscopic resection. *Endoscopy* **45**: 1018-1023, 2013.
- Sekiguchi M, Sekine S, Sakamoto T, et al. Excellent prognosis following Endoscopic resection of patients with rectal neuroendocrine tumors despite the frequent presence of lymphovascular invasion. *J Gastroenterol* **50**: 1184-1189, 2015.
- Kojima M, Ikeda K, Saito N, et al. Neuroendocrine tumors of the large intestine: clinicopathological features and predictive factors of lymph node metastasis. *Front Oncol* **6**: 173, 2016.
- Klöppel G, Couvelard A, Perren A, et al. ENETS Consensus Guidelines for the Standards of Care in Neuroendocrine Tumors: towards a standardized approach to the diagnosis of gastroenteropancreatic neuroendocrine tumors and their prognostic stratification. *Neuroendocrinology* **90**: 162-166, 2009.
- Margolis B, Tergas AI, Chen L, et al. Natural history and outcome of neuroendocrine carcinoma of the cervix. *Gynecol Oncol* **141**: 247-254, 2016.

The Internal Medicine is an Open Access article distributed under the Creative Commons Attribution-NonCommercial-NoDerivatives 4.0 International License. To view the details of this license, please visit (<https://creativecommons.org/licenses/by-nc-nd/4.0/>).