

Available online at [www.sciencedirect.com](http://www.sciencedirect.com)

ScienceDirect

journal homepage: [www.elsevier.com/locate/radcr](http://www.elsevier.com/locate/radcr)

## Case Report

# Posterior lumbar subcutaneous edema as the rare sign of IgA vasculitis (Henoch-Schönlein purpura): A case of a child ☆☆☆★

Toshinori Yasumura, MD<sup>a,\*</sup>, Tetsuya Katsumori, MD<sup>a</sup>, Osamu Kizu, MD<sup>a</sup>, Hiromu Umehara, MD<sup>b</sup>, Yoshitomo Nakai, MD<sup>c</sup>

<sup>a</sup> Department of Radiology, Saiseikai Shiga Hospital, Ohashi 2-4-1, Ritto, Shiga, 520-3046, Japan

<sup>b</sup> Department of Pediatrics, Saiseikai Shiga Hospital, Ohashi 2-4-1, Ritto, Shiga, 520-3046, Japan

<sup>c</sup> Department of Radiology, Kyoto Prefectural University of Medicine, 465 Kajii-cho, Kawaramachi-Hirokoji, Kyoto, 602-8566, Japan

## ARTICLE INFO

## Article history:

Received 1 December 2020

Accepted 6 December 2020

## Keywords:

Posterior lumbar subcutaneous edema

IgA vasculitis

Henoch-Schönlein purpura

MRI

CT

Children

## ABSTRACT

Posterior lumbar subcutaneous edema (PLSE) is often found on MRI in adults with obesity or various lumbar conditions. We report a case of a 6-year-old boy with IgA vasculitis (Henoch-Schönlein purpura) along with PSLE observed on CT and MRI. The finding is markedly rare in patients with IgA vasculitis, with only limited cases previously reported in the literature. The edema was symmetrically localized along the erector spinae muscle with a smooth margin. These findings differed from the irregularly accumulated edema observed in some adult cases. PLSE should not be overlooked as a nonspecific finding. When symmetrical and circumscribed PLSE is found in children, IgA vasculitis should be added to differential diagnosis in PLSE.

© 2020 The Authors. Published by Elsevier Inc. on behalf of University of Washington.

This is an open access article under the CC BY-NC-ND license

(<http://creativecommons.org/licenses/by-nc-nd/4.0/>)

## Introduction

Posterior lumbar subcutaneous edema (PLSE) is incidentally found in adults on several imaging tools such as magnetic resonance image (MRI) or computed tomography (CT) [1–3]. The rates of such radiographic findings were reported to range

from 29.7% to 40.1% in adults [2,3]. Although PLSE is considered an incidental finding associated with obesity or various lumbar disorders [1–3], the clinical significance of these findings remains unclear as it is usually not treated. Furthermore, the etiology of PLSE has not been established. In addition to obesity and lumbar disorders, PLSE is sometimes found as a sequela secondary to trauma, previous surgery or

☆ Competing interest: None of the authors have identified a conflict of interest.

☆☆ Funding: No funding was received for this study from any companies or organizations.

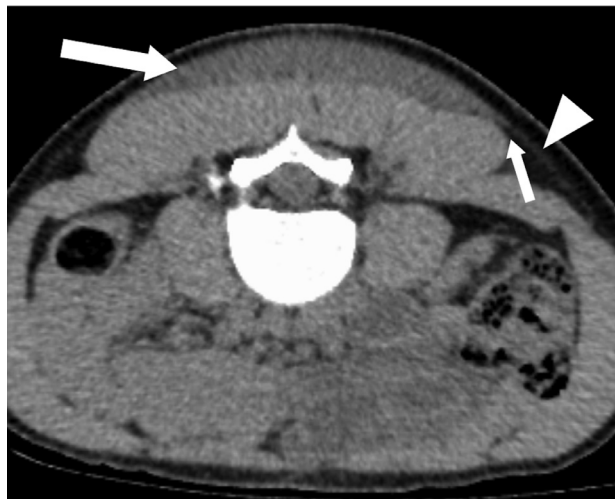\* Acknowledgments: We would like to thank Dr. Tatsuya Yoshikawa, Department of Radiology, Saiseikai Shiga Hospital, for preparation of this manuscript.

\* Corresponding author.

E-mail address: [yasumura@koto.kpu-m.ac.jp](mailto:yasumura@koto.kpu-m.ac.jp) (T. Yasumura).

<https://doi.org/10.1016/j.radcr.2020.12.016>

1930-0433/© 2020 The Authors. Published by Elsevier Inc. on behalf of University of Washington. This is an open access article under the CC BY-NC-ND license (<http://creativecommons.org/licenses/by-nc-nd/4.0/>)

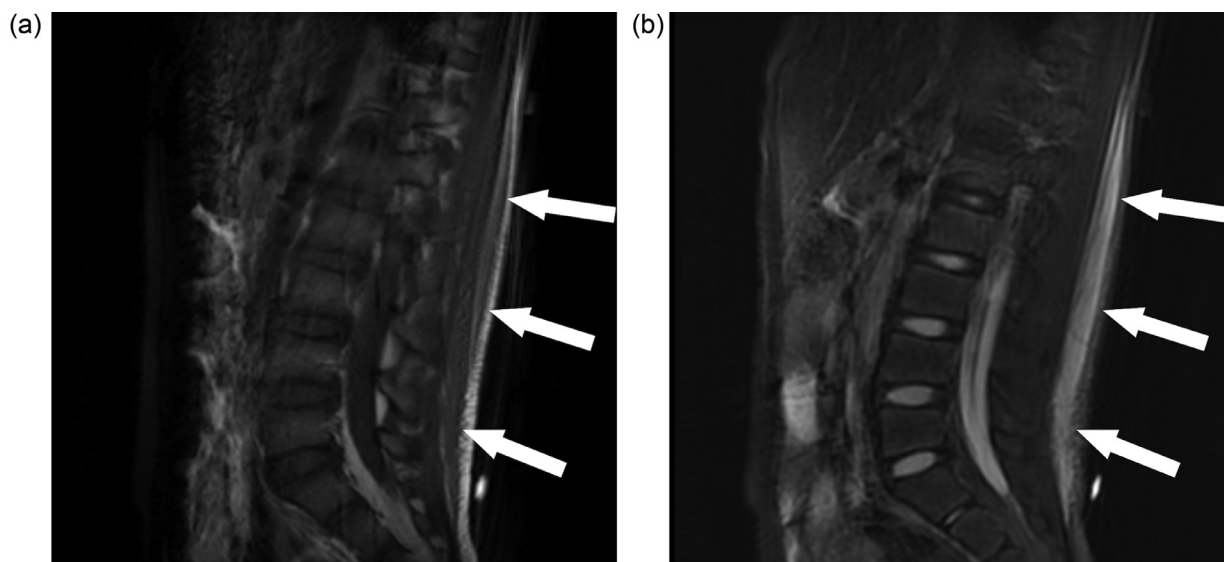


**Fig. 1 – Axial abdominal CT image showing fluid collection (long arrow) as a low-dense, symmetrically localized area along the erector spinae muscle. Note a small gap (short arrow) between the superficial fascia (arrowhead) and erector spinae muscle.**

interventional therapy, and infectious infiltration [3]. We describe a case of a 6-year-old boy with PLSE observed on CT and MRI. The patient had IgA vasculitis (Henoch-Schönlein purpura) causing subcutaneous edema, but PLSE is markedly rare in patients with IgA vasculitis. The present case report discusses the clinical significance of these radiographic findings.

## Case report

A 6-year-old boy presented to our hospital due to the sudden onset of severe back pain accompanied by marked swelling of the lumbar back. The patient was unable to walk because of bilateral knee joint pain and right leg edema. Although he had no history of trauma, the orthopedic surgeon suspected the back swelling and pain to be caused by subcutaneous hematoma secondary to potential trauma or blood diseases. Blood examination revealed no abnormality in the platelet count or coagulation fibrinolysis factors. On abdominal CT, the fluid collection was observed as a low-dense, symmetrically localized area along the erector spinae muscle with a smooth and clear margin (Fig. 1). These features differed from those of typical hematoma or abscess. Moreover, these were unlike the edema that was irregularly accumulated along the superficial fascia in some previous reports [2–4]. On lumbar MRI, the space occupied by the lesion had a low signal on T1-weighted images and high signal on T2-weighted images, corresponding to edema and fluid collection, that is, PLSE (Fig. 2). The patient subsequently developed palpable purpura on the legs and arms, abdominal pain, nausea, and exacerbated swelling of the leg and arm joints. Additional blood examination also revealed that the factor XIII level slightly decreased. As these findings fulfilled the criteria of IgA vasculitis [5,6], the pediatrician diagnosed the patient with IgA vasculitis. Based on the clinical diagnosis, the PLSE observed on CT and MRI may have been associated with IgA vasculitis. No renal disorder was noted. The back swelling rapidly improved and the other clinical symptoms gradually improved without medication after one month. At 2 months after the onset of symptoms, he was free from clinical symptoms.



**Fig. 2 – Sagittal lumbar MRI demonstrated posterior lumbar subcutaneous edema and fluid collection (arrows) in the posterior lumbar subcutaneous soft tissue. The lesion had a low signal on T1-weighted image (a) and high signal on fat suppression T2-weighted image (b).**

---

## Discussion

PLSE was previously reported as an incidental finding associated with obesity or various lumbar conditions based on the results of several observational studies with a large sample size of adults with >13 years old [1–3]. In contrast, there are limited reports regarding PLSE with radiographic imaging in children [5–7]. In the present case, PLSE was found on CT and MRI in a 6-year-old child with IgA vasculitis. This case is similar to the previous 3 case reports regarding children, which suggested that PLSE is related to IgA vasculitis in children [5–7]. In addition, the PLSE finding improved along with the other symptoms related to IgA vasculitis; therefore, we considered the current findings to be associated with IgA vasculitis in this case.

IgA vasculitis mainly involves in childhood and includes palpable purpura, arthralgias, abdominal pain, and renal disorders. Subcutaneous edema is also commonly observed and often involves the hands, ankles, and feet [8]. However, PLSE is a marked rare finding in patients with IgA vasculitis [5–7]. To our knowledge, only three cases were previously reported [5–7]. We think the radiographic finding is important because PLSE can be an early sign before major findings of IgA vasculitis are manifested. Also, this radiographic sign can be expected to aid in early detecting underlying IgA vasculitis.

There are many reported potential causes of PLSE, including infectious, inflammatory, traumatic, hydrostatic, and even neoplastic causes. Subcutaneous edema in patients with IgA vasculitis was reported to be due to be acute, small-vessel vasculitis [9]. Regarding the present case, PLSE may have been induced by inflammation associated with IgA vasculitis. In the present case, CT demonstrated that the edema was symmetrically accumulated and circumscribed along erector spine muscle, suggesting that the existing structure of surrounding tissues is relatively preserved. This may be a key diagnostic feature of IgA vasculitis, which aids in differentiating more destructive diseases like trauma. The histopathological findings of the subject can have provided additional valuable information regarding PLSE; however, as the back swelling rapidly improved, and MRI and CT did not suggest potential malignancy in the present case, we did not obtain the specimen for histopathological examination, resulting in no radiological and histopathological correlations.

In summary, based on the present case and previous reports, we consider that PLSE should not be overlooked as a non-specific finding. In particular, when symmetrical and circumscribed PLSE is found on CT or MRI in children, IgA vasculitis should be added to differential diagnosis in PLSE. The

knowledge regarding PLSE will aid in avoiding unnecessary further examinations and quickly making a definitive diagnosis, leading to appropriate medical care.

---

## Informed consent

We obtained written informed consent for the retrospective use of medical data and publication from patient's parent.

---

## IRB approval

Institutional review board in the institution approved the publication of this case.

---

## REFERENCES

- [1] Shi H, Schweitzer ME, Carrino JA, Parker L. MR imaging of the lumbar spine: relation of posterior soft-tissue edema-like signal and body weight. *AJR Am J Roentgenol* 2003;180:81–6.
- [2] Quattrocchi CC, Giona A, Di Martino A, Gaudino F, Mallio CA, Errante Y, et al. Lumbar subcutaneous edema and degenerative spinal disease in patients with low back pain: a retrospective MRI study. *Musculoskelet Surg* 2015;99(2):159–63.
- [3] Nemeč US, Friedrich KM, Arnoldner MA, Schwarz FK, Weber M, Trattng S, et al. When an incidental MRI finding becomes a clinical issue. *Wiener klinische Wochenschrift* 2020;132:27–34.
- [4] Verger AA, Pillebout E, Guillevin L, Thervet E, Terrier B. IgA vasculitis (Henoch-Schönlein purpura) in adults: diagnostic and 3 therapeutic aspects. *Autoimmun Rev* 2015;14(7):579–85.
- [5] Schaefer B, Soprano C. Five-year-old boy presenting with severe back pain, swelling, and refusal to walk. *Clin Pediatr* 2014;53(1):95–7.
- [6] Duman MA, Duru NS, Çalıřkan B, Sandıkçı H, Çengel F. Lumbar swelling as the unusual presentation of Henoch-Schonlein Purpura in a child. *Balkan Med J* 2016;33(3):360–2.
- [7] Shimizu A, Shimabukuro M, Shimizu M, Asai S, Tomizawa S, Hatakeyama S, et al. Painful subcutaneous edema of the lumbar region in IgA vasculitis. *Pediatr Int* 2019;61:624–5.
- [8] Nussinovitch M, Prais D, Finkelstein Y, Varsano I. Cutaneous manifestations of Henoch-Schönlein purpura in young children. *Pediatr Dermatol* 1998;5:426–8.
- [9] Lava SAG, Milani GP, Fossali EF, Simonetti GD, Agostoni C, Bianchetti MG. Cutaneous manifestations of small-vessel leukocytoclastic vasculitides in childhood. *Clin Rev Allergy Immunol* 2017;53(3):439–51.