

Far-lateral Transcondylar Approach to Anterior Foramen Magnum Lesions - Our Experience

Abstract

Background: Initial surgical management of the anterior foramen magnum lesions through the posterior approaches was fraught with unacceptable morbidity, mortality, and incomplete removal. The far-lateral approach provides excellent exposure and access to these lesions resulting in complete excision of these lesions with reduced frequency of unwanted complications. **Materials and Methods:** Eight patients with lesions anterior to the brainstem and upper cervical cord were surgically treated using the far-lateral transcondylar approach. Two of these patients had a meningioma while three patients had “white epidermoid.” One patient had a vertebral artery (VA) aneurysm while another was a rare case of lower brainstem compression by the VA and the last was a clival chordoma. The technical aspects of this surgical procedure are briefly illustrated in this article. **Results:** Total excision was achieved in five neoplastic cases while subtotal excision was done in one case. The VA aneurysm was satisfactorily clipped while in the brainstem compression patient, microvascular decompression was done. The VA aneurysm patient developed postoperative lower cranial nerve palsies. There were no fresh postoperative deficits in any of the other patients. One patient had an unexplained sudden cardiorespiratory arrest 18 h after the surgery and succumbed. One patient had cerebrospinal fluid (CSF) otorrhea which was satisfactorily managed by intrathecal CSF drainage. **Conclusion:** The far-lateral transcondylar approach provides excellent approach to lesions located anterior to the brainstem and upper cervical cord. Total excision of these benign lesions is safely possible through this approach.

Keywords: Craniovertebral junction, far-lateral transcondylar approach, foramen magnum, ventral brain stem, white epidermoid

Introduction

The anterior foramen magnum and craniocervical junction are a site for various neoplastic lesions such as meningioma, chordoma, epidermoid, neurofibroma, and vascular lesions such as a vertebral artery (VA) aneurysm. Initial surgical management of these lesions was fraught with morbidity and even mortality and incomplete removal due to the proximity of important neurovascular structures.^[1-3] However, development of lateral approaches has provided excellent exposure and access to these lesions resulting in complete excision of these lesions and reduced the frequency of unwanted complications. We present our short series of eight patients whom we treated using the far-lateral approach with excellent results in seven patients.

Materials and Methods

We treated eight patients [Table 1] - three males and five females, with lesions

anterior to the brainstem and cervical cord. Prior informed consent was taken from the patients and relatives regarding surgery and use of their data for research activities including scientific publications. There was no need to take a special permission from the institution as the surgery performed on these patients was a well-established standard procedure. Two of these lesions were meningiomas, three were epidermoids, one clival chordoma, and two were vascular lesions - one VA aneurysm and another was a rare case of brainstem compression by the VA loop. All patients underwent surgery through the far-lateral transcondylar approach, and gross total resection was achieved in five of the neoplastic cases. Subtotal excision was done in the patient with clival chordoma. VA aneurysm was clipped, and in the brain stem compression by a vascular loop, microvascular decompression was done. Five patients presented with neck pain, one patient with brainstem compression presented with severe spastic quadriparesis and the

**S. Balaji Pai,
G. Raghuram¹,
G. C. Keshav,
Elvis Rodrigues**

*Department of Neurosurgery,
Bangalore Medical College and
Research Institute, ¹Department
of Neurosurgery, Columbia Asia
Referral Hospital, Bengaluru,
Karnataka, India*

Address for correspondence:

Dr. S. Balaji Pai,
737, 14th Cross, Girinagar II
Phase, Bengaluru - 560 085,
Karnataka, India.
E-mail: balajipai65@yahoo.
co.in

Access this article online

Website: www.asianjns.org

DOI: 10.4103/ajns.AJNS_273_16

Quick Response Code:



How to cite this article: Pai SB, Raghuram G, Keshav GC, Rodrigues E. Far-lateral transcondylar approach to anterior foramen magnum lesions - Our experience. *Asian J Neurosurg* 2018;13:651-5.

This is an open access journal, and articles are distributed under the terms of the Creative Commons Attribution-NonCommercial-ShareAlike 4.0 License, which allows others to remix, tweak, and build upon the work non-commercially, as long as appropriate credit is given and the new creations are licensed under the identical terms.

For reprints contact: reprints@medknow.com

Table 1: Demography, approaches, complications, and pathology of the 8 patients having anterior foramen magnum lesions

Case number	Age/sex	Presentation	Preoperative diagnosis	Procedure	Complications	Histopathology
1	35/male	Neck pain	Epidermoid	Far-lateral transcondylar approach and gross total excision	Nil	Epidermoid
2	62/female	Neck pain	Meningioma	Far-lateral transcondylar approach and gross total excision	Paradoxical CSF rhinorrhea	meningioma
3	42/female	Neck pain	Meningioma	Far-lateral transcondylar approach and gross total excision	Nil	Meningioma
4	30/female	Neck pain	Epidermoid	Far-lateral transcondylar approach and gross total excision	Death	Epidermoid
5	58/male	Neck pain	Epidermoid	Far-lateral transcondylar approach and gross total excision	Nil	Epidermoid
6	40/female	Severe spastic quadriplegia	Vertebral artery loop compressing on brain stem	Far-lateral transcondylar approach and microvascular decompression	Nil	Not applicable
7	50/male	Subarachnoid hemorrhage	Vertebral artery aneurysm	Far-lateral transcondylar approach and clipping	Transient ipsilateral lower cranial nerve palsy	Not applicable
8	48/female	Bilateral lower cranial nerve palsy	Clival chordoma	Far-lateral transcondylar approach and subtotal excision	CSF otorrhea	Chordoma

CSF – Cerebrospinal fluid

VA aneurysm presented with subarachnoid hemorrhage. The patient with clival chordoma presented with bilateral lower cranial nerve palsy. MR imaging was done in all the patients, and a preoperative diagnosis of “white epidermoid” was made in three cases while meningioma was the imaging diagnosis in the other two cases. Digital subtraction angiogram was performed in the patient with VA aneurysm. All of them were confirmed histopathologically postoperatively. The operative technique adopted by us is described below.

Position

As in all neurosurgical procedures, position is of utmost importance in the outcome of the surgical procedure. We used a modified park-bench position. The patient is placed in the lateral position and supported with side supports, straps, and adhesive plaster so that the body is held tightly during any sideward tilt of the table if required. The contralateral arm is dropped and positioned below the level of the body in a dependent position, padded adequately and fixed to the horizontal bar of the Sugita Head Frame. The head is flexed, rotated, and laterally flexed by around 30 degrees to the opposite side so that the mastoid is at the highest position. The ipsilateral shoulder is pulled away from the field using adhesive plaster.

Incision

The side of the approach is dictated by the lateral extension of the lesion. We use a retroauricular curvilinear incision starting 2–3 cm above and behind the pinna and continues inferiorly to the neck over the posterior border of the sternocleidomastoid muscle to the level of C3 or C4.

Exposure

Muscle exposure

The muscles in this area are in three layers. The first superficial layer consists of trapezius and sternocleidomastoid. The middle layer consists of splenius capitis, longissimus capitis, and semispinalis capitis. Both these layers are incised, detached, and reflected as a single layer, and the suboccipital triangle is exposed. This triangle, the third layer, consists of the rectus capitis posterior major medially, inferior oblique inferiorly, and superior oblique superolaterally. Both the oblique muscles are attached to the C1 transverse process laterally; medially, the inferior oblique is attached to the C2 spinous process while the superior oblique is attached to the temporo-occipital suture. The triangle also contains the C1 nerve root and the horizontal part of the VA. The rectus is detached from the nuchal line and reflected posteriorly. The VA is surrounded by a venous plexus which has also been referred to as the suboccipital cavernous sinus.

Exposure of the vertebral artery

Exposure and control of the extradural VA are an important step in this approach. This is achieved by identifying the VA from its exit at the C2 foramen transversarium, between C2-C1 foramina, exit from C1 foramen, and over the C1 lateral mass vertebral groove to enter the dura mater. Some small branches from the VA to the adjacent muscles may be sacrificed.

Bone exposure

A lateral suboccipital craniectomy is performed followed by hemilaminectomy of C1. The extent of the

suboccipital craniectomy medially and superiorly depends on the extent of the lesion and the exposure required. The transverse-sigmoid junction may also be exposed if required. If further inferior exposure is required, hemilaminectomy of C2 and C3 may be done depending on the extent of the lesion. The posterior 30%–40% of the occipital condyle is drilled extradurally. This step helps in the angle of exposure and greater visualization of the ventral and ventrolateral aspect of the craniovertebral junction. In no instance was the VA transposed.

Dural opening

The dura is opened in a slightly curvilinear fashion. The dural flap is sutured to the adjacent muscles to maximize the exposure [Figure 1].

Tumor resection

The arachnoid is incised and pushed in a lateral to medial direction. A dural cuff is preserved around the VA. All the various lower cranial nerves and the VA are visualized [Figure 2]. In the case of a meningioma, the base was first coagulated and detached and the tumor was debulked using an ultrasonic surgical aspirator. The capsule and rest of the tumor are then removed after freeing it from the adjacent nerves, brainstem and the VA and basilar artery [Figure 3]. “White epidermoids” are creamish in color and consistency and total removal is easily achieved using only the suction. Total removal was achieved in all cases with no neurovascular injury. Perfect hemostasis could be easily achieved once total tumor removal was completed [Figure 4].

In vertebral artery aneurysm case

Satisfactory clipping was done after the application of temporary clip [Figure 5].

In vertebral artery loop compressing on brainstem case

Microvascular decompression was done using Teflon patch.

Closure

Dura was closed but not in a watertight fashion. However, it was covered with autologous fascial graft harvested from the neck and stuck to the dura using fibrin glue. This was further supplemented with free fat graft and gel foam. The exposed mastoid air cells are covered with bone wax. The muscle layers are approximated. We have not resorted to any intrathecal or wound drain.

Results

Total resection of lesion could be achieved in all cases of meningiomas and epidermoids. Subtotal excision of the clival chordoma was done. The VA aneurysm was satisfactorily clipped while in the brainstem compression by VA vascular loop, microvascular decompression was done. All the patients had an uneventful operative course. All were extubated at the completion of surgery. The VA

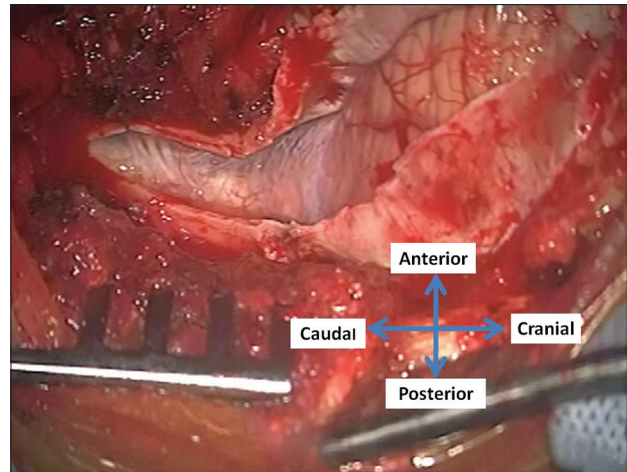


Figure 1: Operative photograph showing lateral suboccipital craniectomy and C1 hemilaminectomy. Dura opened and reflected anteriorly

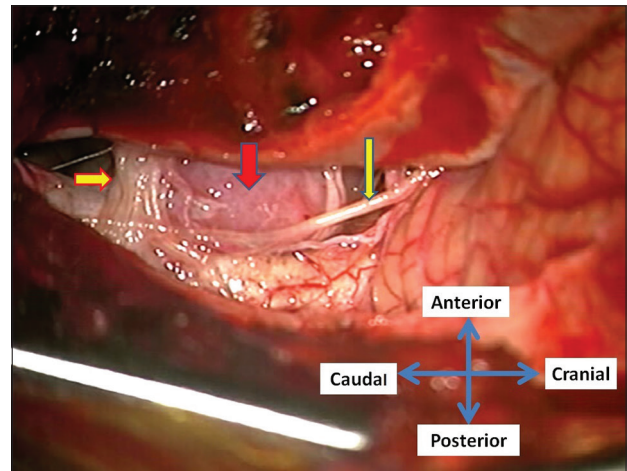


Figure 2: After opening the arachnoid, the anteriorly placed meningioma (red arrow) is seen. Also seen are the C1 root (thick yellow arrow) and spinal accessory nerve (thin yellow arrow)

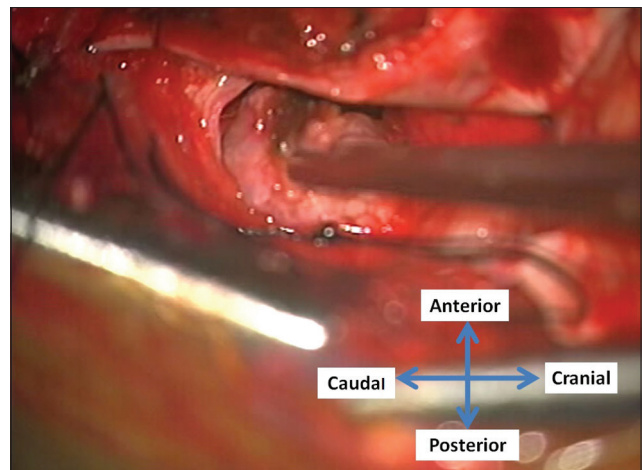


Figure 3: Tumor being delivered out after debulking with ultrasonic surgical aspirator

aneurysm patient had ipsilateral lower cranial nerve palsies which gradually improved. One female patient with an

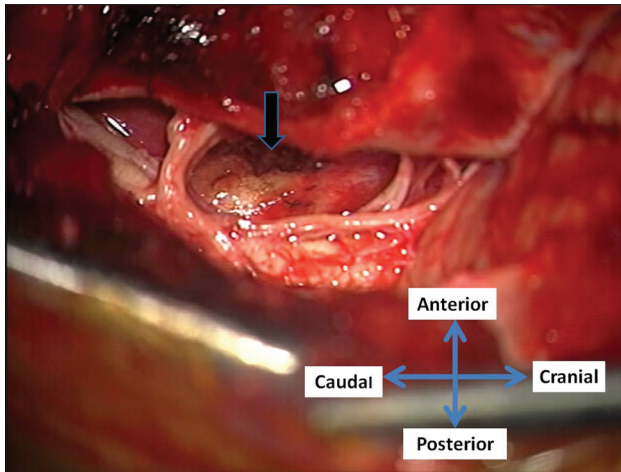


Figure 4: After total removal of the meningioma. The dural attachment (black arrow) is coagulated

epidermoid had a sudden unexplained cardiorespiratory arrest 18 h after the surgery from which she could not be revived. The prearrest events did not suggest any neurological cause. In another patient, a transient paradoxical cerebrospinal fluid (CSF) rhinorrhea occurred, while CSF otorrhea was encountered in another patient. Both the patients were successfully managed by intrathecal CSF drainage. No fresh neurological deficits or any other untoward complications were noted in any of the other patients.

Discussion

Anterior foramen magnum lesions, extending from the clivus to the upper spinal cord, have posed a challenge to neurosurgeons. Excision of these lesions through standard posterior approaches has been fraught with unacceptable morbidity and mortality.^[1] Moreover, total resection is usually not possible with the posterior approach. The far-lateral approach has helped in accessing the anterior and anterolateral corridor and complete excision of these benign lesions.^[4] It provides excellent exposure of the lateral aspect and anterior aspect of the brainstem and upper cervical spinal cord. The use of this approach for clipping of a VA-posterior inferior cerebellar artery (PICA) aneurysm has been reported.^[5]

The basic far-lateral approach, initially proposed by Heros, is a low suboccipital approach that extends up to but does not include removal of part of the condyles.^[1,6] This approach decreases cerebellar, brainstem, and upper cervical cord retraction required to visualize the structures anterior to the brainstem and upper cervical cord. Moreover, the tumor-brain interface is encountered early during surgery making separation of the neoplasm from the normal structures easier. The other added advantage is the early proximal control of the VA in case of vertebrobasilar aneurysms.^[5] Different nomenclatures for this approach have been used leading to significant confusion.^[2,7] Various

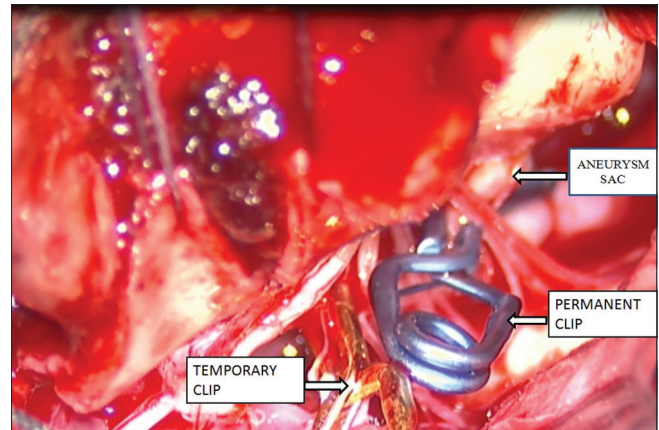


Figure 5: Permanent clip applied to the neck of the sac after application of temporary clip proximally on vertebral artery

modifications of this approach have been proposed by different authors. Some of these modifications include the following: (1) the transcondylar approach directed through the occipital condyle, (2) the supracondylar approach directed above the occipital condyle, and (3) the paracondylar approach directed through the area lateral to the occipital condyle.^[3,4]

Two types of incisions have been described - a posterolateral (horseshoe) flap starting from the ipsilateral mastoid tip and rising upward and curving medially and down to the C3; a curvilinear retromastoid incision curving anteriorly to the posterior border of the sternocleidomastoid at the level of C4-C5.^[8-10] The muscles are detached as described earlier. The transverse process of the C1 acts as a landmark to the surgeon in identifying the muscles and preventing VA injury. In the standard posterior and posterolateral approaches, a detailed knowledge of the suboccipital muscles is not essential. The far-lateral approach, however, requires a detailed knowledge of the suboccipital muscles since the deeper layer muscles are separated separately.

Knowledge of the suboccipital triangle and the position of the VA in the triangle as well as the common variants of the VA course are essential during the dissection of the extracranial VA. The portion of the VA between C2 foramen and the superolaterally placed C1 foramen should be dissected carefully as the VA may form a medial loop in this location. The V3 (horizontal portion of the VA) is encased by a venous plexus and is dissected subperiosteally to prevent any injury to the VA. The muscular and meningeal branches which arise from the VA may be sacrificed, but an uncommon extracranial origin of the PICA if present should be carefully preserved.^[4,9] Some of the authors advocate the transposition of the VA, but we have not found it to be necessary in our experience.

Lateral suboccipital craniectomy or a craniotomy is done. The suboccipital craniectomy should include the entire bulk of the lesion and should extend laterally up to the sigmoid sinus, and inferiorly, the rim of foramen magnum needs

to be excised.^[7] C1 hemilaminectomy is done using drill or rongeurs. This may be extended inferiorly to include C2 depending on the inferior extent of the lesions. In our series, C2 hemilaminectomy was performed in one case. Drilling the posterior third of the occipital condyle using the high-speed drill is an important step in this approach. Some authors have avoided drilling the condyle, especially in neoplasms which have already displaced the adjacent neurovascular structures.^[7,8] However, we advocate drilling of the occipital condyle in this approach as the angle of visualization is flattened by this step.^[9,11] The importance and utility of this step will be appreciated on opening the dura and reflecting the dural flap anteriorly. This is similar to the drilling of the sphenoid ridge in a pterional approach to make the exposure flat. Drilling the condyle more than 50% will cause instability necessitating occipito-cervical stabilization.^[9,11] Further, extradural drilling of the jugular tubercle has been proposed by some surgeons to increase visualization of the mid clivus and area in front of the brainstem in the midline.^[4]

A curvilinear dural incision helps in reflecting the anterior flap further laterally and increasing the anterior visualization.^[9,10] Superior and inferior extensions of the dural opening are determined by the extent of the lesion. A sharp arachnoid dissection is done, and the tumor-brain interface is usually well visualized. We have used an ultrasonic surgical aspirator for tumor debulking. The meningiomas that we encountered in this area were amenable to the usage of the ultrasonic surgical aspirator. The dural attachment was cauterized after total tumor removal. The epidermoids usually do not pose a surgical challenge as they are amenable for suction, especially the “white epidermoids.” Adequate precautions to prevent postoperative CSF leakage from the wound should be taken. The far-lateral approach has been modified and extended inferiorly and to excise anterior intradural and some extradural lesions in the cervical spine.^[11]

Conclusion

The far-lateral transcondylar approach is a very useful approach to lesions located ventrolateral and even ventral to the brainstem and upper cervical spinal cord. It provides excellent exposure to the lesion and adjacent

neurovascular structures with minimal or no retraction. Various modifications of this approach have been described and applied depending on the lesion and its extent. This approach provides hope for a surgical cure for these usually benign lesions which would otherwise prove to be fatal due to their critical location.

Financial support and sponsorship

Nil.

Conflicts of interest

There are no conflicts of interest.

References

1. Wen HT, Rhoton AL Jr, Katsuta T, de Oliveira E. Microsurgical anatomy of the transcondylar, supracondylar, and paracondylar extensions of the far-lateral approach. *J Neurosurg* 1997;87:555-85.
2. Liu JK, Rao G, Schmidt MH, Couldwell WT. Far lateral transcondylar transtuberular approach to lesions of the ventral foramen magnum and craniovertebral junction. *Contemp Neurosurg* 2007;29:1-7.
3. Arnautovic KI, Al-Mefty O, Husain M. Ventral foramen magnum meningiomas. *J Neurosurg* 2000;92 1 Suppl:71-80.
4. Rhoton AL Jr. Far lateral and transcondylar approaches. *Neurosurgery* 2007;61:S4-211-28.
5. Bragg TM, Duckworth EA. Contralateral far-lateral approach for clipping of a ruptured vertebral artery-posterior inferior cerebellar artery aneurysm. *Neurosurg Focus* 2008;25:E9.
6. Lanzino G, Paolini S, Spetzler RF. Far-lateral approach to the craniocervical junction. *Oper Neurosurg* 2005;57:367-71.
7. Boulton MR, Cusimano MD. Foramen magnum meningiomas: Concepts, classifications, and nuances. *Neurosurg Focus* 2003;14:e10.
8. Kumar CV, Satyanarayana S, Rao BR, Palur RS. Extreme lateral approach to ventral and ventrolaterally situated lesions of the lower brainstem and upper cervical cord. *Skull Base* 2001;11:265-75.
9. Babu RP, Sekhar LN, Wright DC. Extreme lateral transcondylar approach: Technical improvements and lessons learned. *J Neurosurg* 1994;81:49-59.
10. Sharma BS, Gupta SK, Khosla VK, Mathuriya SN, Khandelwal N, Pathak A, et al. Midline and far lateral approaches to foramen magnum lesions. *Neurol India* 1999;47:268-71.
11. Liu JK, Couldwell WT. Far-lateral transcondylar approach: Surgical technique and its application in neurenteric cysts of the cervicomedullary junction. Report of two cases. *Neurosurg Focus* 2005;19:E9.