


Severe blunt trauma to the transplanted kidney

Kosuke Omukai , Yuya Yoshimura , Tomohisa Tokura, Tatsuya Nodagashira, Akihide KonDepartment of emergency,
Hachinohe City Hospital,
Hachinohe, Japan

Correspondence to

Dr Kosuke Omukai; kosuke.
omukai@gmail.comReceived 25 February 2023
Accepted 3 June 2023

A patient in her early 50s who had received living-donor kidney transplantation at the age of 26 years was admitted to our emergency department after a motor vehicle crash. The patient was restless, and her blood pressure was 92/44 mm Hg, pulse rate was 82 beats per minute, respiratory rate was 24 breaths per minute, body temperature was 36.1°C, and the Glasgow Coma Scale score was E4V4M6. She experienced cold sweats and her face appeared pale. She was in hemorrhagic shock and had a tender abdomen, with slight distention without bruising and peritoneal irritation. Focused assessment with sonography for trauma revealed an echo-free space in the abdomen and the right thoracic cavity. Chest radiography showed a right hemothorax. We initiated massive transfusion and rapidly administered packed red blood cells and fresh frozen plasma using a rapid transfusion system. We performed tracheal intubation and placed a resuscitative endovascular balloon occlusion of the aorta (REBOA) catheter through the right femoral artery into zone 1. A 28 Fr chest tube was inserted into the right thorax, and approximately 700 mL of blood was

immediately drained. She responded to the transfusion so the balloon of REBOA was not inflated.

CT showed a right hemopneumothorax, a rib fracture, intraperitoneal fluid retention, and a right retroperitoneal hematoma. Enhanced CT showed a lacerated transplanted kidney on the right side of the pelvis and extravasation of the contrast medium (figures 1 and 2). She was hemodynamically stable during CT scanning without inflating the balloon of REBOA.

WHAT WOULD YOU DO?

- Conservative management with transfusion
- Interventional radiology (selective embolization)
- Emergency nephrorrhaphy or partial nephrectomy
- Emergency nephrectomy

WHAT WE DID AND WHY?

- Emergency nephrectomy

An emergency laparotomy was performed. The abdomen was opened with a midline abdominal incision and approximately 2000 mL of blood was observed. The graft kidney parenchyma was

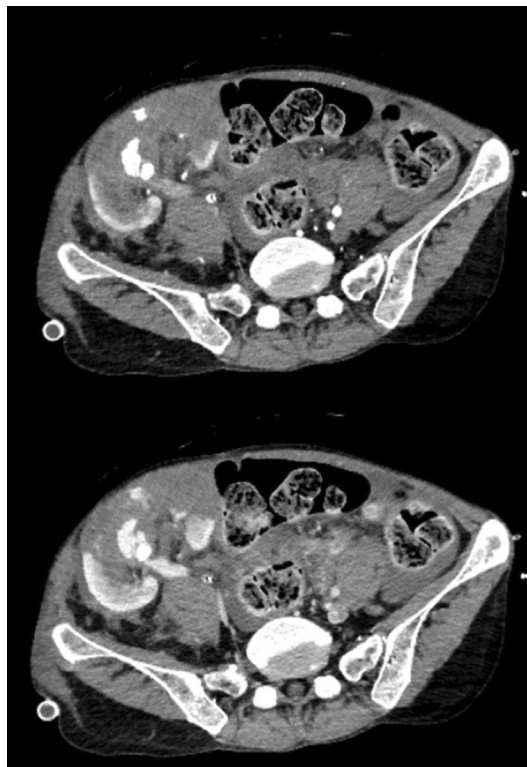


Figure 1 Enhanced computed tomography showing a lacerated transplanted kidney and extravasation of the contrast medium. (Top:arterial phase, Bottom:parenchymal phase),

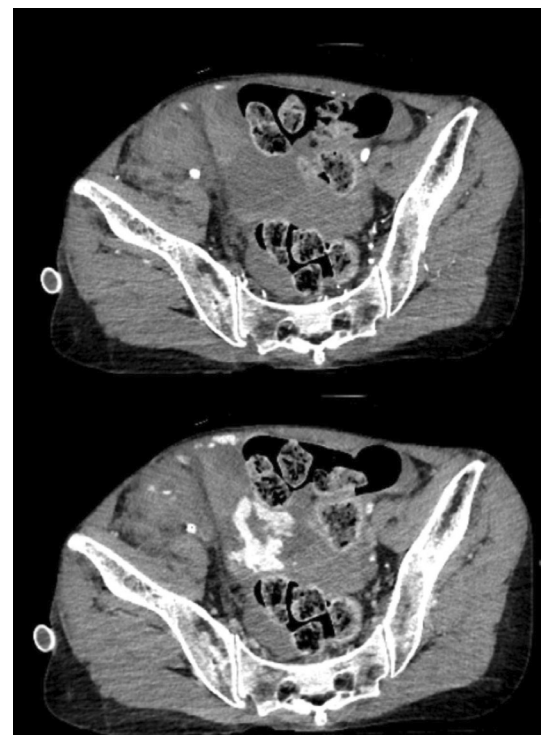

Figure 2 Enhanced computed tomography showing extravasation of the contrast medium in the pelvis. (Top: arterial phase, Bottom:parenchymal phase).

© Author(s) (or their employer(s)) 2023. Re-use permitted under CC BY-NC. No commercial re-use. See rights and permissions. Published by BMJ.

To cite: Omukai K, Yoshimura Y, Tokura T, *et al.* *Trauma Surg Acute Care Open* 2023;**8**:e001115.

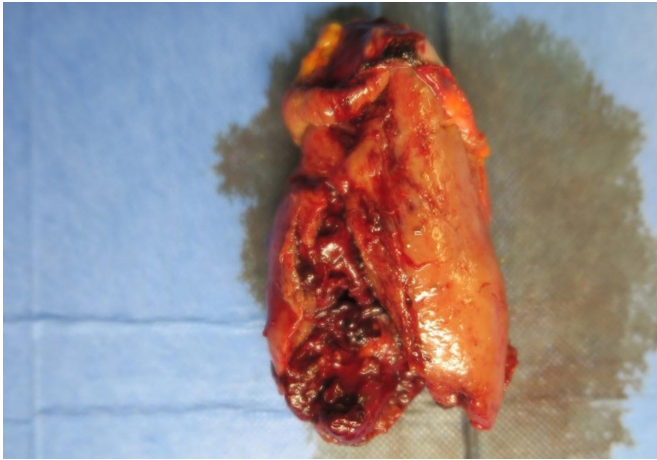

Figure 3 Resected transplanted kidney specimen.

deeply lacerated into the renal pelvis and was almost transected (figure 3), which was of grade IV injury. We clamped the hilum of the injured kidney, but there was continuous venous bleeding in the vicinity. We explored the bleeding site and found an approximately 2 cm laceration of the right external iliac vein, which was anastomosed to the injured transplanted kidney, located on the dorsal side of the right external iliac artery. There was no injury on the right internal iliac artery, which was anastomosed to the injured transplanted kidney. Hemostasis of the external iliac vein was difficult, and the patient's blood pressure fell again despite blood transfusion. REBOA was partially inflated for 37 minutes until hemostasis was achieved. Inflating the balloon increased blood pressure, decreased bleeding, and improved visibility in the surgical field. The transplanted kidney was resected, and the laceration of the right external iliac vein was sutured. The bleeding was stopped. Her postoperative course was good and there were no complications, but the patient needed dialysis again.

This case involved severe blunt trauma to the transplanted kidney with an external iliac vein injury. The transplanted kidney was mobile in the pelvis, whereas the diseased kidneys were fixed to the retroperitoneum. The external iliac veins are vulnerable to traction of the transplanted kidney, which becomes mobile on external forces to the abdominal pelvis and to be lacerated near the anastomoses. This might be a rare and specific injury pattern associated with transplanted kidney injury.

We determined that CT scan was important to determine a treatment plan that would maximize the chances of preserving the transplanted organ, although we wanted to get the patient

to the operating room as soon as possible. Depending on the results of the CT scan, the transplanted kidney could have been preserved with non-operative management (NOM) or arterial embolization. Unfortunately, the patient's kidney could not be saved as a result. The start of the procedure was delayed for 18 minutes due to CT scanning, but if hemodynamic instability occurs during that time, hemodynamic support could be provided by partially inflating the REBOA.

According to the current guidelines, laparotomy is the first-line therapy for renal injury with unstable hemodynamics, and NOM might be the choice with stable hemodynamics. Injured transplanted kidneys should be salvaged as much as possible, but NOM of severely injured transplanted kidneys remains controversial. When a transplanted kidney injury is treated conservatively, complications such as renal infarction, renal abscess, rebleeding, decreased renal function, and rejection have been reported.

To achieve hemostasis of massive abdominal hemorrhage in this case, it was necessary to stop bleeding from not only the renal injury but also the venous injury. Endovascular embolization cannot stop bleeding from the laceration of the external iliac vein. Given the severity and type of injury and the patient's unstable hemodynamics, it was impossible to salvage and repair the injured transplanted kidney. Nephrectomy was the best treatment option. This was a rare case of severe injury to the transplanted kidney that required nephrectomy.

Contributors KO, YY, and TT conceived the idea of the report. KO, YY, and TT contributed to the interpretation of the results. TN and AK supervised the conduct of this report. All authors reviewed the article draft and revised it critically for intellectual content. All authors approved the final version of the article to be published.

Funding The authors have not declared a specific grant for this research from any funding agency in the public, commercial or not-for-profit sectors.

Competing interests None declared.

Patient consent for publication Obtained.

Ethics approval This study involves human participants. This is a case report. Participants gave informed consent to participate in the study before taking part.

Provenance and peer review Not commissioned; externally peer reviewed.

Open access This is an open access article distributed in accordance with the Creative Commons Attribution Non Commercial (CC BY-NC 4.0) license, which permits others to distribute, remix, adapt, build upon this work non-commercially, and license their derivative works on different terms, provided the original work is properly cited, appropriate credit is given, any changes made indicated, and the use is non-commercial. See: <http://creativecommons.org/licenses/by-nc/4.0/>.

ORCID iDs

Kosuke Omukai <http://orcid.org/0000-0001-5264-7349>

Yuya Yoshimura <http://orcid.org/0000-0002-6156-6417>