

Original paper

## Percutaneous lung needle biopsies – utility and complications in various chest lesions: a single-institution experience

Małgorzata Jelitto-Gorska<sup>1A,C,E,F</sup>, Michał Studniarek<sup>2D,F</sup>, Agata Durawa<sup>3B,F</sup>, Tomasz Marjanski<sup>4DE</sup>, Edyta Szurowska<sup>1A</sup>

<sup>1</sup>Second Department of Radiology, Medical University of Gdansk, Poland

<sup>2</sup>First Department of Radiology, Medical University of Gdansk, Poland

<sup>3</sup>University Medical Centre of Gdansk, Poland

<sup>4</sup>Department of Thoracic Surgery, Medical University of Gdansk, Poland

### Abstract

**Purpose:** It is crucial to obtain a specific diagnosis before treatment of chest pathology is initiated. The purpose of the study is to present the utility of percutaneous biopsies, core and fine-needle aspiration, in various thoracic lesions, and related complications.

**Material and methods:** A total of 593 transthoracic biopsies were performed in the Department of Radiology between 2013 and 2016. Fine-needle aspiration biopsy (FNAB) and core biopsy (CB) were implemented. The procedures were divided into four groups according to the location of the pathology: lung lesions (LL – 540), mediastinal masses (MM – 25), chest wall tumours (CWT – 13), and pleural lesions (PL – 15). The lung lesion group was divided into two subgroups: lung nodules and lung infiltrations. All groups were analysed in respect of diagnostic accuracy, pathological findings, and complication rate.

**Results:** Pathological diagnosis was confirmed in 447 cases after all 593 procedures. The sensitivity of malignancy diagnosis in the group of lung tumours was 75% for FNAB and 89% for CB. The sensitivity in other groups, where CB was a preferable technique, was counted for lung infiltration, mediastinal masses, chest wall tumours, and pleural lesions and amounted to 83.3%, 90.9%, 100%, and 85.7%, respectively. In the group of lung tumours malignancy was confirmed most commonly (79%), while in the lung infiltration group benign processes dominated (83%). There was no statistical difference between the pneumothorax rate after CB and FNAB. Haemoptysis appeared more often after CB.

**Conclusions:** FNAB and CB are useful, safe, and sensitive tools in the diagnostic work-up. They can both be used to diagnose almost all chest pathologies.

**Key words:** computed tomography, needle biopsy, chest pathology.

### Introduction

To obtain a definite diagnosis of chest pathology is not an easy task. Groups of pulmonary nodules, lung infiltrations, and other chest pathologies comprise a variety of malignant and benign lesions that are difficult to differentiate with use of radiological investigation [1].

In numerous studies investigators have evaluated the usefulness of transthoracic needle biopsy in the diagnostic

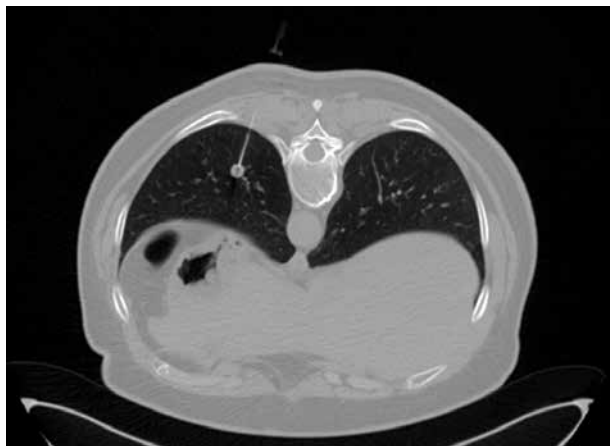work-up of lung parenchymal lesions [2-4], but only a few studies have elaborated this diagnostic tool for chest wall tumours, mediastinal masses, or pleural lesions [5-7]. Both fine-needle aspiration and core biopsy have high diagnostic accuracy with acceptable complication rates [8, 9]. The purpose of the study is to present the diagnostic accuracy, pathological findings, and risk of complications connected with the aspiration or core transthoracic needle biopsy in various chest pathologies.

### Correspondence address:

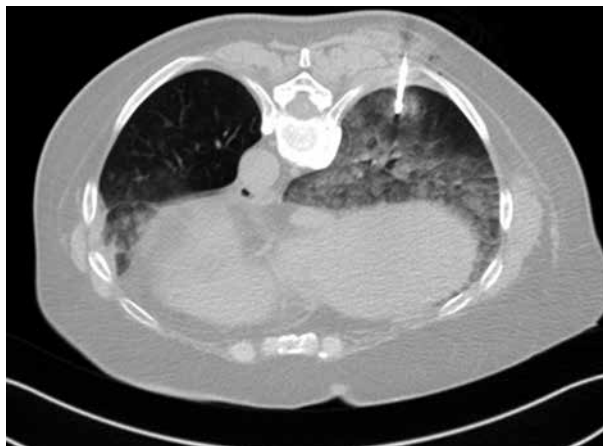
Małgorzata Jelitto-Górska, MD, 36 Kalinowa St., 80-177 Gdańsk, Poland, phone: +48 793 211 622, e-mail: [jelitto@gumed.edu.pl](mailto:jelitto@gumed.edu.pl)

### Authors' contribution:

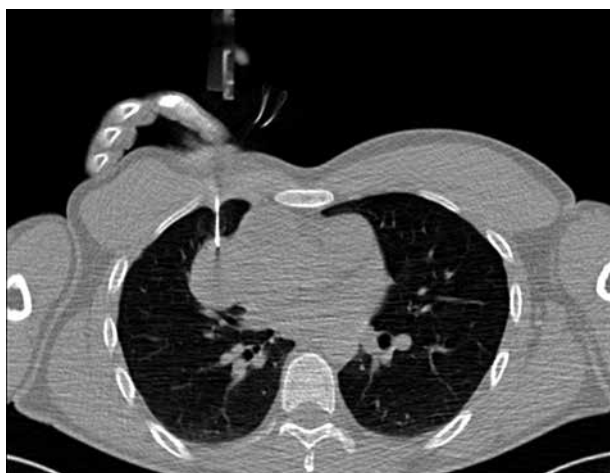
A Study design · B Data collection · C Statistical analysis · D Data interpretation · E Manuscript preparation · F Literature search · G Funds collection



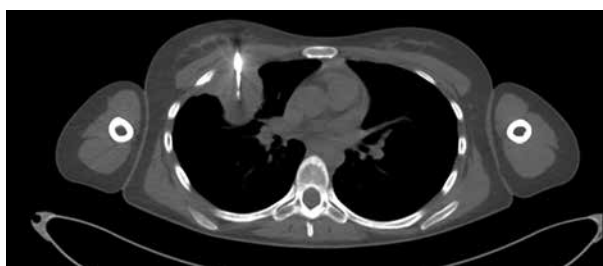**Figure 1.** An example of lung tumour biopsy – typical carcinoid was confirmed



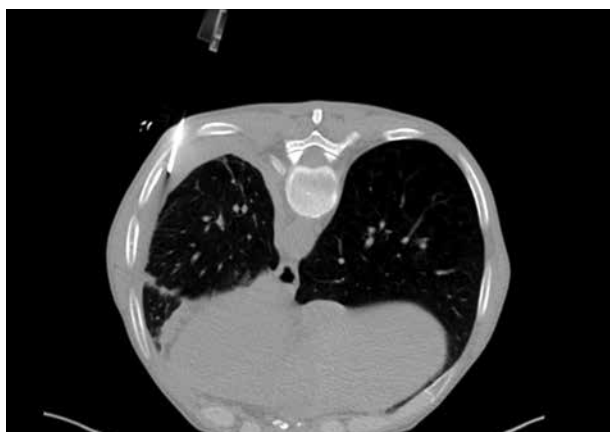**Figure 2.** An example of lung infiltration biopsy – pulmonary adenocarcinoma was confirmed



**Figure 3.** An example of mediastinal mass biopsy in a male patient – primary mediastinal choriocarcinoma was confirmed



**Figure 4.** An example of chest wall tumour biopsy – Ewing sarcoma was confirmed



**Figure 5.** An example of pleural lesion biopsy – pathological evaluation confirmed mesothelioma

## Material and methods

A total of 593 transthoracic biopsies were performed between April 2013 and August 2016 in our Radiology Department by the same radiologist. We present a retrospective analysis of the procedures.

All biopsies were performed computed tomography (CT)- or CT-fluoroscopy-guided and were performed using a 128-row CT scanner.

Fine-needle aspiration biopsy (FNAB) or core biopsy (CB) were performed.

Before the procedure, informed consent was obtained in all cases. A 1% solution of lidocaine was used as local anaesthesia.

All performed procedures were divided into four groups according to the location of the pathology:

- lung lesions (LL) – 540 procedures: all intraparenchymal lesions with probable lung parenchyma origin (including lung lesions infiltrating the mediastinum, pleura, or chest wall), subdivided into:
  - lung tumours: well-defined nodules with sharp, definite margins separating them from healthy lung parenchyma,
  - lung infiltration: ill-defined lesions without sharp borders, which infiltrate lung parenchyma;
- mediastinum masses (MM) – 25 procedures: both mass or lymph nodes located originally in the mediastinum (bone or pleural lesions with mediastinal involvement were excluded from this group);
- chest wall tumours (CWT) – 13 procedures: masses with probable origin within chest wall structures such as ribs and muscles (lung tumours with chest wall involvement were excluded from this group);
- pleural lesions (PL) – 15 procedures: pathologies located within or between parietal and visceral pleura

**Table 1.** Biopsy details for various groups of pathologies

	Lung tumours	506	Lung infiltration	34	Mediastinal masses	25	Chest wall tumours	13	Pleural lesions	15
Size (mm)	27.2			41.2		55.2		44.3		
Biopsy details										
FNAB (22-gauge)	214	42.3%	2	5.9%	4	16%	0	0%	0	0%
Use of CT fluoroscopy	4	1.9%	0	0%	2	50%				
CB	292	57.7%	32	94.1%	21	84%	13	100%	15	100%
12-gauge	4	1.3%	1	3.1%	0	0%	3	23%	2	13%
14-gauge	48	16.5%	9	28.1%	1	4.8%	7	53.8%	4	27%
16-gauge	87	29.9%	16	50%	15	71.4%	2	15.4%	6	40%
18-gauge	149	51%	6	18.8%	5	23.8%	1	7.7%	3	20%
20-gauge	4	1.3%	0	0%	0	0%	0	0%	0	0%
Use of CT fluoroscopy	165	60.8%	0	0%	18	85.7%	3	23%	3	20%

FNAB – fine-needle aspiration biopsy, CT – computed tomography, CB – core biopsy

(lung tumours with pleural infiltration were excluded from this group).

Examples of lesions from separate groups are presented in Figures 1-5. For each group specific information such as pathological outcomes, sensitivity, and complication rate is provided.

As regards complications, we noted that all (even the smallest) areas of pneumothorax were visualised in the follow-up X-ray the next day after the procedure. Also, we analysed the pneumothorax in respect of whether chest tube insertion was needed or not. Pneumothorax requiring chest drainage was defined as any symptomatic pneumothorax (pain and/or dyspnoea) or pneumothorax surrounding the entire lung on plain PA chest X-ray. The decision was undertaken by a board-certified thoracic surgeon.

We also noted any alveolar haemorrhages that appeared in follow-up CT scan both with or without further haemoptysis. We recorded all cases of blood spitting observed after the procedure, including minor spitting without the need for drug administration.

For statistical analysis, raw numbers and percentage values were used for descriptive data. Fisher's exact and Wilcoxon tests were used for a comparable analysis of separate groups.

Sensitivity for malignancy detection was calculated.

The result was considered true positive when a malignancy revealed after FNAB or CB was confirmed by surgical resection or other diagnostic procedure such as endobronchial ultrasound-guided biopsy (EBUS), bronchofiberoscopy, or thoracoscopy, or when the pathological result was sufficient for further treatment. The result was considered false negative when biopsy revealed no malignancy, but after surgery or other diagnostic procedure the neoplastic character of the tumour was confirmed.

Negative cases without any further diagnostic work-up or CT control were excluded from the sensitivity calculations.

## Results

### Biopsy details

The average size of punctured lung nodules was 27 mm and lung infiltration was 41 mm ( $p < 0.01$ ). In the case of lung tumours, both CB and FNAB were performed with comparable frequency rate (214 FNAB vs. 292 CB), but in the lung infiltration group core biopsy was the preferred technique (32 CB vs. 2 FNAB,  $p < 0.01$ ).

The mean size of mediastinal tumours was 55 mm and chest wall tumours 44 mm. We did not measure the size of pleural lesions because most of them were widely spread in the entire pleura. Core biopsy was the preferred diagnostic technique in all three groups (MM – 84%, CWT and PL – 100%). CT fluoroscopy during core biopsy was widely used in the MM group (in 85% of procedures) but only occasionally in the CWT and PL groups (20-27% of procedures).

For the CB procedures of lung tumours an 18-gauge needle was used most commonly, but in other groups of lesions higher gauge needles were selected.

Biopsy details are summarised in Table 1.

### Diagnostic accuracy and pathological outcomes

Specific pathological diagnosis was confirmed in 447 cases after all 593 procedures. Sensitivity of malignancy diagnosis in the group of lung tumours was 75% for FNAB and 89.1% for CB. Sensitivity in other groups, where CB was also the most preferred technique, was counted, respectively, for lung infiltration, mediastinal masses, chest wall tumours, and pleural lesions as 83.3%, 90.9%, 100%, and 85.7%.

In the group of lung tumours malignancy was confirmed most commonly (79%), but in the lung infiltra-

tion group benign process was revealed more frequently (83%). In the MM and CWT group malignant neoplasm dominated in pathological analysis, but among pleural lesions the rate of malignant and benign processes was comparable.

The most common malignancy in the lung tumour group was adenocarcinoma (135 of 295; 46%). Among benign nodular lesions, acute or chronic inflammatory process was the most common finding (43 of 76; 57%). Interstitial diseases and inflammatory processes were most commonly confirmed in the lung infiltration group (20 of 34; 59%). Small cell carcinoma and lymphoma dominated among mediastinal pathologies. Metastatic character of chest wall tumours was proven in 88% cases. In pleural lesions the rate of metastases and benign, fibrotic changes was comparable.

Detailed information about diagnostic accuracy and pathological results is presented in Table 2 and Table 3.

### Complications

In the group of lung tumours pneumothorax was revealed on follow-up X-ray in 71 of 214 (33.2%) FNABs and 89 of 292 (30.5%) CBs, and there was no statistical difference between these two techniques ( $p = 0.2$ ).

The frequency of chest tube insertion due to pneumothorax was also comparable for each of the techniques ( $p = 0.9$ ) and amounted to 14% for FNAB and 12.3% for CB. The frequency of drainage in the lung infiltration group after CB was 12.5%, and it was the same as in the lung tumour group ( $p = 0.7$ ).

The pneumothorax rate in the mediastinal masses group was 23.8%, but drainage was necessary in one case only. In the other two groups pneumothorax was observed occasionally, and it never required further intervention.

Alveolar haemorrhage was commonly seen after procedures performed due to lung tumour and lung infil-

tration, and definitely more frequently when core needle was used ( $p < 0.01$ ). Moreover, haemoptysis also was often seen after CB, but only occasionally after FNAB (12.3% in CB vs. 1.4% in FNAB,  $p < 0.01$ ). There was no revealed haemoptysis after procedures performed due to mediastinal mass, chest wall tumour, or pleural lesion.

Complications are listed in Table 4.

### Discussion and conclusions

In chest radiology, behind the large variety of radiological outcomes stands an even greater number of pathological diagnoses. For further treatment it is crucial to differentiate malignant neoplasms from benign processes. In daily practice of many institutions CT-guided percutaneous needle biopsy is still the gold standard of evaluation of chest pathologies [5, 7, 8, 10].

In this study we presented our experience in CT-guided needle biopsies performed due to chest pathologies. In our material we found several significant issues:

1. Core biopsy is a more sensitive technique in lung malignancy detection than fine-needle aspiration biopsy.
2. Core biopsy is a highly accurate technique for evaluation other chest pathologies such as mediastinal masses, chest wall tumours, or pleural lesions.
3. There is no statistical difference between pneumothorax rate and pneumothorax requiring drainage after CB and FNAB.
4. Haemoptysis was observed more commonly after CB than after FNAB.

In a meta-analysis Zhang *et al.* reported that the sensitivity for FNAB varied between 68% and 95%, and between 84% and 97% for CB [8]. A comparison of our results with those from Zhang *et al.* shows that we obtained similar sensitivity for FNAB and CB in evaluation of lung tumours. We also observed that CT-guided core biopsy is an effective and very safe procedure in the diagnostic field

**Table 2.** Diagnostic accuracy calculated for all groups of pathologies

	Lung tumours		Lung infiltration	Mediastinal masses	Chest wall tumours	Pleural lesions
	FNAB	CB	CB and FNAB	CB and FNAB	CB	CB
Number of procedures	214	292	34	25	13	15
Diagnosis obtained	131 (61.2%)	241 (82.5%)	30 (88.2%)	21 (84.0%)	13 (100.0%)	11 (73.3%)
Malignant	115 (53.7%)	180 (61.6%)	5 (14.7%)	20 (80.0%)	8 (61.5%)	6 (40.0%)
Benign	16 (7.5%)	60 (20.5%)	25 (3.5%)	1 (4.0%)	5 (38.5%)	5 (33.3%)
No diagnosis	83 (38.8%)	52 (17.8%)	4 (11.8%)	4 (16.0%)	0 (0.0%)	4 (26.7%)
TP	114	180	5	20	8	6
TN	37	55	21	2	3	5
Sensitivity	75.0%	89.1%	83.3%	90.9%	100.0%	85.7%
Not included in calculation	25 (11.7%)	35 (10.8%)	7 (20.6%)	1 (4.0%)	2 (15.4%)	3 (20.0%)

FNAB – fine-needle aspiration biopsy, CB – core biopsy, TP – true positive, TN – true negative

**Table 3.** Specification of pathological findings in all groups of chest pathologies

Pathological findings	Lung tumours		Lung infiltration		Mediastinal masses		Chest wall tumours		Pleural lesions	
<b>Malignant</b>	<b>115</b>	<b>180</b>	<b>5</b>	<b>20</b>	<b>8</b>	<b>6</b>				
Non-specified NSCLC	12 (10.4%)	11 (6.1%)	0 (0.0%)	1 (5.0%)	0 (0.0%)	0 (0.0%)				
Adenocarcinoma	59 (51.3%)	76 (42.2%)	3 (60.0%)	0 (0.0%)	0 (0.0%)	0 (0.0%)				
Carcinoma planoepitheliale	18 (15.7%)	43 (23.9%)	0 (0.0%)	0 (0.0%)	0 (0.0%)	0 (0.0%)				
Neuroendocrine NSCLC	3 (2.6%)	7 (3.8%)	0 (0.0%)	0 (0.0%)	0 (0.0%)	0 (0.0%)				
SCLC	9 (7.8%)	4 (2.2%)	0 (0.0%)	6 (30.0%)	0 (0.0%)	0 (0.0%)				
Combined NSCLC + SCLC	5 (4.3%)	3 (1.6%)	0 (0.0%)	0 (0.0%)	0 (0.0%)	0 (0.0%)				
Mesothelioma malignum	0 (0.0%)	0 (0.0%)	0 (0.0%)	0 (0.0%)	0 (0.0%)	1 (16.7%)				
Metastases	9 (7.8%)	30 (16.6%)	2 (40.0%)	3 (15.0%)	7 (87.5%)	5 (83.3%)				
<b>Others</b>	<b>0 (0.0%)</b>	<b>6 (3.3%)</b>	<b>0 (0.0%)</b>	<b>0 (0.0%)</b>	<b>0 (0.0%)</b>	<b>0 (0.0%)</b>				
Sarcoma	0 (0.0%)	3 (1.9%)	0 (0.0%)	2 (10.0%)	1 (12.5%)	0 (0.0%)				
Thymic cancer	0 (0.0%)	0 (0.0%)	0 (0.0%)	1 (5.0%)	0 (0.0%)	0 (0.0%)				
Choriocarcinoma	0 (0.0%)	0 (0.0%)	0 (0.0%)	1 (5.0%)	0 (0.0%)	0 (0.0%)				
Lymphoma	0 (0.0%)	3 (0.6%)	0 (0.0%)	6 (30.0%)	0 (0.0%)	0 (0.0%)				
<b>Benign</b>	<b>16</b>	<b>60</b>	<b>25</b>	<b>1</b>	<b>5</b>	<b>5</b>				
Sarcoidosis	0 (0.0%)	5 (8.3%)	2 (8.0%)	0 (0.0%)	0 (0.0%)	0 (0.0%)				
Tuberculosis	2 (12.5%)	6 (10%)	3 (12.0%)	0 (0.0%)	0 (0.0%)	0 (0.0%)				
Inflammatory process	6 (37.5%)	37 (61.7%)	10 (40.0%)	1 (100.0%)	3 (60.0%)	0 (0.0%)				
Interstitial disease	0 (0.0%)	3 (5%)	10 (40.0%)	0 (0.0%)	0 (0.0%)	0 (0.0%)				
Granulomatosis with polyangiitis	0 (0.0%)	3 (5%)	0 (0.0%)	0 (0.0%)	0 (0.0%)	0 (0.0%)				
<b>Others</b>	<b>8 (50.0%)</b>	<b>6 (10%)</b>	<b>0 (0.0%)</b>	<b>0 (0.0%)</b>	<b>2 (40.0%)</b>	<b>5 (100.0%)</b>				
Neurofibroma	0 (0.0%)	2 (3.8%)	0 (0.0%)	0 (0.0%)	0 (0.0%)	0 (0.0%)				
Hamartoma	6 (37.5%)	0 (0.0%)	0 (0.0%)	0 (0.0%)	0 (0.0%)	0 (0.0%)				
Fibrotic pleural lesions	0 (0.0%)	1 (1.9%)	0 (0.0%)	0 (0.0%)	0 (0.0%)	5 (100.0%)				
Pneumoconiosis	2 (12.5%)	0 (0.0%)	0 (0.0%)	0 (0.0%)	0 (0.0%)	0 (0.0%)				
Rheumatoid nodule	0 (0.0%)	0 (0.0%)	0 (0.0%)	0 (0.0%)	0 (0.0%)	0 (0.0%)				
Atypical adenomatous hyperplasia	0 (0.0%)	3 (1.9%)	0 (0.0%)	0 (0.0%)	0 (0.0%)	0 (0.0%)				

NSCLC – non-small cell lung cancer, SCLC – small cell lung cancer

**Table 4.** Complication after biopsy procedure reported in each group of chest pathologies

Complications	Lung tumours				Lung infiltration				Mediastinal masses			Chest wall tumours		Pleural lesions		
	FNAB	214	CB	292	FNAB	2	CB	32	FNAB	4	CB	21	CB	13	CB	15
Pneumothorax	71	33.2%	89	30.5%	1	50.0%	8	25.0%	0	0.0%	5	23.8%	0	0.0%	1	8.3%
Pneumothorax without chest tube insertion	41	19.2%	53	18.2%	1	50.0%	4	12.5%	0	0.0%	4	19.0%	0	0.0%	1	8.3%
Pneumothorax with chest tube insertion	30	14.0%	36	12.3%	0	0.0%	4	12.5%	0	0.0%	1	4.8%	0	0.0%	0	0.0%
Alveolar haemorrhage	62	29.0%	113	38.7%	0	0.0%	10	31.3%	0	0.0%	2	9.5%	0	0.0%	0	0.0%
Haemoptysis	3	1.4%	36	12.3%	0	0.0%	4	12.5%	0	0.0%	0	0.0%	0	0.0%	0	0.0%
Pleural haematoma	3	1.4%	4	1.4%	0	0.0%	0	0.0%	0	0.0%	0	0.0%	0	0.0%	0	0.0%

NAB – fine-needle aspiration biopsy, CB – core biopsy

of other chest pathologies [9]. Other authors also recommended it as the procedure of first choice in the evaluation of mediastinal masses [6], chest wall tumours [7], and pleural lesions [5], obviating more invasive procedures such as thoracoscopy, mediastinoscopy, or thoracotomy.

Heering *et al.* analysed numerous previous studies according to complication rate, and noted that the pneumothorax rate and pneumothorax with intervention varied greatly (8-50% and 0-19%, respectively) [9]. According to their analysis, the pneumothorax rate is strongly connected with the size of the needle, and its rate is higher after CB procedures. Conversely, the pneumothorax and pneumothorax with intervention rate in our study was similar

in each technique used. However, as in the above-mentioned meta-analysis, we found that a thicker needle increased the risk of haemoptysis [9].

## Conclusions

Both FNAB and CB are useful, safe, and sensitive tools, which can be used in chest pathology diagnostic work-up, with acceptably low risk of complications.

## Conflict of interest

The authors report no conflict of interest.

---

## References

1. Laspas F, Roussakis A, Efthimiadou R, et al. Percutaneous CT-guided fine-needle aspiration of pulmonary lesions: Results and complications in 409 patients. *J Med Imaging Radiat Oncol* 2008; 52: 458-462.
2. Geraghty PR, Kee ST, McFarlane G, et al. CT-guided transthoracic needle aspiration biopsy of pulmonary nodules: needle size and pneumothorax rate. *Radiology* 2003; 229: 475-481.
3. Yeow KM, Tsay PK, Cheung YC, et al. Factors affecting diagnostic accuracy of CT-guided coaxial cutting needle lung biopsy: retrospective analysis of 631 procedures. *J Vasc Interv Radiol* 2003; 14: 581-588.
4. Montaudon M, Latrabe V, Pariente A, et al. Factors influencing accuracy of CT-guided percutaneous biopsies of pulmonary lesions. *Eur Radiol* 2004; 14: 1234-1240.
5. Azrumelashvili T, Mizandari M, Dundua T. Imaging Guided Percutaneous Core Biopsy Of Pulmonary And Pleural Masses – Technique And Complications. *Georgian Med News* 2016; 250: 25-33.
6. Petranovic M, Gilman MD, Muniappan A, et al. Diagnostic yield of CT-guided percutaneous transthoracic needle biopsy for diagnosis of anterior mediastinal masses. *Am J Roentgenol* 2015; 205: 774-779.
7. Azrumelashvili T, Mizandari M, Magalashvili D, et al. Imaging Guided Percutaneous Core Biopsy Of Thoracic Bone And Soft Tissue Lesions – Technique And Complications. *Georgian Med News* 2016; 250: 17-24.
8. Zhang HF, Zeng XT, Xing F, et al. The diagnostic accuracy of CT-guided percutaneous core needle biopsy and fine needle aspiration in pulmonary lesions: a meta-analysis. *Clin Radiol* 2016; 71: e1-10.
9. Heerink WJ, de Bock GH, de Jonge GJ, et al. Complication rates of CT-guided transthoracic lung biopsy: meta-analysis. *Eur Radiol* 2017; 27: 138-148.
10. Belfiore G, Di Filippo S, Guida C, et al. CT-guided biopsy of lung lesions. *Nucl Med Biol* 1994; 21: 713-719.