

Bilateral decompression and intervertebral fusion via unilateral fenestration for complex lumbar spinal stenosis with a mobile microendoscopic technique

Baoshan Xu, MD, PhD*, Haiwei Xu, MD, Xinlong Ma, MD, Yue Liu, MD, PhD, Qiang Yang, MD, PhD, Hongfeng Jiang, MD, PhD, Ning Li, MD, Ning Ji, MD

Abstract

For complex lumbar spinal stenosis, using of endoscopy technique may provide clear vision with less invasive dissection of paravertebral muscle. The objective of this study was to evaluate the feasibility and clinical efficacy of bilateral decompression and intervertebral fusion via unilateral fenestration for complex lumbar spinal stenosis using mobile microendoscopic discectomy (MMED) technique.

A total of 61 patients with complex lumbar spinal stenosis (lumbar canal stenosis combined with degenerative spondylolisthesis, instability, and scoliosis) were treated with this procedure. Patients with isolated lumbar spinal stenosis or spondylolisthesis greater than grade II were excluded. The index levels included L4/5 in 52 patients, L5/S1 in 6 patients, L3-L5 in 2 patients and L4-S1 in 1 patient. The preoperative Oswestry Disability Index (ODI) score was 42.6 ± 10.2 , lumbar visual analog scale (VAS) score was 6.1 ± 4.2 , and leg VAS score was 7.1 ± 5.1 . During the operation, ipsilateral enlarged fenestration was made using the MMED technique. The disc and cartilage endplate were thoroughly removed, and the contralateral ligamentum flavum and the inner layer of lamina were undercut to release the contralateral nerve root. The intervertebral space was released and prepared, followed by bone grafting and cage insertion. Percutaneous pedicle system was used for reduction and fixation. The operative time and blood loss were recorded, and patients were followed-up for at least 3 years (36–48 months, average 41 months) to evaluate the clinical efficacy.

The procedure was successful in all patients, with no nerve injury or conversion to open operation. The mean operative time was 120 minutes (range, 100–180 minutes), with a mean blood loss of 100 mL (range, 50–200 mL). Postoperative x-ray and CT showed sufficient decompression and improvement of spinal alignment. At 3 years after surgery, the ODI scores, lumbar and leg VAS scores decreased from preoperative 42.6 ± 10.2 , 6.1 ± 4.2 , and 7.1 ± 5.1 to 8.6 ± 7.0 , 1.8 ± 1.3 , and 0.9 ± 0.6 , respectively ($P = .00$ for each comparison). The clinical results were excellent in 36 cases, good in 23, and fair in 2, according to the MacNab scale.

The procedure of bilateral decompression and intervertebral fusion via unilateral fenestration using the MMED technique can provide satisfactory clinical results for complex lumbar spinal stenosis.

Abbreviations: AP = anteroposterior, BDUF = bilateral decompression via unilateral fenestration, CT = computed tomography, DSH = disc space height, MED = microendoscopic discectomy, MIS-TLIF = minimally invasive transforaminal lumbar interbody fusion, MMED = mobile microendoscopic discectomy, MRI = magnetic resonance imaging, ODI = Oswestry Disability Index, PLF = posterior lumbar fusion, PLIF = posterior lumbar interbody fusion, TLIF = transforaminal lumbar interbody fusion, VAS = visual analog scale.

Keywords: complications, endoscopic surgery, intervertebral disk displacement, lumbar spine, spinal stenosis

Editor: Somchai Amornyoitin.

This study was supported by the National Natural Science Foundation of China (Nos. 81272046 and 31500781), the Natural Science Foundation of Tianjin (No. 15JCYBJC25300), and the Key Research Foundation of the Tianjin Health Bureau (No. 14KG121).

The authors have no conflicts of interest to disclose.

Department of Minimally Invasive Spine Surgery, Tianjin Hospital, Tianjin, People's Republic of China.

* Correspondence: Baoshan Xu, Department of Minimally Invasive Spine Surgery, Tianjin Hospital, 406 Jie Fang Nan Road, Hexi District, Tianjin 300211, People's Republic of China (e-mail: xubaoshan99@126.com).

Copyright © 2018 the Author(s). Published by Wolters Kluwer Health, Inc. This is an open access article distributed under the terms of the Creative Commons Attribution-Non Commercial License 4.0 (CCBY-NC), where it is permissible to download, share, remix, transform, and buildup the work provided it is properly cited. The work cannot be used commercially without permission from the journal.

Medicine (2018) 97:4(e9715)

Received: 20 June 2017 / Received in final form: 1 January 2018 / Accepted: 8 January 2018

<http://dx.doi.org/10.1097/MD.00000000000009715>

1. Introduction

Lumbar spinal stenosis is a common disease with increasing incidence along with the aging of population.^[1] Except in cases of isolated lumbar spinal stenosis, some patients suffering from lumbar spinal stenosis have spondylolisthesis, scoliosis, or horizontal or axial instability.^[2] In literature, complex lumbar stenosis has been described differently.^[2–3] In this study, we defined complex lumbar spinal stenosis to be those patients who had lumbar spinal stenosis combined with spondylolisthesis (1–2 degree according to Meyerding classification),^[4] scoliosis (>10 degree), or evidence of radiographic instability. During surgical treatment for complex lumbar spinal stenosis, sufficient decompression, reduction and fusion are needed, and extensive paraspinal muscle dissection is required using traditional surgery techniques.^[2] With the development of minimally invasive techniques, some surgeons have, in recent years, performed decompression and fusion through tubes with a light source, such as minimally invasive transforaminal lumbar interbody fusion (MIS-TLIF), which becomes a popular procedure with good

results. However, MIS-TLIF is usually performed under direct vision of naked eyes, muscles adhere to articular process need to be detached to achieve good exposure, and the contralateral undermined decompression is difficult without assistance of endoscope.^[5]

With the development of spinal endoscopic technology, bilateral decompression via unilateral fenestration (BDUF) can be achieved for lumbar spinal stenosis with microendoscopic discectomy (MED).^[6] However, this procedure is challenging for complex stenosis because of the hyperplasia and distortion of the lamina, flavum, and facet. The mobile microendoscopic discectomy (MMED) system designed by Destandau in France, known as “Destandau technique” with free tilted channels, is beneficial for decompression and other operations under various conditions; but this technique has not been reported in fusion surgery until now. On the basis of BDUF with MMED for isolated lumbar spinal stenosis, we suppose that BDUF and intervertebral fusion can be performed using MMED technique with good vision and fewer traumas. In this study, we prospectively evaluated the feasibility and efficacy of this technique in the surgical treatment of complex lumbar spinal stenosis.

2. Materials and methods

2.1. Patient information

All procedures in this study were approved by the Ethics Committee of Tianjin Hospital. In this prospective study, patients with complex lumbar spinal stenosis were treated with bilateral decompression and intervertebral fusion via unilateral fenestration using the MMED technique from April 2013 to August 2014. The inclusion criteria were as follows: (1) intermittent claudication and/or sciatic nerve pain in bilateral lower extremity; (2) poor results or recurrent symptoms after conservative treatment for more than 6 months; (3) preoperative Oswestry Disability Index (ODI) score > 30; and (4) computed tomography (CT), magnetic resonance imaging (MRI), and x-ray in the hyperextension and hyperflexion positions showing lumbar canal stenosis combined with degenerative spondylolisthesis, instability, and scoliosis involving 1 to 2 index segments and consistent with the clinical manifestations. The following conditions were excluded: isolated lumbar disc herniation, isolated lumbar spinal stenosis, bilateral severe bony stenosis, no fewer than 3 index segments, spondylolisthesis greater than grade II (Meyerding), infection, and tumors.

A total of 61 patients were enrolled in the study, including 35 males and 26 females, with a mean age of 66.2 years (range,

56–76 years). All patients complained of bilateral lumbocrural pain and intermittent claudication that were dominant in 1 limb. The course of disease ranged from 6 months to 10 years with a mean of 2.9 years. The preoperative ODI score was 42.6 ± 10.2 , the lumbar visual analog scale (VAS) score was 6.1 ± 4.2 , and the leg VAS score was 7.1 ± 5.1 . Of the patients enrolled, 58 had 1 index level and 3 had 2 index levels, including L4/5 in 52 patients, L5/S1 in 6 patients, L3-L5, in 2 patients and L4-S1 in 1 patient. All the patients received BDUF and interbody fusion using the MMED technique.

3. Surgical technique

3.1. Characteristics and improvements of the MMED system

The MMED (Endospine, Karl Storz, Germany) system is mobile and self-balanced erect in the incision, not connecting the operation table (Fig. 1A). The cone-shaped outer tube and inner tube are connected through a chute (Fig. 1B and C), and the inner tube includes 3 separate channels (an 8 mm working channel, a 4 mm telescope channel, and a 4 mm suction channel, and there is a 12° angle between the working channel and the telescope channel) and a built-in nerve retractor (Fig. 1D). During surgery, the tubes can be tilted with surgical instruments, which is helpful for accessing the operating field.^[7,8] The outer tube only allows the pass of a cage no more than 10 mm high, so we fabricated slight larger outer tubes with similar shape, that allow the pass of cages of 12 and 14 mm high (Patent No.: 201510629741.0) (Fig. 1E).

3.2. Operation method

3.2.1. The surgery was performed by the first author and an assistant surgeon.

3.2.1.1. Location and channel installation. The surgery was carried out under general anesthesia with the patient in prone position. The position and direction of the index intervertebral space were located with a special localizing device using lateral C-arm fluoroscopy,^[7,9] and the projection of the pedicle of the superior and inferior vertebral bodies was located using anteroposterior C-arm fluoroscopy. A vertical paraspinous incision was made medial to the projection of pedicle on the side of dominant symptoms that was about 2.5 cm long for 1 index level and 3.5 cm long for 2 index levels. The fascia and subcutaneous tissue were incised sharply, and bipolar coagulation was used for hemostasis. Scissors and a 12 mm chisel were inserted along the spinous process to detach the paraspinous muscle from the lamina. The outer tube filled with obturator was inserted into the incision

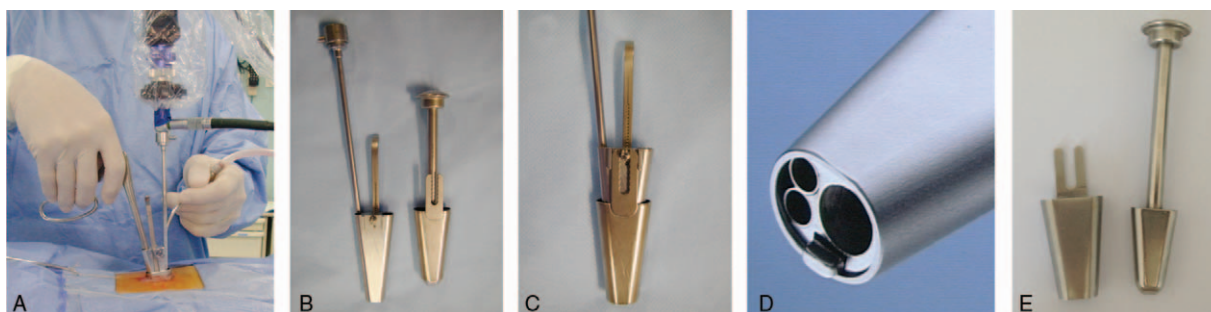


Figure 1. The MMED system and its application. (A) The tubes can be freely tilted during the operation; (B) the inner (left) and outer (right) tube with the obturator; (C) the inner tube was inserted into the outer tube along the chute; (D) there are 3 channels in the inner tube: a telescope channel, a suction channel, and a working channel; and (E) the larger outer tube (left), which allows the pass of a 14 mm high cage, and the obturator (right). MMED = mobile microendoscopic discectomy.

along the location direction. The obturator was removed, and the soft tissue in the tube was removed to expose the interlaminar space, the inferior part of the upper lamina and the medial part of the facet. The inner tube was inserted into the outer tube with the camera and imaging system installed.

3.2.1.2. Nerve decompression. The inferior part of the upper lamina and the medial part of the inferior articular process were burring off with a long-handle bur until the ligamentum flavum was fully exposed. The ligamentum flavum was elevated and removed to expose the dural sac. Decompression was performed along the lateral margin of the dural sac and the nerve root. Enlarged fenestration was performed with resection of the medial part of the superior articular process to fully expose the posterolateral side of the disc. Cotton pieces were used to retract and protect the dural sac and nerve root, and the nerve retractor was pushed into the canal if exposure was unsatisfactory. The annulus fibrosus was cut sharply, and the disc material in the intervertebral space was completely removed. After sufficient decompression on the ipsilateral side, the tubes were tilted toward the contralateral side. The fundus of the spinous process was resected using a high-speed bur and a Kerrison rongeur. The contralateral hyperplastic ligamentum flavum and the inner layer of lamina were undercut with the Kerrison until the contralateral nerve root was exposed and released.^[10]

3.2.1.3. Bone grafting and cage placement. With enlarged fenestration and enough resection of facet, posterolateral part of the disc space was fully exposed. The disc and endplate cartilage were completely curetted off with long-handle curettes by tilting the instruments and channels in various direction. The disc space was rinsed with saline using a special long irrigator until the debris was cleared and the bony endplate exposed. After the nerve root and dural sac were well retracted and protected by pieces of cotton, adequate space was created for the pass of testing mold and cage. The inner tube was removed, and the intervertebral space was distracted and tested with a testing mold under direct vision. The autologous bone from decompression and allogeneic bone were mixed and grafted into the intervertebral space, followed by insertion of a suitable cage (Capstone, Medtronic Sofamor Danek) filled with bone graft. The self-made larger outer tube was used if a 12 or 14 mm high cage was needed. The position of cage and the reduction were checked under fluoroscopy, and the pieces of cotton were taken out.

3.2.1.4. Percutaneous fixation. The pedicles of the proximal and distal vertebral bodies were punctured under fluoroscopy,

through the same incision and intermuscular space on the fenestration side, and percutaneous on the contralateral side. The guide wire was inserted, followed by tapping and inserting hollow pedicle screws (Sextent 2, Medtronic Sofamor Danek). The residual spondylolisthesis and expected reduction were measured on fluoroscopy, and reduction distances were prepared on the sleeve of screws. Suitable connecting rods were measured and inserted, and the residue spondylolisthesis was reduced when the rods were compressed and fixed into the heads of screws. More compression was performed on the convex side for patients with scoliosis.

A thin drainage was inserted in the field of fenestration, and the incisions were closed routinely. For two-level interventions, the procedure of decompression and bone grafting was same as the previous description. During percutaneous fixation, the puncture and insertion of pedicle screws in the middle vertebral body were performed with a mold to be in line with the proximal and distal screws.

3.3. Postoperative management and follow-up

The drainage was removed in 12 to 24 hours, and lumbar anteroposterior (AP) and lateral x-ray and CT exam were taken. The patients were encouraged to ambulate in 2 days after the operation with soft waist collar. Patients were re-examined in the outpatient department at 3 months, 1 year, and 3 years after the operation. The ODI score and the lumbar and leg VAS scores were assessed, and the clinical results were evaluated according to the Macnab scale^[11] (excellent: the symptom has completely disappeared and the patient is able to return to their original work and activities; good: occasional pain, capable of light work; fair: symptoms partially resolved with persistent pain, not capable of work; poor: nerve root pain requiring further surgery).

The patients were followed for at least 3 years (36–48 months, average 41 months). During the follow-up, the implant, spinal alignment and fusion were evaluated using lumbar AP and lateral x-ray. Brantigan and Steffee criteria^[12] were used to assess the intervertebral fusion (Table 1). The disc space height (DSH, the average of the anterior and posterior height of intervertebral space) and spondylolisthesis ratio (the ratio of translation distance to the anteroposterior diameter of the superior endplate of the distal vertebral body) were measured using the lumbar lateral x-ray. Scoliosis was measured according to the Cobb angle on the AP film for patients with lumbar scoliosis.

3.4. Statistics

All data were analyzed using SPSS 16.0 (Chicago, IL). Measurement data were expressed as the mean ± SD. Differences

Table 1
Brantigan and Steffee criteria.

Classification	Description
A	Obvious collapse of construct due to pseudoarthrosis, loss of disc height, vertebral slip, broken screws, displacement of the cage, resorption of bone graft
B	Probable significant resorption of the bone graft due to pseudoarthrosis, major lucency, or gap visible in fusion area
C	Uncertain nonunion, bone graft visible in the fusion area at approximately the density originally achieved at surgery. A small lucency or gap may be visible involving a portion of the fusion area with at least half of the flat area
D	Probable fusion bone bridges entire fusion area with at least the density achieved at surgery. There should be no lucency between the donor and vertebral bone. Fusion bone in the fusion area is radiographically more dense and mature than originally achieved by surgery
E	Optimally, there is no interface between the donor and vertebral bone, although a sclerotic line between the graft and vertebral bone indicates fusion. Other signs of the solid fusion include mature bony trabeculae bridging the fusion area, resorption of the anterior traction spur, anterior progression of the graft within disc space, and fusion of facet joints

Table 2

The clinical and radiological results before operation, at 3 months, 1 year, and 3 years after operation.

	Pre-op	3 months post-op	1 year post-op	3 years post-op
ODI (61 patients)	42.6 ± 10.2	11.8 ± 8.1 [*]	9.0 ± 6.8 ^{*,†}	8.6 ± 7.0 ^{*,†,‡}
Lumbar VAS (61 patients)	6.1 ± 4.2	2.9 ± 2.2 [*]	2.1 ± 1.5 ^{*,†}	1.8 ± 1.3 ^{*,†,‡}
Leg VAS (61 patients)	7.1 ± 5.1	2.0 ± 1.1 [*]	1.1 ± 0.9 ^{*,†}	0.9 ± 0.6 ^{*,†,‡}
DSH (mm, 61 patients)	7.5 ± 3.1	9.8 ± 5.2 ^{*,‡}	9.8 ± 4.8 [*]	9.7 ± 4.5 ^{*,‡}
Sp ratio (%; 42 patients)	18.1 ± 6.2	10.9 ± 5.1 ^{*,‡}	11.2 ± 5.3 [*]	11.6 ± 5.3 ^{*,‡}
Cobb angle (°, 19 patients)	24.2 ± 8.9	17.4 ± 7.2 ^{*,‡}	18.2 ± 7.4 [*]	19.1 ± 6.8 ^{*,‡}

DSH = disc space height, ODI = Oswestry Disability Index, Sp = spondylolisthesis, VAS = visual analog scale.

^{*} Represented $P < .05$ compared with pre-op.

[†] Represented $P < .05$ compared with 3 months post-op.

[‡] Represented $P > .05$ compared with 1 year post-op.

between groups were assessed using paired *t* test. A value of $P < .05$ was considered statistically significant.

4. Results

The surgery was successful in all 61 patients, with no nerve injury or conversion to open operation. The tubes were wrongly tilted to proximal level in 2 cases, which were corrected before discectomy with fluoroscopy. The mean operative time was 120 minutes (range, 100–180 minutes), with a mean blood loss of 100 mL (range, 50–200 mL). The postoperative drainage volume ranged from 10 to 100 mL. Patients were encouraged to ambulate 1 to 2 days after surgery and had a mean postoperative hospital stay of 4.5 days (range, 3–6 days). The lumbar and leg pain were greatly relieved after the surgery. Postoperative lumbar x-rays showed that the DSH was restored, spondylolisthesis was generally reduced, and scoliosis was partially corrected (Table 2). CT scans showed sufficient decompression in bilateral spinal canal and good retention of the contralateral facet and muscle (Figs. 2 and 3).

Complications included laceration of dura sac and leakage of cerebrospinal fluid in 2 cases with severe stenosis and adhesion, and the drainage was removed 48 and 72 hours after operation, followed by normal heal of incision. One patient with stenosis and degenerative scoliosis experienced radiate pain and weakness of hip flexion at contralateral thigh after L4/5 fusion, which resolved with conservative treatment including nonsteroidal antiinflammatory drugs in 4 weeks. Three patients complained local pain around the screw head that resolved in 2 weeks with physiotherapy.

The ODI scores, lumbar, and leg VAS scores decreased significantly 3 months after surgery ($P < .05$, compared with pre-op), and they further decreased to 9.0 ± 6.8 , 2.1 ± 1.5 , and 1.1 ± 0.9 , respectively, at 1 year after surgery ($P < .05$, compared with pre-op and 3 months after the surgery) and 8.6 ± 7.0 , 1.8 ± 1.3 , and 0.9 ± 0.6 , respectively, at 3 years after surgery ($P < .05$, compared with pre-op and 3 months after the surgery; $P > .05$, compared with 1 year after the surgery) (Table 2). The clinical results at 3 years after surgery were excellent in 36, good in 23, and fair in 2 cases according to the Macnab scale.

The lumbar x-rays at follow-up showed no loosening or failure of implants, and no displacement of cages. At 3 years after surgery, the fusion was evaluated on x-rays according to Brantigan and Steffee criteria, and the fusion was D in 29 cases and E in 32 cases. At 3 months, 1 year and 3 years after operation, the DSH increased significantly compared to that before operation ($P < .05$); while the spondylolisthesis and Cobb angle decreased significantly compared to that before operation ($P < .05$). The difference of DSH, spondylolisthesis ratio, and

Cobb among 3 months, 1 year, and 3 years after surgery were not significant ($P > .05$) (Table 2).

5. Discussion

5.1. Surgical treatments for complex lumbar spinal stenosis

Extensive dissection of the paraspinal muscle is needed during conventional surgeries for complex stenosis, such as posterior lumbar fusion (PLF), posterior lumbar interbody fusion (PLIF), and transforaminal lumbar interbody fusion (TLIF), and that may result in atrophy of the paraspinal muscle and intractable low back pain in some patients.^[2] Bilateral decompression via a unilateral approach has emerged as a new minimally invasive technique for complex stenosis in recent years. Hamasaki et al^[13] performed a biomechanical study on 8 cadaveric human lumbar spines and determined that bilateral decompression via a unilateral approach produced fewer biomechanical changes in terms of stiffness and preserved more than 80% stiffness in the intact spine. However, bilateral exposure and decompression via a unilateral approach are challenging through a tube without endoscope, so endoscopic technique plays an important role in this approach. Guiot et al^[14] performed microendoscopic BDUF for lumbar stenosis in human cadavers with satisfactory decompression of the spinal canal, which proved the feasibility and efficacy of microendoscopic BDUF for lumbar stenosis. Khoo and Fessler^[15] performed microendoscopic BDUF in 25 patients of lumbar stenosis, sufficient decompression was achieved with bilateral bony and ligamentous decompression while the supraspinous–interspinous ligaments and contralateral musculature were preserved, with less bleeding and good stability. However, the tube of conventional MED system is connected and fixed to the operating bed, so the visional field is fixed, and the manipulation of instruments is limited by the direction of tube. Therefore, BDUF with conventional MED is very challenging for the complex lumbar spinal stenosis, partly due to severe hyperplasia of the lamina and articular process, distortion of the facet joint and deformity.

Percutaneous TLIF has emerged as a novel fusion technique. Morgenstern R^[16] performed percutaneous TLIF using a posterolateral approach for 30 patients of degenerative disk disease with satisfactory result. Besides, he performed endoscopic TLIF with percutaneous transpedicular screw fixation for patients of spondylolisthesis at L4–5 level, that was less aggressive than open or MIS-TLIF surgery, however, sufficient decompression of lamina could not be achieved during endoscopic TLIF.^[17] So, in this study, we tried to perform BDUF and intervertebral

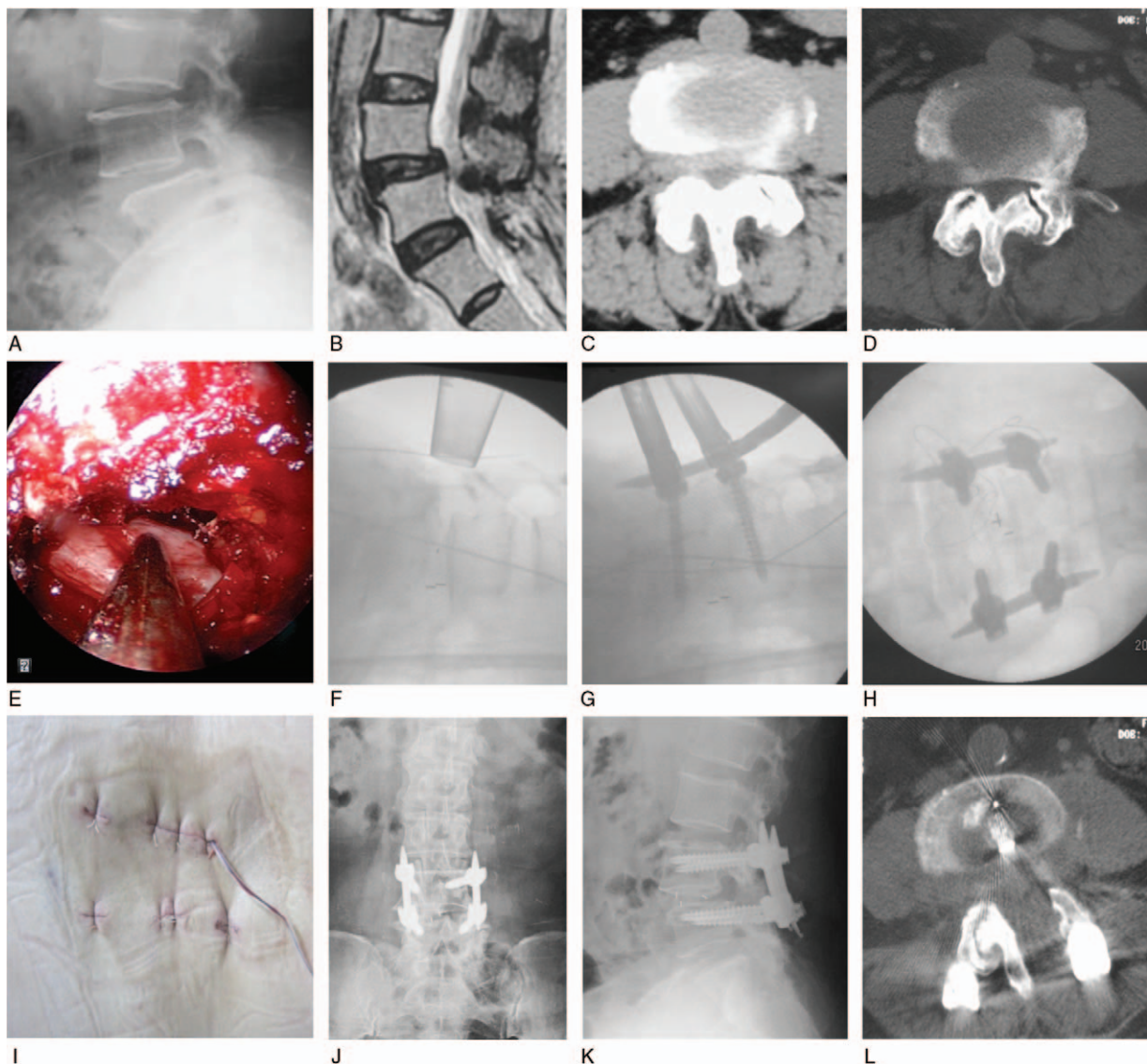


Figure 2. A 64-year-old woman with L4,5 spinal stenosis combined with spondylolisthesis was treated with bilateral decompression via left fenestration and intervertebral fusion using the MMED technique. The symptoms disappeared after the operation, and the clinical result was excellent. (A) Preoperative x-ray showing L4/5 spondylolisthesis. (B) Preoperative MRI showing L4,5 disc protrusion combined with spondylolisthesis. (C and D) Preoperative CT scans showing L4,5 bilateral spinal stenosis. (E) Intraoperative endoscopic vision showing the contralateral nerve root after undermined contralateral decompression. (F) Intraoperative radiological image showing bone grafting and intervertebral fusion. (G) Intraoperative radiological image showing the placement of the connecting rod after the insertion of percutaneous screws. (H) Anteroposterior x-ray showing good positioning of the connecting rod. (I) There was one 2.5 cm incision for decompression (a negative pressure drainage was placed), 2 contralateral incisions for the placement of pedicle screws, and 2 incisions for the puncture of the connecting rods. (J and K) Postoperative anteroposterior and lateral x-rays showing good position of instruments and improved spondylolisthesis. (L) Postoperative CT scans revealing bilateral decompression, enlargement of the canal, intact contralateral structure and good position of the cage. CT=computed tomography, MMED=mobile microendoscopic discectomy, MRI=magnetic resonance imaging.

fusion using MMED technique for the treatment of complex lumbar spinal stenosis, which has not been reported until now.

5.2. The advantages of decompression and fusion with MMED technique

The MMED system, designed by Destandau, is a mobile and self-balancing system with outer and inner conical tubes. The system can be moved and tilted easily, as well as the vision field, and the direction of instruments is various as needed.^[18] Lysoń et al^[19] treated 45 patients of lumbar disc prolapse with MMED, fenestration, and discectomy were easily and successfully performed with good to excellent outcomes in 89% of patients.

Our team has treated more than 2000 patients using MMED, and BDUF was performed for more than 300 cases of canal stenosis.^[18] In recent years, we found that even complex lumbar spinal stenosis can be adequately decompressed, and the intervertebral space can be prepared and grafted with MMED technique, so this technique has been used routinely for decompression and fusion of complex lumbar stenosis in our department. Since this technique has not been reported for fusion surgery in the literature, the advantages and disadvantages are analyzed according to our application as follow.

First, adequate bilateral decompression can be obtained with a less-invasive maneuver using MMED. The thickened lamina and medial part of articular process can be removed with burring

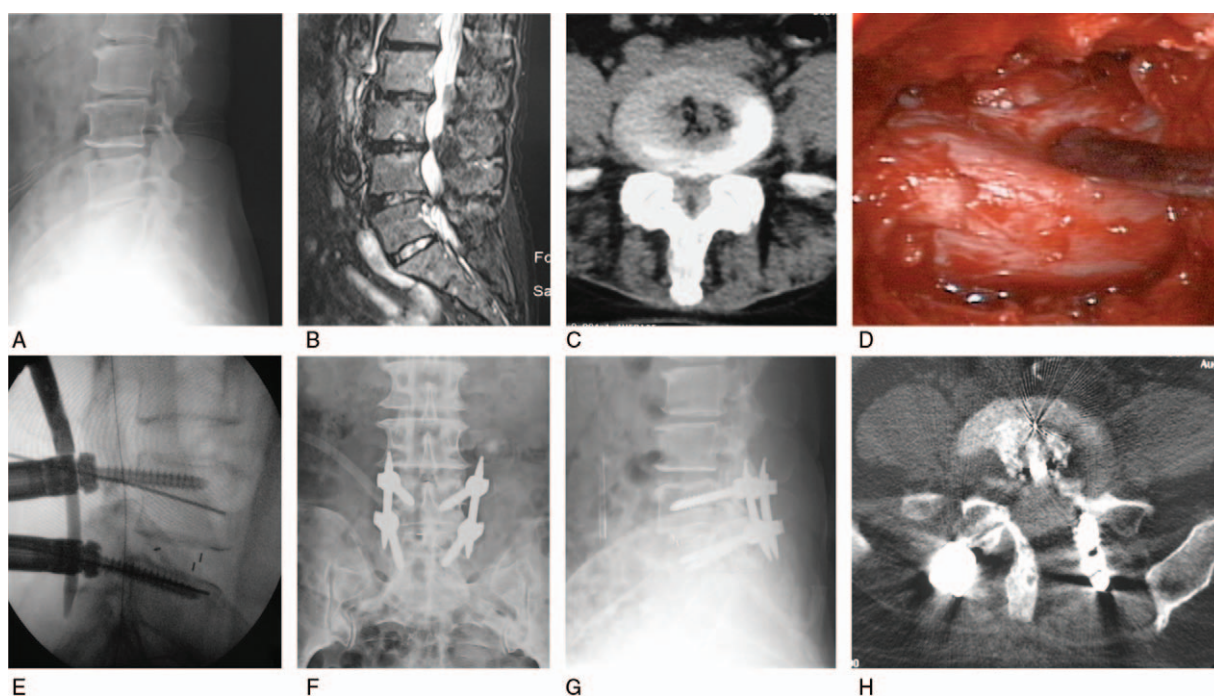


Figure 3. A 60-year-old woman with L4,5 spinal stenosis and retrospondylolisthesis had claudication for 8 years, she was treated with bilateral decompression via left fenestration and intervertebral fusion using the MMED technique. The symptoms resolved after operation with Macnab excellent results. (A) Preoperative x-ray showing L4/5 retrospondylolisthesis. (B) Preoperative MRI showing L4,5 disc protrusion and canal stenosis. (C) Preoperative CT scans showing L4,5 bilateral spinal stenosis. (D) Intraoperative endoscopic vision showing bilateral sufficient decompression. (E) Intraoperative fluoroscopy showing that spondylolisthesis was reduced by cage and percutaneous pedicle screw system. (F and G) Postoperative anteroposterior and lateral x-ray showing good positioning of cage and implants. (H) CT scans showing bone graft around cage and bilateral decompression with nearly intact contralateral lamina. CT = computed tomography, MMED = mobile microendoscopic discectomy, MRI = magnetic resonance imaging.

while the dural sac and nerve are protected by thick ligamentum flavum, which is detached and resected by maneuver that does not further squeeze the compressed nerve with Kerrison in narrow canal. By tilting the tubes toward the contralateral side, hyperplastic ligamentum flavum, and inner layer of the lamina can be clearly exposed and removed with sufficient release of the contralateral nerve root.

Second, the intervertebral space can be prepared sufficiently with MMED system. Since the tube can be moved and tilted by instruments as intended, the cephalad and caudal cartilage endplates could be completely scraped off with various long curettes, exposing bony endplates for grafting. Then the inner tube is extracted, testing molds, and cages no more than 10 mm high can be inserted through the outer tube. For patients with large intervertebral space, self-made larger outer tubes are used for the pass of higher testing mold and cage.

In our cases, the height of the intervertebral space and lumbar lordosis were first restored with the insertion of the cage, which might be beneficial to intervertebral stability and fusion. Percutaneous pedicle screws were installed and residual spondylolisthesis was further reduced using the screws. In our 61 patients of complex lumbar spinal stenosis, sufficient decompression and fusion were successfully performed with adequate release and preparation of the intervertebral space, bone grafting with a suitable cage, and percutaneous fixation, with little blood loss and limited injury to the bones and muscles. The hospital stay was reduced compared to our open surgery (mean blood loss: 238.9 mL and mean postoperative hospital stay: 7.3 days) during the same period.^[20] Postoperative x-rays showed the restoration of spinal alignment, and CT scans revealed sufficient decompression and

good preservation of the contralateral lamina and facet joint. During the follow-up, the ODI score and the lumbar and leg VAS scores decreased significantly, with maintenance of reduction on x-ray. Therefore, sufficient decompression, reduction, and fusion can be achieved using the MMED technique for complex lumbar canal stenosis, with good vision and reduced trauma.

5.3. The pitfalls of intervertebral fusion with the MMED system

The MMED is a mobile system that requires single-hand manipulation, with the left hand holding the suction and the right hand manipulating the instruments, that requires the cooperation of 2 hands and coordination of the hands and eyes. However, this technique is very beneficial for decompression and fusion after it has been mastered, the pitfalls and precaution in our application were summarized as follows. (1) The position and direction of the index intervertebral space should be located and marked under fluoroscopy before operation, and the tube must be installed strictly in the marked direction, otherwise, the tube could deviate to adjacent level, which occurred in our 2 cases. Intraoperative fluoroscopy is indispensable if the index level is not determined. (2) The high-speed bur should be moved horizontally, while vertical movement or pressing of the bur is forbidden to prevent entanglement of the ligaments and nerve. (3) The fenestration should be enlarged laterally to create enough space for the pass of cage, so the majority of inferior articular process and the medial part of the superior articular process are often removed. (4) For contralateral decompression, the dural sac could be protected with cotton piece, and the Kerrison should be

manipulated upward to undercut the lamina and ligamentum flavum. (5) The intervertebral space should be curetted and prepared sufficiently by tilting the instruments, and a larger outer tube is needed for the pass of big cage in case of large intervertebral space. The nerve root should be protected carefully by cotton pieces before insertion of the cage. (6) During installation of percutaneous pedicle screws, the boundary of the pedicle should be carefully identified from hyperplasia bone, and care should be taken to avoid injury to the decompressed nerves. For two-level fusion, the head of middle screw should be in line with the heads of cranial and caudal screws to guarantee the passage of the connecting rod. (7) Appropriate indication should be considered according to the surgeon experience. For patients with severe bony canal stenosis, bilateral decompression or open surgery may be safer. For severe deformities or spondylolisthesis more than 2°, open surgery may be indicated for thorough release, decompression, and reduction.

5.4. The deficiencies of the study

This study did not include a randomized control group due to the variety of patients' conditions and choices; however, these patients had shorter recovery time and hospital stay compared to our patients received open surgery at the same period. Secondly, satisfactory results were achieved in short-term (36 months) follow-up, while the results and efficacy of this technique needs to be evaluated during long-term follow-up.

6. Conclusion

The procedure of bilateral decompression and intervertebral fusion via unilateral fenestration using MMED technique can provide satisfactory clinical results for complex lumbar spinal stenosis, with less surgical trauma and good preservation of stable structure.

References

- [1] Azimi P, Mohammadi HR, Benzel EC, et al. Lumbar spinal canal stenosis classification criteria: a new tool. *Asian Spine J* 2015;9:399–406.
- [2] Gibson JN, Depreitere B, Pflugmacher R, et al. Decompression and paraspinous tension band: a novel treatment method for patients with lumbar spinal stenosis and degenerative spondylolisthesis. *Spine J* 2015;15:S23–32.
- [3] Hansraj KK, O'Leary PF, Cammisa FP Jr, et al. Decompression, fusion, and instrumentation surgery for complex lumbar spinal stenosis. *Clin Orthop Relat Res* 2001;18–25.
- [4] Meyerding HW. Spondylolisthesis. *Surg Gynecol Obstet* 1932;54:371–7.
- [5] Tanaka N, Nakanishi K, Kamei N, et al. Clinical results of microsurgical bilateral decompression via unilateral approach for lumbar canal stenosis with multiple-level involvement. *Eur J Orthop Surg Traumatol* 2015;25:191–8.
- [6] Wada K, Sairyo K, Sakai T, et al. Minimally invasive endoscopic bilateral decompression with a unilateral approach (endo-BiDUA) for elderly patients with lumbar spinal canal stenosis. *Minim Invasive Neurosurg* 2010;53:65–8.
- [7] Xu BS, Destandau J, X Q, et al. Mobile microendoscopic discectomy technique for lumbar disc herniation and canal stenosis. *Zhonghua Gu Ke Za Zhi* 2009;29:112–6.
- [8] Destandau J. A special device for endoscopic surgery of lumbar disc herniation. *Neurol Res* 1999;21:39–42.
- [9] T QS, X BS, X Q, et al. The application of a localizing device in the microendoscopic lumbar discectomy. *Zhonghua Gu Ke Za Zhi* 2010;30:308–9.
- [10] Xu BS, X Q, J N, et al. Bilateral decompression via unilateral fenestration with mobile microendoscopic discectomy technique for canal stenosis of the lumbar spine. *Zhonghua Gu Ke Za Zhi* 2010;30:575–8.
- [11] Macnab I. Negative disc exploration: an analysis of the causes of nerve root involvement in sixty-eight patients. *J Bone Joint Surg (Am)* 1971; 53:891–903.
- [12] Brantigan JW, Steffee AD. A carbon fiber implant to aid interbody lumbar fusion. Two-year clinical results in the first 26 patients. *Spine (Phila Pa 1976)* 1993;18:2106–7.
- [13] Hamasaki T, Tanaka N, Kim J, et al. Biomechanical assessment of minimally invasive decompression for lumbar spinal canal stenosis: a cadaver study. *J Spinal Disord Tech* 2009;22:486–91.
- [14] Guiot BH, Khoo LT, Fessler RG. A minimally invasive technique for decompression of the lumbar spine. *Spine (Phila Pa 1976)* 2002;27:432–8.
- [15] Khoo LT, Fessler RG. Microendoscopic decompressive laminotomy for the treatment of lumbar stenosis. *Neurosurgery* 2002;51(5 suppl):S146–54.
- [16] Morgenstern R, Morgenstern C. Percutaneous transforaminal lumbar interbody fusion (pTLIF) with a posterolateral approach for the treatment of degenerative disk disease: feasibility and preliminary results. *Int J Spine Surg* 2015;9:41.
- [17] Morgenstern R. Full Endoscopic transforaminal lumbar interbody fusion approach with percutaneous posterior transpedicular screw fixation in a case of spondylolisthesis grade I with L4-5 central stenosis correspondence. *J Crit Spine Cases* 2010;3:115–9.
- [18] Xu BS, Tan QS, Xia Q, et al. Bilateral decompression via unilateral fenestration using mobile microendoscopic discectomy technique for lumbar spinal stenosis. *Orthop Surg* 2010;2:106–10.
- [19] Lysoń T, Mariak Z, Jadeszko M, et al. Results of Destandau microendoscopic lumbar discectomy. *Neurol Neurochir Pol* 2008;42:105–11.
- [20] Hey HW, Hee HT. Open and minimally invasive transforaminal lumbar interbody fusion: comparison of intermediate results and complications. *Asian Spine J* 2015;9:185–93.