

# Pterional approach versus unilateral frontal approach on tuberculum sellae meningioma: Single centre experiences

Muhammad Zafrullah Arifin, Ignatius Mardjono, Roland Sidabutar, Beny Atmadja Wirjomartani, Ahmad Faried

Department of Neurosurgery, Faculty of Medicine Universitas Padjadjaran–Dr. Hasan Sadikin General Hospital, Bandung, Indonesia

## ABSTRACT

**Introduction:** Tuberculum Sellae Meningioma is one of the most challenging surgeries among neurosurgeons. Many approaches have been established in the effort of removing the tumor and some of them are supported by an advanced neurosurgical technology. In this study, we aim to compare the efficacy of the two most common approaches, the pterional and the unilateral frontal.

**Materials and Methods:** This was a retrospective study that aimed to observe the efficacy of the two most common approaches used in our center, the pterional and the unilateral frontal, in resecting the tuberculum sellae meningioma, which was held in Dr. Hasan Sadikin General Hospital, Bandung, from July 2007-July 2010. Twenty patients were enrolled with half of them operated by the pterional approach and the rest by unilateral frontal approach. We evaluated six parameters: tumor size, degree of tumor removal, surgery duration, post-operative cerebral edema, patients' outcome, and length of stay, which were evaluated to take measure of the efficacy of each procedure.

**Results:** We found that the pterional approach gave more advantages than the unilateral frontal. Total tumor removal, especially in tumor size  $\geq 3$  cm was achieved in a greater number of subjects in the pterional ( $P < 0.023$ ). Other advantages of the pterional compared to the unilateral frontal were a shorter surgical duration ( $P = 0.024$ ), shorter length of stay ( $P = 0.009$ ) and less frequency of post-operative cerebral edema incidence ( $P = 0.023$ ).

**Conclusion:** According to our facilities and conditions, it seems that the pterional approach have more advantages than the unilateral frontal approach in tuberculum sellae meningioma surgery.

**Key words:** Tuberculum sellae meningioma, pterional approach, unilateral frontal approach

## Introduction

Tuberculum sellae meningioma is one of the most challenging surgeries in neurosurgical field. The tumor may fill the sellar and suprasellar area with dural attachment

generally at tuberculum sellae. This attachment may extend anteriorly to limbus sphenoidale, superiorly to chiasmatic sulcus, and posteriorly to diaphragma sellae. As the tumor grows it will displace, stretch, or even encase vital structures; Optic nerves may displace superiorly, internal carotid arteries may shift to the lateral, and if the tumor extends backward it may push pituitary stalk posteriorly.<sup>[1,2]</sup>

Several surgical approaches such as bifrontal, unilateral frontal, supraorbital keyhole, and pterional were proposed to resect this tumor and we truly understand that the preference of surgical approaches, tactics, and strategies is a surgeon's authority.<sup>[1,3-6]</sup> However, in our institution at Dr. Hasan Sadikin General Hospital we commonly use the pterional and the unilateral frontal approach. The purpose of this study is to compare the efficacy of those two approaches in resecting the tuberculum sellae meningioma.

Access this article online	
Quick Response Code:	Website: www.asianjns.org
	DOI: 10.4103/1793-5482.95691

### Address for correspondence:

Dr. Ignatius Mardjono, Department of Neurosurgery, Faculty of Medicine, Universitas Padjadjaran–Dr. Hasan Sadikin General Hospital, Jl. Pasteur No. 38, Bandung 40161, Indonesia.  
E-mail: joy\_mardjono@yahoo.com

## Materials and Methods

This was a retrospective study that aimed to observe the efficacy of the two most common approaches used in our center, the pterional and the unilateral frontal, in resecting the tuberculum sellae meningioma, which was held in Dr. Hasan Sadikin General Hospital, Bandung, from July 2007 to July 2010. Twenty patients were enrolled in this study; all of them have solely dural attachment to tuberculum sellae. Tumors were operated through pterional approach ( $n=10$ ) and unifrontal frontal approach ( $n=10$ ). Parameters to be evaluated are tumor size, degree of tumor removal, surgery duration, post-operative cerebral edema, patients' outcome, and length of stay to measure the efficacy of each procedure. The design of this study is experimental. Data analysis was performed using SPSS for windows version 13.0., with  $P$  value of  $\leq 0.05$  considered significant.

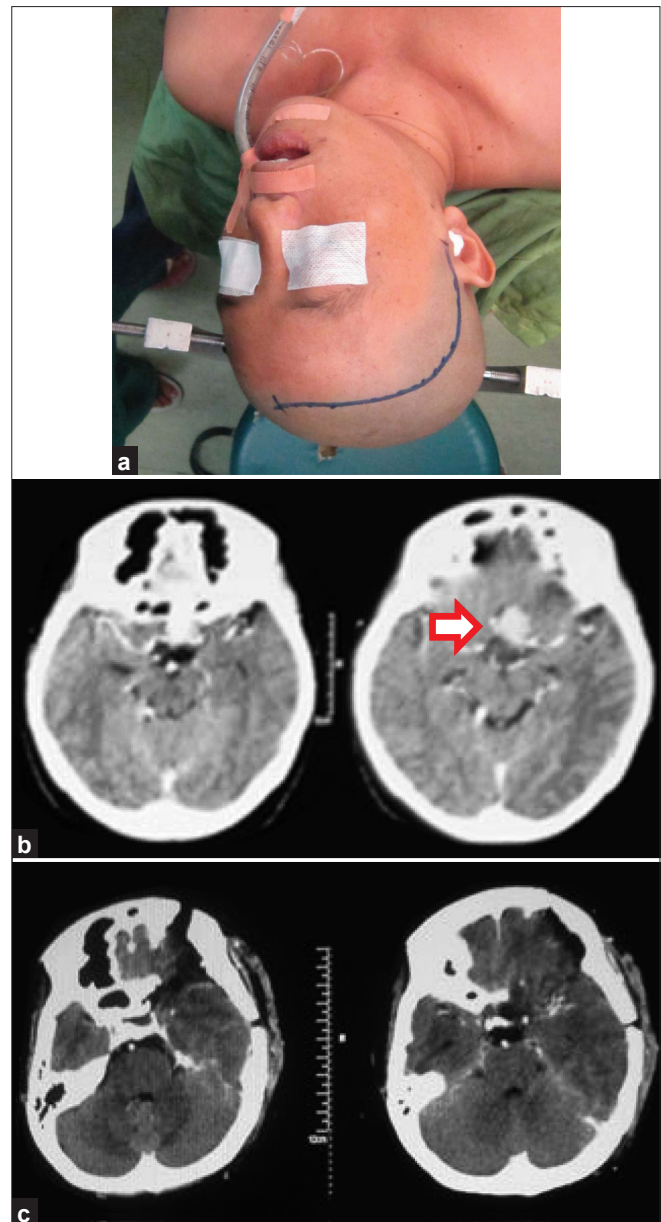
### Pterional approach

This technique is the lateral approach to get the tuberculum sellae meningioma. The patient positioned supine with the head turned about  $45^\circ$  to the opposite side along the *ala minor* of the sphenoid wing and slightly retroflexed about  $10^\circ$  [Figure 1a]. Head fixation is done by using three pins Sugita headrest. The scalp incision starts just anterior to the tragus, behind the superficial temporal artery then it continue superiorly behind the hairline towards the midline. The subgaleal scalp is elevated and we prefer interfascial dissection to preserve the frontal branch of the facial nerve.<sup>[7]</sup> Pericranial flap is transected along the superficial temporal line and prepared for frontal sinus' cranialization or for duroplasty. Temporal muscle is incised to the periosteum, parallel to the skin incision, then the muscle and the pericranium are flapped inferiorly.

Three burr holes are made, the first is located at MacCarthy keyhole, the second is located at the temporal base above the posterior part of the zygoma, and the last is located beneath the temporal line. The bone flap cut is made with the craniotome, from the temporal hole through the squamous suture, the superficial temporal line, and the lateral orbital rim to the keyhole. From the keyhole, the bone cut is continued to the temporal hole making it as a circle. Duramater is opened in curve fashion with sphenoid wing on its base. The next step is splitting the sylvian fissure to drain the cerebrospinal fluids (CSF) and to open the access to the tumor area.

### Unifrontal frontal approach

This approach has been widely used to resect the tuberculum sellae meningioma. This technique is the medial approach to get the tuberculum sellae meningioma. The patient was placed in the supine position with head turned  $20^\circ$ – $30^\circ$  to the contralateral side and slight retroflexion was also performed to allow the frontal lobe slightly fell back, assuming in less



**Figure 1:** Pterional approach marking (a) A representative head CT scan before; (b) and after pterional approach surgery; (c) Red arrow: Tuberculum sellae meningioma

lobe retraction during surgery. Head was fixed using the three pins Sugita headrest. Skin incision was made similar to the pterional approach, but the inferior border was slight superior than the pterional. Two burr holes were made; the first placed on the McCarthy keyhole and the second was placed just above the superior orbital rim, lateral to the frontal sinus. The craniotomy was made using craniotome with bone flap's length about 4 cm and height about 3 cm. If the frontal sinus is exposed intentionally or accidentally, the sinus' mucosa was removed and cauterized. Frontal sinus then tamponaded with bone wax and covered with the pericranial flap. After tacking the dura, it was opened in semilunar fashion with its base toward the orbital rim.

Frontal lobe is slightly retracted to identify the suprachiasmatic cistern and open it to drain the CSF to give more relaxation to the brain. Incision is enlarged to open the sylvian fissure from medial to lateral. The opening of sylvian fissure will facilitate further dissection to reveal and identify major vital structures such as optic nerves, optic chiasm, olfactory nerves, and internal carotid arteries with its major branches. After the vital structures are secured, the next step is to devascularize the tumor followed by tumor mass debulking using suction.

## Results

The study had been held in Neurosurgery Department of Dr. Hasan Sadikin general hospital from 2007 to 2010. We obtained 20 patients with tuberculom sellae meningioma, 16 females and 4 males. Samples were homogenized based on magnetic resonance imaging (MRI) or CT scanning, age distribution, and types of surgical approach. Patient's characteristics are shown in Table 1. Age distribution was between 33 and 44 years ( $38.8 \pm 5.493$ ), the mean age in the pterional group was  $41.4 \pm 8.39$ , and the mean age in the subfrontal group was  $40.4 \pm 7.21$  years old. Dr. Hasan Sadikin Hospital Neuro-oncology team did all surgeries.

In our series total removal was achieved in eleven patients and partial removal in nine patients. Among the total tumor removal eight of them was achieved with pterional approach [Figure 1b and c] and the rest three patients with unilateral frontal approach. Post-operation cerebral edema occurred in nine patients, 22.2% in patients with pterional approach and 77.8% in patients with unilateral frontal. Mean surgical length in pterional and unilateral frontal approach were 6.3 hours and 8.7 hours, respectively [Table 2].

## Discussions

There are many publications of surgical approaches to tuberculom sellae meningioma since its first report. All of these approaches have their advantages and disadvantages, but in the present time only several approaches are popular among neurosurgeons, those are pterional, unilateral frontal, frontolateral, bifrontal, and their modifications, and transsphenoid.<sup>[1,5,6]</sup> In our institution, resecting tuberculom sellae meningioma is usually performed with pterional and unilateral frontal approach.

The pterional approach was first popularized by Yasargil and has been used to treat various pathological conditions in skull base.<sup>[7]</sup> This approach is usually combined with the transsylvian approach to expose the sellar–parasellar, anterior skull base, and central skull base regions. Our rationale to use this approach is a consideration of taking advantages of natural planes and spaces in which nature has provided to expose the base of the brain without significant brain

**Table 1: Patient characteristics**

Characteristic	Frequency	%
Age	$38,8 \pm 5,493$ YO	
Sex		
Male	8	40,0
Female	12	60,0
Tumor size		
$\geq 3$ cm	9	45,0
$< 3$ cm	11	55,0
Surgical time	$7,5 \pm 2,236$ hours	
LOS	$7,4 \pm 3,662$ days	
Removal		
Total	11	55,0
Partial	9	45,0
Outcome		
Alive	13	65,0
Death	7	35,0

YO – Years old; LOS – Length of stay

**Table 2 : Paired test variable in tuberculom sellae meningioma patients**

	Pterional	Unilateral subfrontal	P value
Degree of removal			0.023*
Total removal	8	3	
Partial removal	2	7	
Post operative edema			0.023*
Positive	2	7	
Negative	8	3	
Length of stay	5.8 days	9 days	0.009
Surgical length	6.3 hours	8.7 hours	0.024
Outcome			0.678
Alive	7	6	
Dead	3	4	

retraction. The advantages of pterional approach are early visualization of optic apparatus and internal carotid artery (ICA), attacking side is on the more severe optic nerve palsy, shorter distance to sellar region, and less retraction of frontal lobe.<sup>[8]</sup> The disadvantages of pterional approach are narrow space and angle, and risk of profuse bleeding when removing the tumor.<sup>[6-12]</sup>

The unilateral frontal approach is quite popular to expose the anterior skull base and sellar region. Its direct and wide exposure of the anterior skull base structure is its power; its accessibility to ethmoidal arteries is very helpful to devascularize the tumor and decrease the risk of profuse bleeding. There are several unfavorable things about this approach, such as the need of more frontal lobe retraction to expose the surgical field, the longer access to get the sellar region, the limitation to expose the optic apparatus and parasellar region, the higher chance of CSF leakage, the limitation of surgical view by prominent orbital roof, and the higher risk of olfactory nerves injury.<sup>[5,6,8,13-15]</sup>

**Table 3: Surgical time for each approach**

Hours	Duration of operating TSM tumor						Total
	5	6	7	9	10	12	
Approach TSM tumor							
Pterional patient	4	2	3	0	1	0	10
Unilateral subfrontal patient	0	2	2	3	1	2	10
Total	4	4	5	3	2	2	20

TSM – Tuberculoma sellae meningioma

**Table 4: ICU length of stay after surgery**

Days	LOS patient with TSM tumor										
	2	3	4	5	6	7	8	9	10	12	18
Pterional patients	2	1	1	0	1	1	3	0	1	0	0
Unilateral subfrontal patients	0	0	0	1	2	1	1	2	1	1	1
Total	2	1	1	1	3	2	4	2	2	1	1

ICU – Intensive care unit; LOS – Length of stay; TSM – Tuberculoma sellae meningioma

In our studies, we found that several things are consistent to the previous report, except the increase number of post operative cerebral edema that occurred more often in patients with unilateral frontal approach, as shown in Table 2. (pterional=2 patients, unilateral frontal=7 patients,  $P=0.023$ ). In these series, no major bleeding occurred, assuming that the edema was the result of frontal lobe over retraction. In purpose to reduce the brain edema, we used the standard neuroanesthetic method, mannitol, and drained the liquid cerebrospinal (LCS) by opening the arachnoid. The LCS drainage seemed very helpful to relax the brain during surgery, but it did not for the unilateral subfrontal approach. The problem in such condition was the swollen brain; it seems that the LCS drainage from cerebral arachnoid was not enough to reduce the edema. We assume that the application of lumbar drainage for reducing the brain edema would be helpful.

The gross total removal was better achieved with the pterional compared to the unilateral frontal (Table 2; pterional=8; unilateral frontal=3,  $P=0.023$ ). This is due to the involvement of the optic nerve that somewhat has a certain degree of difficulty to be removed from the anterior direction. Duration of operation was faster in pterional surgery with mean time 6.3 h, while unilateral frontal surgery has a mean time of 8.7 h ( $P=0.024$ ) as shown in Tables 2 and 3. The other significant difference we found is the length of stay (LOS), we found that patient with pterional surgery had a shorter intensive care unit (ICU) days as shown in Tables 2 and 4 (mean: 5.8 days vs. 9 days of unilateral frontal,  $P=0.009$ ). We presumed that the ICU LOS had a correlation with the event of post-operative cerebral edema.

The patient's outcome is 7 patients died (pterional: 3 patients and unilateral frontal: 4 patients). The cause of death are assumed to be associated with hypothalamic injury, pneumonia, and brain herniation.

## Conclusions

Many studies have been reported about the advantages and disadvantages of these two approaches. We believe that every neurosurgeon has his authority in preferences, tactics, and strategies in treating tuberculoma sellae meningioma. In our institution, it seems that the pterional approach is more effective in treating the tumor than the unilateral frontal.

## References

- Nakamura M, Samii M. Surgical management of tuberculoma sellae meningioma. In: Ramina R, Aguiar PH, Tatagiba M, (editors): Samii's Essentials in Neurosurgery. Berlin, Heidelberg: Springer Verlag; 2008. p. 98-105.
- Kinjo T, Al-Mefty O, Ciric I. Diaphragma Sellae Meningioma. Neurosurgery 1995;36:197-209.
- Samii M, Gerganov VM. Surgery of extra-axial tumors of the cerebral base. Neurosurgery 2008;(Suppl 3):1153-61.
- Jallo G, Benjamin V. Tuberculoma sellae meningioma: Microsurgical anatomy and surgical technique. Neurosurgery 2002;51:1432-40.
- Knosp E. Management of anterior fossa lesion. In: Sindou M, (editor): Practical Handbook of Neurosurgery from Leading Neurosurgeons. New York: Springer Verlag; 2009. p. 79-94.
- Nakamura M, Roser F, Struck M, Vorkapic P, Samii M. Tuberculoma sellae meningiomas: Clinical outcome considering different surgical approaches. Neurosurgery 2006;59:1019-29.
- Yasargil MG. Interfascial pterional (frontotemporosphenoidal) craniotomy. In: Yasargil MG, (editor). Microneurosurgery. Stuttgart: George Thieme Verlag; 1984. p. 215-20.
- Vallo B, Russel S. Tuberculoma sellae meningioma. Neurosurgery 2005;56(ONS Suppl 2):411-7.
- Goel A, Muzumdar D, Desai K. Tuberculoma sellae meningiomas: Management on the basis of surgical experiences with 70 patients. Neurosurgery 2002;51:1358-64.
- Fahlbusch R, Schott W. Pterional surgery of meningiomas of the tuberculoma sellae and planum sphenoidale: Surgical results with special consideration of ophthalmological and endocrinological outcomes. J Neurosurg 2002;96:235-43.
- Shick U, Hassler W. Surgical management of tuberculoma sellae meningioma: Involvement of the optic canal and visual outcome. J Neurol Neurosurg Psychiatry 2005;76:977-83.
- Ciric I, Rosenbalt S. Suprasellar meningiomas. Neurosurgery 2001;49:1372-7.
- Al-Mefty O, Smith R. Tuberculoma sellae meningiomas. In: Al-Mefty O, (editor) Meningiomas. New York: Raven Press; 1991.p. 395-411.
- Chi J, McDermott M. Tuberculoma sellae meningioma. Neurosurg Focus 2003;14:e6.
- Mahmoud M, Nader R, Al-Mefty O. Optic canal involvement in tuberculoma sellae meningiomas: Influence on approach, recurrence, and visual recovery. Neurosurgery 2010;66(ONS Suppl 1):108-19.

**How to cite this article:** Arifin MZ, Mardjono I, Sidabutar R, Wirjomartani BA, Faried A. Pterional approach versus unilateral frontal approach on tuberculoma sellae meningioma: Single centre experiences. Asian J Neurosurg 2012;7:21-4

**Source of Support:** Nil, **Conflict of Interest:** None declared.