

Arthroscopically Assisted Reduction of Sagittal-Plane Disruption of Distal Tibiofibular Syndesmosis



Yiu Ho Sin, M.B.Ch.B., and
Tun Hing Lui, M.B.B.S.(HK), F.R.C.S.(Edin), F.H.K.A.M., F.H.K.C.O.S.

Abstract: Injuries to the distal tibiofibular syndesmosis can occur in conjunction with ankle fractures. Sagittal instability of the syndesmosis is more critical than coronal instability and must be taken into account when considering reduction and fixation of the syndesmosis. The purpose of this Technical Note is to report the technique of arthroscopically assisted reduction of sagittal-plane disruption of the distal tibiofibular syndesmosis. This ensures a comprehensive assessment of the pattern of syndesmotic disruption, which can aid anatomic reduction of the syndesmosis.

Stability of the distal tibiofibular syndesmosis relies on the ligamentous structures and the bony architecture.¹⁻³ Injuries to the syndesmosis can occur in conjunction with ankle fractures 13% to 50% of the time.^{4,5} Some of the injuries can lead to instability of the syndesmosis, which can be either latent or frank instability.⁶ If the unstable syndesmosis is missed or not properly reduced and stabilized, chronic syndesmosis instability and early degeneration of the ankle joint can result.⁷ During open reduction and internal fixation of ankle fractures, surgeons should assess the integrity of the syndesmosis. It should be noted that coronal, sagittal, rotational, or longitudinal instability of the syndesmosis can occur.^{8,9} A combination of frank and latent instability of the syndesmosis in different planes can occur.^{8,9} The fibula shows maximal motion in the sagittal plane with disruption of the syndesmosis.¹⁰ Intraoperative assessment of frank sagittal instability under fluoroscopy is unreliable because measurements

on lateral images to assess the syndesmosis have not been well defined.¹⁰ Moreover, the anteroposterior view is not sensitive to detect sagittal instability because there is no increase in tibiofibular clear space.¹¹ An intraoperative stress test under fluoroscopy for latent sagittal instability is also unreliable. Translation of the lateral malleolus in the sagittal plane cannot be measured reliably with conventional radiology because of the external rotation of the ankle itself during stress examination.¹² Advanced intraoperative imaging techniques, such as 3-dimensional fluoroscopic imaging, are useful for assessment of the integrity of the syndesmosis. However, they are not always available. Ankle arthroscopy allows assessment of frank or latent instability of the syndesmosis in the coronal, sagittal, and transverse planes.^{8,9} It can also detect any associated chondral lesions.¹³

The purpose of this Technical Note is to report the technique of arthroscopic assessment and reduction of sagittal-plane disruption of the distal tibiofibular syndesmosis. This is important because sagittal instability seen during anterior and posterior stress testing of the fibula is far more accurate than isolated coronal-plane stress testing for accurately diagnosing syndesmotic instability.¹⁴ This is especially true if ankle distraction is applied because the syndesmosis diastasis in the coronal plane will be significantly less compared with arthroscopic evaluation in the

From the Department of Orthopaedics and Traumatology, North District Hospital, Sheung Shui, China.

The authors report that they have no conflicts of interest in the authorship and publication of this article. Full ICMJE author disclosure forms are available for this article online, as [supplementary material](#).

Received December 16, 2018; accepted January 22, 2019.

Address correspondence to Tun Hing Lui, M.B.B.S.(HK), F.R.C.S.(Edin), F.H.K.A.M., F.H.K.C.O.S., Department of Orthopaedics and Traumatology, North District Hospital, 9 Po Kin Road, Sheung Shui, NT, Hong Kong SAR, China. E-mail: luithderek@yahoo.co.uk

© 2019 by the Arthroscopy Association of North America. Published by Elsevier. This is an open access article under the CC BY-NC-ND license (<http://creativecommons.org/licenses/by-nc-nd/4.0/>).

2212-6287/181521

<https://doi.org/10.1016/j.eats.2019.01.014>

Table 1. Indications and Contraindications of Arthroscopically Assisted Reduction of Sagittal-Plane Disruption of Distal Tibiofibular Syndesmosis

Indications	Contraindications
All ankle fractures undergoing open reduction and internal fixation	No contraindication

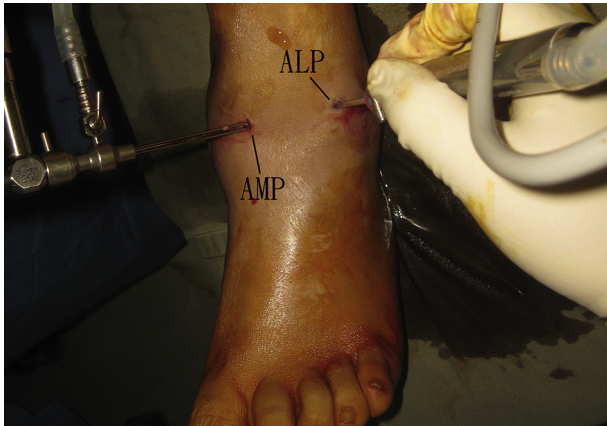


Fig 1. Arthroscopically assisted reduction of sagittal-plane disruption of distal tibiofibular syndesmosis of the left ankle. The patient is in the supine position with the hip and knee flexed. Ankle arthroscopy is performed using the anteromedial portal (AMP) and anterolateral portal (ALP).

absence of distraction.¹⁵ In contrast, measurement of sagittal-plane disruption of the syndesmosis is not affected by ankle distraction.¹⁵ This procedure is indicated in all ankle fractures undergoing open reduction and internal fixation. There is no absolute contraindication to this arthroscopic procedure (Table 1).

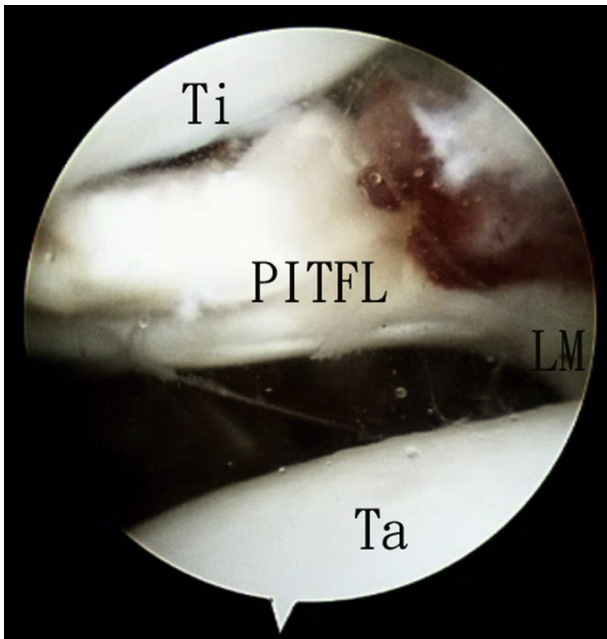


Fig 2. Arthroscopically assisted reduction of sagittal-plane disruption of distal tibiofibular syndesmosis of the left ankle. The patient is in the supine position with the hip and knee flexed. The anteromedial portal is the viewing portal, and the anterolateral portal is the working portal. The integrity of the posterior inferior tibiofibular ligament (PITFL) is assessed. In the illustrated case, the ligament is ruptured in its tibial insertion. (LM, lateral malleolus; Ta, talar dome; Ti, tibia.)

Technique

Preoperative Planning and Patient Positioning

Computed tomography (CT) is a useful preoperative investigation to study frank disruption of the syndesmosis. There is significant variance in the bony anatomy of the syndesmosis between individuals, but there is minimal difference between the ankles of the same patient.¹⁰ The uninjured ankle provides a precise definition of normal tibiofibular relations, and therefore, CT of both ankles should be performed.¹⁰ Syndesmosis assessment using an axial CT scan at the joint level best correlates with the arthroscopic examination.¹⁶ However, latent instability of the syndesmosis cannot be detected by this static investigation. Moreover, the pattern of syndesmosis disruption as shown on preoperative CT may not be the same after reduction and fixation of the ankle fractures.

The patient is placed in the supine position. The hip and knee are flexed with a triangular supporting frame (Innomed, Savannah, GA) under the knee. This can relax the triceps surae. No continuous ankle traction is used. A thigh tourniquet is applied to provide a bloodless surgical field. Fluid inflow is by gravity, and no arthro-pump is used. A 2.7-mm 30° arthroscope (Henke Sass Wolf, Tuttlingen, Germany) is used for this procedure.

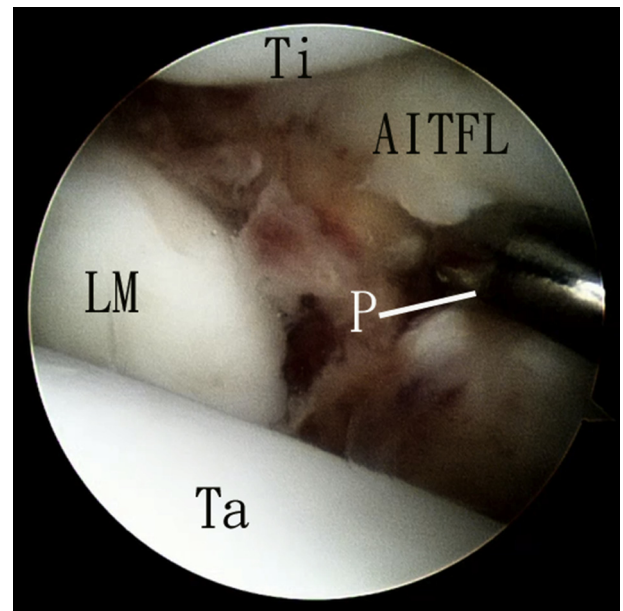


Fig 3. Arthroscopically assisted reduction of sagittal-plane disruption of distal tibiofibular syndesmosis of the left ankle. The patient is in the supine position with the hip and knee flexed. The anteromedial portal is the viewing portal, and the anterolateral portal is the working portal. The integrity of the anterior inferior tibiofibular ligament (AITFL) is assessed. In the illustrated case, the AITFL is torn at its fibular insertion. (LM, lateral malleolus; P, arthroscopic probe; Ta, talar dome; Ti, tibia.)

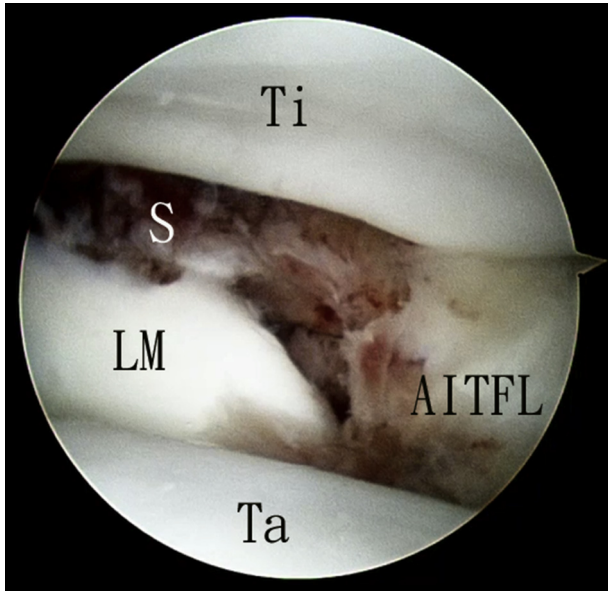


Fig 4. Arthroscopically assisted reduction of sagittal-plane disruption of distal tibiofibular syndesmosis of the left ankle. The patient is in the supine position with the hip and knee flexed. The anteromedial portal is the viewing portal. Diastasis of the distal tibiofibular syndesmosis (S) is seen. (AITFL, anterior inferior tibiofibular ligament; LM, lateral malleolus; Ta, talar dome; Ti, tibia.)

Portal Placement

The standard anterolateral and anteromedial ankle arthroscopy portals are used (Fig 1). The anterolateral portal is just lateral to the peroneus tertius tendon, and the anteromedial portal is just medial to the tibialis anterior tendon. Three- to four-millimeter skin incisions

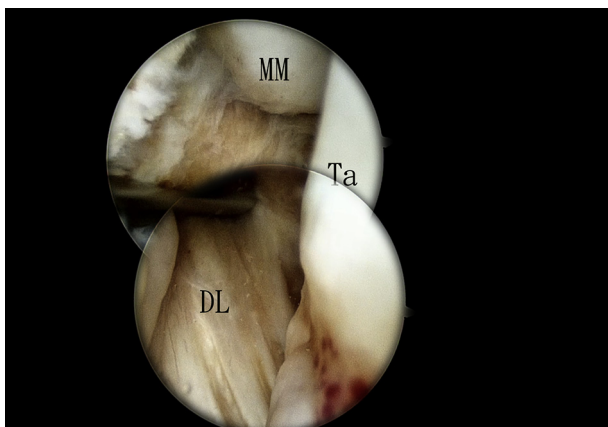


Fig 5. Arthroscopically assisted reduction of sagittal-plane disruption of distal tibiofibular syndesmosis of the left ankle. The patient is in the supine position with the hip and knee flexed. The anterolateral portal is the viewing portal, and the anteromedial portal is the working portal. The anterior part of the deep deltoid ligament (DL) (deep anterior tibiotalar ligament) is traced from the medial malleolus (MM) down to the medial talus (Ta).

are made at the portal sites. The subcutaneous tissue is bluntly dissected down to the anterior ankle capsule with a hemostat. The capsule is pierced by the hemostat.

Assessment of Integrity of Posterior Inferior Tibiofibular Ligament

The anteromedial portal is the viewing portal, and the anterolateral portal is the working portal. The inflamed synovium is resected with an arthroscopic shaver (Dyonics; Smith & Nephew, Andover, MA). The integrity of the posterior inferior tibiofibular ligament is assessed in its whole span from the fibular to tibial side. Any substance tear or the presence of a posterior malleolar fracture is noted. In the illustrated case, the posterior inferior tibiofibular ligament is torn at its tibial insertion (Fig 2).

Assessment of Integrity of Anterior Inferior Tibiofibular Ligament

The anteromedial portal is the viewing portal, and the anterolateral portal is the working portal. The arthroscope is placed in the joint proper as well as in the anterior ankle recess to obtain a complete assessment of the anterior inferior tibiofibular ligament. The ligament is examined for any tear. In the illustrated case, the anterior inferior tibiofibular ligament is torn at its fibular insertion (Fig 3).

Assessment of Sagittal-Plane Stability of Distal Tibiofibular Syndesmosis

The anteromedial portal is the viewing portal, and the anterolateral portal is the working portal. The interosseous

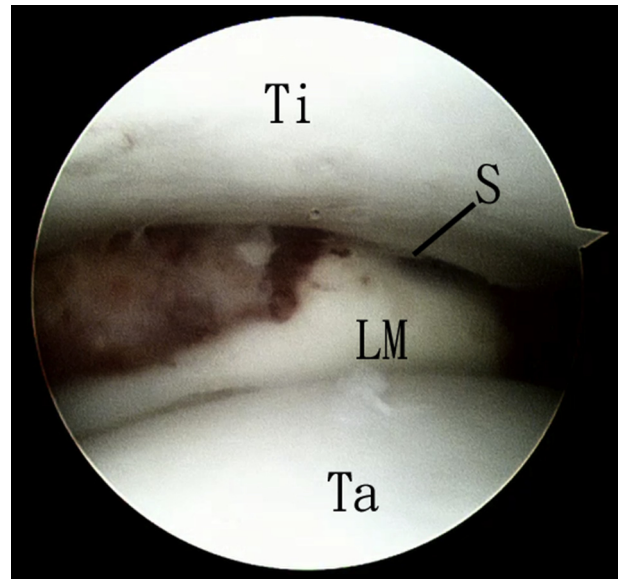


Fig 6. Arthroscopically assisted reduction of sagittal-plane disruption of distal tibiofibular syndesmosis of the left ankle. The patient is in the supine position with the hip and knee flexed. The anteromedial portal is the viewing portal. The distal tibiofibular syndesmosis (S) is reduced. (LM, lateral malleolus; Ta, talar dome; Ti, tibia.)

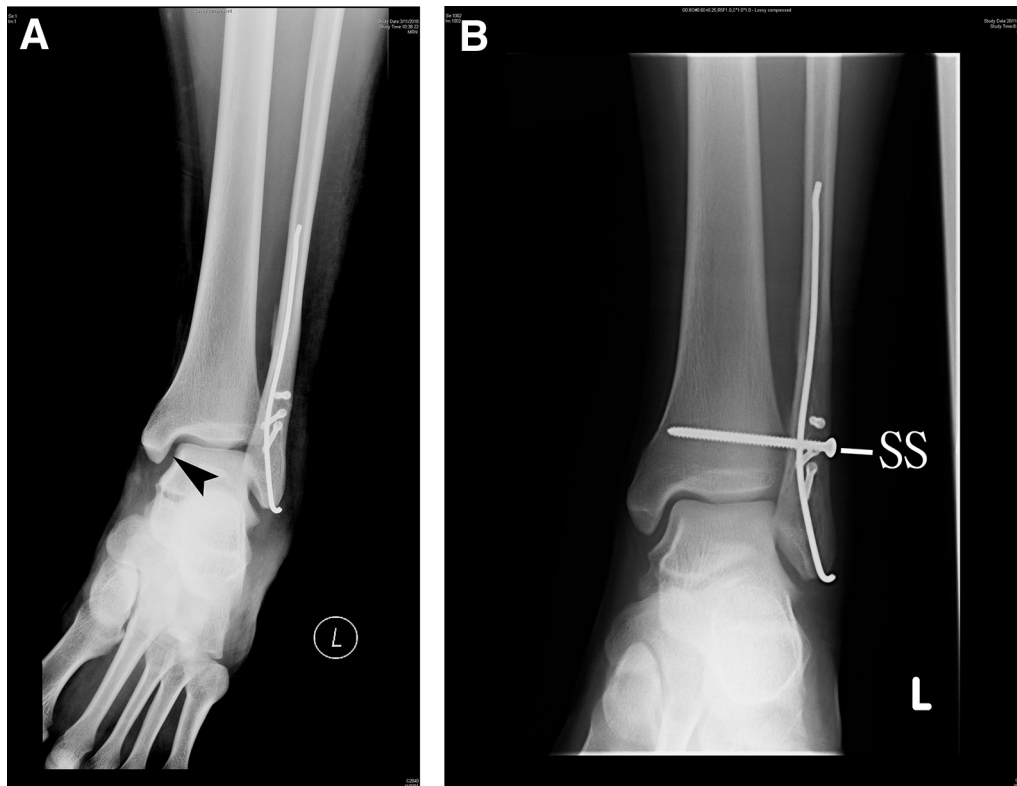


Fig 7. Arthroscopically assisted reduction of sagittal-plane disruption of distal tibiofibular syndesmosis of the left ankle (L). The patient is in the supine position with the hip and knee flexed. (A) The ankle radiograph of the illustrated case before arthroscopy showed a widened medial ankle space (arrowhead). (B) The ankle radiograph after arthroscopically assisted reduction and fixation of the syndesmosis showed that the widened medial ankle space was corrected. (SS, syndesmotic screw.)

ligament is a few millimeters above the ankle joint line and usually cannot be visualized by ankle arthroscopy. Diastasis of the syndesmosis can be shown by passage of the arthroscopic shaver through the syndesmosis.¹⁷ Sagittal-plane instability of the syndesmosis can be shown by pushing the lateral malleolus anteriorly and posteriorly (Fig 4).

Assessment of Integrity of Deep Deltoid Ligament

The anterolateral portal is the viewing portal, and the anteromedial portal is the working portal. The anterior part of the deep deltoid ligament (deep anterior tibiotalar ligament) can be traced from the medial malleolus down to the medial talus. In the illustrated case, the deep anterior tibiotalar ligament is intact (Fig 5).

Arthroscopically Assisted Reduction of Syndesmosis

The anteromedial portal is the viewing portal. The syndesmosis is reduced by pushing the lateral malleolus anteriorly until the gap between the tibia and lateral malleolus is closed (Fig 6). The gaps in the torn anterior and posterior inferior tibiofibular ligaments are also closed.

Screw Fixation of Syndesmosis

The reduced syndesmosis is temporarily transfixed with a 1.6-mm K-wire. A syndesmotic screw measuring

3.5 or 4.5 mm (depending on the size of the distal fibula) is inserted 2 to 2.5 cm above the ankle joint (Fig 7, Video 1, Table 2).

Discussion

Sagittal instability of the distal tibiofibular syndesmosis is more critical than coronal instability and must be taken into account when considering reduction and fixation of the syndesmosis.¹⁰ If sagittal-plane disruption of the syndesmosis is misinterpreted as coronal-plane disruption, an inappropriate strategy of reduction of the syndesmosis may be adopted and may lead

Table 2. Pearls and Pitfalls of Arthroscopically Assisted Reduction of Sagittal-Plane Disruption of Distal Tibiofibular Syndesmosis

Pearls	Pitfalls
1. Arthroscopic synovectomy is useful to aid visualization of the syndesmotic and collateral ligaments.	1. The fibular fracture should be properly reduced and fixed to provide a length-stable fibula before the arthroscopic procedure.
2. Besides closing the syndesmosis, anatomic reduction of the syndesmosis can be confirmed by closing the gaps at the torn anterior and posterior inferior tibiofibular ligaments.	2. The reduction of the fibular fracture should be assessed fluoroscopically to avoid shortening or rotational malreduction.

Table 3. Advantages and Risks of Arthroscopically Assisted Reduction of Sagittal-Plane Disruption of Distal Tibiofibular Syndesmosis

Advantages	Risks
1. Comprehensive assessment of injuries to syndesmotiic and collateral ligaments	1. Injury to superficial peroneal nerve
2. Complete picture of syndesmosis disruption can be obtained	2. Injury to saphenous nerve and vein
3. Assessment and treatment of associated chondral lesions	3. Injury to syndesmotiic ligaments and collateral ligaments
	4. Injury to articular cartilage
	5. Malreduction of syndesmosis

to malreduction of the syndesmosis and chronic syndesmosis disruption.

Intraoperative stress radiography fails to detect approximately half of the cases of instability confirmed at arthroscopy.¹⁸ In the presence of associated injuries requiring surgery, arthroscopic viewing with stress examination is the diagnostic benchmark when available.¹⁸ Besides assessment of the pattern of disruption of the syndesmosis and integrity of the syndesmotiic ligaments, the surgeon should pay attention to the integrity of the deltoid ligament because disruption of the deltoid ligament appears to destabilize the syndesmosis in the coronal and sagittal planes when associated with partial disruption of the syndesmosis.^{10,19} In the case of latent instability of the syndesmosis, we still prefer fixation and stabilization of the syndesmosis because the complication rate of syndesmotiic stabilization is low and unaddressed syndesmotiic instability may lead to chronic instability with a poorer prognosis.^{12,14}

The advantages of this arthroscopic technique include performing a comprehensive assessment of the injuries to the syndesmotiic and collateral ligaments, obtaining a complete picture of the syndesmosis disruption, and performing an assessment and treatment of associated chondral lesions. The potential risks include malreduction of the syndesmosis and injuries to the superficial peroneal nerve, the saphenous nerve and vein, the syndesmotiic ligaments, the collateral ligaments, and the articular cartilage (Table 3). Extravasation is common but usually not a problem because no arthro-pump is used and the irrigation fluid will leak out through the lateral incision for reduction and fixation of the fibular fracture. Arthroscopically assisted reduction of sagittal-plane disruption of the distal tibiofibular syndesmosis is not a technically demanding procedure and can be attempted by average foot and ankle arthroscopists.

References

- Hunt KJ. Syndesmosis injuries. *Curr Rev Musculoskelet Med* 2013;6:304-312.
- Ogilvie-Harris DJ, Reed SC, Hedman TP. Disruption of the ankle syndesmosis: Biomechanical study of the ligamentous restraints. *Arthroscopy* 1994;10:558-560.
- Liu Q, Lin B, Guo Z, Ding Z, Lian K, Lin D. Shapes of distal tibiofibular syndesmosis are associated with risk of recurrent lateral ankle sprains. *Sci Rep* 2017;7:6244.
- Warner SJ, Fabricant PD, Garner MR, Schottel PC, Helfet DL, Lorich DG. The measurement and clinical importance of syndesmotiic reduction after operative fixation of rotational ankle fractures. *J Bone Joint Surg Am* 2015;97:1935-1944.
- Latham AJ, Goodwin PC, Stirling B, Budgen A. Ankle syndesmosis repair and rehabilitation in professional rugby league players: A case series report. *BMJ Open Sport Exerc Med* 2017;3:e000175.
- de-Las-Heras Romero J, Alvarez AML, Sanchez FM, et al. Management of syndesmotiic injuries of the ankle. *EFORT Open Rev* 2017;2:403-409.
- Olson KM, Dairyko GH Jr, Toolan BC. Salvage of chronic instability of the syndesmosis with distal tibiofibular arthrodesis: Functional and radiographic results. *J Bone Joint Surg Am* 2011;93:66-72.
- Lui TH, Ip KY, Chow HT. Comparison of radiologic and arthroscopic diagnoses of distal tibiofibular syndesmosis disruption in acute ankle fracture. *Arthroscopy* 2005;21:1370-1374.
- Chan KB, Lui TH. Role of ankle arthroscopy in management of acute ankle fracture. *Arthroscopy* 2016;32:2373-2380.
- Switaj PJ, Mendoza M, Kadakia AR. Acute and chronic injuries to the syndesmosis. *Clin Sports Med* 2015;34:643-677.
- Chan KB, Lui TH. Isolated anterior syndesmosis diastasis without fracture. *Arch Orthop Trauma Surg* 2007;127:321-324.
- van Zuuren WJ, Schepers T, Beumer A, Sierevelt I, van Noort A, van den Bekerom MPJ. Acute syndesmotiic instability in ankle fractures: A review. *Foot Ankle Surg* 2017;23:135-141.
- Da Cunha RJ, Karnovsky SC, Schairer W, Drakos MC. Ankle arthroscopy for diagnosis of full-thickness talar cartilage lesions in the setting of acute ankle fractures. *Arthroscopy* 2018;34:1950-1957.
- Vopat ML, Vopat BG, Lubberts B, DiGiovanni CW. Current trends in the diagnosis and management of syndesmotiic injury. *Curr Rev Musculoskelet Med* 2017;10:94-103.
- Lubberts B, Guss D, Vopat BG, Wolf JC, Moon DK, DiGiovanni CW. The effect of ankle distraction on arthroscopic evaluation of syndesmotiic instability: A cadaveric study. *Clin Biomech (Bristol, Avon)* 2017;50:16-20.
- Ahn TK, Choi SM, Kim JY, Lee WC. Isolated syndesmosis diastasis: Computed tomography scan assessment with arthroscopic correlation. *Arthroscopy* 2017;33:828-834.
- Guyton GP, DeFontes K III, Barr CR, Parks BG, Camire LM. Arthroscopic correlates of subtle syndesmotiic injury. *Foot Ankle Int* 2017;38:502-506.
- Kellett JJ, Lovell GA, Eriksen DA, Sampson MJ. Diagnostic imaging of ankle syndesmosis injuries: A general review. *J Med Imaging Radiat Oncol* 2018;62:159-168.
- Massri-Pugin J, Lubberts B, Vopat BG, Wolf JC, DiGiovanni CW, Guss D. Role of the deltoid ligament in syndesmotiic instability. *Foot Ankle Int* 2018;39:598-603.