

Suturing the Anterior Cruciate Ligament Using a No. 16 Intravenous Catheter Needle in Avulsion Anterior Cruciate Ligament Injury



Korakot Maliwankul, M.D., and Chaiwat Chuaychoosakoon, M.D.

Abstract: Avulsion anterior cruciate ligament injuries are more common in pediatric patients. There are several methods of fixation available for these injuries (tibial intercondylar eminence fractures), such as the pullout suture technique, screw fixation, and suture anchor fixation. Currently, a pullout technique is widely used for fixation. We purpose a pullout technique method using a modified No. 16 intravenous catheter needle to suture the anterior cruciate ligament fiber instead of a suture hook or suture passer. We also use one anterior tibial tunnel for this arthroscopic pullout fixation technique to decrease the incidence of physeal injury in pediatric patients by using many tibial tunnels.

An anterior cruciate ligament (ACL) tear is one of the most common sports injuries. This injury usually results from twisting the knee during a sports activity. In adults, the injury site is usually at the mid-substance ACL tear or at the femoral footprint because bone is stronger than ligaments. This is in contrast to very young patients, in whom the skeletally immature bone is weaker than the ligaments, and thus avulsion ACL injuries are more common in pediatric patients. The key treatment of this injury is to anatomically fix the avulsion fragment to the fracture base. There are several methods of fixation available in these injuries, such as the pullout suture technique,¹⁻³ screw fixation, and suture anchor fixation.⁴

For the pullout technique, there are 2 important steps to achieve a good stability fixation. First, the surgeon must suture the ACL bundle near the base of the bony fragment using a suture hook or a suture passer. This

device is quite expensive and not available in many countries for patients with limited finances. The second step is to create more than one tibial tunnel, which most surgeons use for pullout fixation.¹⁻³ In pediatric patients, more tunnels create a greater risk of physeal injury. With regard to these problems in a pediatric patient, we experimented with a method using a modified No. 16 intravenous (IV) catheter needle (Nipro, Bridgewater, NJ) with a PROLENE No. 1 suture (Ethicon, Raynham, MA) to suture the ACL fiber instead of a suture hook or suture passer, and, using method, we also required only one anterior tibial tunnel technique for this arthroscopic pullout fixation technique.

Surgical Technique

The patient was prepared and sterilely draped in the supine position. A tourniquet was applied and inflated at 250 mm Hg. The knee was set at 90° flexion. Knee arthroscopy was then performed with anterolateral (AL), accessory AL, and anteromedial (AM) portals. The arthroscopic sheath with a camera was inserted into the knee joint via the AL portal. An arthroscopic diagnosis was performed, and the result showed an avulsion injury of the ACL from the tibial bone (Fig 1). After arthroscopic diagnosis, the camera was then moved to the accessory AL portal. A no. 16 IV catheter needle was bent into a 45° crescent curve shape using 2 needle holders (Fig 2 A and B) and loaded with a PROLENE No. 1 suture. The modified no. 16 IV catheter needle was introduced through the AM portal and used to suture the ACL bundle above the bony fragment at the

From the Department of Orthopaedic Surgery and Physical Medicine, Faculty of Medicine, Prince of Songkla University, Songkhla, Thailand.

The authors report that they have no conflicts of interest in the authorship and publication of this article. Full ICMJE author disclosure forms are available for this article online, as [supplementary material](#).

Received March 9, 2020; accepted April 25, 2020.

Address correspondence to Chaiwat Chuaychoosakoon, M.D., Department of Orthopaedic Surgery and Physical Medicine, Faculty of Medicine, Prince of Songkla University, 15 Karnjanavanich Rd., Hat Yai, Songkhla 90112, Thailand. E-mail: psu.chaiwat@gmail.com or chaiwat.c@psu.ac.th

© 2020 by the Arthroscopy Association of North America. Published by Elsevier. This is an open access article under the CC BY-NC-ND license (<http://creativecommons.org/licenses/by-nc-nd/4.0/>).

2212-6287/20337

<https://doi.org/10.1016/j.eats.2020.04.019>

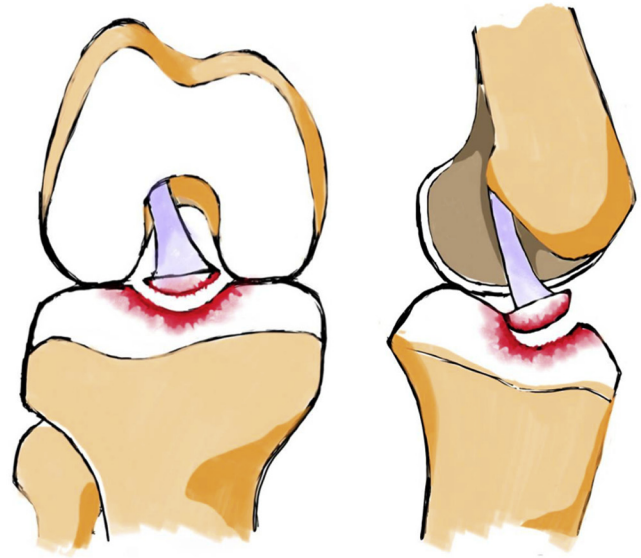
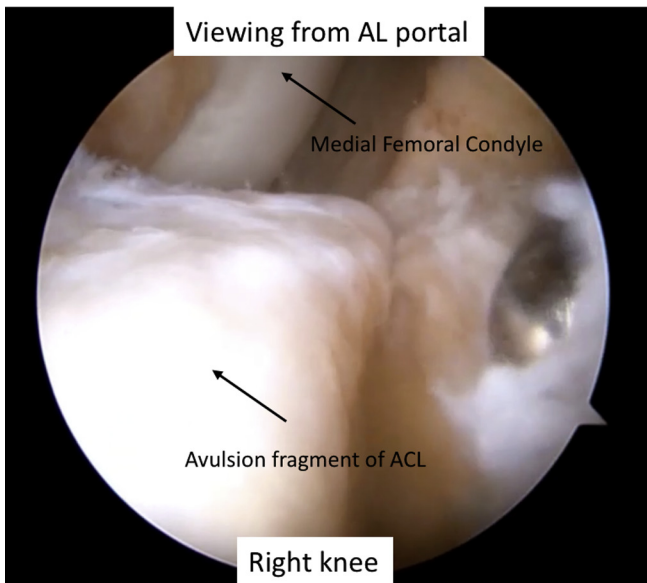


Fig 1. The patient was supine with 90° right knee flexion. The AL was the viewing portal, whereas the AM portal was the working portal. The arthroscopic finding was an avulsion ACL injury. (ACL, anterior cruciate ligament; AL, anterolateral; AM, anteromedial.)

anterior half of the ACL from the medial side (Fig 3A) to the lateral side (Fig 3B). A suture retriever was used to grasp the PROLENE No. 1 suture through the AL portal. The modified no. 16 IV catheter needle was used to stitch the ACL bundle from the medial side to the lateral side at the posterior half of the ACL. Two sutures of PROLENE No. 1 were replaced with ETHIBOND No. 5 (Ethicon, Somerville, NJ) by a shuttle relay technique (Fig 4 A and B). The 4 limbs of the ETHIBOND No. 5 were grasped and brought out through the AM portal using the suture passer. A shaver was inserted through

the AM portal to remove the fibrous tissue and prepare the base of the avulsion fragment and fracture base for fixation (Fig 5). A guide pin was inserted from the AM aspect of tibia to the anterior border of the fracture base using an ACL aiming device. We used the elbow type of aiming device because the key is to use the tip of the aiming device to compress the avulsion fragment during the tibial tunnel creation (Fig 6). The ENDO-BUTTON drill bit was used to drill a hole to create the tibial tunnel. A loop suture of ETHIBOND No. 2 was inserted through the tibial tunnel using the guide pin

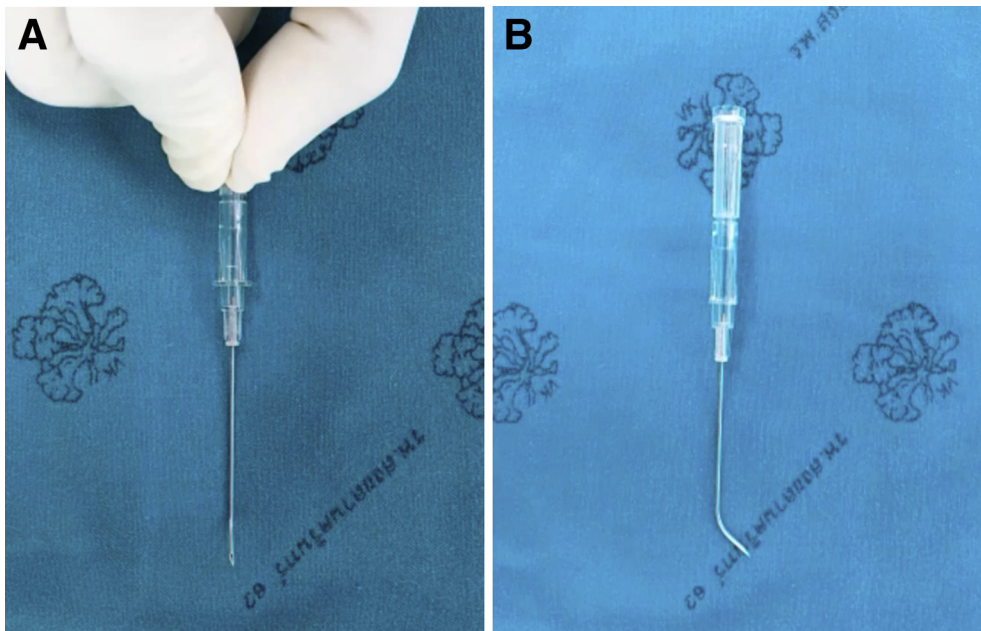
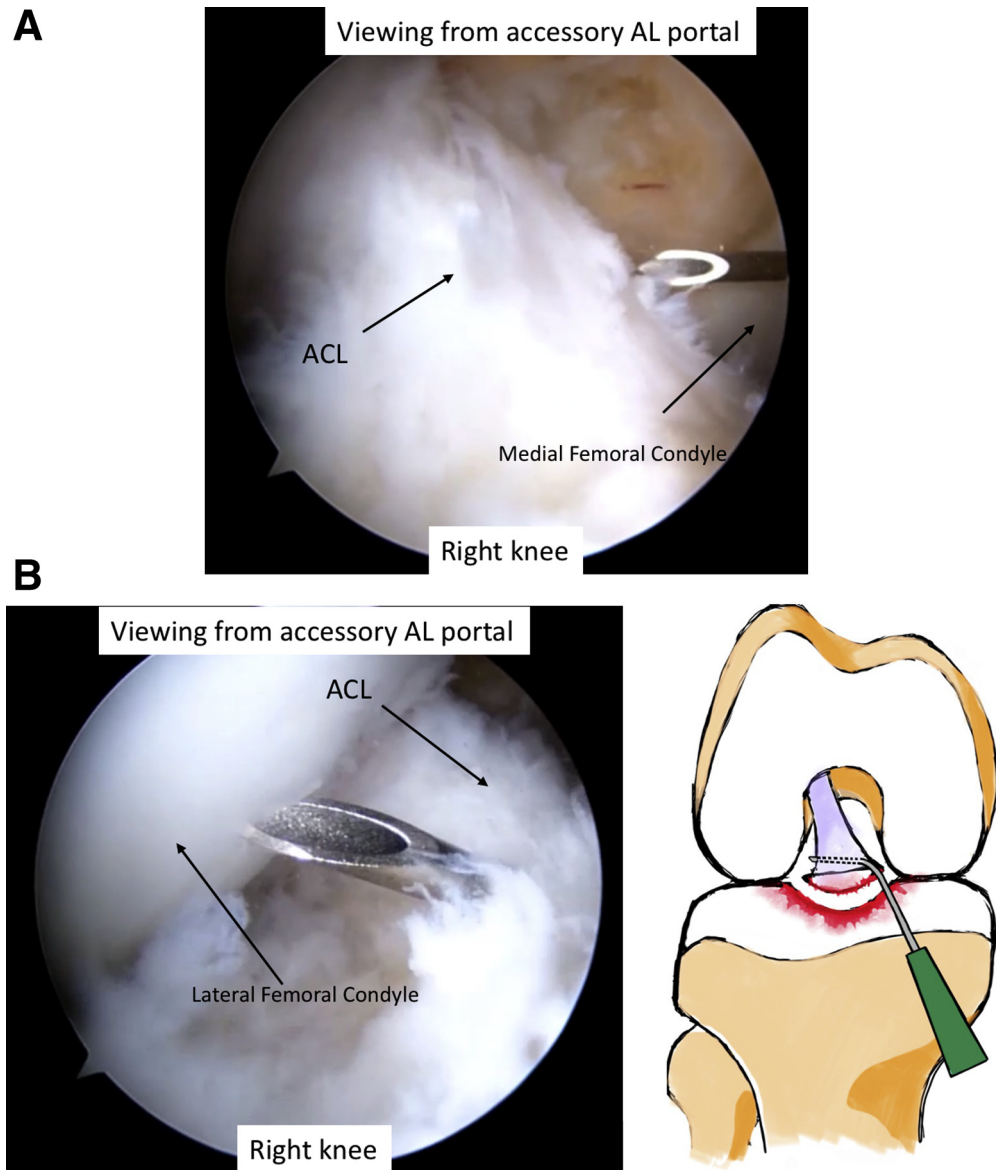


Fig 2. The 45° crescent curve of a no. 16 intravenous catheter needle in top view (A) and lateral view (B).

Fig 3. The patient was supine with the right knee in 90° flexion. The accessory AL was the viewing portal, whereas the AL and AM portals were the working portals. The modified no. 16 intravenous catheter needle was used to stitch the ACL from the medial side (A) to the lateral side (B). (ACL, anterior cruciate ligament; AL, anterolateral; AM, anteromedial.)



then the looped suture of the ETHIBOND No.2 was passed through the AM portal using a suture passer. The 4 limbs of ETHIBOND No. 5 were passed through the tibial tunnel by a shuttle relay technique. The 4 limbs of ETHIBOND No. 5 were pulled down to reduce the avulsion fracture and are tightened over a 3-hole small plate at the AM surface of the tibia. The knee stability was good after examination with Lachman test and anterior Drawer test. Postoperative radiographs (Fig 7 A and B) showed good reduction of the avulsion fracture compared with the preoperative radiographs (Fig 7 C and D). The entire surgical technique is shown in Video 1, with audio narration. Tables 1 and 2 present the key points, advantages, and disadvantages, pitfalls, and some tips for using this technique.

Postoperative Management

The patient's knee was immobilized in the full extension position with a knee brace for 3 weeks, during which the patient was allowed to walk with partial weight-bearing on the operated-on leg axillary crutches. At 3 weeks, the patient began range-of-motion exercises and was encouraged to slowly increase the amount of weight they could bear on the leg.

Discussion

The principle treatment of an avulsion ACL is to fix the bony fragment to the fracture base. In contrast, the purpose of ACL injury treatment is to reconstruct the ACL using an autograft or allograft.

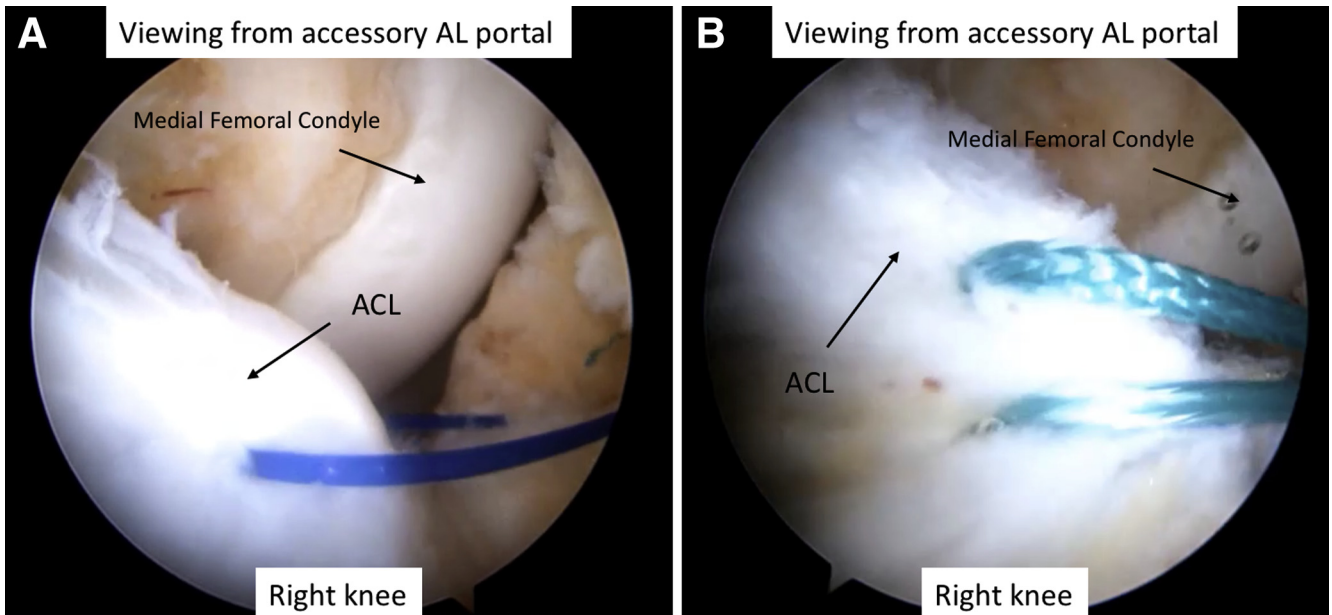


Fig 4. The patient was supine with the right knee in 90° flexion. The accessory AL was the viewing portal, whereas the AM portal was the working portal. Two PROLENE No. 1 sutures (A) were replaced with ETHIBOND No. 5 (B) by a shuttle relay technique. (ACL, anterior cruciate ligament; AL, anterolateral; AM, anteromedial.)

In the past, the gold standard treatment for avulsion ACL was open reduction and internal fixation. There were many surgical approaches to fix the bony fragment, such as screw, suture anchor, and pullout fixations. Nowadays, arthroscopic surgery is widely used rather than open surgery, but the methods of fixation are the same. The benefits of arthroscopic fixation are

that it is less invasive, and the patient normally has a faster recovery.

Screw fixation is a good technique for securing and fixing the bony fragment, but it is most suitable for large

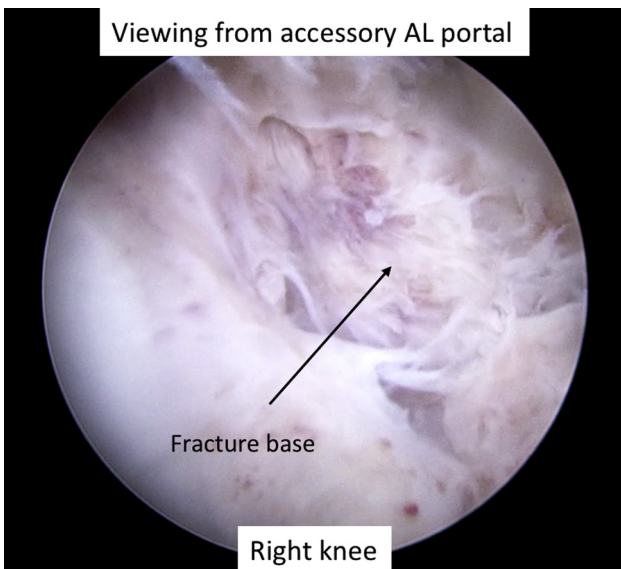


Fig 5. The patient was supine with the right knee in 90° flexion. The accessory AL was the viewing portal, whereas the AM portal was the working portal. A shaver was inserted through the AM portal to remove the fibrous tissue and prepare the base of the avulsion fragment and fracture base for fixation (AL, anterolateral; AM, anteromedial.)

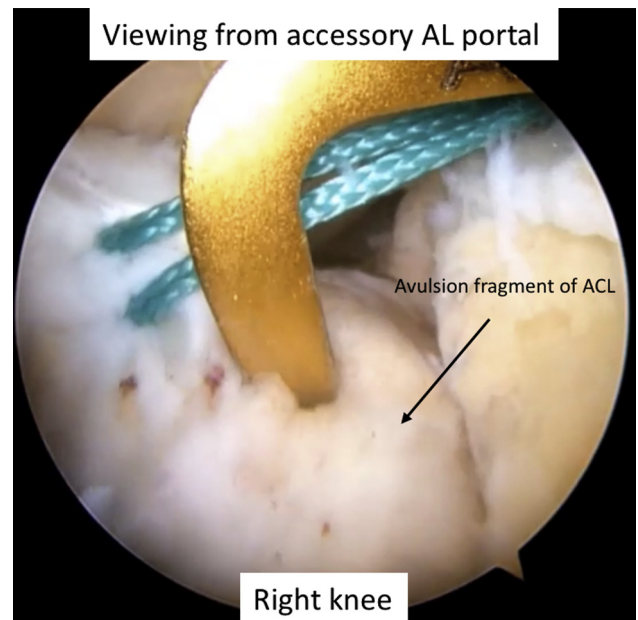


Fig 6. The patient was supine with the right knee in 90° flexion. The accessory AL was the viewing portal, whereas the AM portal was the working portal. The tibial tunnel was created using the elbow type of an ACL aiming device. (ACL, anterior cruciate ligament; AL, anterolateral; AM, anteromedial.)

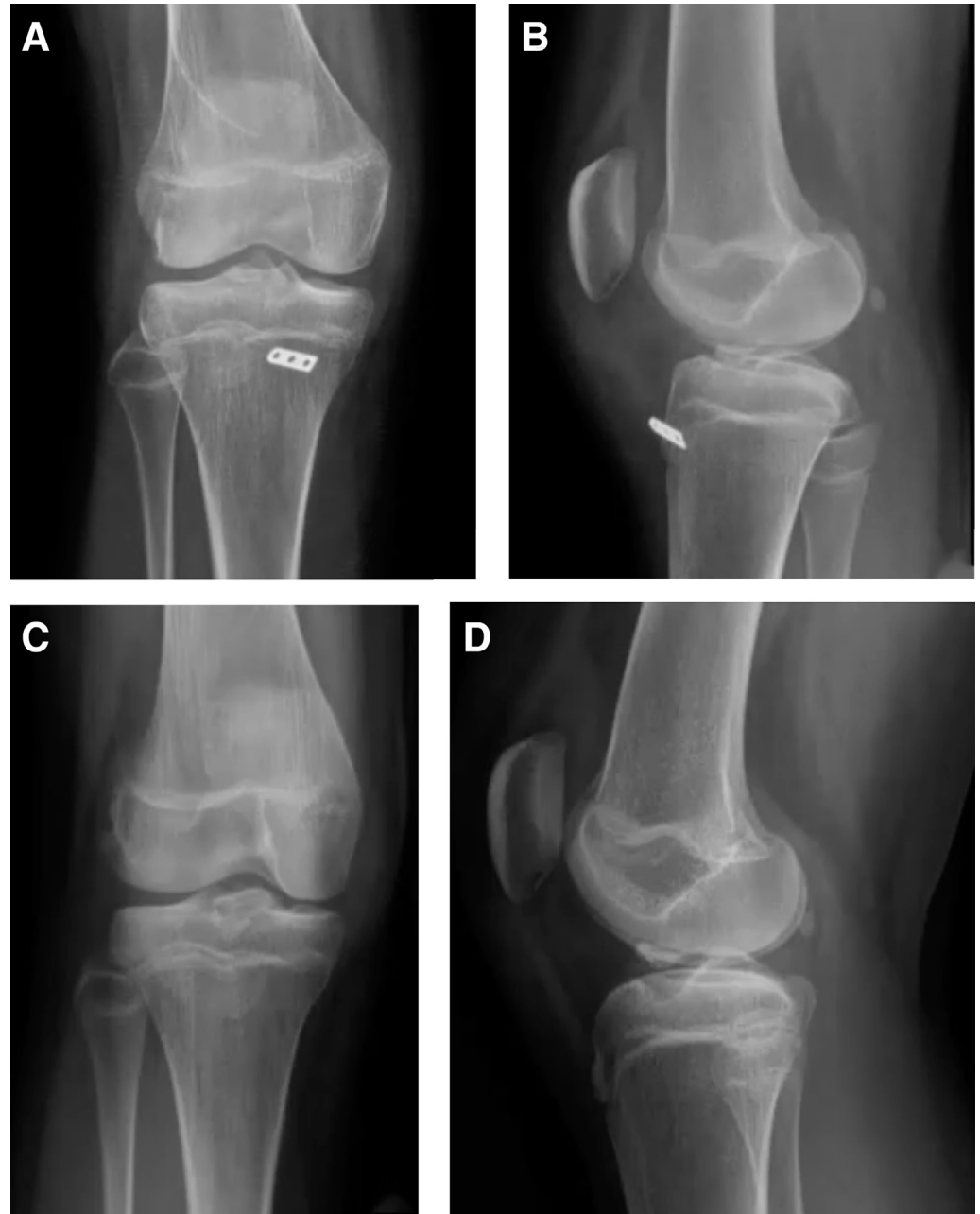

Fig 7. Postoperative radiographic imaging: (A) anteroposterior view of right knee, (B) lateral view. Initial radiographic imaging: (C) anteroposterior view of right knee, (D) lateral view.

avulsion fragments, as it carries the risk of screw impingement with the knee in extension.

The suture anchor technique provides good stability for the avulsion fragment by compressing the bony fragment to the fracture base and can achieve good clinical outcomes. There are 2 places in which the suture anchor can be applied, at the edge of the fracture site or at the central bed of the fracture. With the pullout suture technique, there are 2 important steps for proper fixation of the avulsion fragment. First, the ACL fiber must be pierced near the base of the bony fragment, a step for which most surgeons use a suture

hook or suture passer to pierce the ACL fiber. These devices are expensive and can be used only once or twice. For this modified technique, we experimented with using a modified no. 16 IV catheter needle as the suture hook and suture passer. The surgeon can adjust the needle to create the desired curve, i.e., a direct curve, a right 45° curve, or a left 45° curve, using a needle-holder.

This device is inexpensive and available in all hospitals. When using this device, surgeons should use it gently and avoid excessive manipulation because there is a risk of breaking the tip of the catheter. The second

Table 1. Pearls and Pitfalls**Pearls**

To achieve a good clinical outcome, there are some key points to be noted when using this surgical technique:

In subacute and chronic cases, the surgeon should be careful to remove all of the fibrous tissue between the avulsion fragment and the fracture base.

The surgeon should prepare the bone base between the avulsion fracture and fracture base before the fixation.

The posterior soft tissue at the posterior border of the avulsion fragment and fracture base should be left intact and used as a hinge after securing the fixation.

The surgeon should test the knee stability after the fixation.

To avoid physal injury, the surgeon should create the tibial tunnel above the physis or create more than one tunnel as indicated by the situation.

The elbow-type ACL aiming device should be used to create the tibial tunnel because the tip of the aiming device can also be used to hold the avulsion fragment.

Pitfalls

To prevent a postprocedure anterior gap remaining at the fracture site, the avulsion fragment should be fixed with the leg in the extension position

It is a risk for the tip of catheter to break if the surgeon uses it with excessive manipulation.

ACL, anterior cruciate ligament.

step is to create the tibial tunnel. The surgeon can create 1, 2, 3, or 4 tunnels.^{5,6} More than 1 tunnel can provide a good security of fixation. We created 1 anterior tunnel to pull the suture through. Normally, the pitfall of this type of pullout technique is that an anterior gap remains after fixation. The sutures that are passed through the anterior tunnel compress the avulsion fragment. The key is to preserve the posterior fibrous tissue at the posterior border of the fragment as the posterior hinge. Creating only 1 tibial tunnel is also a benefit in patients with an open physis, as the more tunnels there are, the greater the chance of physal injury.

Table 2. Advantages and Disadvantages**Advantages**

- This technique can be used in any size of avulsion ACL injury.
- A no. 16 IV catheter needle is available in all hospitals.
- It is easy to retension the suture if the tension loosens during tightening.

Disadvantage

- The soft tissue at the anteromedial aspect of tibia may be irritated by a 3-hole small plate.
-

ACL, anterior cruciate ligament; IV, intravenous.

Acknowledgments

The authors sincerely thank the patient for allowing us to disclose the information, Trisak Kingchan for assistance with drawing the illustrations, and Dave Patterson for assistance in English editing.

References

1. Kobayashi S, Harato K, Udagawa K, et al. Arthroscopic treatment of tibial eminence avulsion fracture with suture tensioning technique. *Arthrosc Tech* 2018;7:e251-e256.
2. Boutsiadis A, Karataglis D, Agathangelidis F, Ditsios K, Papadopoulos P. Arthroscopic 4-point suture fixation of anterior cruciate ligament tibial avulsion fractures. *Arthrosc Tech* 2014;3:e683-e687.
3. Sheth MR, Tapasvi SR, Patil SS. Primary repair of tibial-sided avulsion of the anterior cruciate ligament. *Arthrosc Tech* 2016;5:e901-e906.
4. Kim JI, Kwon JH, Seo DH, Soni SM, Muñoz M, Nha KW. Arthroscopic hybrid fixation of a tibial eminence fracture in children. *Arthrosc Tech* 2013;2:e117-e120.
5. Elqirem Z, Alhanbali M, Sbieh Y. Double-row fixation for avulsion of anterior cruciate ligament. *Arthrosc Tech* 2019;8:e1473-e1477.
6. Elsaid ANS, Zein AMN, ElShafie M, El Said NS, Mahmoud AZ. Arthroscopic single-tunnel pullout suture fixation for tibial eminence avulsion fracture. *Arthrosc Tech* 2018;7:e443-e452.