



Special Section on Technical Considerations for Hemorrhage Control; Edited by Dr. Chad Ball and Dr. Kelly Voght

Lung hemorrhage in trauma: Technical tricks and tips

Evan Barber, MD, Sean C. Grondin, MD, MPH, Colin Schieman, MD*

Department of Surgery, Section of Thoracic Surgery, University of Calgary, Calgary, Alberta, Canada



ARTICLE INFO

Article history:

Received 15 October 2021

Received in revised form 19 January 2022

Accepted 25 January 2022

Available online 02 February 2022

ABSTRACT

At some point as the on-call trauma surgeon, you may need to operate on a bleeding lung. This concise review addresses preoperative and intraoperative considerations for traumatic lung injuries, including how to deal with specific findings at the time of surgery.

© 2022 The Author(s). Published by Elsevier Inc. This is an open access article under the CC BY-NC-ND license (<http://creativecommons.org/licenses/by-nc-nd/4.0/>).

WORDS OF ENCOURAGEMENT

Although many lung injuries can be managed with chest tubes and resuscitation alone, at some point as the on-call trauma surgeon, you may need to operate on a bleeding lung. If this is outside your comfort zone, fortunately, controlling bleeding and repairing injuries can be successfully performed without in-depth knowledge of the pulmonary and mediastinal anatomy. With a large anterolateral thoracotomy, suction, sponge stick, clamp, and stapler, you can generally see and achieve everything you need to!

BEFORE THE INCISION

If your patient has hemorrhage requiring emergency thoracic surgery, consider ABCD as you continue to resuscitate your patient and prepare for surgery:

- 1) **Airway**—The patient may have blood in the airway. Usually, a standard endotracheal tube with 2-lung ventilation is all that is required, but remind the team to perform frequent suctioning as needed. Keeping the uninjured lung clear of debris is critical to maintain oxygenation.
- 2) **Bronchial blocking**—If suctioning is inadequate to keep blood out of the noninjured lung, ask your team to block the injured side with an endobronchial blocker or "mainstem" the endotracheal tube down the uninjured side. Double-lumen tubes are used in elective cases, but exchanging for one now generally is not worth the time and risk in the trauma setting [1].
- 3) **Call a friend**—Call for a second surgeon or the most experienced set of hands available.
- 4) **Decide on your incision(s)**—At this point, it is often unknown which organs are bleeding or even which body cavity, and you may need to

prioritize a laparotomy or thoracotomy depending on the situation. The most versatile chest incision will be an anterolateral thoracotomy, with extension if necessary across the sternum known as a "clamshell." This is relatively quick and simple to perform, allows access to more than just the lung, and has the added advantage of keeping the patient supine. On occasion, a posterolateral thoracotomy may be performed if the patient is stable and you suspect injuries more posteriorly, usually with the help of a chest surgeon.

MAKING THE INCISION

Anterolateral Thoracotomy (+/– Clamshell). Position the patient supine with arms outstretched; as a bonus, place a roll under the back on the surgical side. Prep and drape the patient from neck to knees as you would for any trauma. You are aiming for an incision at the fourth or fifth intercostal space, which roughly corresponds to below the nipple in male patients and the inframammary fold in female patients. Try to follow the angulation of the ribs and make the incision large, from sternum to the bed. With a knife, cut rapidly through the skin, fatty subcutaneous tissue, pectoralis and serratus fibers, and the intercostal muscles above the rib. You can bluntly open the pleura along the rib, but beware of rib fractures if you are using a finger. Use a rib spreader with the handle toward you and crank it open. If necessary, you can extend transversely across the sternum as a "clamshell" using a Gigli saw or Lebsche knife. Deal with the internal mammary vessels as they will bleed. A second rib spreader on the other side can also help optimize your exposure.

YOU'RE IN! NOW WHAT?

Step 1—Get Temporary Control of Bleeding and Visualize Your Injuries. A ventilated lung is difficult to work with and repair, but unfortunately, you likely would not have the luxury of 1-lung ventilation in these cases. Intermittent apnea can give you some time to see and

* Corresponding author.

E-mail address: Colin.Schieman@albertahealthservices.ca (C. Schieman).

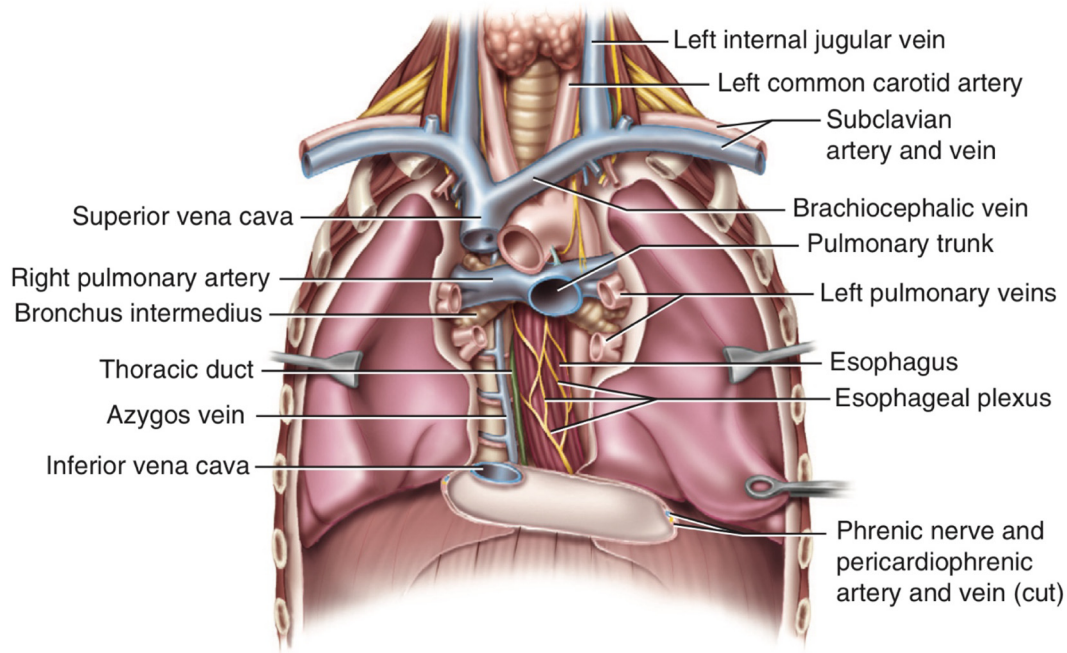


Fig 1. Anterior view of the thorax and mediastinum without the heart. This figure was published in “Thoracic Surgery Atlas” by Ferguson with illustrations by Rhead, p. 139, Copyright W.B. Saunders, Inc, an affiliate of Elsevier (2007) [3].

work. As you would in the abdomen, pack the chest upon entry and assess your injuries. For temporary control of bleeding, careful directed pressure with sponge sticks to the hilum or lung is very effective. Finger occlusion of the hilum is another option for major bleeding [2]. Occasionally, the entire chest cavity will need to be packed to control bleeding; once controlled, the packs can be carefully removed to identify the source.

Step 2—Optimize Exposure, Make A Plan, Arm Yourself. Further extend your incision if necessary (including across the sternum if needed), crank open your retractors, and get your clamps/staplers/sutures ready. Make sure anesthesia is caught up and aware of your plan.

Step 3—Execute Your Plan! Depending on the injuries you have identified, you may decide to proceed with repairs, resections, or packing. In general, large resections are ideally avoided, but your hand may be forced, particularly when in damage control mode. Without lung isolation, you may need to ask for intermittent apnea to help you work; another trick is to have your assistant squeeze the lung with their hands or a large clamp. Here is some guidance on how to proceed, depending on the scenario you find yourself in.

Getting Proximal and Distal Control. First, a little anatomy review (Figs 1 and 2) [3]. On either side, there is a superior and inferior pulmonary vein. The inferior pulmonary ligament leads up to the inferior

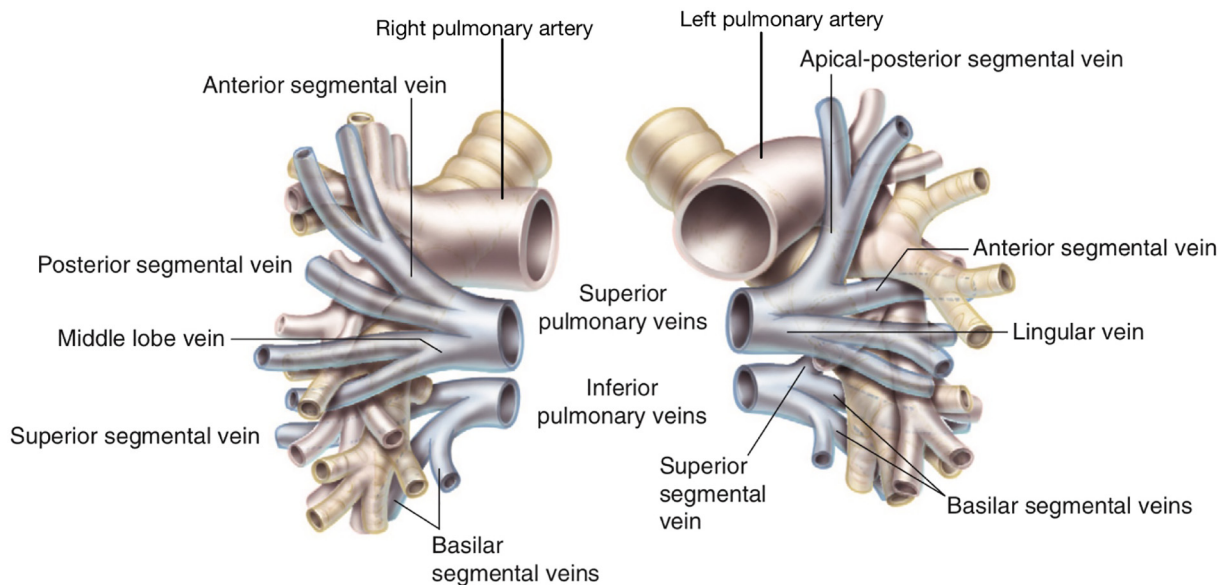


Fig 2. Anterior view demonstrating the relationship of the pulmonary vessels and bronchi. This figure was published in “Thoracic Surgery Atlas” by Ferguson with illustrations by Rhead, p. 55, Copyright W.B. Saunders, Inc, an affiliate of Elsevier (2007) [3]; modified to label the pulmonary arteries.

pulmonary vein, and the main pulmonary artery sits behind and slightly superior to the superior pulmonary vein [4]. The veins can be safely handled with forceps and retracted, whereas the artery is soft and prone to tearing. The left pulmonary artery has a shorter distance before its first branch compared to the right, which makes proximal control more difficult on the left [4]; an option is to quickly incise the pericardium overlying the hilum to allow intrapericardial control.

Now, let us put this into action. If you are lucky, a small peripheral injury will not require formal control of the hilar vessels; otherwise, you have a couple of options for achieving control depending on your comfort and experience. Regardless of your approach, now is a good time to take down the inferior pulmonary ligament up to the inferior vein. From there, if you can quickly and safely dissect out the hilar vessels and your injury is away from the hilum, have your assistant place pressure on the bleeding while you dissect them out. An umbilical tape with a Rummel tourniquet works well on the veins and main pulmonary arteries, but right angle vascular clamps are another option. Finally, if your injury is proximal on the hilar vessels, not allowing you to dissect them out, or if you are otherwise uncomfortable with this dissection, draw up the lung and place a large clamp across the entire hilum.

Focal Peripheral Injuries. An injury to the periphery of the lung is the best-case scenario and is treated with a quick wedge resection using a stapler.

Missile Wound to the Lung. If the lung has a tubular injury such as from a bullet, pulmonary tractotomy may be done to exteriorize the injury [5]. This is achieved by firing a stapler with one jaw down the hole; the area of injury is now exposed and can be dealt with using sutures or packing.

Large Raw Surface. If you have a large raw injured surface or contusion, packing for 24 to 48 hours is a good option [6]. A lung that is contused will not tolerate mechanical stapling very well, and resection in this scenario probably will not be necessary.

(The Dreaded) Pulmonary Artery Bleed and Central Vascular Injuries. The pulmonary artery is rarely amenable to a simple primary suture repair. It is very thin-walled, and attempts at repair without good proximal and distal control will likely tear the vessel further. Achieving proximal and distal control for the purpose of vessel repair is easier said than done in the trauma setting (especially for those less familiar with the anatomy), and usually, these cases will be in damage control mode. Therefore, the safest option for major injuries to the pulmonary vessels will usually be resection despite the mortality associated with this [7]. If the injury is within the lung, a deep wedge resection using thick tissue staplers may be possible below the injury. Otherwise, if pneumonectomy is required to control the bleeding, the hilum can be divided en masse with a stapler. If a thoracic surgeon is available and the patient's condition allows, a vessel repair or anatomic resection may be possible, but this usually not the case.

Major Bleeding and Inability to Get Proximal Control. If a pulmonary vessel injury is so proximal that you are unable to get adequate control for repair or resection, this is usually an unrecoverable situation and the patient will have already exsanguinated. In the rare event you are faced

with this, your only hope is maintaining pressure while arranging for cardiopulmonary bypass if available [8]. This may allow the cardiac surgeon to repair the injured vessel at its origin. Keep in mind that bypass requires anticoagulation which may be contraindicated depending on your patient's injuries.

TAKE-HOME POINTS

1. Remember that your patient may be bleeding into their airway.
2. Lung isolation is needed if the uninjured lung is drowning in blood despite suctioning; bronchial blockers or "mainstemming" the ET tube are safer options than a double-lumen tube.
3. The anterolateral thoracotomy is the go-to chest incision for trauma.
4. Packing and pressure are your best initial maneuvers for temporary control of bleeding.
5. Peripheral lung injuries are best treated with stapled wedge resection.
6. Large raw surfaces can be packed, ideally avoiding resection.
7. Major pulmonary vascular injuries require rapid proximal control. Large stapled resection up to and including pneumonectomy may be needed despite the associated mortality.

Disclosures

Author Contribution. All authors contributed to the material and review of this manuscript.

Conflict of Interest

The authors have no relevant conflicts of interest to declare.

Funding Source

Funding was not received for this manuscript.

Ethics Approval

Ethics approval was not required.

References

- [1] Hirshberg A, Mattox KL. Top knife: the art & craft of trauma surgery. Castle Hill Barns, Shrewsbury, UK: tfm Pub; 2005; 163–4.
- [2] Mattox KL, Moore EE, Feliciano DV. Trauma. 7th ed.. New York: McGraw-Hill Medical; 2013; 471–2.
- [3] Ferguson MK. Thoracic surgery atlas. Philadelphia: PA: Saunders/Elsevier; 2007; 55–139.
- [4] Gray H, Clemente CD. Anatomy of the human body. 30th American ed.. Philadelphia: Lea & Febiger; 1985; 658–794.
- [5] Wall MJ, Villavicencio RT, Miller CC, Aucar JA, Granchi TA, Liscum KR, et al. Pulmonary tractotomy as an abbreviated thoracotomy technique. J Trauma. 1998;45(6): 1015–23.
- [6] Manzano-Nunez R, Chica J, Gómez A, Naranjo MP, Chaves H, Muñoz LE, et al. The tenets of intrathoracic packing during damage control thoracic surgery for trauma patients: a systematic review. Eur J Trauma Emerg Surg. 2021;47(2):423–34.
- [7] Phillips B, Turco L, Mirzaie M, Fernandez C. Trauma pneumonectomy: a narrative review. Int J Surg. 2017;46:71–4.
- [8] Dauphine C, McKay C, De Virgilio C, Omari B. Selective use of cardiopulmonary bypass in trauma patients. Am Surg. 2005;71(1):46–50.