



Histopathological Changes in Placenta of Severe Acute Respiratory Syndrome Coronavirus 2 (SARS-Cov-2) Infection and Maternal and Perinatal Outcome in COVID-19

Ruchika Garg¹ · Rachana Agarwal¹ · Divya Yadav¹ · Saroj Singh¹ · Harendra Kumar² · Ritu Bhardwaj¹

Received: 17 October 2021 / Accepted: 27 May 2022
© Federation of Obstetric & Gynecological Societies of India 2022

Abstract

Background Whether vertical transmission or placental pathology occurs after maternal infection during pregnancy remains unknown. There is a clear need for studies on the impact of COVID-19 on pregnancy outcome. A systemic inflammatory or hypercoagulable state may be the contributing factor for placental pathology.

Methods The pregnant women with COVID-19 who delivered between May 2020 and May 2021 were followed and data were collected about pregnancy course and placentas were examined for macro- and microscopical changes and were compared to controls with non-infected women.

Results Placenta of COVID-19-infected females had increased prevalence of decidual arteriopathy and placental injury reflecting hypoxia and uteroplacental insufficiency within the intervillous space. Features of maternal vascular malperfusion such as increased syncytial knots were present in 100% cases. Fibrinoid necrosis was seen in 100% cases and increased focal perivillous fibrin depositions were presented in 37.7% cases. About one fourth infected placentas had evidence of villitis. Even after matching for comorbidities like preeclampsia, these changes were present.

Conclusion The most common pathological findings of the placenta of COVID-19 infections are signs of maternal and fetal malperfusion. Future studies should target infections in different stage of gestation, including first and second trimesters.

Keywords SARS-CoV 2 (severe acute respiratory syndrome coronavirus 2) · COVID-19 (coronavirus disease 2019) · Histopathological changes · Placental changes · Pregnancy · Placenta · RT-PCR (reverse transcriptase polymerase chain reaction) · MVM (maternal vascular malperfusion)

Introduction

Placenta is a useful interface between mother and the fetus. Whether vertical transmission or placental pathology occurs after maternal COVID-19 infection during pregnancy remains unknown. COVID-19 can increase inflammatory and oxidative stress in the placenta. SARS-CoV-2 gains access to human cells via angiotensin-converting enzyme 2 (ACE-2). ACE-2 receptors are present abundantly on the

Dr. Ruchika Garg (MS, FICOG) is an Professor OBG; Dr. Rachana Agarwal (MS, FICOG) is an Professor OBG; Dr. Divya Yadav (MS, FICOG) is an Associate Professor OBG; Prof. Dr. Saroj Singh (M.S, FAMAS, FICOG.) is a Head of the Department; Dr. Harendra Kumar (MD) is an Professor; Ritu Bhardwaj is a Junior Resident OBG.

✉ Rachana Agarwal
rachanaagrawal15@gmail.com

Ruchika Garg
ruchikagargagra@gmail.com

Divya Yadav
drdivyayadavsharma@gmail.com

Saroj Singh
drsarojsingh@hotmail.com

Harendra Kumar
dr_haren@yahoo.co.in

¹ Department of Obstetrics and Gynaecology, S N Medical College, Agra, U.P., India

² Department of Pathology, S N Medical College, Agra, U.P., India

placental syncytiotrophoblasts. This might contribute to vertical transplacental transmission to the fetus [1]. Till date, very few neonates have tested positive for SARS-CoV-2. Theoretically, placenta can be involved directly by SARS-CoV2 infection. Virus can indirectly lead to inflammation in placenta or hypoxia in placenta. There is a clear need for studies on the impact of COVID-19 on pregnancy outcome. A systemic inflammatory or hypercoagulable state may be the contributing factor for placental pathology [2].

To the best of our knowledge, till date, this is the first study from India, that studied placental histopathology in severe acute respiratory syndrome coronavirus 2 (SARS-CoV-2) pregnant women matched with controls. Globally also literature is sparse on histopathological changes in placentas of COVID-19-infected women.

Aim

To study histopathologic changes in the placentas of women with coronavirus disease 2019 (COVID-19) during pregnancy.

Secondary Endpoints

1. To compare changes in placenta of SARS-Cov-2 positive pregnant women with placenta of pregnant women with no infection.
2. To determine correlation of placental changes with maternal and perinatal outcome.

Material and Methods

Pregnant women with COVID-19 who delivered between May 2020 and May 2021 were followed, and data were collected about pregnancy course, maternal and fetal outcomes. Placentas were examined for macro- and microscopical morphology in both cases and controls and were compared to controls who were not infected with COVID-19, matched by age, body mass and comorbidities like preeclampsia because they can act as confounders.

Inclusion Criteria

Group A

Pregnant women who are RT-PCR positive for SARS-CoV-2 and delivered at our institution between May 2020 and May 2021.

Group B

Pregnant women who had no COVID infection and delivered between May 2020 and May 2021.

Exclusion Criteria

1. Pregnant women with unknown status of RT-PCR for SARS-Cov-2.
2. Pregnant women with equivocal result of RT-PCR for SARS-CoV-2.
3. Pregnant women with infection of syphilis and chorioamnionitis.
4. Pregnant women with known case of any other viral infection like dengue, chickenpox.
5. Pregnant women in first and second trimester.

All the placentas were kept apart for 48 h to reduce infectivity if any. Histopathological number was given to each specimen. Placentas were looked for any missing lobe or cotyledons and stored and fixation in 10% buffered formalin was done. The specimen was carefully grossed as the size, shape, weight thickness at center, number of cotyledons and site of insertion of umbilical cord. Sectioning and representative sampling of any lesion present was done. Sections underwent routine processing, embedding, sectioning and staining with H&E. Histologic examination was performed by pathologists who were aware of the SARS-Cov-2 status. After removing both the maternal decidua and all the fetal membranes, the umbilical cord was trimmed from the placental disk. Then, histologic multiple samples were collected as follows: Samples were trimmed from the membranes, umbilical cord, umbilical cord insertion and from the placental cotyledons. Neonates were tested for SARS-CoV-2 using PCR of nasopharyngeal swabs after 48 h of birth according to our hospital protocol.

The study was approved by Ethics Committee, and informed consent was obtained from all the patients.

Statistics

Chi-square test was applied to compare among groups. Continuous variables were studied as mean + standard deviation. Statistical analyses were performed using SPSS software.

Results

- Both groups were comparable with respect to parity, and pregnancy complications like pregnancy-induced hypertension, gestational diabetes and hypothyroidism. All the women included in study were in third trimester. There were no statistically significant differences between his-

topathological changes (maternal vascular malperfusion) in placentas of patients with preeclampsia (as all had late onset preeclampsia only) and gestational diabetes in COVID-19 positive patients and those who had no COVID-19 infection. Fetal distress was significant in COVID-19-infected women versus non-infected women.

All the patients we studied were term pregnancies. They had history of acquiring COVID-19 only few days back. As soon as they were diagnosed with COVID-19, they were admitted. Patients who had no labor signs were managed conservatively. So we could not comment on placental changes at other gestational ages. Majority of patients had mild infection (Table 1). Only 8/45 had moderate infection defined as oxygen saturation less than 94 percent. Majority of patients were delivered by cesarean section done mostly for previous cesarean section and other obstetric indications. Preterm labor was reported in 7/45, and difference was not significant in cases and controls. Complications like postpartum hemorrhage were not significantly different between the groups. Fetal distress and meconium-stained liquor were reported in 7/45 and were more in COVID cases compared to non-infected controls (2/45). Mean 5 min Apgar score of babies was 8/10. There was no neonatal death, and all

neonates were timely discharged (Table 1). Our neonatal outcome was good except for fetal distress and asphyxia in newborns which were managed by NICU admission. One Intrauterine fetal death (IUID) was because of obstructed labor in first wave, we have not included this case as till then we had not started the study. In second wave, IUIDs were there but despite clinical suspicion in many patients SARS-CoV-2 RT-PCR and rapid antigen test turned out to be negative, they could not be added in the study sample. All neonates with coronavirus disease 2019 infection in mother tested negative for severe acute respiratory syndrome coronavirus-2 by RT-PCR. Vertical transmission from mother to fetus was not seen in our study. There were no maternal deaths in both cases and controls.

Features of maternal vascular malperfusion (MVM) such as increased syncytial knots and fibrinoid necrosis were seen in 100% cases. Increased focal perivillous fibrin depositions were presented in 37.7% cases. About one fourth infected placentas had evidence of villitis. Evidence of fetal vascular malperfusion was identified; with placentas from COVID-19 positive women being significantly more likely to show villous agglutination, fetal thrombovasculitis, microcalcifications and chorioamnionitis. Figures 1 and 2 are compared to

Table 1 Clinical characteristics of cases and controls

Features	Cases <i>N</i> =45	Controls <i>N</i> =45	<i>P</i> value
Mean age in years	25.4	24.6	0.74
Mean BMI kg/m ²	22	21.8	0.82
Primigravida	16	23	0.72
Multigravida	29	22	0.75
Gestational age at delivery			
> 37 weeks	35	37	0.74
34–37 weeks	10	8	0.71
Preexisting medical conditions			
Gestational diabetes	1	1	0.72
Thyroid	2	2	0.76
Pregnancy complications			
Preeclampsia	6	7	0.82
IUGR	3	5	0.77
Oligohydramnios	5	5	0.74
Preterm labor	7	6	0.73
Postpartum hemorrhage	6	1	0.06
Mode of delivery			
Vaginal	10 (22.2%)	29 (64.4%)	<0.05
Cesarean	35 (77%)	16 (35.5%)	<0.05
Neonatal outcome			
Fetal distress and meconium stained liquor	7	2	<0.05
Apgar score	8/10	9/10	0.06
NICU admission	5	3	0.06
Neonatal COVID-19 status	Negative in 100%	–	

Fig. 1 Comparison of placental changes in cases and controls

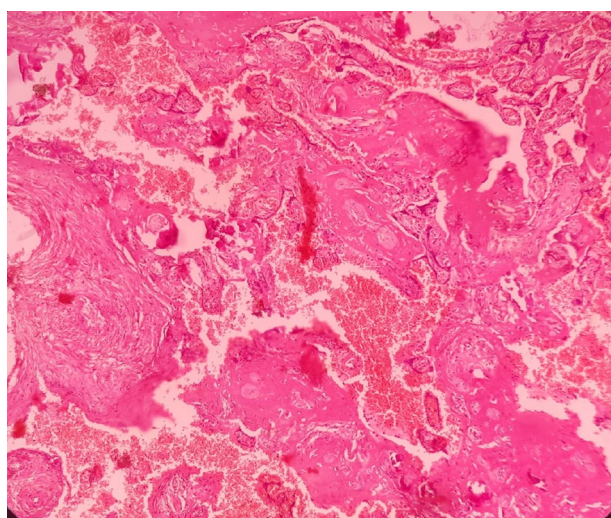
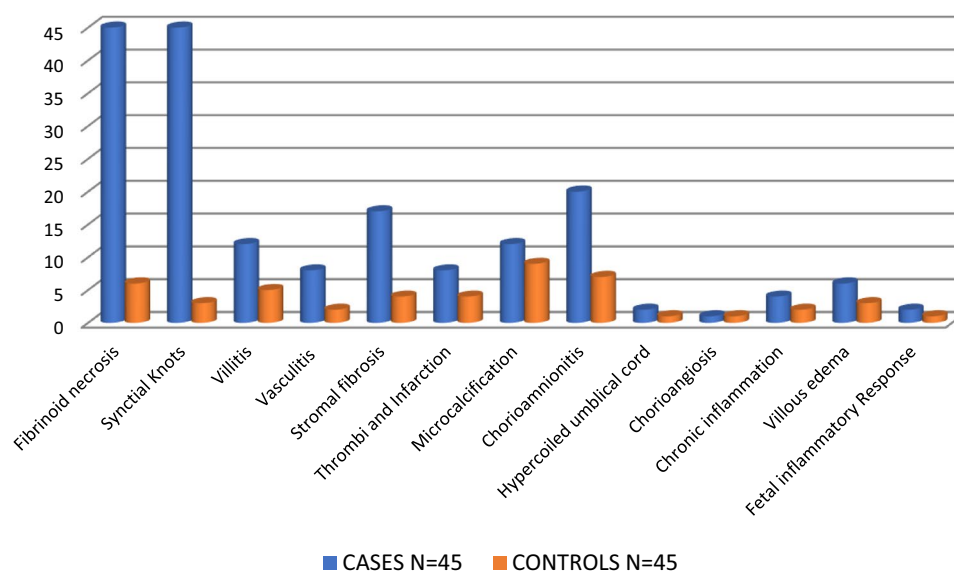


Fig. 2 Placental tissue showing focus of fibrinoid necrosis, stromal fibrosis, focus of microcalcification & hemorrhage (100X, H&E)

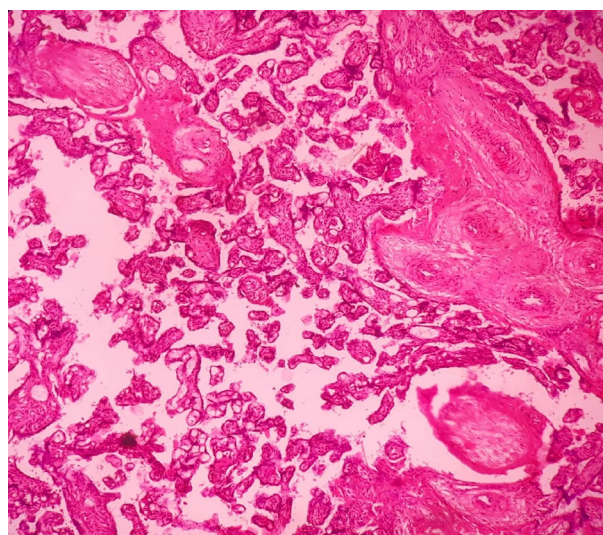


Fig. 3 Placental tissue showing hypovascularity & stromal fibrosis (100X, H&E)

controls. Maternal vascular malperfusion was significantly increased in cases compared to matched controls.

Evidence of maternal and fetal vascular malperfusion and placental inflammation were increased in SARS-CoV2-infected placentas in our study. In univariable analyses, SARS-CoV-2-infected were more likely to have evidence of fetal vascular malperfusion and fibrin deposition (Figs. 1, 2, 3) (37.7% vs 8.8% [4/45] $P < 0.05$) and villitis of unknown etiology (26.6% vs 11% [5/45] $P < 0.05$) (Table 2).

These findings persisted in a subgroup analysis of cases of coronavirus disease 2019 cases compared with controls who were negative for coronavirus disease 2019. In a multivariable model adjusting for maternal age, mode of delivery, preeclampsia, fetal growth restriction, and oligohydramnios,

the frequency of fetal vascular malperfusion abnormalities remained significantly higher in infected group (odds ratio, 10.6). Chorioangiomas is found in maternal hypoxia. Chorioangiomas, acute and chronic inflammation are not increased relative to controls in our study. Villous edema and congestion were significantly higher in infected patients versus controls.

Table 2 Placental pathology in cases and controls

Placental pathology	Cases N=45		Controls N=45		P value
Fibrinoid necrosis	45	100%	6	13.3%	<0.05
Syncytial knots	45	100%	3	6.6%	<0.05
Villitis	12	26.6%	5	11.1%	<0.05
Vasculitis	8	17.7%	2	4.4%	<0.05
Stromal fibrosis	17	37.7%	4	8.8%	<0.05
Thrombi and infarction	8	17.7%	4	11.11%	<0.05
Microcalcification	12	26.6%	9	2%	0.06
Chorioamnionitis	20	44.4%	7	15.6%	0.06
Hypercoiled umbilical cord	2		1		0.06
Chorioangiomas	1		1		0.06
Chronic inflammation	4		2		0.06
Villous edema	6		3		<0.05
Fetal inflammatory response	2		1		0.06

Discussion

It is important to differentiate the effect of COVID-19 from causes of maternal and fetal malperfusion, like pre-existing pregnancy induced hypertension and disseminated intravascular coagulation during pregnancy [2–5].

A preeclampsia-like syndrome has been observed in patients with severe COVID-19 infection, but this preeclamptic state recovered without delivery, once the respiratory condition was improved [6].

The angiotensin-converting enzyme 2 (ACE2) receptor that causes vasoconstriction resulting from renin-angiotensin system dysfunction mediates the SARS-CoV-2 action [7]. Extra copies of ACE2 in women would continue to carry on protection [6].

Presence of SARS-CoV-2 spike protein's mRNA in placental syncytiotrophoblasts has been reported in placentas of COVID-19 patients. Acute and chronic inflammatory changes in the placenta can be a result of maternal and fetal inflammatory response to coronavirus infection.

Histiocytic intervillitis, villous edema and retroplacental hematoma have been found in syncytiotrophoblasts of SARS-CoV-2 placenta. In a study published in American Journal of Clinical Pathology by Shanes et al. [2], it has been reported that patients with SARS-CoV-2 infection have placental decidual arteriopathy and poor maternal vascular perfusion. Fibrinoid necrosis and mural hypertrophy of membrane arterioles suggestive of placental hypoxia have also been found reflecting a systemic inflammation and hypercoagulability similar to changes in preeclampsia and placental insufficiency [8, 9]. Perivillous fibrin deposition was also noted like our study. Placental calcification may be the result of exposures to infection, hypoxia or systemic stress [10].

Fibrinoid necrosis and infarcted villi can cause uteroplacental insufficiency and fetal demise as found in pregnancies with preeclampsia and diabetes [11].

Stromal fibrosis of terminal villi is a consequence of regression after intrauterine fetal death or may be due to impaired placental circulation [12].

Ischemia and hypoxia precipitate fibrosis in villous stroma [13].

Hypoxia induced by SARS-CoV-2 infection may lead to MVM. Results of 20 studies who applied Amsterdam Consensus criteria to categorise the histopathology reported evidence of both fetal vascular malperfusion (FVM) (35.3% of cases) and maternal vascular malperfusion (MVM) (46% cases). Villitis 8.7% cases and intervillitis 6% suggestive of placental inflammation were reported. In 6% cases, evidence of chorioamnionitis was also seen.

Similar inflammatory findings were reported by Richtmann R et al. 2020 [14] in study of five pregnant women.

In a case reported by Vivanti AJ et al. with no evidence of pregnancy complications but still neonate was intubated and tested positive in nasopharyngeal swab, placenta had acute and chronic intervillitis (CD68 macrophages), diffuse perivillous fibrin deposition and infarction. Smithgall et al. reported MVM in 38/51 cases, compared to 16/25 healthy controls; though the results were not significant.

Features of MVM were reported in 46% (69/150) COVID-19 positive cases in third trimester. Baergen and Heller [20] reported that 3/21 placentas (14%) had features of MVM [17]. Both villous agglutination and subchorionic thrombi were significantly increased in the placentas of SARS-CoV-2 positive mothers. Prabhu et al. found one third placentas had MVM in both cases and controls (not significant) and (14/29) had a significant increase in FVM versus 12/106 controls.

FVM was reported in 53 cases, one third of placentas by six studies [15–17]. Hsu et al. reported the presence of the SARS-CoV-2 antigen throughout the placenta, in endothelial cells, but not in the syncytium. SARS-CoV-2 has been identified in the syncytiotrophoblast in two placentas from stillborn twins. About forty percent placentas had FVM in the study by Baergen and Heller. Smithgall et al. found 12/51 placentas had evidence of FVM versus 2/25 controls (non-significant) [19].

By in situ hybridisation, Patanè et al. reported strong staining of the SARS-CoV-2 spike protein mRNA in the syncytiotrophoblast [17], whereas Mulvey et al. [18–20] reported contradictory finding that the level of staining was not different in controls.

FVM is associated with reduced placental weight, stillbirth and fetal growth restriction (FGR) FVM might be the reason for 7/45 cases of fetal distress.

Features of FVM were found in 80% (12/15 cases) by Shanes et al. and in multiple other studies [21–24]

Similar to results of our study, Mulvey et al. reported 100% (5/5) of the placentas examined had FVM, which was absent in controls. Syncytial nodules and syncytial nuclear aggregates were increased and were noted in two placentas [25].

SARS-Cov-2 protein was seen in the cytoplasm of trophoblast by Vivanti et al. [26]. Inflammatory changes were reported in multiple studies. Presence of CD68 + macrophages in the villi and intervillous space suggesting chronic intervillitis was reported in term delivery [27–29].

In first wave, our 85% patients were asymptomatic and rest 15% had mild infection only (fever, cough, etc.) [30]. In second wave, the severity of infection was more as many patients had moderate infection requiring oxygen and few had severe pneumonia and were admitted in ICU for BiPAP. COVID-19 did not lead to more severe infection in pregnant women compared to nonpregnant in the first wave. Pregnant women are at higher risk of acquiring COVID-19 infection but it did not lead to adverse pregnancy outcomes like oligohydramnios, postpartum hemorrhage, etc.

Limitations of the Study

Comparatively, small sample size is the only limitation of our study. Our study is unique in the sense that, we have compared histopathological changes in COVID-19 placentas with normal pregnant women. The duration of disease and infection to delivery interval were very short in our study. Had we were able to follow early third trimester pregnancies who acquired COVID till term, we could have commented on changes from infection to delivery interval but this follow-up was not possible due to poor compliance. Being a government institute, we performed IL-6 and D Dimer in patients with severe diseases requiring Intensive Care Unit

(ICU) but not in study patients as they were all clinically stable.

Conclusion

Relative to controls, COVID-19 placentas had increased prevalence of decidual arteriopathy, maternal and fetal malperfusion and placental hypoxia and uteroplacental insufficiency in the intervillous space even after matching for comorbidities like preeclampsia. An inflammatory or hypercoagulable state induced by COVID-19 may be responsible. The most common pathological findings of the placenta of COVID-19 infections are signs of maternal and fetal malperfusion but these changes did not lead to adverse maternal outcomes in near delivery patients but fetal malperfusion led to fetal distress in COVID-19 patients. Future studies should target infections in different stage of gestation, including in first and second trimesters.

Funding This article did not receive any funding.

Declarations

Conflict of interest All authors declare that they have no conflict of interest.

Ethical approval Ethical approval was taken from Institutional Ethical Committee. IEC 2021/23 Dated 4 /1/2021.

Informed consent Informed consent was taken from all participants who are included in the study.

References

1. Wong YP, Khong TY, Tan GC. The effects of COVID-19 on placenta and pregnancy: what do we know so far? *Diagnostics (Basel)*. 2021;11(1):94. <https://doi.org/10.3390/diagnostics11010094>.
2. Shanes ED, Mithal LB, Oteros S, et al. Placental pathology in COVID-19. *Am J Clin Pathol*. 2020;154(1):23–32. <https://doi.org/10.1093/ajcp/aqaa089>.
3. Khalid E, Ali ME, Ali KZ. Full-term birth weight and placental morphology at high and low altitude. *Int J Gynaecol Obstet*. 1997;57:259–65.
4. Narasimha A, Vasudeva DS. Spectrum of changes in placenta in toxemia of pregnancy. *Indian J Pathol Microbiol*. 2011;54:15–20.
5. Tomas SZ, Prusac IK, Roje D, et al. Trophoblast apoptosis in placentas from pregnancies complicated by preeclampsia. *Gynecol Obstet Invest*. 2011;71:250–5.
6. Mendoza M, Garcia-Ruiz I, Maiz N, et al. Pre-eclampsia-like syndrome induced by severe COVID-19: a prospective observational study. *BJOG Int J Obstet Gynaecol*. 2020. <https://doi.org/10.1111/1471-0528.16339>.

7. Garg R, Agrawal P. COVID-19 outcomes in postmenopausal and perimenopausal females: is estrogen hormone attributing to gender differences? *J Midlife Health*. 2020;11:250–6.
8. Levy A, Yagil Y, Bursztyn M. ACE2 expression and activity are enhanced during pregnancy. *Am J Physiol Regul Integr Comp Physiol*. 2008;295:R1953–61.
9. Wallingford MC, Benson C, Chavkin NW, et al. Placental vascular calcification and cardiovascular health: it is time to determine how much of maternal and offspring health is written in stone. *Front Physiol*. 2018;9:1044. <https://doi.org/10.3389/fphys.2018.01044>.
10. Shams F, Rafique M, Samoo NA, et al. Fibrinoid necrosis and hyalinization observed in normal, diabetic and hypertensive placentae. *J Coll Physicians Surg Pak*. 2012;22(12):769–72.
11. Emmrich P. Pathology of the placenta. IX. Intrauterine fetal death. Regression. Edema and fibrosis of the villous stroma. *Zentralbl Pathol*. 1992;138(1):1–8.
12. Ohmaru-Nakanishi T, Asanoma K, Fujikawa M, et al. Fibrosis in preeclamptic placentas is associated with stromal fibroblasts activated by the transforming growth factor- β 1 signaling pathway. *Am J Pathol*. 2018;188:683–95.
13. Ahmed I, Eltaweel N, Antoun L, et al. Severe pre-eclampsia complicated by acute fatty liver disease of pregnancy, HELLP syndrome and acute kidney injury following SARS-CoV-2 infection. *BMJ Case Rep*. 2020;13:e237521.
14. Richtmann R, Torloni MR, Otani ARO, et al. Fetal deaths in pregnancies with SARS-CoV-2 infection in Brazil: a case series. *Case Rep Women's Health*. 2020. <https://doi.org/10.1016/j.crwh.2020.e00243>.
15. Hosier H, Farhadian S, Morotti R, et al. SARS-CoV-2 infection of the placenta. *MedRxiv*. 2020:2020. <https://doi.org/10.1101/2020.04.30.20083907>.
16. Patanè L, Morotti D, Giunta MR, et al. Vertical transmission of COVID-19: SARS-CoV-2 RNA on the fetal side of the placenta in pregnancies with COVID-19 positive mothers and neonates at birth. *Am J Obstet Gynecol MFM*. 2020. <https://doi.org/10.1016/j.ajogmf.2020.100145>.
17. Prabhu M, Cagino K, Matthews KC, et al. Pregnancy and postpartum outcomes in a universally tested population for SARS-CoV-2 in New York City: a prospective cohort study. *BJOG Int J Obstet Gynaecol*. 2020. <https://doi.org/10.1111/1471-0528.16403>.
18. Mulvey JJ, Magro CM, Ma LX, et al. Analysis of complement deposition and viral RNA in placentas of COVID-19 patients. *Ann Diagn Pathol*. 2020;46:151530. <https://doi.org/10.1016/j.anndiagpath.2020.151530>.
19. Smithgall MC, Liu-Jarin X, Hamele-Bena D, et al. Third trimester placentas of SARS-CoV-2-positive women: histomorphology, including viral immunohistochemistry and in situ hybridization. *Histopathology*. 2020. <https://doi.org/10.1111/his.14215>.
20. Baergen RN, Heller DS. Placental pathology in covid-19 positive mothers: preliminary findings. *Pediatr Dev Pathol*. 2020;23:177–80. <https://doi.org/10.1177/1093526620925569>.
21. Kuhrt K, Mc MJ, Nanda S, et al. Placental abruption in a twin pregnancy at 32 weeks' gestation complicated by coronavirus disease 2019 without vertical transmission to the babies. *Am J Obstet Gynecol MFM*. 2020. <https://doi.org/10.1016/j.ajogmf.2020.100135>.
22. Pulinx B, Kieffer D, Michiels I, et al. Vertical transmission of SARS-CoV-2 infection and preterm birth. *Eur J Clin Microbiol Infect Dis*. 2020. <https://doi.org/10.1007/s10096-020-03964->.
23. Baud D, Greub G, Favre G, et al. Second-trimester miscarriage in a pregnant woman with SARS-CoV-2 infection. *J Am Med Assoc*. 2020;323:2198–200. <https://doi.org/10.1001/jama.2020.7233>.
24. Ferraiolo A, Barra F, Kratochwila C, et al. Report of positive placental swabs for SARS-CoV-2 in an asymptomatic pregnant woman with COVID-19. *Medicina (B Aires)*. 2020;56:306. <https://doi.org/10.3390/medicina56060306>.
25. Hsu AL, Guan M, Johannesen E, et al. Placental SARS-CoV-2 in a pregnant woman with mild COVID-19 disease. *J Med Virol*. 2021;93(2):1038–44. <https://doi.org/10.1002/jmv.26386>.
26. Vivanti AJ, Vauloup-Fellous C, Prevot S, et al. Transplacental transmission of SARS-CoV-2 infection. *Nat Commun*. 2020;11:3572.
27. Algarroba GN, Rekawek P, Vahanian SA, et al. Visualization of SARS-CoV-2 virus invading the human placenta using electron microscopy. *Am J Obstet Gynecol*. 2020. <https://doi.org/10.1016/j.ajog.2020.05.023>.
28. Chen S, Huang B, Luo DJ, et al. Pregnancy with new coronavirus infection: clinical characteristics and placental pathological analysis of three cases. *Zhonghua Bing li xue za zhi Chin J Pathol*. 2020;49(5):418–23. <https://doi.org/10.3760/cma.j.cn112151-20200225-00138>.
29. Ernst LM. Maternal vascular malperfusion of the placental bed. *APMIS*. 2018;126:551–60. <https://doi.org/10.1111/apm.12833>.
30. Agarwal N, Garg R, Singh S, et al. Coronavirus disease 2019 in pregnancy: maternal and perinatal outcome. *J Educ Health Promot*. 2021;10(1):194. https://doi.org/10.4103/jehp.jehp_954_20.

Publisher's Note Springer Nature remains neutral with regard to jurisdictional claims in published maps and institutional affiliations.

Springer Nature or its licensor holds exclusive rights to this article under a publishing agreement with the author(s) or other rightsholder(s); author self-archiving of the accepted manuscript version of this article is solely governed by the terms of such publishing agreement and applicable law.