

Clinical Study

Anogenital Lesions: Kaposi's Sarcoma and Its Mimicks

Louis-Jacques van Bogaert

National Health Laboratory Service, Polokwane/Mankweng Hospital Complex and University of Limpopo, Groblersdal 0470, South Africa

Correspondence should be addressed to Louis-Jacques van Bogaert, louis.vanbogaert@nhls.ac.za

Received 31 July 2012; Accepted 13 September 2012

Academic Editors: S. Ausayakhun and G. D'ettore

Copyright © 2012 Louis-Jacques van Bogaert. This is an open access article distributed under the Creative Commons Attribution License, which permits unrestricted use, distribution, and reproduction in any medium, provided the original work is properly cited.

Kaposi's sarcoma (KS) is a low-grade vascular neoplasm associated with human herpes virus-8 (HHV-8) infection, and, in the epidemic form, with the human immunodeficiency virus (HIV). Although HHV-8 is present in all body fluids and is sexually transmitted, there are surprisingly few reports of anogenital KS. Clinically, especially in HIV/KS endemic areas, dark stained skin patches or nodules are prone to misdiagnosis, especially in dark-skinned individuals. Therefore, a biopsy is recommended. The histologic appearance spans a broad spectrum of KS and non-KS lesions; therefore, the final diagnosis should be confirmed by HHV-8 immunohistochemistry. We report a series of 36 anogenital biopsies from a group of 16 documented HIV-positive patients; in 20 the HIV serostatus was unknown. There were ten KS (five in HIV-positive patients), and 26 non-KS (11 in HIV-positive subjects) lesions. In the era of HIV/AIDS, anogenital lesions may be the first manifestation of KS in immunocompromised individuals and should be biopsied. The histological diagnosis should be confirmed by HHV-8 immunohistochemistry.

1. Introduction

The human herpes virus-8 (HHV-8), also called Kaposi's sarcoma herpes virus (KSHV), is the causative agent of all types of Kaposi's sarcoma (KS), namely the classic, endemic, iatrogenic immunosuppression, and the epidemic/human immunodeficiency virus (HIV) related forms. The modes of acquisition of the KSHV and its transmission vary with age, gender, geography, and sexual practices [1]. Although the virus is omnipresent its incidence is highest in KS endemic regions such as sub-Saharan Africa (sSA).

In Uganda, HHV-8 DNA was detected in 28 percent of oral swabs and 27 percent of blood samples of healthy asymptomatic subjects [2]. Hence, saliva is a potential source of transmission. KSHV is transmitted to children from maternal and nonmaternal sources in KS-endemic regions, and occurs via nonsexual routes [3–6]. It has been shown that, in sSA, infection occurs during childhood mainly via maternal saliva and breast milk [7, 8]. Anthropologic research in sSA has identified that pre-mastication of foods of infants and children is traditional, and that saliva, semen, and vaginal fluids are used while engaging in nonsexual practices associated with childcare [9–11].

The sexual transmission of KSHV is more controversial. In the industrialized world, there is evidence of transmission between men having sex with men (MSM) via anal but not oroanal sex [7, 12, 13]. Heterosexual transmission is affirmed by some [14–18]. Others deny it [5, 19]. Since KSHV is present in semen and in uterine cervical scrapings, sexual transmission appears to be very plausible [17, 20, 21]. However, despite the high incidence of KSHV infection and its presence in the male and female genital tract, surprisingly few cases of anogenital KS have been reported in the literature, associated or not with HIV coinfection, in males or females [22–27].

The purpose of this study was to describe the clinical and histopathological spectrum of anogenital lesions either under- or overdiagnosed as KS in a HIV/AIDS endemic province of South Africa.

2. Materials and Methods

The study was carried out at the Histopathology Department of the National Health Laboratory Service of the Limpopo Province. The population is mainly rural and is in excess of

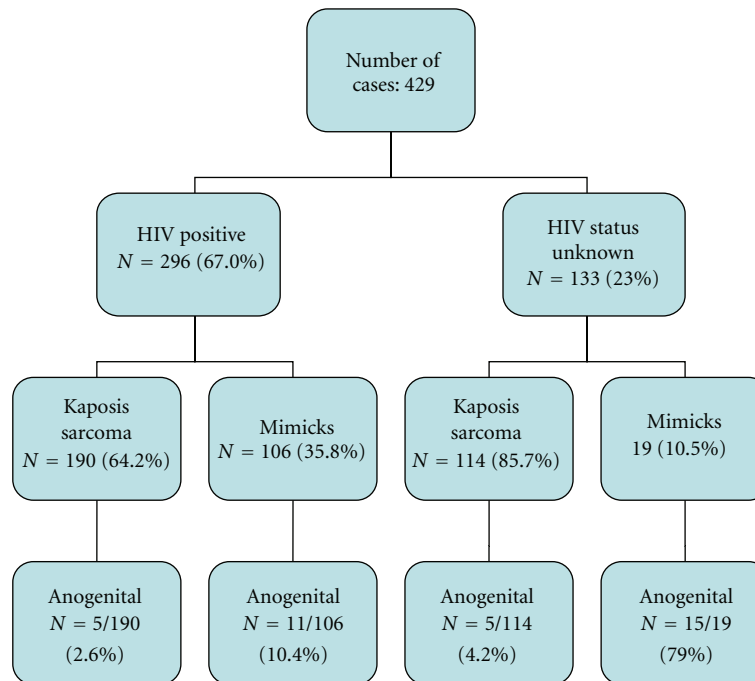


FIGURE 1: Flow chart of the distribution of cases.

5 M. The department receives and reports all the histology specimens from the public hospitals in the province.

The cases were retrieved from a prospective survey of 429 biopsy and LAN-1 immunohistochemically stained cases from March 2010 through July 2012 (Figure 1). Patients' data were recorded from the biopsy request form and the laboratory data base. The following information was compiled: age, gender, clinical information, clinical provisional diagnosis, and HIV serostatus.

Routine streptavidin-biotin-peroxidase immunostaining with diaminobenzidine was performed on formalin-fixed paraffin-embedded tissue using a murine monoclonal antibody directed against the C-terminus of the latent nuclear antigen-1 (LNA-1) molecule of HHV-8 (clone 13B10; Novocastra, Newcastle upon Tyne, UK).

Patients' anonymity was preserved. Ethical approval was obtained from the institutional research ethics committee.

3. Results

Figure 1 illustrates the distribution of cases by HIV status, immunohistochemically diagnosed KS, and mimicks. We collected a total of 36 cases of anogenital lesions: 15 in males and 21 in females. Sixteen (44.4%) had a documented HIV infection; 20 were of unknown HIV serostatus.

Table 1 shows the clinicopathology of male anogenital lesions. There were 4 KS and 11 mimicks; four (26.6%) were HIV-positive. Pyogenic granulomas accounted for 7 (46.6%) of non-KS lesions. KS was clinically suspected in one case only.

Table 2 illustrates the clinicopathological presentation of female anogenital lesions. Twelve (46.2%) were known to be

HIV-positive. The clinical diagnosis of KS was made in cases with known disseminated KS.

4. Discussion

African endemic KS has been identified for many decades in the past. Currently, the increasing prevalence of HIV infection complicates all efforts to clearly distinguish the endemic variant from the HIV-related one [28]. The clinical presentation and natural history of the endemic KS are now blending with those of the epidemic or AIDS-associated disease [29]. The distinction is clinically relevant because, although it is amenable to highly active antiretroviral treatment (HAART), AIDS-associated KS carries a poor prognosis [30]. Unfortunately, in South Africa, there is still widespread reluctance to be tested for HIV. This is attributable to the official opt-in policy (voluntary counseling and testing), and the fear of stigma and discrimination. This adds to the difficulty in distinguishing endemic from epidemic KS cases.

Early reports on African KS concentrated on the gender differences and histological features [31, 32]. One publication indicated that the most common presentation was cutaneous; it emphasised the rarity of anogenital location [33]. In a textbook of 1957, Bluefarb cited six patients with KS of the glans penis [34]. A series of 29 KS cases retrospectively collected from 1973 till 1985 in Uganda mentioned external genital involvement of 15 [35]. A Nigerian report mentioned that anogenital involvement was more common in HIV-positive cases [36]. A more recent publication of 66 biopsy-confirmed KS and HIV-seropositive patients found 10 (15.2%) genital sites (not otherwise specified); no genital KS was found in 11 cases of endemic KS [28]. Among

TABLE 1: Clinicopathological presentation of anogenital lesions in males.

Age	HIV Status	Clinical Presentation	Histopathology
54	Unknown	Scrotal mass	Nodular stage KS
38	Positive	Perineal ulcer	Plaque stage KS
29	Unknown	Penile ulcer	Nodular stage KS
35	Unknown	Penile KS	Early patch stage KS
49	Unknown	Scrotal ulcer	Pyogenic granuloma
34	Positive	Scrotal ulcer	Pyogenic granuloma
27	Unknown	Scrotal pyogenic granuloma	Pyogenic granuloma
72	Unknown	Scrotal ulcer	Pyogenic granuloma
30	Unknown	Penile ulcer	Pyogenic granuloma
59	Positive	Perianal ulcer	Pyogenic granuloma
63	Unknown	Perianal ulcer	Pyogenic granuloma
47	Unknown	Perianal nodule	Hemangioma
24	Unknown	Scrotal nodule	Hemangioma
32	Positive	Fournier's gangrene	Fournier's gangrene
41	Unknown	Penile nodule	Malignant fibrous histiocytoma

TABLE 2: Clinicopathological presentation of anogenital lesions in females.

Age	HIV Status	Clinical Presentation	Histopathology
48	Positive	Vulvar mass	Nodular stage KS
31	Positive	Vulvar mass (disseminated KS)	Nodular stage KS
33	Unknown	Cervical erosion	Nodular stage KS
34	Positive	Vulvar nodule	Early patch stage KS
24	Unknown	Vulvar nodule	Nodular stage KS
24	Positive	Vaginal KS	Nodular stage KS
19	Positive	Vulvar KS	Pyogenic granuloma
48	Unknown	Anal ulcer	Pyogenic granuloma
40	Unknown	Vaginal ulcer	Pyogenic granuloma
35	Positive	Vulvar nodule	Pyogenic granuloma
44	Positive	Vulvar nodule	Pyogenic granuloma
22	Negative	Vulvar nodule	Pyogenic granuloma
44	Positive	Anal ulcer	Pyogenic granuloma
25	Positive	Vulvar nodule	Fibrous histiocytoma
25	Positive	Vulvar carcinoma	Fibrous histiocytoma
49	Unknown	Vulvar nodule	Fibrous histiocytoma
58	Unknown	Cervical mass	Pedunculated leiomyoma
49	Unknown	Vulvar violaceous lesion	Lichen planus
42	Positive	Vulvar dark skin patch	Melanocytic melanoma
45	Positive	Vulvar nodule	Hemangioma
43	Unknown	Cervical erosion	Cervical cancer

twenty biopsy-proven Nigerian KS, the penis and rectum were involved in what appears to be cases of disseminated KS [37]. In an Ugandan series of 197 HIV-associated KS (only 62% biopsy-proven) it was reported that 6% were located on the genitals (no gender distribution or precise anatomic location); half of the series had lesions in two or more anatomic locations [38]. The difficulty with most of these reports is that the anogenital location seems to have been part of multicentric or disseminated KS, and that none was LNA-1 confirmed.

It is now well established that both the clinical and histological diagnosis of KS is fraught with over- and under-diagnosis because of the wide range of mimickers [39, 40]. Therefore, especially in HIV/AIDS and KS endemic areas, a clinical lesion suspect of KS should be biopsied, and the histopathological diagnosis must be supported by HHV-8 immunohistochemistry. Clinically, the most common mimickers are seborrheic keratosis, haemangioma, and pyogenic granulomas. Histopathologically, around thirty lesions are part of the differential diagnosis [39, 40]. Seborrheic

keratosis mimicks early patch stage KS. Pyogenic granulomas and haemangioma mimick nodular stage KS. Fibrous histiocytoma and tendosynovitis mimick the plaque stage, to name only a few and most common ones.

Literature case reports all illustrate that vulvar KS appeared clinically as a mass, a papilloma, or an abscess; none was initially suspected to be a KS [22–26]. In the present series, KS was clinically diagnosed only in one instance; one was overdiagnosed microscopically as KS before LAN-1 immunostaining.

In conclusion, anogenital KS is rare and easily misdiagnosed even in HIV/KS endemic regions. Therefore, a high clinical suspicion threshold should prompt a biopsy, and the diagnosis of KS should be confirmed by LNA-1 immunohistochemistry to avoid misdiagnosis and wrong management.

Conflict of Interests

The author declares no conflict of interests.

References

- [1] B. Biryahwaho, S. C. Dollard, R. M. Pfeiffer et al., “Sex and geographic patterns of human herpesvirus 8 infection in a nationally representative population-based sample in Uganda,” *Journal of Infectious Diseases*, vol. 202, no. 9, pp. 1347–1353, 2010.
- [2] C. Johnston, J. Orem, F. Okuku et al., “Impact of HIV infection and Kaposi Sarcoma on human herpesvirus-8 mucosal replication and dissemination in Uganda,” *PLoS ONE*, vol. 4, no. 1, Article ID e4222, 2009.
- [3] S. M. Mbulaiteye, R. M. Pfeiffer, D. Whitby, G. R. Brubaker, J. Shao, and R. J. Biggar, “Human herpesvirus 8 infection within families in rural Tanzania,” *Journal of Infectious Diseases*, vol. 187, no. 11, pp. 1780–1785, 2003.
- [4] S. Mbulaiteye, V. Marshall, R. K. Bagni et al., “Molecular evidence for mother-to-child transmission of Kaposi sarcoma-associated herpesvirus in Uganda and K1 gene evolution within the host,” *Journal of Infectious Diseases*, vol. 193, no. 9, pp. 1250–1257, 2006.
- [5] A. A. Adjei, H. B. Armah, F. Gbagbo, I. Boamah, C. Adu-Gyamfi, and I. Asare, “Seroprevalence of HHV-8, CMV, and EBV among the general population in Ghana, West Africa,” *BMC Infectious Diseases*, vol. 8, article 111, 2008.
- [6] L. M. Butler, W. A. Were, S. Balinandi et al., “Human herpesvirus 8 infection in children and adults in a population-based study in rural Uganda,” *Journal of Infectious Diseases*, vol. 203, no. 5, pp. 625–634, 2011.
- [7] R. Bagni and D. Whitby, “Kaposi’s sarcoma-associated herpesvirus transmission and primary infection,” *Current Opinion in HIV and AIDS*, vol. 4, no. 1, pp. 22–26, 2009.
- [8] M. Dedicoat, R. Newton, K. R. Alkharsah et al., “Mother-to-child transmission of human herpesvirus-8 in South Africa,” *Journal of Infectious Diseases*, vol. 190, no. 6, pp. 1068–1075, 2004.
- [9] J. M. Wojcicki, “Traditional behavioural practices, the exchange of saliva and HHV-8 transmission in sub-Saharan African populations,” *British Journal of Cancer*, vol. 89, no. 10, pp. 2016–2017, 2003.
- [10] J. M. Wojcicki, R. Newton, M. I. Urban et al., “Risk factors for high anti-HHV-8 antibody titers ($\geq 1:51,200$) in black, HIV-1 negative South African cancer patients: a case control study,” *BMC Infectious Diseases*, vol. 3, article 21, 2003.
- [11] J. M. Wojcicki, C. Kankasa, C. Mitchell, and C. Wood, “Traditional practices and exposure to bodily fluids in Lusaka, Zambia,” *Tropical Medicine and International Health*, vol. 12, no. 1, pp. 150–155, 2007.
- [12] G. J. P. van Griensven, E. C. Boucher, and R. A. Coutinho, “Oro-anal sex and the occurrence of Kaposi’s sarcoma,” *Genitourinary Medicine*, vol. 69, no. 1, pp. 77–78, 1993.
- [13] E. A. Engels, J. O. Atkinson, B. I. Graubard et al., “Risk factors for human herpesvirus 8 infection among adults in the United States and evidence for sexual transmission,” *Journal of Infectious Diseases*, vol. 196, no. 2, pp. 199–207, 2007.
- [14] M. A. Eltom, S. M. Mbulaiteye, A. J. Dada, D. Whitby, and R. J. Biggar, “Transmission of human herpesvirus 8 by sexual activity among adults in Lagos, Nigeria,” *AIDS*, vol. 16, no. 18, pp. 2473–2478, 2002.
- [15] L. Lavreys, B. Chohan, R. Ashley et al., “Human herpesvirus 8: seroprevalence and correlates in prostitutes in Mombasa, Kenya,” *Journal of Infectious Diseases*, vol. 187, no. 3, pp. 359–363, 2003.
- [16] C. Henke-Gendo and T. F. Schultz, “Transmission and disease association of Kaposi’s sarcoma-associated herpes virus: recent developments,” *Current Opinion in Infectious Diseases*, vol. 17, no. 1, pp. 53–57, 2004.
- [17] O. Bagasra, D. Patel, L. Bobroski et al., “Localization of human herpesvirus type 8 in human sperms by in situ PCR,” *Journal of Molecular Histology*, vol. 36, no. 6-7, pp. 401–412, 2005.
- [18] A. Dupuy, T. Schulz, S. Chevret et al., “Asymmetrical transmission of human herpesvirus 8 among spouses of patients with Kaposi sarcoma,” *British Journal of Dermatology*, vol. 160, no. 3, pp. 540–545, 2009.
- [19] T. B. Campbell, M. Borok, B. Ndemera et al., “Lack of evidence for frequent heterosexual transmission of human herpesvirus 8 in zimbabwe,” *Clinical Infectious Diseases*, vol. 48, no. 11, pp. 1601–1608, 2009.
- [20] P. Monini, L. de Lellis, M. Fabris, F. Rigolin, and E. Cassai, “Kaposi’s sarcoma-associated herpesvirus DNA sequences in prostate tissue and human semen,” *The New England Journal of Medicine*, vol. 334, no. 18, pp. 1168–1172, 1996.
- [21] P. K. S. Chan, W. H. Li, M. Y. M. Chan, and A. F. B. Cheng, “Detection of human herpesvirus 8 in cervical cells of Chinese women with abnormal Papanicolaou smears,” *Clinical Infectious Diseases*, vol. 29, no. 6, pp. 1584–1585, 1999.
- [22] A. F. Audouin, P. Lopes, and Y. Lenne, “Kaposi’s sarcoma of the uterine cervix and atypical condyloma in a female patient with a heart transplant (during the postpartal period),” *Archives d’Anatomie et de Cytologie Pathologiques*, vol. 36, no. 5-6, pp. 226–228, 1988.
- [23] S. B. Rajah, J. Moodley, D. J. Pudifin, J. Duursma, and K. Cooper, “Kaposi’s sarcoma associated with acquired immunodeficiency syndrome presenting as a vulvar papilloma. A case report,” *South African Medical Journal*, vol. 77, no. 11, pp. 585–586, 1990.
- [24] M. A. Macasaet, A. Duerr, W. Thelmo, S. D. Vernon, and E. R. Linger, “Kaposi sarcoma presenting as a vulvar mass,” *Obstetrics and Gynecology*, vol. 86, no. 4, pp. 695–697, 1995.
- [25] R. M. Riggs and J. McCarthy, “Vulvar Kaposi’s sarcoma in a woman with AIDS: a case report,” *Journal of Reproductive Medicine for the Obstetrician and Gynecologist*, vol. 50, no. 9, pp. 730–732, 2005.
- [26] B. W. Laartz, C. Cooper, A. Degryse, and J. T. Sinnott, “Wolf in sheep’s clothing: advanced kaposi sarcoma mimicking vulvar

- abscess," *Southern Medical Journal*, vol. 98, no. 4, pp. 475–477, 2005.
- [27] K. H. Kim, J. I. Choi, K. H. Ryu et al., "Primary classic Kaposi's sarcoma of the penis in an HIV-negative patient," *Korean Journal of Urology*, vol. 51, no. 11, pp. 803–806, 2010.
- [28] G. Wamburu, E. J. Masenga, E. Z. Moshi, P. Schmid-Grendelmeier, W. Kempf, and C. E. Orfanos, "HIV—associated and non—HIV associated types of Kaposi's sarcoma in an African population in Tanzania. Status of immune suppression and HHV-8 seroprevalence," *European Journal of Dermatology*, vol. 16, no. 6, pp. 677–682, 2006.
- [29] O. W. Mwanda, P. Fu, R. Collea, C. Whalen, and S. C. Remick, "Kaposi's sarcoma in patients with and without human immunodeficiency virus infection, in a tertiary referral centre in Kenya," *Annals of Tropical Medicine and Parasitology*, vol. 99, no. 1, pp. 81–91, 2005.
- [30] K. M. Chu, G. Mahlangeni, S. Swannet, N. P. Ford, A. Boulle, and G. Van Cutsem, "AIDS-associated Kaposi's sarcoma is linked to advanced disease and high mortality in a primary care HIV programme in South Africa," *Journal of the International AIDS Society*, vol. 13, no. 1, article 23, 2010.
- [31] J. A. Gordon, "Kaposi's sarcoma: a review of 136 Rhodesian African cases," *Postgraduate Medical Journal*, vol. 43, no. 502, pp. 513–519, 1967.
- [32] K. M. O'Connell, "Kaposi's sarcoma: histopathological study of 159 cases from Malawi," *Journal of Clinical Pathology*, vol. 30, no. 8, pp. 687–695, 1977.
- [33] G. Slavin, H. M. Cameron, and H. Singh, "Kaposi's sarcoma in mainland Tanzania: a report of 117 cases," *British Journal of Cancer*, vol. 23, no. 2, pp. 349–357, 1969.
- [34] S. M. Bluefarb, *Kaposi's Sarcoma*, Charles Thomas, Springfield, Ill, USA, 1957.
- [35] E. Katongole-Mbidde, C. Banura, and M. Nakakeeto, "Diagnostic implications of genital Kaposi's sarcoma," *East African Medical Journal*, vol. 66, no. 8, pp. 499–502, 1989.
- [36] A. Z. Mohammed, E. J. C. Nwana, and A. N. Manasseh, "Changing patterns of Kaposi's sarcoma in Nigerians," *Tropical Doctor*, vol. 35, no. 3, pp. 168–169, 2005.
- [37] M. B. Kagu, H. A. Nggada, H. I. Garandawa, B. H. Askira, and M. A. Durosinmi, "AIDS-associated Kaposi's sarcoma in Northeastern Nigeria," *Singapore Medical Journal*, vol. 47, no. 12, pp. 1069–1074, 2006.
- [38] W. Phipps, F. Ssewankambo, H. Nguyen et al., "Gender differences in clinical presentation and outcomes of epidemic kaposi sarcoma in Uganda," *PLoS ONE*, vol. 5, no. 11, Article ID e13936, 2010.
- [39] S. R. Long, M. J. Whitfeld, C. Eades, J. E. Koehler, A. P. Korn, and C. J. Zaloudek, "Bacillary angiomatosis of the cervix and vulva in a patient with AIDS," *Obstetrics and Gynecology*, vol. 88, no. 4, pp. 709–711, 1996.
- [40] J. L. Urquhart, A. Uzieblo, and S. Kohler, "Detection of HHV-8 in pyogenic granuloma-like kaposi sarcoma," *American Journal of Dermatopathology*, vol. 28, no. 4, pp. 317–321, 2006.