

## Case Report

---

# Gastrointestinal Complications of Intra-Abdominal Desmoid Tumors: A Case Report and Review of the Literature

Darcy Morris<sup>a</sup> Raquel Gonzalez<sup>b</sup> Jane Cook<sup>c</sup> Jonathan Metts<sup>d</sup>  
Peter Shaw<sup>d</sup>

<sup>a</sup>Office of Medical Education, Johns Hopkins All Children's Hospital, St. Petersburg, FL, USA;

<sup>b</sup>Division of Pediatric Surgery, Johns Hopkins All Children's Hospital, St. Petersburg, FL,

USA; <sup>c</sup>Division of Radiology, Johns Hopkins All Children's Hospital, St. Petersburg, FL, USA;

<sup>d</sup>Cancer and Blood Disorders Institute, Johns Hopkins All Children's Hospital, St. Petersburg, FL, USA

## Keywords

Desmoid tumor · Tumor perforation · Bowel obstruction · Case report

## Abstract

A 15-year-old male with a mesenteric desmoid tumor and underlying familial adenomatous polyposis presented 2 weeks after initiating sorafenib with severe abdominal pain and chills and was found to have an acute abdomen. Exploratory laparotomy revealed a necrotic, ruptured tumor with impending small bowel obstruction. The patient was later able to resume sorafenib and experienced sustained a radiographic response. It is possible that sorafenib toxicity contributed to tumor rupture yet later provided clinical benefit. Here we review the gastrointestinal complications that are associated with intra-abdominal desmoid tumors and their therapies.

© 2022 The Author(s).

Published by S. Karger AG, Basel

## Introduction

Desmoid tumor (DT; aggressive fibromatosis) is a locally aggressive soft tissue neoplasm arising from musculoaponeurotic planes found most often in adolescents and young adults. It is an extremely rare neoplasm, accounting for only an incidence of 0.03% of all neoplasm

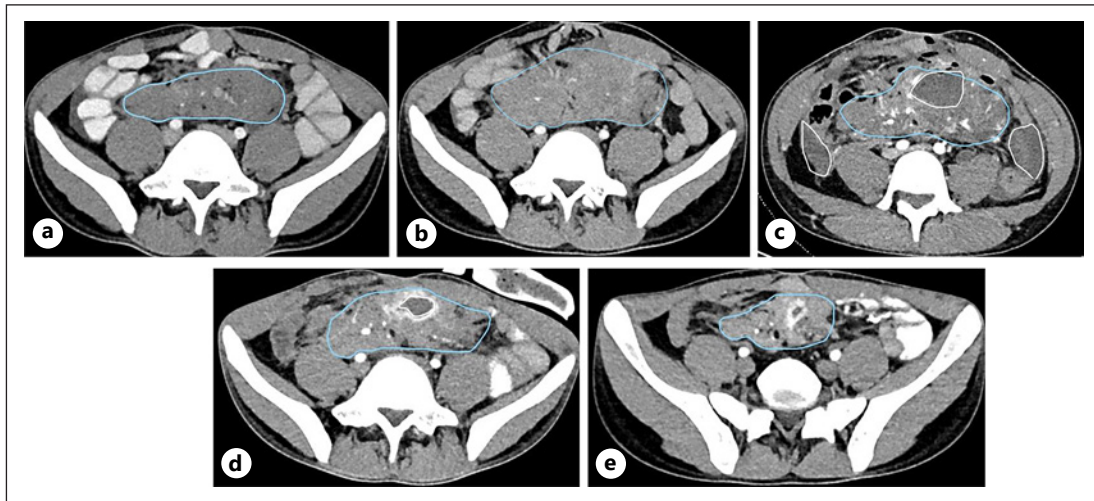
diagnoses and 3% of all soft-tissue neoplasms [1]. While DT is classified as benign due to the absence of metastatic potential, it carries a significant morbidity burden due to its locally infiltrative behavior [2]. While DT may present spontaneously, patients with familial adenomatous polyposis (FAP) carry a significantly higher risk of DT (800–1,000 fold higher than the general population). DT is estimated to occur in 10–15% of patients with FAP and represents the main risk of early mortality for these patients since the introduction of prophylactic proctocolectomy [1, 3, 4]. DT in the setting of FAP typically presents within the abdominal compartment including the bowel mesentery, and despite optimal management, DT may exhibit invasive behavior, which may lead to significant complications, including intra-abdominal surgical emergencies. Here we review a case of an intra-abdominal DT complicated by tumor necrosis, perforation, and small bowel obstruction in an adolescent with FAP after initiation of a tyrosine kinase inhibitor and review gastrointestinal complications of DT.

### Case Report

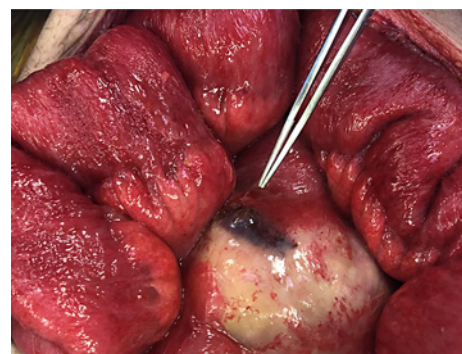
An 11-year-old male presented due to recurrent bloody stools and a paternal history of FAP. He was diagnosed with FAP with adenomatous polyposis coli (APC) gene sequencing demonstrating a five-nucleotide deletion at codon 1309, the most common pathogenic variant of APC [5]. A colonoscopy at diagnosis demonstrated more than one hundred polyps. At 12 years old, he underwent prophylactic proctocolectomy with ileoanal reconstruction and diverting ileostomy, followed by ileostomy reversal several months later. He then presented at 15 years old with severe intermittent abdominal pain for 1 month. Computed tomography (CT) of the abdomen/pelvis revealed a 4 × 11 × 13-cm soft tissue tumor within the root of the mesentery (shown in Fig. 1a). A CT-guided biopsy demonstrated a fibrotic spindle cell lesion, and immunohistochemical analysis of the specimen was positive for desmin and  $\beta$ -catenin and negative for CD117, S100, AE-1/3-keratin, and anaplastic lymphoma kinase consistent with a diagnosis of DT. The mass was located at the root of the mesentery, surrounded by mesenteric vessels. The mass was deemed unresectable due to potential compromise of the mesenteric vasculature, which could lead to loss of small bowel or even mortality. After initial hesitation by the family for medical treatment, they eventually agreed 4 months after the biopsy to start tamoxifen 120 mg once daily and sulindac 150 mg twice daily. A CT scan of the abdomen/pelvis after 6 months of this treatment revealed continued enlargement of the tumor, now measuring 6 × 12 × 16 cm (shown in Fig. 1b), and the tumor was noted to abut the distal ileum with focal ileal wall thickening.

Due to continued tumor growth, therapy was changed to sorafenib 400 mg daily. Two weeks after the initiation of sorafenib, the patient presented to the emergency department with acute, severe left-sided abdominal pain, and physical exam revealed diffuse abdominal tenderness and guarding. A CT of the abdomen/pelvis showed a rim-enhancing complex free fluid and extraluminal air in the distribution of the DT as well as rim-enhancing free fluid posterior to the rectum, concerning tumor rupture and developing abscess (shown in Fig. 1c).

He was taken emergently for exploratory laparotomy and was found to have evidence of tumor rupture within the central aspect of the tumor with evidence of necrosis, and brown, foul-smelling fluid emanating from within the mass (shown in Fig. 2). He was also noted to have purulent fluid throughout the abdominal cavity with fibrinous peel on the small bowel, stomach, and liver. There was no evidence of bowel perforation, although several loops of small bowel were densely adhered to the tumor, concerning impending obstruction. Therefore, a diverting ileostomy was created. Postoperatively, he was treated with



**Fig. 1.** DT images throughout the patient’s clinical course. **a** Diagnostic imaging: CT scan of the abdomen demonstrate a soft tissue mass (blue contour line) within the root of the mesentery with striated margin and surrounding lymph nodes. There is vascular encasement and displacement of surrounding bowel loops and mild lesional enhancement. **b** Imaging after tamoxifen/sulindac therapy: scan of the abdomen demonstrates visible and measurable enlargement of the central mesenteric soft tissue mass (blue contour line) by up to 1.0 cm in each dimension. The lesion has become ill-distinct from distal jejunal bowel loops in the left lower quadrant. **c** Imaging of tumor rupture: CT scan of the central mesentery just above the iliac crests demonstrates complex free fluid and extraluminal air consistent with tumor rupture (white contour lines lateral flanks). There is intralesional central necrosis with complex low attenuating collection (blue and central white contour lines). **d** Baseline imaging after surgery: abdominal CT demonstrates diminished size of the intralesional rim enhancing cavity (white contour line). The overall size of the lesion and its surrounding process has diminished in size; however, the overall tumor load appears subjectively stable (blue contour line). **e** Imaging after 10 months of sorafenib therapy: abdominal CT demonstrates significant reduction of overall tumor size (blue contour line) as well as diminished size of the rim enhancing complex central fluid collection.



**Fig. 2.** Ruptured intra-abdominal DT densely adhered to adjacent matted, inflamed small bowel.

10 days of piperacillin-tazobactam. Cultures of the abdominal fluid had polymicrobial growth with *Escherichia coli*, *Klebsiella pneumoniae*, *Streptococcus bovis*, and *Enterococcus faecalis*. The origin of the gaseous distention was presumed to be from tumor rupture secondary to the necrosis with bacterial overgrowth, as evidenced by the various organisms evident in the peritoneal fluid culture. However, a bowel microperforation which healed spontaneously cannot be excluded. Recovery was complicated by several readmissions pertaining to his ileostomy output, weight loss, and parenteral nutrition dependence.

A CT scan 4 months after surgery demonstrated a residual mass with central fluid density measuring  $4.3 \times 3 \times 3.9$  cm (shown in Fig. 1d). After extensive discussion of treatment options, the family elected to resume sorafenib. The patient reports that he tolerates the medication well, without any clinically evident toxicities notable to the patient or the medical team. Three months after re-initiation of sorafenib, the tumor had decreased in size measuring  $3.7 \times 3.1 \times 3.9$  cm, and at 10 months after initiation, it measured  $2.9 \times 1.5 \times 1.9$  cm (shown in Fig. 1e). He continues on sorafenib at this time. His ileostomy remains in place and is functional, and several rounds of surveillance imaging with oral contrast have shown normal-caliber bowel. Reversal of the ileostomy is under consideration. His overall activity level is at baseline, and overall, he is doing well, and he no longer requires parenteral nutrition.

## Discussion

We present a patient with FAP and mesenteric DT that resulted in an acute abdomen due to tumor rupture with impending small bowel obstruction several months after initial diagnosis and 2 weeks after initiating sorafenib. There are several important risk factors for developing DTs. FAP is an important risk factor for developing intra-abdominal DTs, with an approximate 800–1,000-fold increase in developing DTs compared to the general population [6]. Other important risk factors include Gardner syndrome, surgical trauma, elevated estrogen levels, and family history [1]. It may also occur postoperatively after resection of non-DT malignancies such as gastrointestinal stromal tumor or colon cancer. DTs vary greatly in their natural course, ranging in severity from asymptomatic to highly aggressive. Church [7] reported four common clinical courses DTs may take, including spontaneous resolution (10% of cases), cycles of advancement and resolution (30% of cases), clinical stability (50% of cases), and those with aggressive progression (10% of cases). Common anatomic locations of DT include the extremities and abdominal wall, though in patients with FAP, intra-abdominal tumors involving the mesentery and abdominal wall tumors comprise the majority of cases, cases with prior surgical trauma serving as a key risk factor for their development. Intra-abdominal DTs represent a clinical challenge because of their propensity to involve the bowel mesentery and the elevated risks of therapeutic surgery due to the high operative mortality rate, high risk of DT recurrence, and the stimulation of de novo DT [8].

As mentioned prior, the incidence of FAP-associated DTs is staggeringly higher than that of sporadically occurring DTs, and this difference can be explained on a molecular level. The development of DTs is associated with the Wnt-signaling cascade in the upregulation of the growth-promoting  $\beta$ -catenin protein [1]. In this cascade, the protein APC is a tumor suppressor protein that helps to regulate  $\beta$ -catenin levels through degradation. In those with FAP, an inactivating germline mutation occurs in the APC gene, leading to a null-allele of this gene. A somatic mutation in the other allele can result in a functional knockout of the APC gene, preventing the degradation of  $\beta$ -catenin. In contrast, the vast majority of sporadic cases of DT are caused by somatic oncogenic mutations that occur in the CTNNB1 gene, which encodes  $\beta$ -catenin, leading to a more stabilized and less degradable form of  $\beta$ -catenin. Both scenarios result in the overexpression of the growth-promoting  $\beta$ -catenin protein, leading to neoplasms, and in mesenchymal cells, the development of DTs. As such, DT should be highly considered in patients with nuclear  $\beta$ -catenin expression on biopsy of smooth muscle or fibroblastic neoplasms. In fact, in a study by Bhattacharya et al. [9], all DTs studied, including both sporadic and FAP-associated, demonstrated diffuse nuclear staining of  $\beta$ -catenin, whereas none of the other lesions examined had nuclear  $\beta$ -catenin.

Imaging plays an important role in diagnosis, pre-surgical planning, and follow-up of intra-abdominal DTs. In the effort to limit radiation for the pediatric patient, these tumors are often first seen by ultrasound at presentation; however, ultrasound has limited value as DTs can be seen with variable echogenicity, variable margins, and, if large, not fully visualized. Once identified, these patients are referred for CT imaging for improved characterization and extent of the tumor. CT findings of a DT are not specific but include hyperdense to muscle on non-enhanced contrast CT with variable and heterogeneous hypoenhancement on contrast enhanced CT [10]. These tumors typically arise in the mesentery and become aggressive, which can displace, retract, encase, or compress adjacent bowel loops. There can also be invasion into adjacent bowel, organs, and abdominal wall musculature, encasement of mesenteric vessels, and often central cavitation, which may have air fluid levels if there is concomitant invasion and communication with a bowel lumen. Magnetic resonance imaging of DT demonstrates iso- to hyperintense to skeletal muscle on T2-weighted and isointense to muscle on T1-weighted images and is commonly used in abdominal wall and extra-abdominal DT. Position emission tomography has a more limited role in the management of DT; these tumors have low avidity to F-18 FDG due to low metabolic activity of the tumor [10]. Monitoring therapeutic response can be done by CT (the preferred modality) to look for size and attenuation changes, or by MR imaging by monitoring size, T2 signal intensity, and degree of enhancement.

In recent years, initial observation has been recommended in DT except when surgically reversible life-threatening sequelae occur, or patient symptoms or rapid progression dictate the need for intervention [2]. When surgery is considered, the goal is a wide excision with negative margins to minimize the risk of recurrence. While surgical resections of abdominal wall DT are often successful, resection of intra-abdominal DT carries a higher rate of operative morbidity/mortality due to hemorrhagic complications and loss of bowel [7]. When surgical resection is contraindicated or deemed to be highly morbid, systemic therapies take on a greater role in the management of disease, often with a goal of non-progression and symptom control. Common systemic treatment modalities for intra-abdominal DT include nonsteroidal anti-inflammatory drugs such as sulindac, selective estrogen receptor modulators such as tamoxifen, surgery, and antiangiogenic agents such as sunitinib or, as in this patient, sorafenib [2]. Gounder et al. [11] demonstrated that sorafenib treatment for advanced and refractory DT conferred a 2-year progression-free survival rate of 81% versus 36% in the placebo group, including a substantial portion of patients with abdominal and intrabdominal DT. This trial did not report on the number of subjects with spontaneous DT versus those with a genetic predisposition such as FAP; thus, caution must be used in drawing conclusions on sorafenib's efficacy in the DT/FAP population.

Intra-abdominal DTs can present with a number of complications, leading to significant morbidity due to their locally aggressive and infiltrative behavior. Significant complications from DTs include bleeding, ureteral obstruction leading to hydronephrosis, fistulization, ischemia, and, as seen in this patient, tumor perforation and impending bowel obstruction [12]. Small bowel obstruction is common in FAP patients with intra-abdominal DT, with an occurrence rate ranging 27–58% [8]. While this patient's abdominal complications may have occurred spontaneously, the timing of the presentation soon after initiating sorafenib is notable. Acute abdominal emergencies may occur in DT patients treated with antiangiogenic agents due to several underlying mechanisms. First, intestinal perforation after initiation of antiangiogenic agents for DT has been described; in the phase 3 trial of sorafenib for advanced and refractory DT, 1 patient randomized to sorafenib died from disease-related intestinal perforation after initiating sorafenib, though the investigators did not attribute this toxicity to the agent [11]. In another study by Jo et al. [13], 1 patient out of 12 with intra-abdominal DTs had ileal perforation with mesenteric tumor necrosis

3 days after initiating sunitinib, which is also an antiangiogenic TKI. It is thought that angiogenic inhibitors such as sorafenib and sunitinib could damage the intestinal vasculature, leading to ischemic-mediated perforation of the bowel wall. These drugs can cause regression of capillaries in the intestinal villi leading to intestinal wall perforation [14]. Second, rapid treatment response seen with these drugs could lead to rapid onset of tumor necrosis and ultimately lead to fistula formation, hemorrhage, or perforation depending on the tumor's location and attachment to surrounding structures [13–15]. The unpredictable clinical course of DT, including occasional spontaneous regression, makes it challenging to understand the role of sorafenib in this patient's disease response; however, the unrelenting progression of the tumor despite treatment for many months followed by a consistent tumor response after sorafenib initiation increase the probability that sorafenib was therapeutic. We also suspect that rapid treatment response was the cause of our patient's tumor rupture. Even if sorafenib was the cause of tumor rupture, ultimately, given this drug's success in reducing tumor size and burden and consequently reducing the risks of other side effects of DTs including small bowel obstruction, the benefits of this drug can be seen as outweighing the potential risks.

## Conclusion

DTs are rare neoplasms that present with the highest incidence in patients with FAP. Sorafenib and other antiangiogenic agents certainly have a role in the treatment of these locally aggressive tumors, especially when active surveillance and surgery cannot provide benefit. There is a possibility for development of adverse complications such as perforation and fistulization shortly after initiating antiangiogenic treatment, warranting extensive discussion with patients and their families regarding the risk/benefit balance of treatment. Despite the potential side effects, sorafenib has demonstrated therapeutic potential and should be considered when treating these problematic tumors.

## Statement of Ethics

Johns Hopkins Medicine IRB has determined single case reports do not constitute human subjects research requiring IRB review. Written informed consent was obtained from the parent of this patient for publication of this case report and any accompanying images.

## Conflict of Interest Statement

The authors have no conflicts of interest to declare.

## Funding Sources

The authors have no funding to declare.

## Author Contributions

D.M., J.M., and P.S. wrote the manuscript. J.C. and R.G. created figures and captions.

## Data Availability Statement

All data generated or analyzed during this study are included in this manuscript. Further inquiries can be directed to the corresponding author. There are no online supplementary or multimedia material included.

## References

- Lips DJ, Barker N, Clevers H, Hennipman A. The role of APC and beta-catenin in the aetiology of aggressive fibromatosis (desmoid tumors). *Eur J Surg Oncol*. 2009;35(1):3–10.
- Gounder MM, Thomas DM, Tap WD. Locally aggressive connective tissue tumors. *J Clin Oncol*. 2018;36(2):202–9.
- Arvantis ML, Jagelman DG, Fazio VW, Lavery IC, McGannon E. Mortality in patients with familial adenomatous polyposis. *Dis Colon Rectum*. 1990 Aug;33(8):639–42.
- Nieuwenhuis MH, Casparie M, Mathus-Vliegen LM, Dekkers OM, Hogendoorn PC, Vasen HF. A nation-wide study comparing sporadic and familial adenomatous polyposis-related desmoid-type fibromatoses. *Int J Cancer*. 2010;129(1):256–61.
- Friedl W, Aretz S. Familial adenomatous polyposis: experience from a study of 1164 unrelated German polyposis patients. *Hered Cancer Clin Pract*. 2005;3(3):95.
- Campos FG, Martinez CA, Novaes M, Nahas SC, Cecconello I. Desmoid tumors: clinical features and outcome of an unpredictable and challenging manifestation of familial adenomatous polyposis. *Fam Cancer*. 2014;14(2):211–9.
- Church J. Desmoid tumors in patients with familial adenomatous polyposis. *Semin Colon Rectal Sure*. 1995;6:29–32.
- Clark SK, Neale KF, Landgrebe JC, Phillips RK. Desmoid tumours complicating familial adenomatous polyposis. *Br J Surg*. 1999;86(9):1185–9.
- Bhattacharya B, Dilworth HP, Iacobuzio-Donahue C, Ricci F, Weber K, Furlong MA, et al. Nuclear  $\beta$ -catenin expression distinguishes deep fibromatosis from other benign and malignant fibroblastic and myofibroblastic lesions. *Am J Surg Pathol*. 2005;29(5):653–9.
- Braschi-Amirfarzan M, Keraliya AR, Krajewski KM, Tirumani SH, Shinagare AB, Hornick JL, et al. Role of imaging in management of Desmoid-type fibromatosis: a primer for radiologists. *Radiographics*. 2016;36(3):767–82.
- Gounder MM, Mahoney MR, Van Tine BA, Ravi V, Attia S, Deshpande HA, et al. Sorafenib for advanced and refractory desmoid tumors. *N Engl J Med*. 2018 Dec 20;379(25):2417–28.
- Abdalla S, Wilkinson M, Wilsher M, Uzkalnis A. An atypical presentation of small bowel obstruction and perforation secondary to sporadic synchronous intra-abdominal desmoid tumours. *Int J Surg Case Rep*. 2016;20:147–50.
- Jo J-C, Hong YS, Kim K-P, Lee J-L, Lee J, Park YS, et al. A prospective Multicenter Phase II study of sunitinib in patients with advanced aggressive fibromatosis. *Invest New Drugs*. 2014;32(2):369–76.
- Qi WX, Sun YJ, Tang LN, Shen Z, Yao Y. Risk of gastrointestinal perforation in cancer patients treated with vascular endothelial growth factor receptor tyrosine kinase inhibitors: a systematic review and meta-analysis. *Crit Rev Oncol Hematol*. 2014;89(3):394–403.
- Li W, Zhou Y, Li Q, Tong H, Lu W. Intestinal perforation during chemotherapeutic treatment of intra-abdominal desmoid tumor in patients with Gardner's syndrome: report of two cases. *World J Surg Oncol*. 2016;14(1):178.