

Recurrent syncope due to glossopharyngeal neuralgia



Alexander W. den Hartog, MD,^{*} Evelien Jansen, MD,[†] Jasper E. Kal, MD, PhD,[‡]
Debby Duyndam, MD, PhD,[§] Jeldican Visser, MD, PhD,[†] Pepijn van den Munckhof, MD, PhD,[#]
Jonas S.S.G. de Jong, MD, PhD,^{*} Krischan D. Sjaauw, MD, PhD^{*}

From the ^{*}Department of Cardiology, [†]Department of Neurology, [‡]Department of Anesthesiology and Pain Clinic, [§]Department of Radiology, Onze Lieve Vrouwe Gasthuis, Amsterdam, The Netherlands, and [#]Department of Neurosurgery, Academisch Medisch Centrum, Amsterdam, The Netherlands.

Introduction

We report a rare case presenting recurrent syncope in a 50-year-old woman due to idiopathic glossopharyngeal neuralgia (GN).

The patient presented at the emergency department for recurrent syncope, starting 1 week before presentation. All episodes of syncope started with a sharp stabbing pain sensation in the left anterior side of the throat, distributing to the ipsilateral side of the neck and ear, accompanied by heavy swallowing, rotating of the head to the right, generalized tonic seizure-like movements of both arms and legs with the urge to grab the left side of the neck with her hands, and eventually followed by syncope. Syncope lasted from a few seconds up to a minute. After the attack, the patient regained complete consciousness. No postictal symptoms, such as urine incontinency or tongue bite, had occurred. Furthermore, no cardiac symptoms, such as chest pain, palpitations, or vasovagal symptoms, occurred before syncope. Talking, turning of the head, emotional stress, palpitation of the neck, or even sleeping could initiate a new episode of syncope.

There was no history of trauma, unexplained syncope, and epileptic insults or a family history of acute unexplained death. In the year before the presentation, the patient had suffered from recurrent pain on the left side of the neck without syncope for several weeks in 2 different episodes. Complete remission had occurred without any form of medical intervention.

Physical examination revealed an anxious woman. Blood pressure was 125/80 mm Hg with a regular pulse rate of 80 beats/min. The general and cardiologic examination was considered normal. Direct flexible laryngoscopy as well as

examination of ear and nose by an otolaryngologist showed no evidence of abnormality.

Neurological examination demonstrated trigger areas in the distribution of the glossopharyngeal nerve; palpation of the left side of the neck or performing the Weber and the Rinne tests (hearing tests) resulted in neck pain with subsequent bradycardia and asystole, during which patient temporarily lost consciousness. Both noninvasive and invasive monitoring showed a simultaneous decrease in the heart rate and blood pressure with the onset of pain (Figure 1).

An additional investigation showed normal hematological and biochemical examinations. An electrocardiogram demonstrated a sinus rhythm of 83 beats/min, an intermediate heart axis, and normal conduction intervals (PQ interval 150 ms, QRS interval 94 ms, and corrected QT interval 430 ms). No signs of preexcitation, ischemia, or Brugada syndrome were seen on the electrocardiogram. A computed tomographic scan and a magnetic resonance image of the brain, neck, and heart showed no evidence of a tumor or malformation of the aorta, carotid artery, cervical vasculature, or the circle of Willis. Furthermore, the parotid and the submandibular gland and their relationship with brain nerves IX and X were considered normal. An additional magnetic resonance image addressing the anatomical relationship between cranial nerves and vessels demonstrated neurovascular compression of nerve IX by a thick posterior inferior cerebellar artery (PICA). (Figures 2A and 2B).

The diagnosis of GN was made, and pregabalin 150 mg 3 times daily was initiated. Simultaneously, a temporary transvenous pacemaker was inserted because of the increasing frequency and length of syncopal episodes. This resulted in a reduction of the length of syncope (Figure 3). Therefore, a permanent demand dual-chamber pacemaker was implanted and no further episodes of syncope occurred.

Although the frequency and intensity of the pain and the length of syncope were reduced by both interventions, the patient still experienced GN-related pain attacks and pregabalin was replaced by carbamazepine 200 mg (up to 5 times daily).

Eventually, lamotrigine 200 mg 2 times daily was added to the drug regimen. This regimen of carbamazepine and

KEYWORDS Glossopharyngeal neuralgia; Cardiac syncope
(Heart Rhythm Case Reports 2017;3:73–77)

Address reprints and correspondence: Dr Alexander W. den Hartog, Department of Cardiology, Onze Lieve Vrouwe Gasthuis, Oosterpark 9, 1091 AC Amsterdam, The Netherlands. E-mail address: a.w.denhartog@olvg.nl.

KEY TEACHING POINTS

- Craniofacial pain and syncope are associated with glossopharyngeal neuralgia (GN).
- Carbamazepine is considered a first-line treatment of GN.
- Bradyarrhythmic complications of GN are treated with anticholinergic medications or with a β_2 -adrenoreceptor agonist.
- The need for demand dual-chamber pacemakers in the long-term treatment of GN remains controversial.

lamotrigine effectively suppressed both syncope and GN-related pain, and surgery was canceled.

GN

GN is a rare condition of craniofacial pain and represents 0.2%–1.3% of the cases with facial pain.^{1,2} The incidence of GN is approximately 0.8 per 100,000 persons per year and occurs more frequently in male subjects with a mean age of 50.2 ± 14 years.^{1,3–8} The frequency of cardiac syncope in GN is 2%–20%.^{5,9} The diagnostic criteria of GN according to the International Headache Society are listed in Table 1.¹⁰ However, the frequency of GN is underestimated because of difficulties in clinical diagnosis and unawareness of the disease.¹¹

The pain in GN is characterized by paroxysmal lancinating pain and is usually confined to the unilateral somatosensory distribution of the glossopharyngeal or the auricular and pharyngeal branches of the vagus, such as the pharynx. It commonly radiates to the ear and subauricular area, as well as the lateral aspect of the throat and submandibular region.^{12,13} The pain lasts from a few seconds to 5 minutes and is often precipitated or triggered by chewing, coughing, yawning, talking, and swallowing.¹⁴ Although trigger zones are rarely found in GN, syncope in our patient could be provoked by palpitation of the neck and by specific neurological examination. Accompanying symptoms include stridor, coughing, hoarseness, vomiting, sweating, and hypersalivation. GN must be differentiated from trigeminal neuralgia, which shares several characteristics with GN and can occur in a combined form in 10% of patients.¹⁵ Like trigeminal neuralgia, GN may go into spontaneous remission.⁵

“Idiopathic” cranial nerve neuralgias are attributed to a neurovascular nerve compression syndrome at the root entry zone of the respective cranial nerve.¹¹ GN is generally caused by neurovascular compression of nerve IX by the PICA,¹¹ which was first observed postmortem by Brihaye et al.¹⁶ However, several other mechanisms, besides intracranial vascular compression,^{16–21} may cause GN and include Eagle syndrome,²² cerebellopontine angle or cranial base tumors,²³ Chiari type I syndrome,²⁴ pharyngeal

tumors and abscesses,^{25–27} posterior fossa arteriovenous malformations, trauma,²⁸ and multiple sclerosis.²⁹ In our patient, these causes were excluded by neurovascular imaging.

Neurological syncope cascade

Syncope in GN related to neuralgic pain is most likely caused by activation of the dorsal motor nucleus of the vagus nerve by abnormally enhanced input from afferent or ischemic lesions of the glossopharyngeal nerve.³⁰ The reflex arrhythmia could be explained from the fact that afferent nerve impulses from the glossopharyngeal nerve may reach the tractus solitarius of the brainstem and via collateral fibers reach the dorsal motor nucleus of the vagus nerve.³¹ One afferent branch of the glossopharyngeal nerve supplies the somatosensory information to the nucleus ambiguus, while another afferent branch of the glossopharyngeal nerve, the carotid sinus nerve (Hering nerve), conducts impulses from the body of the carotid sinus to the nucleus dorsalis of the vagal nerve.³² It has been hypothesized that by artificial synapses in the glossopharyngeal nerve the impulses from the somatosensory branches stimulate the carotid sinus nerve and thereby the nucleus dorsalis. Activation of this abnormal loop during severe neuralgic pain would be responsible for bradycardia/asystole, with cerebral hypoperfusion, slowing of electroencephalographic activity, syncope, and convulsions in proportion to the duration of asystole.³³ Individual differences in the susceptibility of the dorsal motor nucleus to the pain impulse may explain why not all cases are associated with syncope.

Treatment

Both medical and surgical treatments have been used to treat GN.³⁴

Carbamazepine is considered as a first-line treatment and is thought to be useful in controlling GN-related pain by the inhibitory effect on the brain stem reflex activity.³⁵ Furthermore, it possibly prevents bradycardia.^{36,37} Other medical treatments have been reported and include gabapentin, lamotrigine, and pregabalin.^{38–41} Both pregabalin and gabapentin induce a decreasing release of excitatory neurotransmitters by acting on the $\alpha_2\delta$ subunit of calcium channels.⁴¹ Bradyarrhythmic complications of GN are treated with anticholinergic medications or with a β_2 -adrenoreceptor agonist, such as atropine, isoprenaline, or with temporary pacing.

The need for on-demand dual-chamber pacemakers in the long-term treatment of GN remains controversial.^{31,42} In 1971, a temporary transvenous cardiac pacemaker was inserted for the first time to prevent GN-related syncope.⁴³

However, pacing might prevent or only reduces the length of syncope and does not affect GN-related pain. Furthermore, pacing may not be effective in preventing GN-related syncope in patients who have important vasodepressor response.^{44–46} A permanent demand pacemaker, combined with medical treatment, should be considered depending on

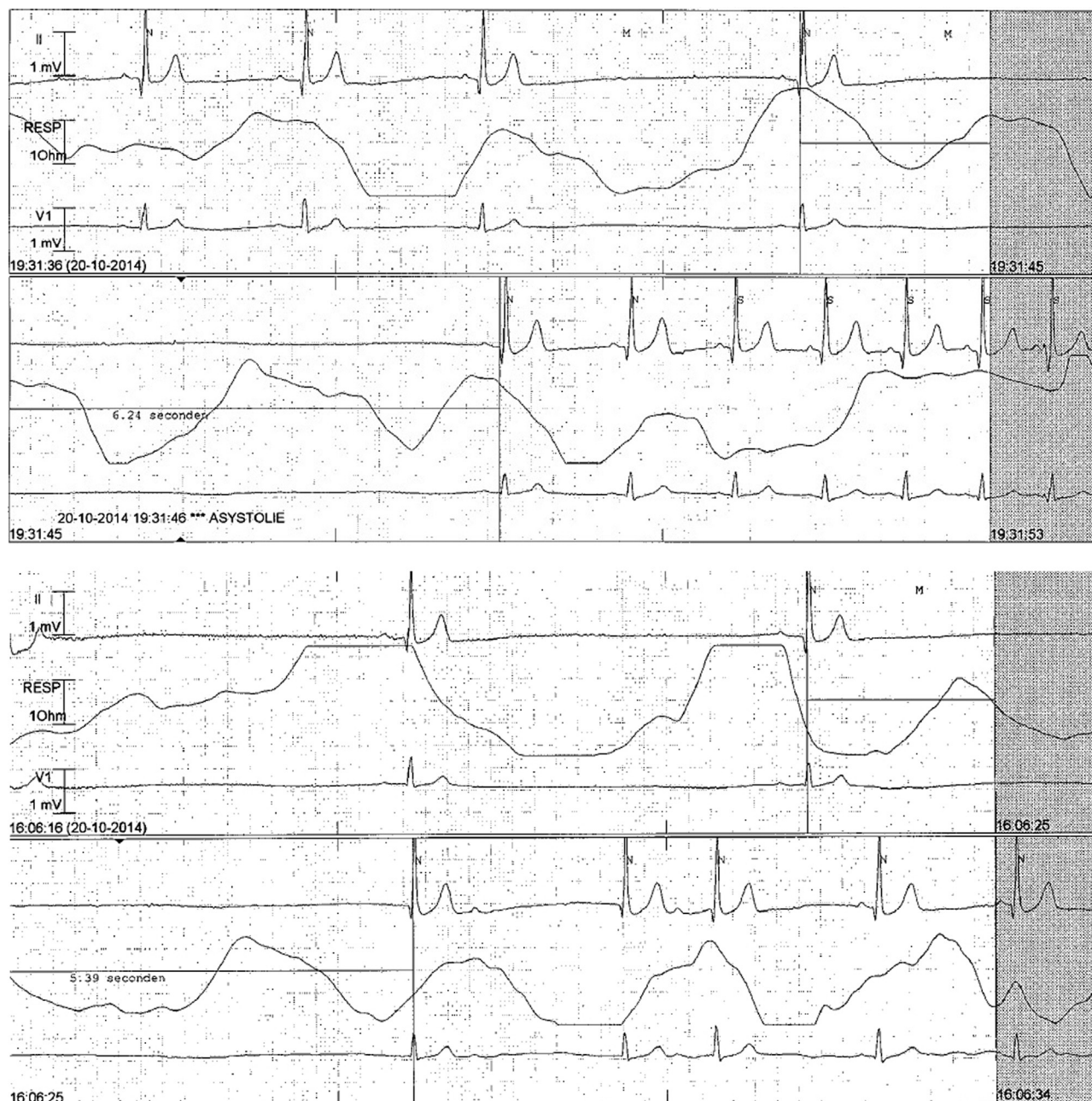


Figure 1 Continuous monitor lead electrocardiogram showing asystole followed by bradycardia and junctional escape during neuralgic pain.

the frequency of syncope and the vasodepressive response before addressing surgical intervention.⁴⁴

Neurovascular surgery

Microvascular decompression is a second-line treatment in idiopathic GN and is reserved only for those who have failed medical treatment and have dual-chamber pacemakers.^{14,47} During this surgery, dissection of the vessel will take place according to the trigeminal nerve decompression suggested by Jannetta and coworkers,⁴⁷ followed

by placing a Teflon interpositum. The rationale behind surgery is that GN is caused by direct compression of the root entry zone of the glossopharyngeal nerve, most often by the PICA, and vascular decompression could resolve this.¹¹ In 1977, Laha et al were the first to report good results of microvascular decompression for GN.¹⁸ Gaul et al¹¹ demonstrated that 16 of the 18 patients were completely pain free after microsurgical decompression for GN and no longer needed any anticonvulsant or other pain medication. Furthermore, studies have shown excellent long-term results.^{8,48}

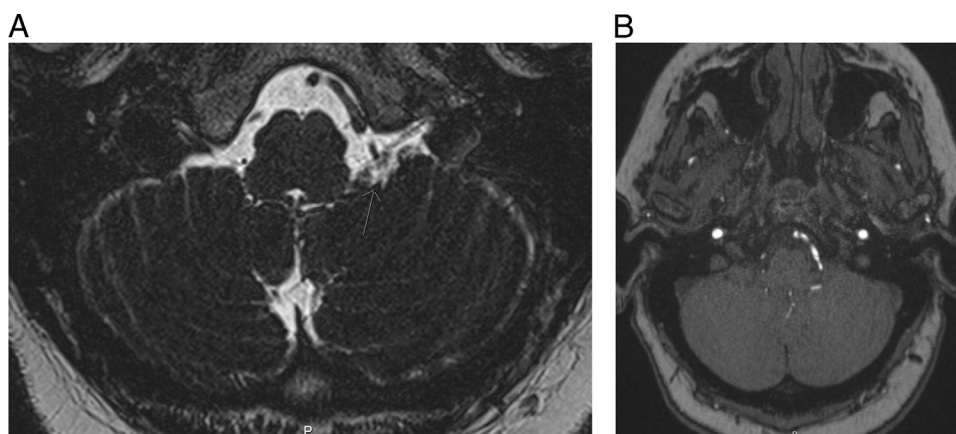


Figure 2 **A:** MRI axial 3D T2 SPACE: the arrow points to the posterior inferior cerebellar artery that cross the glossopharyngeal nerve closely. **B:** MRI axial 3D TOF: the hyperintense line next to the brainstem is the thick posterior inferior cerebellar artery. 3D = 3-dimensional; MRI = magnetic resonance imaging; T2 SPACE = Sampling Perfection with Application optimized Contrasts using different flip angle Evolution; TOF =Time of Flight.

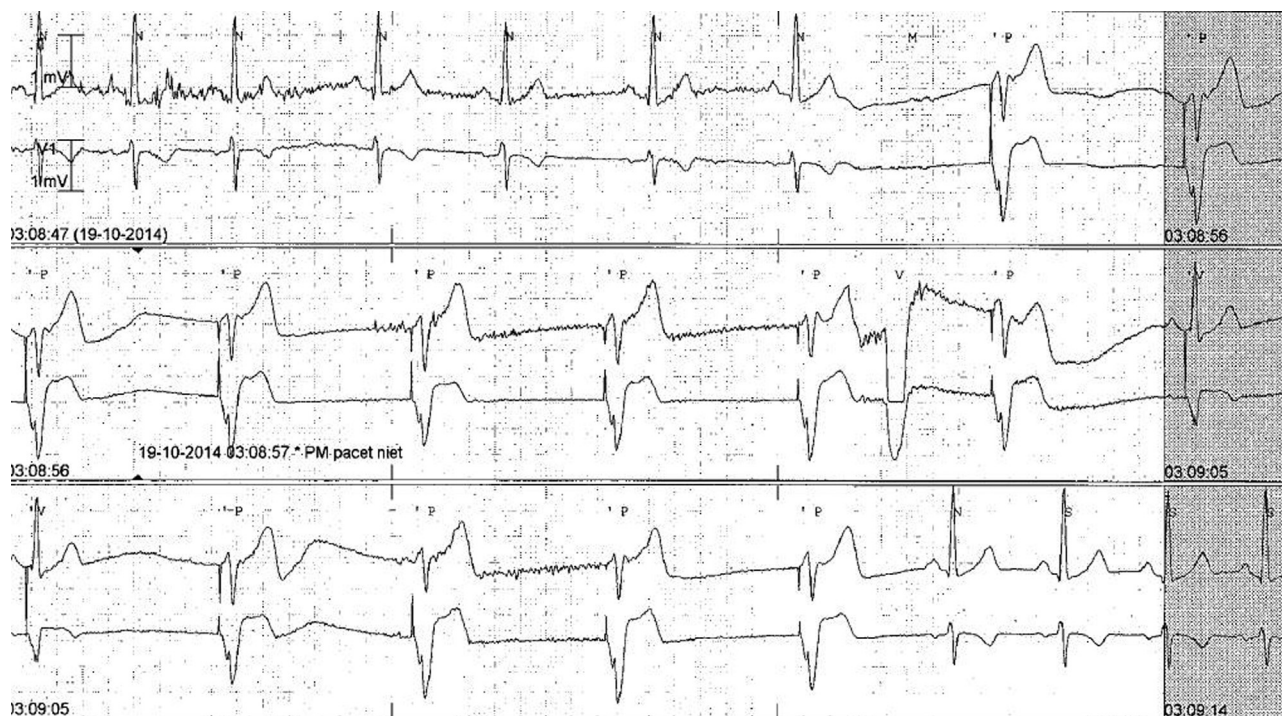


Figure 3 Continuous monitor lead electrocardiogram showing the effect of the pacemaker during an attack.

Table 1 Diagnostic criteria of glossopharyngeal neuralgia according to the International Headache Society¹⁰

1. At least 3 attacks of unilateral pain fulfilling criteria 2 and 3.
2. Pain is located in the posterior part of the tongue, tonsillar fossa, pharynx, or beneath the angle of the lower jaw and/or in the ear.
3. Pain has at least 3 of the following 4 characteristics:
 - a. Recurring in paroxysmal attacks lasting from a few seconds to 2 min
 - b. Severe intensity
 - c. Shooting, stabbing, or sharp in quality
 - d. Precipitated by swallowing, coughing, talking, or yawning
4. No clinically evident neurological deficit

References

1. Chawla JC, Falconer MA. Glossopharyngeal and vagal neuralgia. *Br Med J* 1967;3:529–531.
2. Fraioli B, Esposito V, Ferrante L, Trubiani L, Lunardi P. Microsurgical treatment of glossopharyngeal neuralgia: case reports. *Neurosurgery* 1989;25:630–632.
3. Manzoni GC, Torelli P. Epidemiology of typical and atypical craniofacial neuralgias. *Neurol Sci* 2005;26:s65–s67.
4. Katusic S, Williams DB, Beard CM, Bergstralh E, Kurland LT. Incidence and clinical features of glossopharyngeal neuralgia, Rochester, Minnesota, 1945–1984. *Neuroepidemiology* 1991;10:266–275.
5. Rushton JG, Stevens JC, Miller RH. Glossopharyngeal (vagoglossopharyngeal) neuralgia: a study of 217 cases. *Arch Neurol* 1981;38:201–205.
6. Koopman JSHA, Dieleman JP, Huygen FJ, de Mos M, Martin CGM, Sturkenboom MCJM. Incidence of facial pain in the general population. *Pain* 2009;147:122–127.
7. Pearce JMS. Glossopharyngeal neuralgia. *Eur Neurol* 2006;55:49–52.
8. Patel A, Kassam A, Horowitz M, Chang Y-F. Microvascular decompression in the management of glossopharyngeal neuralgia: analysis of 217 cases. *Neurosurgery* 2002;50:705–710. discussion 710–711.
9. Varrasi C, Strigaro G, Prandi P, Comi C, Mula M, Monaco F, Cantello RM. Complex pattern of convulsive syncope in glossopharyngeal neuralgia: video/EEG report and short review. *Epilepsy Behav* 2011;20:407–409.
10. Headache Classification Committee of the International Headache Society (IHS). The International Classification of Headache Disorders, 3rd edition (beta version). *Cephalalgia* 2013;33:629–808.
11. Gaul C, Hastreiter P, Duncker A, Naraghi R. Diagnosis and neurosurgical treatment of glossopharyngeal neuralgia: clinical findings and 3-D visualization of neurovascular compression in 19 consecutive patients. *J Headache Pain* 2011;12:527–534.
12. Svien HJ, Hill NC, Daly DD. Partial glossopharyngeal neuralgia associated with syncope. *J Neurosurg* 1957;14:452–457.
13. Taha JM, Tew JM. Long-term results of surgical treatment of idiopathic neuralgias of the glossopharyngeal and vagal nerves. *Neurosurgery* 1995;36:926–930. discussion 930–931.
14. Jamshidi A, Masroor MA. Glossopharyngeal neuralgia with cardiac syncope: treatment with a permanent cardiac pacemaker and carbamazepine. *Arch Intern Med* 1976;136:843–845.
15. Rozen TD. Trigeminal neuralgia and glossopharyngeal neuralgia. *Neurol Clin* 2004;22:185–206.
16. Brihaye J, Perier O, Smulders J, Franken L. Glossopharyngeal neuralgia caused by compression of the nerve by an atheromatous vertebral artery. *J Neurosurg* 1956;13:299–302.
17. Jannetta PJ. Cranial nerve vascular compression syndromes (other than tic douloureux and hemifacial spasm). *Clin Neurosurg* 1981;28:445–456.
18. Laha RK, Jannetta PJ. Glossopharyngeal neuralgia. *J Neurosurg* 1977;47:316–320.
19. Morales F, Albert P, Alberca R, de Valle B, Narros A. Glossopharyngeal and vagal neuralgia secondary to vascular compression of the nerves. *Surg Neurol* 1977;8:431–433.
20. Resnick DK, Jannetta PJ, Bissonnette D, Jho HD, Lanzino G. Microvascular decompression for glossopharyngeal neuralgia. *Neurosurgery* 1995;36:64–68. discussion 68–69.
21. Tsuboi M, Suzuki K, Nagao S, Nishimoto A. Glossopharyngeal neuralgia with cardiac syncope: a case successfully treated by microvascular decompression. *Surg Neurol* 1985;24:279–283.
22. Graf CJ. Glossopharyngeal neuralgia and ossification of the stylohyoid ligament. *J Neurosurg* 1959;16:448–453.
23. Orton CI. Glossopharyngeal neuralgia: its diagnosis and treatment. *Br J Oral Surg* 1972;9:228–232.
24. Aguiar PH, Tella OI, Pereira CU, Godinho F, Simm R. Chiari type I presenting as left glossopharyngeal neuralgia with cardiac syncope. *Neurosurg Rev* 2002;25:99–102.
25. Dykman TR, Montgomery EB, Gerstenberger PD, Zeiger HE, Clutter WE, Cryer PE. Glossopharyngeal neuralgia with syncope secondary to tumor: treatment and pathophysiology. *Am J Med* 1981;71:165–170.
26. Giorgi C, Broggi G. Surgical treatment of glossopharyngeal neuralgia and pain from cancer of the nasopharynx: a 20-year experience. *J Neurosurg* 1984;61:952–955.
27. Sobol SM, Wood BG, Conoyer JM. Glossopharyngeal neuralgia-asystole syndrome secondary to parapharyngeal space lesions. *Otolaryngol Head Neck Surg* 1982;90:16–19.
28. Waga S, Kojima T. Glossopharyngeal neuralgia of traumatic origin. *Surg Neurol* 1982;17:77–79.
29. Kahana E, Leibowitz U, Alter M. Brainstem and cranial nerve involvement in multiple sclerosis. *Acta Neurol Scand* 1973;49:269–279.
30. Karnosh LJ, Gardner WJ, Stowell A. Glossopharyngeal neuralgia physiological consideration of the role of ninth and tenth cranial nerves: report of cases. *Trans Am Neurol Assoc* 1947;72:205–207.
31. Giza E, Kyriakou P, Liasides C, Dimakopoulou A. Glossopharyngeal neuralgia with cardiac syncope: an idiopathic case treated with carbamazepine and duloxetine. *Eur J Neurol* 2008;15:e38–e39.
32. Ozverten MF, Türe U, Ozek MM, Pamir MN. Anatomic landmarks of the glossopharyngeal nerve: a microsurgical anatomic study. *Neurosurgery* 2003;52:1400–1410. discussion 1410.
33. Kazemi B, Akbarzadeh F. Syncopal storm caused by glossopharyngeal neuralgia. *Am J Emerg Med* 2012;30(2101):e5–e7.
34. Ferrante L, Artico M, Nardacci B, Fraioli B, Cosentino F, Fortuna A. Glossopharyngeal neuralgia with cardiac syncope. *Neurosurgery* 1995;36:58–63. discussion 63.
35. Evans RW, Torelli P, Manzoni GC. Glossopharyngeal neuralgia. *Headache* 2006;46:1200–1202.
36. Jacobson RR, Russell RW. Glossopharyngeal neuralgia with cardiac arrhythmia: a rare but treatable cause of syncope. *Br Med J* 1979;1:379–380.
37. Kim SS, Lal R, Ruffly R. Bradycardic and vasodepressor syncope secondary to glossopharyngeal neuralgia from hypopharyngeal tumor. *Am Heart J* 1985;109:1101–1102.
38. Moretti R, Torre P, Antonello RM, Bava A, Cazzato G. Gabapentin treatment of glossopharyngeal neuralgia: a follow-up of four years of a single case. *Eur J Pain Lond Engl* 2002;6:403–407.
39. Titlic M, Jukic I, Tonkic A, Grani P, Jukic J. Use of lamotrigine in glossopharyngeal neuralgia: a case report. *Headache* 2006;46:167–169.
40. Kitchener JM, Guido M, Specchio LM. Glossopharyngeal neuralgia responding to pregabalin. *Headache* 2006;46:1307–1308.
41. Savica R, Laganà A, Calabrò RS, Casella C, Musolino R. Vagoglossopharyngeal neuralgia: a rare case of syncope responding to pregabalin. *Cephalalgia* 2007;27:566–567.
42. Ozenci M, Karaoguz R, Conkbayir C, Altin T, Kanpolat Y. Glossopharyngeal neuralgia with cardiac syncope treated by glossopharyngeal rhizotomy and microvascular decompression. *Europace* 2003;5:149–152.
43. Khero BA, Mullins CB. Cardiac syncope due to glossopharyngeal neuralgia: treatment with a transvenous pacemaker. *Arch Intern Med* 1971;128:806–808.
44. Johnston RT, Redding VJ. Glossopharyngeal neuralgia associated with cardiac syncope: long term treatment with permanent pacing and carbamazepine. *Br Heart J* 1990;64:403–405.
45. Weinstein RE, Herec D, Friedman JH. Hypotension due to glossopharyngeal neuralgia. *Arch Neurol* 1986;43:90–92.
46. Cicogna R, Bonomi FG, Curnis A, Mascioli G, Bollati A, Visioli O, Rossi L. Parapharyngeal space lesions syncope-syndrome: a newly proposed reflexogenic cardiovascular syndrome. *Eur Heart J* 1993;14:1476–1483.
47. McLaughlin MR, Jannetta PJ, Clyde BL, Subach BR, Comey CH, Resnick DK. Microvascular decompression of cranial nerves: lessons learned after 4400 operations. *J Neurosurg* 1999;90:1–8.
48. Sampson JH, Grossi PM, Asaoka K, Fukushima T. Microvascular decompression for glossopharyngeal neuralgia: long-term effectiveness and complication avoidance. *Neurosurgery* 2004;54:884–889. discussion 889–890.